



The Egyptian Society of Chest Diseases and Tuberculosis
Egyptian Journal of Chest Diseases and Tuberculosis

www.elsevier.com/locate/ejcdt
www.sciencedirect.com



ORIGINAL ARTICLE

A new look at an old agent for pleurodesis

Khaled H. Mohamed ^{a,*}, Osama A. Hassan ^b

^a Department of Chest Diseases, Faculty of Medicine, Zagazig University, Egypt

^b Department of Cardiothoracic Surgery, Faculty of Medicine, Beni-Suef University, Egypt

Received 9 November 2012; accepted 5 August 2013

Available online 9 October 2013

KEYWORDS

Doxycycline pleurodesis;
Malignant pleural effusion

Abstract *Background and objective:* Malignant pleural effusion (MPE) is a common problem in patients with malignancies. Chemical pleurodesis is the most commonly used palliative option. Parenteral tetracycline (TET) and doxycycline (DOX) are cost-effective and safe in producing pleurodesis but mostly unavailable currently. We investigated whether oral doxycycline could produce an efficient and safe pleurodesis as does parenteral doxycycline, which is currently unavailable in many countries.

Methods: A prospective study of 24 pleurodesis procedures in 22 patients with malignant pleural effusions were conducted over a 3-year period. All pleurodesis was performed with oral forms of doxycycline as the sclerosing agent, where about 1000 mg of doxycycline was taken and prepared from the oral preparation (vibramycin 100 mg/capsule) and mixed in 50 ml. Physiological saline was then administered via tube thoracostomy. We assessed the success or failure of pleurodesis in addition to the frequency of complications and survival. Post-pleurodesis postero-anterior (PA) radiographs were obtained after tube removal and 30 days following the procedure.

Results: Twenty-two patients were included (6 women, 16 men), the mean age was (62.5 years). Origins of MPE were: lung and pleura 8 (36.4%), breast 2 (9.1%), ovarian 2 (9.1%), digestive 3 (13.6%), lymphoma 3 (13.6%) and unknown 4 (18.2%). No immediate perioperative complications were noted. Chest tube duration averaged 4.2 ± 2.6 days. Immediate postoperative events included chest pain in 10 patients (45.5%), fever in 2 (9.1%) patients, pain and fever in 5 patients (22.7%). Sixteen patients (72.7%) had successful pleurodesis and 6 patients (27.3%) had failed pleurodesis at 1 month.

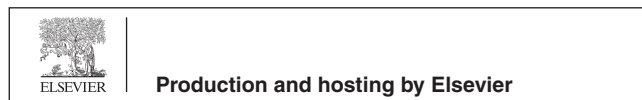
Conclusions: Pleurodesis with oral forms of doxycycline dissolved in sterile saline solution have a high success rate with a low incidence of complications and could be a good option as palliative therapy in patients with symptomatic malignant pleural effusions.

© 2013 Production and hosting by Elsevier B.V. on behalf of The Egyptian Society of Chest Diseases and Tuberculosis. Open access under [CC BY-NC-ND license](https://creativecommons.org/licenses/by-nc-nd/4.0/).

* Corresponding author. Mobile: +20 01223836717.

E-mail address: khaledmohamed@hotmail.com (K.H. Mohamed).

Peer review under responsibility of The Egyptian Society of Chest Diseases and Tuberculosis.



Introduction

Malignant pleural effusions (MPEs) affect approximately 150,000 patients each year in the United States [1]. Lung and breast cancer account for 50–65% of all MPEs, with lymphomas, cancers of the genitourinary and GI tract, and cancers with unknown primaries accounting for the majority of the remaining causes of MPE [2]. Although up to 25% of patients are initially asymptomatic from the effusion, nearly 100% of patients will experience debilitating dyspnea [3]. Despite management of the underlying malignancy with chemotherapy and/or radiation therapy, MPEs tend to persist or recur and require local palliative procedures to control symptoms. Currently available techniques for palliating the dyspnea that is associated with MPE include (1) repeated thoracentesis, (2) pleurodesis, and (3) insertion of tunneled pleural catheters (TPCs) [4].

Pleurodesis is the obliteration of the pleural space by fusion of the visceral and parietal pleurae with fibrous tissue. Recurrent and symptomatic effusions and pneumothoraces are indications for pleurodesis. Most of the agents used for pleurodesis injure the pleura and cause an inflammatory reaction together with a pleural effusion. Subsequently, the local activation of the coagulation system and the production of fibrogenic cytokines such as transforming growth factor β lead to the production of collagen that can result in a pleurodesis [5].

Currently talc [6], tetracycline derivatives [7], and bleomycin [8] are the most frequently used sclerosing agents. Bleomycin is more expensive and less efficient than tetracycline derivatives or talc [5]. The intrapleural injection of talc can cause ARDS and death [9,10]. Tetracycline (35 mg/kg) was the most effective compound when original animal experiments on producing pleurodesis in rabbits were performed [11,12]. The parenteral form of tetracycline is currently not available in most countries. Subsequently, parenteral doxycycline was used for pleurodesis at an approximate dose of 10 mg/kg and was shown to have comparable effectiveness with tetracycline at 35 mg/kg. [7,8]. However, parenteral doxycycline is also not available currently in many parts of the world. In contrast, doxycycline capsules are available worldwide but (to our knowledge) have never been tested for their efficacy and safety in producing pleurodesis in humans when administered via tube thoracostomy. We investigated whether oral doxycycline could produce an efficient and safe pleurodesis as does parenteral doxycycline, which is currently unavailable in many countries.

Subjects and methods

Study population

A prospective study of 24 pleurodesis procedures in 22 patients with malignant pleural effusions were conducted over a 3-year period from May 2009 to June 2012 at the Dallah Hospital, Riyadh, Saudi Arabia. The cause of the malignant pleural effusions was confirmed in all patients with cancer, either by cytologic examination of pleural fluid or by needle pleural biopsy or during a previous recent thoracic evaluation. Criteria for consideration as a candidate for pleurodesis in patients with malignant pleural effusions were as follows: (1) anticipated survival longer than 1 month after performance of the pleuro-

desis; (2) improved respiratory symptoms after a previous therapeutic thoracentesis; (3) cytologic or histologic confirmation of the malignant nature of the pleural effusion; and (4) ability to fully re-expand the lung during drainage of pleural fluid by tube thoracostomy [7].

Procedures and assessments

A size 24F to 28F thoracostomy tube was placed through the seventh or eighth intercostal space at the posterior axillary line and was attached to a water seal with gravity drainage. Pleural fluid volumes were recorded daily, and a chest radiography was taken daily. When the drainage fell below 100 ml/24 h and the lung had expanded completely, pleurodesis was attempted. After instillation of 10 ml of 1% lidocaine, about 1000 mg of doxycycline were taken and prepared from the oral preparation (10 capsules of vibramycin 100 mg/capsule) and mixed in 50 ml physiological saline under sterile conditions then administered via a large syringe, followed by a 30–50 ml of a sterile saline flush. The tube was clamped for 2 h, then unclamped and gravity drainage resumed. The chest tube was removed when the drainage fell below 100 ml/24 h and chest X-ray showed complete lung expansion. Patients were observed for complications, were medicated for pain as needed, and were monitored with daily chest radiographs. In two patients, in whom drainage of the pleural fluid did not diminish below 100 ml/day during the 24–72 h after the initial attempt at pleurodesis, a second intrapleural instillation of doxycycline (500 mg) was used. Post-pleurodesis postero-anterior (PA) radiographs were obtained after tube removal and 30 days following the procedure. Radiographic response at day 30 was classified as successful: no or only minor re-accumulation of pleural fluid, or non-successful: re-accumulation of fluid. Minor re-accumulation refers to re-accumulation of fluid, without symptoms or not requiring repeat drainage, above the post-sclerotherapy level but below the original level [13].

Statistical analysis

The data were expressed as mean \pm SD. All data were analyzed with statistical software (Sigma Stat; SPSS; Chicago, IL). A *p* value < 0.05 was considered significant.

Results

A total of 22 patients were included in this study, of which 16 (72.7%) were males and 6 (27.3%) were females. The mean age for the entire group was 62.5 ± 6.5 years. Pleural effusions were right sided in 10 (45.5%) cases while 12 (54.5%) cases were left sided. Origins of MPE were: lung and pleura 8 (36.4%), breast 2 (9.1%), ovarian 2 (9.1%), digestive 3 (13.6%), lymphoma 3 (13.6%) and undifferentiated carcinoma of unknown primary 4 (18.2%). (Table 1):

Sixteen patients (72.7%) had successful pleurodesis and 6 patients (27.3%) had failed pleurodesis at 1 month (Table 2).

No immediate perioperative complications were noted. Chest tube duration averaged 4.2 ± 2.6 days. Immediate post-operative events included chest pain in 10 patients (45.5%), fever in 2 (9.1%) patients, pain and fever in 5 patients (22.7%) (Table 3).

Table 1 Clinical demographics of the study patients ($n = 22$).

Number of patients	22
Sex, n (%)	
Male	16 (72.7%)
Female	6 (27.3%)
Age, years	62.5 \pm 6.5
Primary tumor, n (%)	
Malignant mesothelioma	2 (9.1%)
Bronchogenic carcinoma	6 (27.3%)
Breast	2 (9.1%)
Ovarian	2 (9.1%)
Digestive	3 (13.6%)
Lymphoma	3 (13.6%)
Unknown	4 (18.2%)
Response, n (%)	
Successful pleurodesis	16 (72.7%)
Failed pleurodesis	6 (27.3%)

Table 2 Results of doxycycline pleurodesis at 1 month.

Diagnosis	Failed pleurodesis	Successful pleurodesis
Lung cancer 6 (27.3%)	2	4 (18.2%)
m. mesothelioma 2 (9.1%)	0	2 (9.1%)
breast cancer 2 (9.1%)	1	1 (4.5%)
Ovarian 2 (9.1%)	0	2 (9.1%)
Digestive 3 (13.6%)	1	2 (9.1%)
Lymphoma 3 (13.6%)	1	2 (9.1%)
Unknown 4 (18.2%)	1	3 (13.6%)
Total 22 (100%)	6 (27.3%)	16 (72.7%)

Table 3 Adverse effects of doxycycline pleurodesis.

Diagnosis	Adverse effects			
	Non	Pain	Fever	Pain and fever
Lung cancer	2	3	0	1
M. mesothelioma	0	1		1
Breast cancer	0	2	0	0
Ovarian	0	1	0	1
Digestive	1	1	0	1
Lymphoma	1	1	0	1
Unknown	1	1	2	0
Total 22 (100%)	5 (22.7%)	10 (45.5%)	2 (9.1%)	5 (22.7%)

Discussion

Our study demonstrates that oral forms of doxycycline are as effective and safe as parenteral doxycycline in producing pleurodesis. The oral forms are less expensive and more widely available than the parenteral forms. It is likely that these results can be widely applied for malignant pleural effusion management, since parenteral tetracycline [14,15] and doxycycline [7,8] have been extensively studied and shown to be effective and safe in producing pleurodesis in patients with malignant pleural effusion.

If pleurodesis is attempted, what agent should be used? Talc is the sclerosing agent most commonly used for chemical pleurodesis by pulmonologists [16,17]. The reason that talc is the most popular agent is that it is widely available, inexpensive,

and perceived to be effective. One concern about talc is that its intrapleural administration has been associated with the development of ARDS and death in some patients. The incidence of ARDS has varied markedly from series to series, and most of the reported cases have been from the United States [9,10].

Many different agents have been injected intrapleurally in attempts to create a pleurodesis, including the tetracycline derivatives [6–8], silver nitrate [18], iodopovidone [19] and bleomycin [8]. There is no convincing evidence that talc is superior to other agents, because there have been very few randomized controlled studies comparing the different agents. Whatever sclerosing agent is used, complete drainage of the pleural effusion is considered crucial for successful pleurodesis.

Many investigators showed that intrapleural instillation of doxycycline is safe and effective for pleurodesis in malignant effusions. In this work, a new method for doxycycline delivery to the pleura was used where about 1000 mg of doxycycline was taken and prepared from the oral preparation (10 capsules of vibramycin 100 mg/capsule) and mixed in 50 ml physiological saline under sterile conditions then administered via tube thoracostomy.

In this study, the oral forms of doxycycline pleurodesis were successful in sixteen patients (72.7%) at 1 month. The effectiveness of intrapleural doxycycline observed in this study in patients with malignant pleural effusions is similar to previous reports that used parenteral doxycycline as a sclerosing agent. Heffner et al. [7] examined the outcome in 31 patients receiving doxycycline through a chest tube for malignant pleural effusions or persistent bronchopleural fistulae. Of the 27 patients with malignant pleural effusions, 21 patients had successful pleurodesis (77.8%) at 1 month. Costa et al. [20] treated 41 malignant pleural effusion patients with doxycycline pleurodesis. A successful pleurodesis (complete or partial) was accomplished in 25 (61%). Porcel et al. [21] conducted a prospective study of 36 rapid pleurodesis procedures in 34 patients with malignant pleural effusions. Patients received 500 mg of intrapleural doxycycline. Complete success of pleurodesis was achieved in (55%), partial success in (26%), and failure in (19%). Thus, the overall success rate of pleurodesis was 81%. Recently, Elnady and Sakr [22], performed pleurodesis in twenty-seven patients with malignant pleural effusion. Thoracoscopy was performed for diagnosis and subsequent doxycycline pleurodesis. At the end of thoracoscopy, a new method for doxycycline delivery to the pleura was used through a pneumatic atomizer insufflations at the end of thoracoscopy (thoracoscopic doxycycline poudrage “TDP”) where about 500–1000 mg of doxycycline was taken and prepared as a powder from the oral preparation (vibramycin 100 mg/capsule). 74.1% had a successful pleurodesis, 18.5% had partial response and 7.4% had failed pleurodesis at 1 month.

Since thoracoscopy is not widely available and needs trained pulmonologists, so doxycycline pleurodesis via tube thoracostomy is much more easier, less expensive with shorter hospital stay.

To our knowledge, Doxycycline prepared from the oral preparation and administered via tube thoracostomy had never been tested for their efficacy and safety in producing pleurodesis in humans. Moreover, the success rate obtained in our study matched that of the literature for parenteral doxycycline.

How doxycycline initiates pleural symphysis is uncertain. Analogous to tetracycline, doxycycline may damage

mesothelial surfaces and interfere with pleural reparative processes through cytostatic effects that have been demonstrated for tetracycline [23], as suggested by observations that intrapleural heparin or urokinase interferes with Tetracycline induced pleurodesis in animals. Doxycycline may interact with intrapleural thrombotic or fibrinolytic processes and induce pleurodesis [24]. Tetracycline has been shown to stimulate mesothelial cell release of growth factors for fibroblast proliferation and deposition of collagen [25]. Furthermore, doxycycline has a capacity to inhibit matrix-degrading metalloproteinases and to promote unopposed collagen and fibrin deposition in the inflamed pleural space [26]. Tetracycline and doxycycline are dose-dependent effective inhibitors of matrix-degrading metalloproteinase (MMP) activity in the pleural fluid. Thus, the pleural fibrotic process needed for pleurodesis is augmented by the reduction of MMP activity that favors remodeling through normal repair of the tissue rather than fibrosis [27].

Pain observed in 10 cases (45.5%) was due to chest tubing or the tumor itself rather than doxycycline powder. Analgesics, prescribed in general for 24 h, easily overcame this problem. A fever greater than 38.5 °C lasting for about 24 h was a recorded complication in 2 cases (9.1%) but it was easily controlled with paracetamol. Pain and fever were noticed in 5 cases (22.7%) as shown in Table 3.

In conclusion, the present study demonstrates that the intrapleural injection of the oral forms of doxycycline dissolved in sterile saline solution produces a pleurodesis that is comparable to that produced by the intrapleural injection of parenteral doxycycline with a high success rate and low incidence of complications and could be a good option as palliative therapy in patients with symptomatic malignant pleural effusions provided that meticulous care for avoiding infection is exercised.

Conflict of interest

None.

Acknowledgments

We appreciate the excellent research assistance of Dr. Abdulrazaq S. AL-Mokhalalati, consultant thoracic surgery, King saud medical city, Riyadh, KSA, who contributed to the techniques and study design.

References

- [1] V.B. Antony, R. Lodenkemper, P. Astoul, et al, Management of malignant pleural effusions, *Eur. Respir. J.* 18 (2) (2001) 402–419.
- [2] G. Antunes, E. Neville, J. Duffy, et al, BTS guidelines for the management of malignant pleural effusions, *Thorax* 58 (Suppl. 2) (2003) ii29–ii38.
- [3] B. Chernow, S.A. Sahn, Carcinomatous involvement of the pleura: an analysis of 96 patients, *Am. J. Med.* 63 (5) (1977) 695–702.
- [4] R. Chakravarthy, E. Armin, L. Carla, et al, Rapid pleurodesis for malignant pleural effusions: a pilot study, *Chest* 139 (2011) 1419–1423.
- [5] R.W. Light, *Pleural Diseases*, fourth ed., Lippincott, Williams and Wilkins, Philadelphia, PA, 2007, pp. 120–123.
- [6] D.L. Hartman, J.M. Gaither, K.A. Kesler, et al, Comparison of insufflated talc under thoroscopic guidance with standard tetracycline and bleomycin pleurodesis for control of malignant pleural effusions, *J. Thorac. Cardiovasc. Surg.* 105 (1993) 743–747.
- [7] J.E. Heffner, R.J. Standerfer, J. Torstveit, et al, Clinical efficacy of doxycycline pleurodesis, *Chest* 105 (1994) 1743–1747.
- [8] E.F. Patz, H.P. McAdams, J.J. Erasmus, et al, Sclerotherapy for malignant pleural effusions: a prospective randomized trial of bleomycin vs doxycycline with small-bore catheter drainage, *Chest* 113 (1998) 1305–1311.
- [9] Y.C.G. Lee, M.H. Baumann, N.A. Maskell, et al, Pleurodesis practice for malignant pleural effusions in five English speaking countries: survey of pulmonologists, *Chest* 124 (2003) 2229–2238.
- [10] D.H. Rehse, R.W. Aye, M.G. Florence, Respiratory failure following talc pleurodesis, *Am. J. Surg.* 177 (1999) 437–440.
- [11] F.S. Vargas, L.R. Teixeira, L.M. Silva, et al, Comparison of silver nitrate and tetracycline as pleural sclerosing agents in rabbits, *Chest* 108 (1995) 1080–1083.
- [12] R.W. Light, N.S. Wang, C.S. Sassoon, et al, Comparison of the effectiveness of tetracycline and minocycline as pleural sclerosing agents in rabbits, *Chest* 106 (1994) 577–582.
- [13] A. Sanchez-Armengol, F. Rodriguez-Panadero, Survival and talc pleurodesis in metastatic pleural carcinoma, revisited. Report of 125 cases, *Chest* 104 (1993) 1482–1485.
- [14] E. Martinez-Moragon, J. Aparicio, M.C. Rogado, et al, Pleurodesis in malignant pleural effusions: a randomized study of tetracycline versus bleomycin, *Eur. Respir. J.* 10 (1997) 2380–2383.
- [15] S.R. Dryzer, M.L. Allen, C. Strange, et al, A comparison of rotation and nonrotation in tetracycline pleurodesis, *Chest* 104 (1993) 1763–1766.
- [16] M.E. Van Meter, K.Y. McKee, R.J. Kohlwes, Efficacy and safety of tunneled pleural catheters in adults with malignant pleural effusions: a systematic review, *J. Gen. Intern. Med.* 26 (1) (2011) 70–76.
- [17] A.M. Olden, R. Holloway, Treatment of malignant pleural effusion: PleuRx catheter or talc pleurodesis? A cost-effectiveness analysis, *J. Palliat. Med.* 13 (1) (2010) 59–65.
- [18] M. da S. Paschoalini, F.S. Vargas, E. Marchi, et al, Prospective randomized trial of silver nitrate vs talc slurry in pleurodesis for symptomatic malignant pleural effusions, *Chest* 128 (2) (2005) 684–689.
- [19] J.D. Neto, S.F. de Oliveira, S.P. Vianna, R.M. Terra, Efficacy and safety of iodopovidone pleurodesis in malignant pleural effusions, *Respirology* 15 (1) (2010) 115–118.
- [20] J.S. Costa, M.L. Lombart, E. Chiner, et al, Pleurodesis in patients with malignant pleural effusions: efficacy of doxycycline, *Chest* (2006), 244S Poster Presentations Wednesday, October 25, 2006.
- [21] J.M. Porcel, A. Salud, M. Nabal, et al, Rapid pleurodesis with doxycycline through a small-bore catheter for the treatment of metastatic malignant effusions, *Support Care Cancer* 14 (5) (2006) 475.
- [22] M. Elnady, A. Sakr, Safety and efficacy of pleurodesis with thoroscopic doxycycline poudrage in malignant pleural effusion, *Chest* 140 (4) (2011), Meeting Abstracts 697A.
- [23] C. Sauter, Cytostatic activity of oxidized tetracycline in vitro. Relevance for the treatment of malignant effusions, *Br. J. Cancer* 57 (1988) 514–515.
- [24] J.T. Good Jr., T.M. I-hers, S.A. Sahn, Intrapleural heparin prevents tetracycline induced pleural symphysis [abstract], *Clin. Res.* 28 (1980) A56.
- [25] V.B. Antony, K.J. Rothfuss, S.W. Codbey, J.A. Sparks, J.W. Iltott, Mechanism of tetracycline-hydrochloride-induced pleurodesis, *Am. Rev. Respir. Dis.* 146 (1992) 1009–1013.
- [26] A.N. Hurewitz, C. Liang, P. Mancuso, S. Zucker, Tetracycline and doxycycline inhibit pleural fluid metalloproteinases, *Chest* 103 (1993) 1113–1117.
- [27] B.C. Marshall, A. Santana, Q.P. Xu, et al, Metalloproteinases and tissue inhibitor of metalloproteinases in mesothelial cells: cellular differentiation influences expression, *J. Clin. Invest.* 91 (1993) 1792–1799.