



Contents lists available at ScienceDirect

# Trauma Case Reports

journal homepage: [www.elsevier.com/locate/tcr](http://www.elsevier.com/locate/tcr)

## Case Report

# Multi-trauma secondary to hypocalcaemia-induced seizure: A case report

Rami Shenouda<sup>a,\*</sup>, Sean Carter<sup>a</sup>, Kemble Wang<sup>a</sup>, Yvonne Chow<sup>b</sup>,  
Duncan J. Topliss<sup>b,c</sup>, Max P. Esser<sup>a</sup>

<sup>a</sup> Department of Orthopaedic Surgery, The Alfred, Australia

<sup>b</sup> Department of Endocrinology & Diabetes, The Alfred, Australia

<sup>c</sup> Department of Medicine, Monash University, Australia

## ARTICLE INFO

### Article history:

Accepted 2 September 2016

Available online 24 October 2016

### Keywords:

Seizure

Fracture

Hypocalcaemia

Hyperparathyroidism

Trauma

## ABSTRACT

**Introduction:** Fractures are known sequelae of seizures. We present a young male with bilateral acetabula and surgical neck of humerus (SNOH), right neck of femur (NOF) and thoracolumbar fractures in the context of a hypocalcaemic seizure secondary to severe malnutrition, secondary hyperparathyroidism and vitamin D deficiency. The authors believe that numerous severe injuries in a single patient secondary to seizure are extremely rare and have not been seen in the literature.

**Case report:** A 25-year-old male presented to A&E following a collapse. He described limited movement and pain in all four limbs and collateral history described a generalised tonic-clonic seizure. XR and CT identified pelvic, femoral and humeral fractures, as well as compression fractures of T11, T12 and L1 vertebrae. His pelvic, femoral and SNOH fractures all required ORIF with intra-operative biopsy revealing abnormal bone quality. His spinal fractures did not require management. His young age and severe injuries prompted endocrinology and neurological evaluation. These revealed severe malnutrition secondary to behavioural and dietary factors with severe hypocalcaemia, secondary hyperparathyroidism and vitamin D deficiency. His metabolic and nutritional deficits were replaced intravenously and orally and his seizure attributed to hypocalcaemia.

**Discussion and conclusion:** Clinical suspicion for fractures should be high as the rate of fracture following seizure is approximately 6% [1]. Close

**Abbreviations:** CT, Computerised Tomography; XR, X-ray; ORIF, Open Reduction Internal Fixation; EEG, electroencephalogram; ALP, alkaline phosphatase; PTH, parathyroid hormone; 25(OH)D, 25-hydroxyvitamin D; A&E, accident and emergency; NOF, neck of femur; SNOH, surgical neck of humerus.

\* Corresponding author at: 13/703 Orrong rd, Toorak 3142, Australia.

E-mail address: [rami.shenouda@gmail.com](mailto:rami.shenouda@gmail.com) (R. Shenouda).

<http://dx.doi.org/10.1016/j.tcr.2016.09.005>

2352-6440/© 2016 The Authors. Published by Elsevier Ltd. This is an open access article under the CC BY-NC-ND license (<http://creativecommons.org/licenses/by-nc-nd/4.0/>).

evaluation and tertiary survey should be completed as missed musculo-skeletal injury has been reported to be over 10% [2] and pre-existing medical and social risk factors may increase the incidence of these injuries [3–4].

Given the young man's presentation, a high clinical suspicion was held for an underlying syndrome such as osteomalacia. Secondary to early aggressive treatment, a biopsy performed was non-diagnostic and features of osteomalacia were not present. Due to the potential consequences of a seizure, the authors recommend individuals who present with seizure or collapse be thoroughly examined and investigated to ensure no co-existing injury or pathology.

© 2016 The Authors. Published by Elsevier Ltd. This is an open access article under the CC BY-NC-ND license (<http://creativecommons.org/licenses/by-nc-nd/4.0/>).

## Introduction

Bony injuries are known sequelae of seizure activity. However, multiple injuries involving all four limbs in young patients are extremely rare. We present an unusual case of a 25-year-old male with multiple significant fractures following a hypocalcaemic seizure, including: bilateral fracture acetabula and femoral protrusion, bilateral surgical neck of humerus fractures, thoracolumbar spine compression fractures (T11, T12 and L1), and a right neck of femur fracture. This occurred in the setting of severe metabolic and nutritional derangement secondary to altered dietary habits, physical activity levels and social isolation. Informed consent was given by the patient for this report.

## Case report

A 25-year-old man initially presented to our hospital following an unknown mechanism where bilateral groin pain and limited movement in all four limbs were noted after falling unconscious in the backseat of a car. Computerised Tomography (CT) scan identified multiple injuries including bilateral acetabulae and surgical neck of humeri, thoracolumbar and right neck of femur fractures.

Collateral history from family suggested that the young man might have had a seizure in the backseat of the car. Relevant history included a potential previous episode of a seizure 2 years ago that did not result in significant injury but was never investigated. He was described as socially withdrawn, sedentary, had a poor diet and rarely ventured outside of his room. Psychiatric review found no signs of psychosis or an autism

**Table 1**  
Initial biochemistry, coagulation profile and vitamin levels.

Test	Result	Reference range
Calcium	1.41 mmol/L	2.15–2.65
Corrected calcium	1.66 mmol/L	2.15–2.65
Albumin	26 g/L	38–50
Magnesium	0.61 mmol/L	0.70–1.10
Phosphate	0.59 mmol/L	0.75–1.50
Zinc	10.9 µmol/L	12–18
Vitamin D 25 (OH)D	<10 nmol/L	>50
PTH	81.8 pmol/L	1.6–6.9
Vitamin B12	97 pmol/L	150–857
Vitamin A	0.3 µmol/L	1.0–2.8
Vitamin E	10.8 µmol/L	12–42
ALP	459 U/L	35–110
INR	1.5	0.9–1.3
Prothrombin Time (PT)	18.6 s	10.6–15.3

spectrum disorder. His lifestyle was attributed to his introverted personality, obsessive trait and disrupted family dynamics.

Endocrine consultation identified the young man to be severely hypocalcaemic with corrected calcium of 1.66 mmol/L (normal 2.15–2.65 mmol/L). This was thought to be the cause of his seizure and intravenous replacement was commenced. Further investigation identified severe micronutrient deficiencies, notably an undetectable 25-hydroxyvitamin D [25(OH)D] level (<10 nmol/L, normal >50 nmol/L) and other fat-soluble vitamin deficiencies of vitamins A and E. Vitamin K was not measured directly but an increased INR and a prolonged Prothrombin Time with no synthetic liver dysfunction were found, however these were corrected pre-operatively. Marked elevation of PTH indicated severe secondary hyperparathyroidism due to the vitamin D deficiency and hypocalcaemia. The marked hypoalbuminaemia was indicative of macronutrient deficiency. The young man's presentation was due to a hypocalcaemic seizure resulting from severe malnutrition and hypovitaminosis D, with subsequent osteomalacia and secondary hyperparathyroidism (see Table 1). Neurological assessment and an electroencephalogram (EEG) determined that the patient did not have epilepsy. All electrolyte and nutritional deficiencies were corrected during inpatient admission.

The patient's injuries were repaired with staged operative fixation, requiring a prolonged stay in the intensive care.

1) Multiple pelvic fractures (see Figs. 1 and 2)

- a. Right acetabulum (displaced acetabular fracture with anterior and posterior column involvement) – ORIF using 7 and 4 hole plates.
- b. Right neck of femur – ORIF using dynamic hip screw and screws to greater trochanter and anterior superior iliac spine.
- c. Left acetabulum (posterior wall and column fracture with anterior hemi-transverse fracture with quadrilateral plate involvement) – ORIF using 10-hole plate.

2) Left proximal humerus – ORIF using 3-hole Philos plate

3) Right proximal humerus – ORIF using 3-hole Philos plate performed four weeks post-injury

4) T11, T12, and L1 compression fracture – non-operative management with no restrictions.

Operative fixation of the right proximal humerus was performed at four weeks following injury, when surveillance radiographs failed to show any callus formation. Intraoperative biopsy was taken, and histological examination of un-decalcified bone (see Fig. 3) showed markedly irregular and thinned trabecular bone that was predominantly woven, with little osteoid surrounding it, and with increased osteoclastic resorption.

Following this he required inpatient rehabilitation for four months. On discharge home he was mobilising independently with two elbow crutches indoors and outdoors up to 40 m.

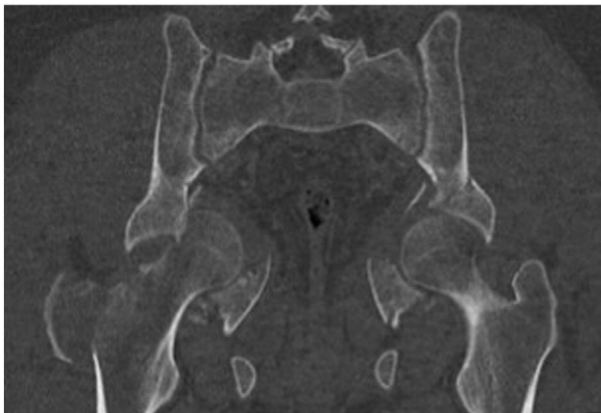
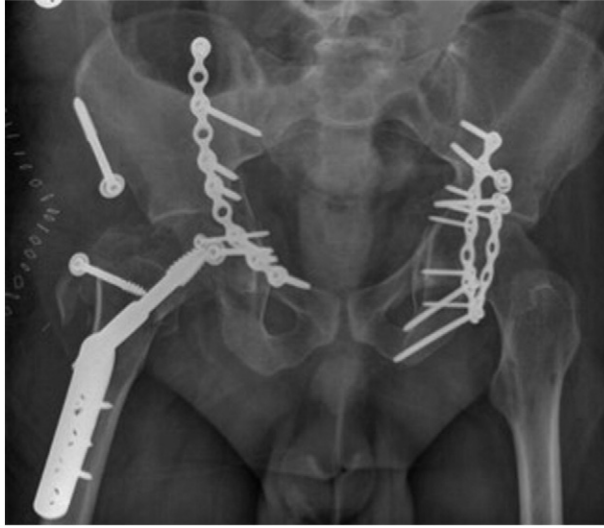
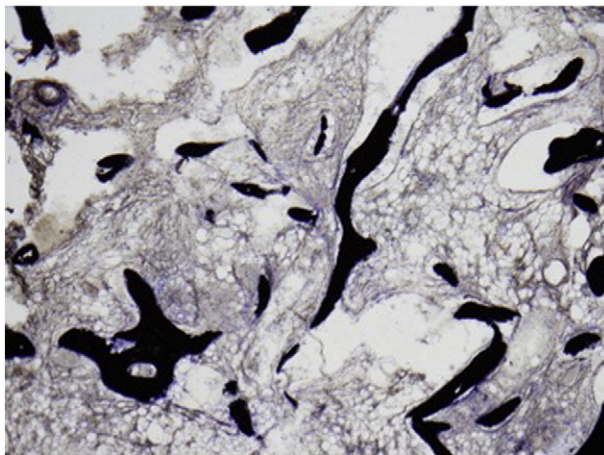
Fig. 1. Pre-operative coronal pelvic CT.



**Fig. 2.** Postoperative AP XR of the pelvis.

### Discussion and conclusion

Following a seizure, clinical suspicion for injury should be high as the rate of injury following a seizure is approximately 14% overall and 6% for fractures [1]. Close evaluation and tertiary survey should be completed following post-ictal recovery as missed musculoskeletal injury has been reported to be over 10% and can be quite severe [2]. Seizures and seizure disorders can produce repeated, forceful convulsions, and pre-existing risk factors such as malnutrition, lack of physical activity and sunlight exposure as well as anti-epileptic medication resulting in reduced bone mineral density may increase the incidence of these injuries [3–4]. Consequently sufferers have a 33% increased lifetime risk of injuries and previous studies have found that 1.1% of patients admitted for seizures also have a fracture identified [1]. Following a presentation of seizure or collapse patients should be evaluated with thorough history, examination, and judicious use of imaging as injury may affect almost any bone [5].



**Fig. 3.** Von Kossa stain. Minimal, irregular trabecular bone and almost no osteoid.

Given the young man's age, multiple injuries, and biochemistry, a high clinical suspicion for an underlying pathological process such as osteomalacia should exist [6]. Osteomalacia is the result of defective mineralisation of the bony matrix. This is distinct from osteoporosis, where there is reduced bone mineral density but normal mineralisation. It is important to distinguish the two entities as treatment differs. Causes of osteomalacia include vitamin D deficiency or defects in vitamin D metabolism, and renal phosphate wasting which can be provoked by medications such as tenofovir. Clinical manifestations of osteomalacia may include bone pain and muscle weakness along with fragility fractures. Often such clinical features are subtle or overlap with other conditions such as osteoporosis and fibromyalgia, thereby hindering recognition of osteomalacia. Diagnostic criteria include: hypocalcaemia or hypophosphatemia raised alkaline phosphatase (ALP), bony pain or muscle weakness, low bone mineral density and suggestive imaging (areas of increased bone uptake on 99mTc-MDP scintigraphy, or Looser's zones on plain radiographs) [6].

Intra-operatively, the patient's bone quality was noted to be extremely poor and a bone biopsy, if it had been taken before medical treatment, may have demonstrated the hallmark histological feature of osteomalacia: namely increased amounts of uncalcified osteoid, due to impaired bone mineralisation. We suggest that, due to the early and aggressive correction of the patient's nutritional and electrolyte abnormalities, any previously abnormal histological features of bone had resolved by the time of the late biopsy. Early diagnosis and treatment may have allowed for some reversible features of osteomalacia to be corrected and were judged to be necessary given delayed diagnosis may have irreversible consequences [7]. It is important to note that these patients may also have impaired bony union and may warrant serial radiographs for surveillance of fracture sites as seen in our case.

The authors believe that the severe and numerous injuries resulting from a single seizure seen in our case have not previously been described in the literature. We recommend that patients who present with seizure or collapse be thoroughly examined and investigated to ensure no injury is missed and no further contributing pathologies exist.

## Disclosures

A/Prof Max P. Esser is an editorial referee for Journal of Injury.

## Conflict of interest statement

All authors confirm that there are no conflicts of interest.

## Acknowledgements

We thank Dr. Louise Hughes – Sydney and South Western Sydney Local Health Districts – for the Von Kossa stains.

## References

- [1] D. Buck, G.A. Baker, A. Jacoby, D.F. Smith, D.W. Chadwick, Patients' experiences of injury as a result of epilepsy, *Epilepsia* 38 (4) (1997) 439–444 Reference for Abstract and.
- [2] N. Lasanionos, G. Mouzopoulos, An undiagnosed bilateral anterior shoulder dislocation after a seizure: a case report, *Cases J.* 1 (2008) 342.
- [3] A. Sharma, L. Avery, R. Novelline, Seizure-induced lumbar burst fracture associated with conus medullaris–cauda equina compression, *Diagn. Interv. Radiol.* 3 (2011) 199–204.
- [4] H. Shah, A. Grover, D. Gadi, K. Sudarshan, Bilateral neck femur fracture following a generalized seizure – a rare case report, *Arch. Bone Joint Surg.* 2 (4) (2014) 255–257.
- [5] L. Lidgren, A. Wallöe, Incidence of fracture in epileptics, *Acta Orthop. Scand.* 48 (4) (1977) 356–361.
- [6] S. Fukumoto, K. Ozono, T. Michigami, M. Minagawa, R. Okazaki, T. Sugimoto, et al., Pathogenesis and diagnostic criteria for rickets and osteomalacia –proposal by an expert panel supported by Ministry of Health, Labour and Welfare, Japan, the Japanese Society for Bone and Mineral Research and the Japan Endocrine Society, *Endocr. J.* 62 (8) (2015) 665–671.
- [7] R. Bhabri, V. Naik, N. Malhotra, S. Taneja, S. Rastogi, U. Ravishanker, et al., Changes in Bone Mineral Density Following Treatment of Osteomalacia, 2006.