



Altered brain morphometry in carpal tunnel syndrome is associated with median nerve pathology ☆☆☆

Yumi Maeda ^{a,b,*}, Norman Kettner ^b, James Sheehan ^c, Jieun Kim ^a, Stephen Cina ^a, Cristina Malatesta ^d, Jessica Gerber ^a, Claire McManus ^d, Pia Mezzacappa ^a, Leslie R. Morse ^e, Joseph Audette ^f, Vitaly Napadow ^{a,b}

^a Athinoula A. Martinos Center for Biomedical Imaging, Department of Radiology, Massachusetts General Hospital, Charlestown, MA 02129, USA

^b Department of Radiology, Logan College of Chiropractic/University Programs, Chesterfield, MO 63017, USA

^c Department of Gastroenterology, Massachusetts General Hospital, Charlestown, MA 02129 USA

^d Department of Physical Medicine and Rehabilitation, Spaulding Rehabilitation Hospital, Medford, MA 02155, USA

^e Department of Physical Medicine and Rehabilitation, Harvard Medical School, Spaulding Rehabilitation Hospital, Boston, MA 02114, USA

^f Department of Pain Medicine, Harvard Vanguard Medical Associates, Atrius Health, Boston, MA 02215, USA

ARTICLE INFO

Article history:

Received 15 November 2012

Received in revised form 15 January 2013

Accepted 7 February 2013

Available online 15 February 2013

Keywords:

Nerve conduction velocity (NCV)

Diffusion tensor imaging (DTI)

Voxel-based morphometry (VBM)

Fractional anisotropy (FA)

Axial diffusivity (AD)

Radial diffusivity (RD)

ABSTRACT

Objective: Carpal tunnel syndrome (CTS) is a common median nerve entrapment neuropathy characterized by pain, paresthesias, diminished peripheral nerve conduction velocity (NCV) and maladaptive functional brain neuroplasticity. We evaluated structural reorganization in brain gray matter (GM) and white matter (WM) and whether such plasticity is linked to altered median nerve function in CTS.

Methods: We performed NCV testing, T1-weighted structural MRI, and diffusion tensor imaging (DTI) in 28 CTS and 28 age-matched healthy controls (HC). Voxel-based morphometry (VBM) contrasted regional GM volume for CTS versus HC. Significant clusters were correlated with clinical metrics and served as seeds to define associated WM tracts using DTI data and probabilistic tractography. Within these WM tracts, fractional anisotropy (FA), axial (AD) and radial (RD) diffusivity were evaluated for group differences and correlations with clinical metrics. **Results:** For CTS subjects, GM volume was significantly reduced in contralesional S1 (hand-area), pulvinar and frontal pole. GM volume in contralesional S1 correlated with median NCV. NCV was also correlated with RD and was negatively correlated with FA within U-fiber cortico-cortical association tracts identified from the contralesional S1 VBM seed.

Conclusions: Our study identified clear morphometric changes in the CTS brain. This central morphometric change is likely secondary to peripheral nerve pathology and altered somatosensory afference. Enhanced axonal coherence and myelination within cortico-cortical tracts connecting primary somatosensory and motor areas may accompany peripheral nerve deafferentation. As structural plasticity was correlated with NCV and not symptomatology, the former may be a better determinant of appropriate clinical intervention for CTS, including surgery.

© 2013 The Authors. Published by Elsevier Inc. Open access under [CC BY license](http://creativecommons.org/licenses/by/3.0/).

Abbreviations: CTS, carpal tunnel syndrome; NCV, nerve conduction velocity; GM, gray matter; WM, white matter; DTI, diffusion tensor imaging; VBM, voxel-based morphometry; FA, fractional anisotropy; AD, axial diffusivity; RD, radial diffusivity; S1, primary somatosensory cortex; M1, primary motor cortex.

☆☆ Study funding: NCCAM, NIH [R01-AT004714, R01-AT004714-02S1, P01-AT002048], NCRP [P41RR14075, S10RR021110].

* Corresponding author at: #2301 149 Thirteenth St., Charlestown, MA 02129, USA. Tel.: +1 617 435 8151; fax: +1 617 726 7422.

E-mail addresses: ymaeda@nmr.mgh.harvard.edu (Y. Maeda), Norman.Kettner@logan.edu (N. Kettner), jds69@nmr.mgh.harvard.edu (J. Sheehan), seesaw@nmr.mgh.harvard.edu (J. Kim), stephencina@hotmail.com (S. Cina), cmalatesta@partners.org (C. Malatesta), jgerber@nmr.mgh.harvard.edu (J. Gerber), mcmansuacupuncture@me.com (C. McManus), pia.hugus@gmail.com (P. Mezzacappa), LMorse4@PARTNERS.ORG (L.R. Morse), Joseph_Audette@vmed.org (J. Audette), vitaly@nmr.mgh.harvard.edu (V. Napadow).

1. Introduction

Carpal tunnel syndrome (CTS) is a common neuropathy associated with median nerve conduction block, as well as pain, numbness and paresthesia in the median nerve innervated territory of the affected hand. CTS is mainly driven by partial deafferentation secondary to the compression of the median nerve within the carpal tunnel (Kiernan et al., 1999). In addition to the peripheral sensorimotor manifestations of CTS, cortical digit representations in the brain display expansion, amplification, and/or shifted locus in the primary somatosensory cortex (S1), as evaluated by both fMRI (Napadow et al., 2006, 2007; Zanette et al., 2006) and MEG (Dhond et al., 2012; Tecchio et al., 2002). These studies suggest that the function of the entire hierarchy of the somatosensory system from the peripheral to the central sites may be altered in CTS. However, it is unclear whether this neuroplastic change extends to morphological reorganization in

brain gray matter (GM) and white matter (WM) and, if so, how it is associated with altered peripheral nerve function and symptomatology.

The last ten years have seen the emergence of models using fMRI to display the functional dynamics of neuronal plasticity related to chronic pain (Apkarian et al., 2011; Lotze et al., 2001). More recently, whole brain and cortical structural MRI methods such as voxel based morphometry (VBM) and cortical thickness have suggested reduced GM volume in chronic pain (Apkarian et al., 2004, 2011; As-Sanie et al., 2012), and cortical thinning in the cases of more severe peripheral deafferentation, such as peripheral nerve transection (Taylor et al., 2009). Additionally, diffusion tensor imaging (DTI) is an MRI modality that has been used to evaluate WM microstructure by assessing molecular diffusion along (axial diffusivity) and perpendicular (radial diffusivity) to specific fiber tracts (Mori and Zhang, 2006). DTI measures have been related to reduced GM morphometry in chronic pain disorders including fibromyalgia (Lutz et al., 2008) and complex regional pain syndrome (CRPS) (Geha et al., 2008). CTS is characterized by a focal primary neuropathic lesion, which allows for the direct investigation of the association between brain neuroplasticity and objective metrics of peripheral pathophysiology.

In this cross-sectional study, we evaluated CTS-associated GM and WM reorganization and determined whether such plasticity was associated with altered peripheral nerve function. We hypothesized that CTS would show GM volume decrease in contralesional S1 and primary motor cortex (M1), as these areas have been previously shown to demonstrate functional neuroplastic change (Napadow et al., 2006). Furthermore, we hypothesized that the magnitude of median nerve conduction block, which is the hallmark of CTS (Kiernan et al., 1999), would correlate with neuroplastic change in (1) GM somatosensory regions and (2) WM tracts connecting to these somatosensory regions.

2. Methods

2.1. Subjects

We evaluated 56 subjects including 28 CTS subjects (48.1 ± 9.6 , mean \pm S.D., 20F) and 28 age-matched healthy controls (HC; 47.3 ± 9.9 , 17F). CTS subjects were enrolled with inclusion criteria: 1) history of pain and/or paresthesia in median nerve innervated areas for duration greater than 3 months and 2) delayed median sensory nerve conduction latency greater than 3.7 ms and/or greater than 0.5 ms compared to ulnar sensory nerve conduction. Exclusion criteria were 1) contraindications to MRI, 2) history of diabetes mellitus or major cardiovascular, respiratory, neurological illnesses, rheumatoid arthritis, 3) wrist fracture with direct trauma to median nerve, 4) current usage of opioid medication, 5) ulnar neuropathy or nerve entrapment other than median nerve, 6) cervical radiculopathy or myelopathy, 7) generalized peripheral neuropathy, or 8.) severe thenar atrophy. All subjects were examined by a physiatrist at Spaulding Rehabilitation Hospital for eligibility, which included the testing of median and ulnar sensory nerve conduction velocities (Cadwell Sierra EMG/NCS Device, Kennewick, WA). Symptomatology was assessed with the Boston Carpal Tunnel Questionnaire (BCTSQ) (Levine et al., 1993).

HC were also enrolled and evaluated with the same procedures as CTS subjects in order to exclude CTS.

All study protocols were approved by the Massachusetts General Hospital (MGH) and Partners Human Research Committee and informed consent was obtained from all subjects.

2.2. Data acquisition

Structural MRI was obtained on a 3.0 T Siemens Trio (Siemens Medical, Erlangen, Germany) equipped with 32-channel head coil at the MGH Athinoula A. Martinos Center for Biomedical Imaging (Charlestown).

A multi-echo MPRAGE T1-weighted pulse sequence was used (TR = 2530 ms, TE1/TE2 = 1.64/30.0 ms, TI = 1200 ms, flip angle = 7°, FOV = 256x256, slices = 176, sagittal acquisition, spatial resolution = $1 \times 1 \times 1$ mm³). Diffusion-weighted MRI was also obtained (b-value = 700 s/mm², directions = 60, 32-channel coil, FOV = 256 mm, slice thickness = 2 mm, 64slices, voxel size = $2 \times 2 \times 2$ mm, TR/TE = 8040/84 ms).

2.3. Voxel based morphometry (VBM) analysis

VBM was accomplished by first preprocessing the structural T1-weighted MRI data using SPM software (SPM8, Institute of Neurology, London, UK) running under Matlab (version 7.7, Mathworks). All individual images were processed in a generative model, which included tissue classification, image registration and bias correction. Nonlinear deformations for warping GM and WM images were determined by DARTEL (Diffeomorphic Anatomical Registration using Exponentiated Lie algebra: DARTEL toolbox8 (Ashburner, 2007)). The warped GM and WM images were smoothed with a Gaussian kernel (FWHM = 10 mm), modulated, and registered to MNI space (i.e. the final DARTEL template brain).

Voxel-wise general linear model (GLM) analysis was performed contrasting GM volumes from CTS versus HC. Significant differences between CTS and HC were determined with age and gender as regressors of no interest. Statistical maps were corrected for multiple comparisons by false discovery rate (FDR, $p < 0.05$) on the voxel level. We then accepted only clusters greater than 100 voxels in size in order to limit the potential for small cluster false positives. In order to avoid possible edge effects at the GM/WM border, we excluded all voxels with GM value lower than 0.2. In order to better understand the association between GM volume and CTS-related pathology, we correlated GM volumes from all subjects with a) NCV and b) symptom severity. For the latter, pain symptoms were summarized as the average of questions 1–5, while paresthesia symptoms (numbness/tingling) were summarized as the average of questions 6–10 from the BCTSQ.

In order to account for variability in the laterality of the more affected hand, the imaging data were also analyzed by mirroring data across the mid-sagittal plane in CTS subjects whose more affected hand was the left hand. This analysis was important for brain regions known to be lateralized relative to peripheral lesions in the somatosensory system such as S1, M1, and ventro-posterolateral nucleus of the thalamus. This mirrored analysis was used to interpret only these regions, while the conventional, non-mirrored analysis was used for all other brain areas.

2.4. Diffusion tensor imaging (DTI) analysis

DTI data processing was performed using the FMRIB Software Library (FDT v2.0, FSL v4.1.9). Prior to fitting the diffusion tensor model, all datasets were skull stripped (Brain Extraction Tool) and eddy current corrected (eddycorrect). The DTI tensor model was then fit using voxel-wise linear least squares (dtifit). Probabilistic tractography was performed in subject-space using Bayesian Estimation of Diffusion Parameters Obtained using Sampling Techniques (BedpostX). In order to perform tracking, seeds were created using the results from VBM analyses contrasting CTS and HC (see above). These MNI-registered regions of interest (ROIs) were transformed to subject space using FMRIB Non-linear Image Registration Tool (FNIRT), which calculated an alignment warp between the subject-space FA maps and the MNI-space FMRIB58 FA map. The VBM-derived ROIs in subject space were then radially dilated by 1 voxel to assure intersection with WM and a WM mask was used to exclude GM voxels. Probabilistic tractography (FA threshold = 0.2, max steps 2000, step length = 0.5 mm, 5000 iterations per voxel) was then performed on each subject for each of the seed ROIs. Tracts were normalized across all subjects by dividing each voxel in the tract by the

total number of waypoints counted in the entire tract (waytotal) (Johansen-Berg and Behrens, 2009). These subject space tracts were then warped to MNI space to create a group averaged map, restricted to a 5% threshold of the normalized waytotal, a previously validated methodology (Johansen-Berg and Behrens, 2009).

The tracts determined from all 3 ROIs were used to investigate seed-specific WM connections, and as masks to evaluate any significant group differences (CTS-HC) in DTI metrics including FA, AD (λ_1), and RD (average of λ_2 and λ_3). In WM, AD reflects diffusion parallel to axon bundles and is a marker of axonal integrity (Budde et al., 2009; Song et al., 2003). RD is the magnitude of diffusion orthogonal to the axonal axis and is modulated by axonal membrane properties and myelination along fiber tracts (Song et al., 2002, 2003). FA provides a summary measure of relative difference in AD and RD (degree of anisotropy) and is scaled from 0 (isotropic) to 1 (anisotropic). In order to evaluate if WM microstructure within tracts of interest was associated with CTS-related pathology, we correlated CTS subjects' FA, AD and RD with median NCV, pain, and paresthesia, as defined above.

The existence of crossing fibers is an important potential confound to DTI estimation. To evaluate the probability of crossing fibers, we calculated the mode of the diffusion tensor, which refers to tensor shape and is scaled from -1 (planar; $AD \approx RD$, high probability of crossing fibers) to 1 (linear; $AD > RD$, low probability) (Ennis and Kindlmann, 2006).

3. Results

3.1. Demographic and clinical features

The more affected (NCV slowing) hand was the right hand in 19 (67.9%) CTS subjects. Median NCV was significantly slower in CTS compared to HC (CTS: 36.8 ± 7.1 m/s, HC: 53.1 ± 5.1 , mean \pm S.D., $p < 10^{-12}$). There were no differences in ulnar NCV between CTS and HC (CTS: 55.6 ± 6.9 m/s, HC: 55.0 ± 5.6 , $p = 0.70$). All CTS subjects reported both pain (2.5 ± 0.8 , mean \pm SD, on a scale from 1 to 5), and paresthesia/numbness (2.7 ± 0.9 , mean \pm SD, on a scale from 1 to 5). Self-reported CTS symptom duration was 8.5 ± 9.1 (mean \pm SD) years. We found a significant inter-subject correlation between pain and paresthesia severity ($r = 0.50$, $p < 0.01$) and a weak (trending) negative correlation between paresthesia and symptom duration ($r = -0.30$, $p = 0.1$), while pain ($r = -0.11$, $p > 0.5$) was not correlated with symptom duration.

3.2. VBM analyses

VBM analysis revealed that GM volume was reduced in left S1 (Table 1, Fig. 1). This result was more prominent when VBM data were mirrored across the mid-sagittal plane for left hand affected CTS (i.e. reduced GM was in the contralesional S1 hand area). GM volume was also reduced in the right posterior thalamus (consistent with the pulvinar) and right frontal pole (Table 1, Fig. 1). A linear regression analysis in our study sample revealed that NCV was

positively correlated to GM volume in contralesional S1 ($r = 0.45$, $p < 0.01$, Fig. 2). We found a weak (trending) correlation within the CTS group ($r = 0.24$, $p = 0.1$), while in the HC group, the correlation was not significant ($r = 0.18$, $p = 0.2$). Neither CTS symptomatology nor symptom duration had significant correlation with GM volume decrease in these ROIs.

3.3. Diffusion tensor imaging (DTI) analyses

DTI-based tractography identified a U-fiber cortico-cortical association tract connecting S1 (seed cluster defined from the result above) with pre-central gyrus (putative M1, Fig. 3). WM tracts connecting to this S1 seed also included superior longitudinal fasciculus (SLF), consistent with SLF II (Makris et al., 2005). The right posterior thalamus seed generated tracts consistent with the fornix, stria-terminalis, and inferior fronto-occipital fasciculus. The right frontal pole seed generated a tract consistent with the uncinate fasciculus. There was also slightly sub-threshold evidence for connecting fibers of the inferior fronto-occipital fasciculus and frontal aspects of the corpus callosum.

Within the S1-associated WM tract space, DTI metrics (FA, AD, RD, and mode) did not differ between CTS and HC. However, in the saddle region of the U-fiber cortico-cortical tract connecting contralesional S1 with M1, we found that FA was negatively correlated ($r = -0.65$), while RD was positively correlated ($r = 0.72$) with NCV (Fig. 4). Within both of these FA and RD clusters, the DTI mode was positive for CTS subjects (FA cluster: 0.23 ± 0.20 ; RD cluster: 0.02 ± 0.14) and was not correlated to NCV (FA cluster: $r = -0.06$; RD cluster: $r = 0.14$), suggesting that crossing fibers did not influence these results. No correlations to NCV were noted for any other DTI metrics. We also did not find any group differences nor correlations in any other tract space (thalamus and frontal pole seed spaces), nor significant correlation between CTS symptomatology and DTI metrics in any of the tracts noted above.

4. Discussion

This multimodal study investigated CTS-associated morphological reorganization in the brain's GM and WM, and determined its association with altered peripheral nerve function. Our main finding was that CTS subjects demonstrated reduced GM volume in somatosensory (S1), visuomotor (thalamic pulvinar), and multisensory integration/cognitive (frontal pole) processing regions. GM reduction in S1 was specific to the contralesional cortical representation of the hand region. Moreover, GM volume in S1 was significantly correlated with NCV. Thus, the slower the median NCV across the wrist, the more pronounced the S1 GM volume reduction. We then used DTI to evaluate WM microstructure in the specific WM tracts connected to this S1 region. Interestingly, we found that NCV was negatively correlated with FA, and positively correlated with RD, within the U-fiber cortico-cortical tract connecting contralesional S1 with M1. Our results suggest that CTS, a chronic peripheral neuropathy, also results in structural remodeling and neuroplasticity in the brain, which is closely linked to reduced peripheral nerve conduction.

4.1. Reduced GM volume in CTS

While ambiguity exists as to whether GM reductions represent degenerative atrophy or neuroplastic reorganization (maladaptive or compensatory), reduced GM volume in CTS subjects is consistent with findings observed in other chronic pain conditions in humans (Apkarian et al., 2004, 2011; As-Sanie et al., 2012) and animal models (Seminowicz et al., 2009), and may also relate to previous VBM findings of use-dependent plasticity (Draganski et al., 2006). In fact, S1 functional plasticity has been correlated with both diminished GM volume and changes in the diffusion tensor that suggest the growth

Table 1

Regional GM volume differences: CTS-HC. MNI coordinates and t-values are listed for the peak voxel in the cluster.

Region	Side	MNI coordinates x, y, z (mm)	T-value/p-value	Cluster volume (mm ³)
Non-flipped analysis				
Thalamus	Right	10, -28, 12	-3.74/<0.0001	375
Frontal pole	Right	16, 64, -12	-3.68/<0.0001	633
S1	Left	-36, -36, 56	-3.58/<0.0001	338
Flipped analysis				
S1	Contra	-44, -32, 56	-3.65/<0.0001	390

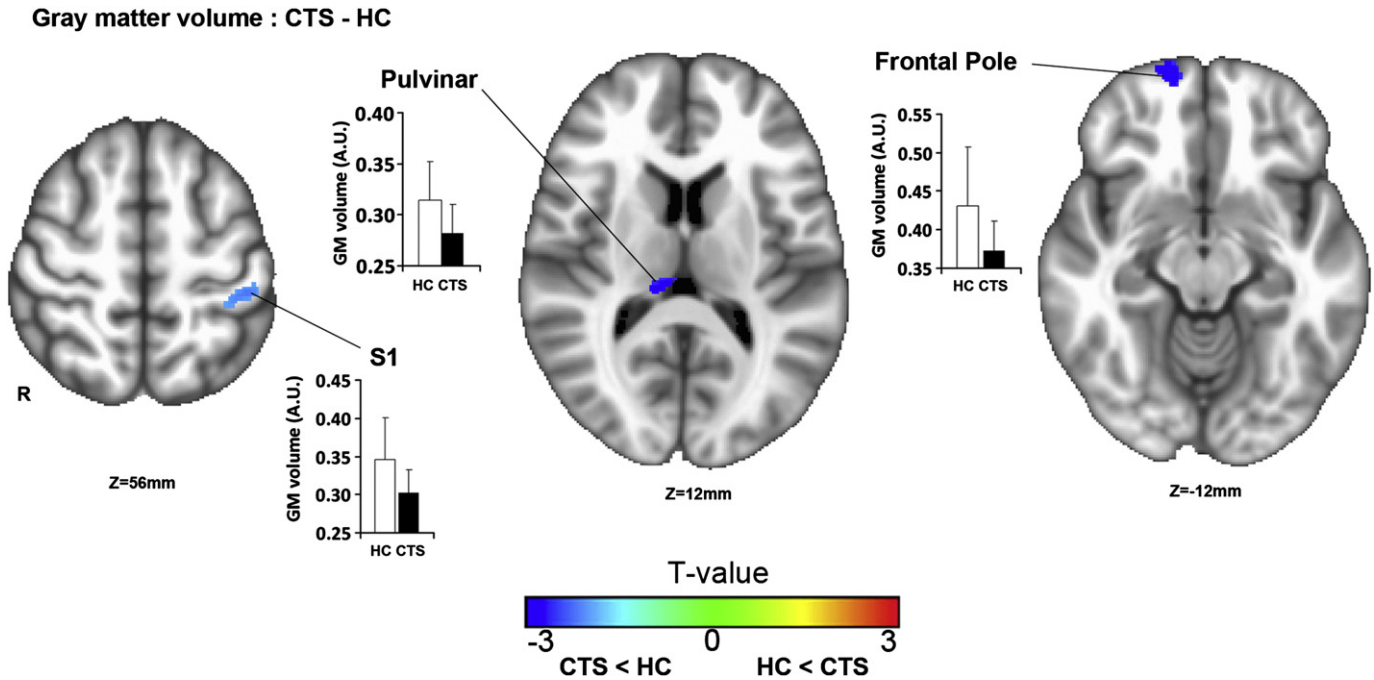


Fig. 1. GM volume in CTS was reduced compared to HC. Voxel based morphometry (VBM) demonstrated reduced GM volume in CTS within the contralesional S1 hand cortical representation. Reduced GM was also noted in right pulvinar and frontal pole. The bar graphs relate mean GM volume from the peak voxel of significant clusters. Error bars denote standard deviation.

of new lateral connections in spinal cord injury patients (Henderson et al., 2011). These findings are interesting as we have previously shown that CTS patients also demonstrate functional neuroplasticity within S1 representations of median nerve innervated territories (Napadow et al., 2006). However, it should also be noted that not all GM morphometry studies demonstrate GM volume decrease in chronic pain patients. For instance, a recent study noted that patients suffering from temporomandibular disorder (a non-neuropathic pain syndrome) did not show any GM decrease, while trigeminal neuropathic pain patients did demonstrate GM decrease in the thalamus and other brain regions

(Gustin et al., 2011). These results are consistent with our demonstration of GM volume decrease in CTS patients, as CTS can also be characterized as a neuropathic pain disorder.

4.2. Reduced GM volume in S1

In CTS, the median nerve is compressed at the carpal tunnel, resulting in ischemia (Seiler et al., 1989), inflammation, and elevated tunnel pressure. This pathophysiological sequence of events triggers altered afferent input from affected digits, and decreased nerve conduction along median nerve sensory fibers (Kiernan et al., 1999). Thus, S1 GM decreases in CTS may be the consequence of partial deafferentation or desynchronization in S1 inputs, and Taylor et al. recently found that peripheral nerve transection (a more severe form of deafferentation) was also associated with reduced GM in contralesional S1 (Taylor et al., 2009). However, this previous study did not associate contralesional S1 GM reductions with slowing of peripheral conduction velocities, an important finding in our study that strongly links peripheral pathophysiology with altered brain morphology. While histological changes supporting this structural plasticity are unknown, a number of animal studies have demonstrated that use-dependent structural plasticity is associated with GM increase mediated by neuronal (Lerch et al., 2011), and dendritic spine remodeling (Thomas and Baker, 2012; Xu et al., 2009). In turn, GM reduction has been hypothesized to be mediated by events ranging from neuronal or glial death (May, 2008) to loss of dendritic spine density (Metz et al., 2009).

As GM reduction in S1 was specifically associated with decreased impulse conduction along the median nerve, similar to what we found for functional brain reorganization in CTS (Napadow et al., 2006, 2007), we propose that cortical reorganization in CTS extends to structural change, triggered by chronically altered peripheral afference. Interestingly, GM decreases in contralesional S1 correlated with reduced median NCV and not symptomatology. Multiple CTS studies have found that median nerve conduction does not correlate well with symptomatology (Green et al., 2012; Mondelli et al., 2000). Symptoms such

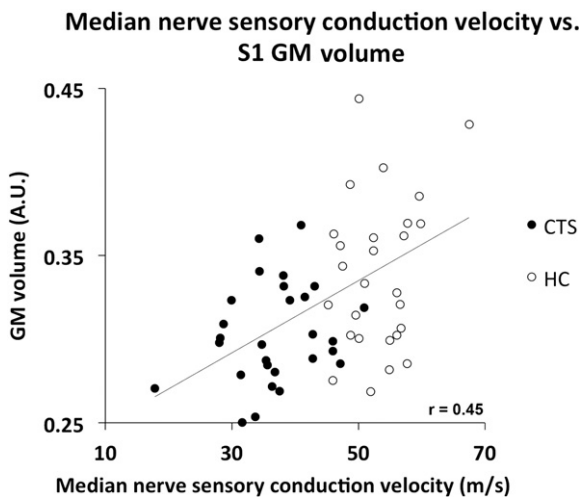


Fig. 2. Reduced GM volume was correlated with median nerve conduction velocity. Regression analysis found that median NCV correlated with reduced GM volume in S1. Thus, the slower the velocity and the more disrupted the peripheral nerve function, the more pronounced was the S1 GM volume reduction. N.B. GM volume was extracted from each subject from the significant group level S1 cluster.

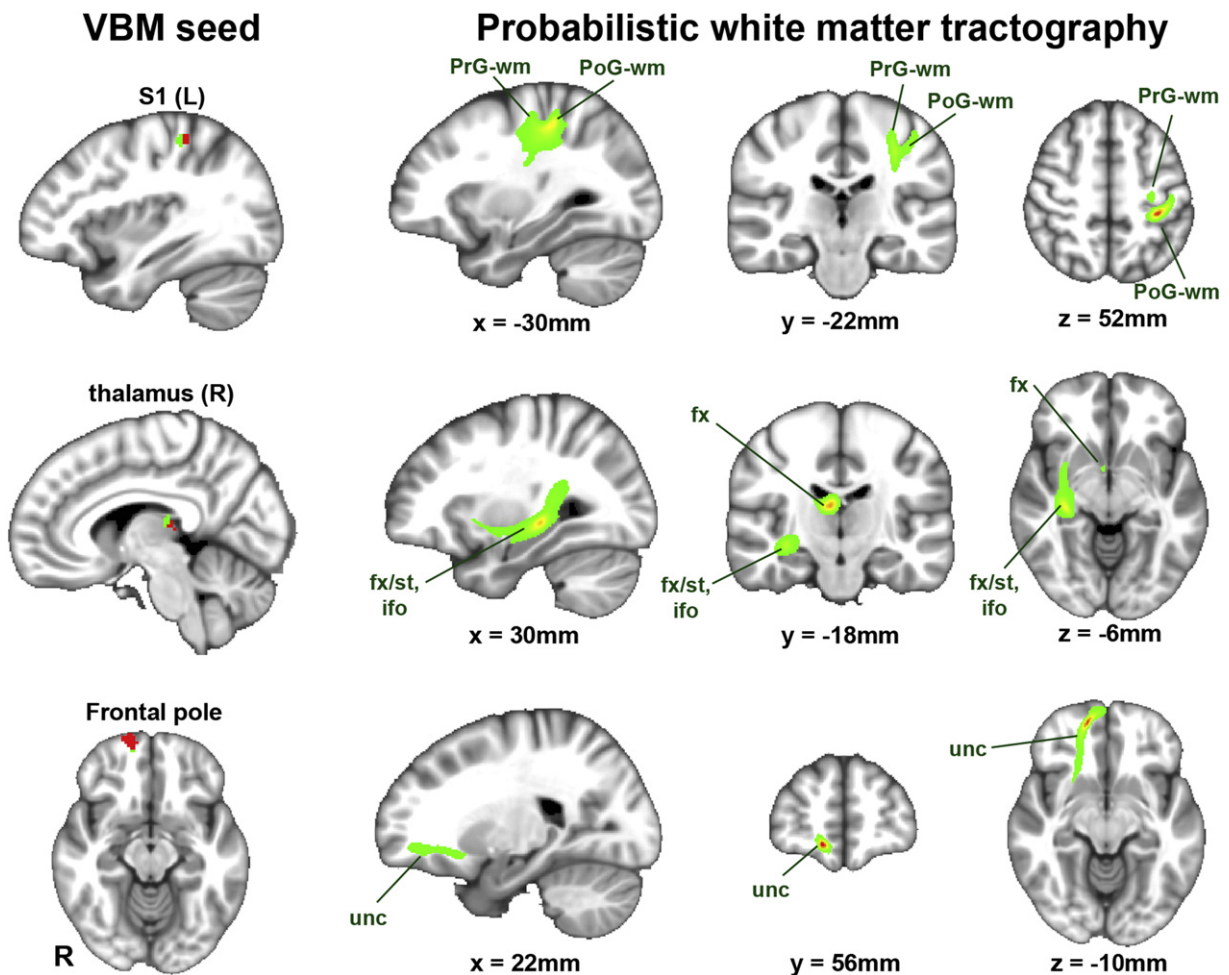


Fig. 3. Significant clusters from the VBM analysis served as seeds to evaluate the WM tracts connected to regions showing reduced GM. [Left column] To create the seeds, significant VBM clusters (red) were dilated and masked by their WM intersection (green). [Right columns] Probabilistic WM tractography identified that the contralesional S1 VBM cluster was mainly connected to contralesional M1 via a U-fiber cortico-cortical association tract. The right posterior thalamus (pulvinar) seed generated tracts consistent with the fornix, stria-terminalis, and inferior fronto-occipital fasciculus. The right frontal pole seed generated a tract consistent mainly with the uncinate fasciculus.

as pain and paresthesias can fluctuate and are self reported. On the other hand, NCV is an objective electrophysiological marker evaluating the severity of an impaired median nerve, and was directly correlated with reduced GM in contralesional S1.

4.3. WM microstructure in S1/M1 cortico-cortical tract associated with NCV

We further found that greater FA and lower RD in a saddle region of the cortico-cortical U-fiber WM tract connecting S1 to M1 was correlated with NCV. This result suggests that enhanced axonal coherence and myelination which can produce lower RD (Song et al., 2003, 2002) within the WM connecting the pre- and post-central gyri, is also specifically associated with reduced peripheral nerve function. Myelination in the CNS can be induced or inhibited by increased or decreased neuronal activity, respectively (Demerens et al., 1996). Thus, WM microstructure in association with NCV may represent compensatory mechanisms for facilitating communication between S1 and M1. S1/M1 communication, as well as S1 communication with premotor and other prefrontal sensorimotor integration centers via the SLF (which was also found to be connected to our specific S1 seed), is critical for fine motor control (Shinoura et al., 2005), a functional deficiency in CTS (Radwin et al., 2004). Additionally, previous studies have suggested that GM volume reduction occurs secondary to functional brain plasticity (Seminowicz et al., 2011). Our previous studies have noted significant functional

plasticity for somatosensory afference reaching S1 (Napadow et al., 2006, 2007). While confirmatory evidence awaits longitudinal studies, we suggest that the GM and WM changes are downstream from the previously noted functional neuroplasticity.

4.4. Reduced GM volume in thalamus

Reduced GM was also found in the right thalamus, consistent with the pulvinar nucleus. The pulvinar is a higher order relay important for cortico-cortical communication in the visual system (Sherman, 2007) and may also contribute in visuomotor integration (Grieve et al., 2000). Deprivation of afferent input leads to GM reduction in the posterolateral thalamus (Draganski et al., 2006), and other thalamic nuclei, such as the pulvinar, may also be affected due to thalamo-thalamic interactions (Elias et al., 2012). Reduced pulvinar GM may relate to disrupted visuomotor integration underlying the deficient psychomotor performance noted in CTS (Radwin et al., 2004). DTI analysis found that WM tracts leading to/away from this pulvinar region were consistent with the fornix, stria-terminalis, and inferior fronto-occipital fasciculus, tracts likely to relay visuospatial information to prefrontal cortical regions supporting executive control over fine motor commands (Grieve et al., 2000). Interestingly, pulvinar involvement in pain was also recently highlighted by Sprenger et al., who found that lesions in the ventral posterior/pulvinar border

DTI metrics vs. median n. conduction velocity

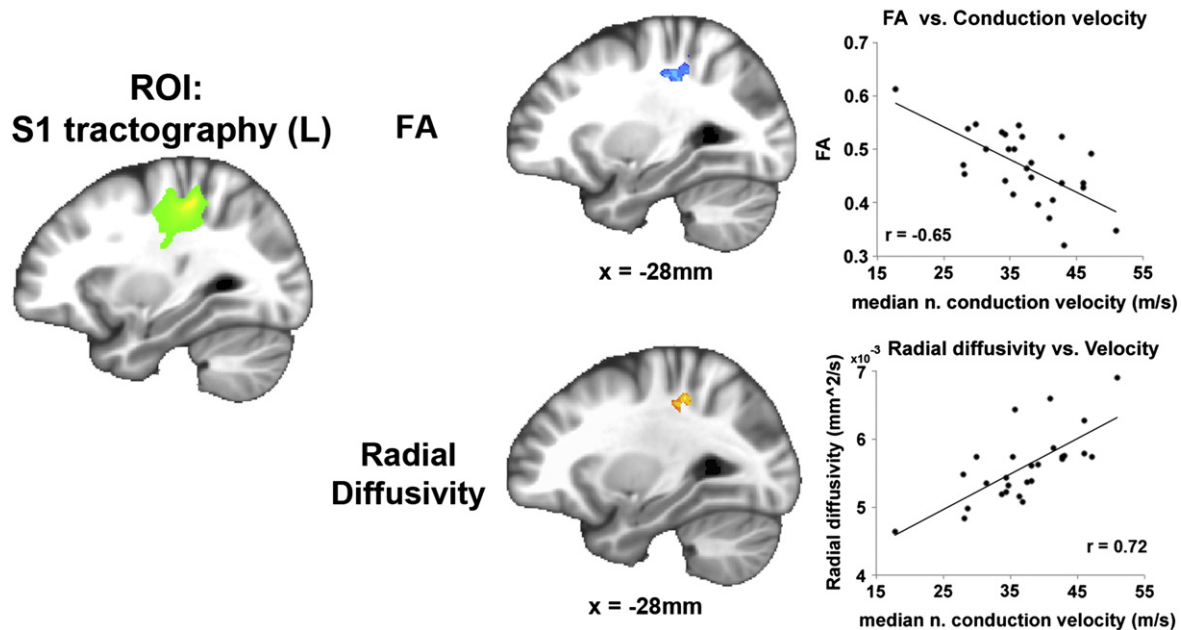


Fig. 4. DTI metrics were correlated with median nerve function. A linear regression constrained by the tract identified using the S1 VBM seed found that fractional anisotropy (FA) and radial diffusivity (RD) correlated with CTS subjects' median nerve conduction velocity (NCV). For FA, a cluster in the saddle region of the U-fiber bundle connecting the post-central and pre-central gyri demonstrated a negative correlation with median NCV. For RD, a near identical cluster in the saddle region demonstrated positive correlation with median NCV. Lower velocity (i.e. greater peripheral pathology) was associated with higher FA and lower RD in this region.

zone most readily predicted whether or not post-thalamic stroke patients developed pain (Sprenger et al., 2012).

4.5. Reduced GM volume in frontal pole

Reduced GM was also found in the frontal pole, which appears to be important for monitoring cognitive and motor outcomes as well as multi-sensory integration and executive motor control (Tsujimoto et al., 2010). Decreased GM in the frontal pole may contribute to impaired executive control of motor responses demonstrated in psychomotor testing (Radwin et al., 2004). However, our DTI analysis found that WM tracts leading to/away from this frontopolar region were consistent with the uncinate fasciculus, a limbic tract that has been associated with affective and cognitive dysfunction (Tartaglia et al., 2012), and which connects the frontal pole with the medial temporal lobe. Thus, future studies should further explore how affective dimensions of CTS symptomatology and psychomotor disruption relate to reduced GM in the pulvinar and frontal pole, as well as plasticity in WM tracts connected to these regions.

4.6. Limitations

A limitation of our study was that we did not include severe CTS subjects, and future research will need to clarify if severe CTS with motor dysfunction and atrophy will also demonstrate GM decrease in motor processing regions. Additionally, as structural plasticity following chronic pain may be reversible (Seminowicz et al., 2011), future longitudinal studies should evaluate if effective treatment that ameliorates symptomatology and improves median NCV can also normalize GM volume. Finally, a significant correlation between GM volume and median NCV was only found in the combined CTS and HC group, and may have been partially due to the significant group differences noted between these groups. However, a trending correlation was also noted within the CTS group, suggesting that this relationship was not solely due to the group difference. Ultimately,

greater power may be needed for this relationship to reach significance in CTS subjects, who presented with a reduced dynamic range compared to the combined CTS and HC groups.

5. Conclusions

CTS demonstrated significant GM reductions in the contralesional hand area of S1, as well as right frontal pole and pulvinar. S1 GM reduction was correlated with NCV. In addition, WM microstructure within cortico-cortical U-fiber tracts connecting contralesional S1 with M1 was also correlated with NCV. Thus, structural plasticity in cortical GM and WM occurred as a consequence of peripheral neuropathy in CTS, which supports the view that CTS is not just a peripheral disorder but is accompanied by CNS remodeling. Finally, these results underscore the importance of nerve conduction studies in determining appropriate clinical interventions, including surgery.

Acknowledgments

This work was supported by the NCCAM, National Institutes of Health [R01-AT004714, R01-AT004714-02S1, P01-AT002048], as well as by the National Center for Research Resources (NCRR) [P41RR14075, S10RR021110].

References

- Apkarian, A.V., Sosa, Y., Sonty, S., Levy, R.M., Harden, R.N., Parrish, T.B., Gitelman, D.R., 2004. Chronic back pain is associated with decreased prefrontal and thalamic gray matter density. *Journal of Neuroscience* 24, 10410–10415.
- Apkarian, A.V., Hashmi, J.A., Baliki, M.N., 2011. Pain and the brain: specificity and plasticity of the brain in clinical chronic pain. *Pain* 152, S49–S64.
- Ashburner, J., 2007. A fast diffeomorphic image registration algorithm. *NeuroImage* 38, 95–113.
- As-Sanie, S., Harris, R.E., Napadow, V., Kim, J., Neshewat, G., Kairys, A., Williams, D., Clauw, D.J., Schmidt-Wilcke, T., 2012. Changes in regional gray matter volume in women with chronic pelvic pain: a voxel-based morphometry study. *Pain* 153, 1006–1014.

- Budde, M.D., Xie, M., Cross, A.H., Song, S.K., 2009. Axial diffusivity is the primary correlate of axonal injury in the experimental autoimmune encephalomyelitis spinal cord: a quantitative pixelwise analysis. *Journal of Neuroscience* 29, 2805–2813.
- Demerens, C., Stankoff, B., Logak, M., Anglade, P., Allinquant, B., Couraud, F., Zalc, B., Lubetzki, C., 1996. Induction of myelination in the central nervous system by electrical activity. *Proceedings of the National Academy of Sciences of the United States of America* 93, 9887–9892.
- Dhond, R., Ruzich, E., Witzel, T., Maeda, Y., Malatesta, C., Morse, L., Audette, J., Hamalainen, M., Kettner, N., Napadow, V., 2012. Spatiotemporal mapping cortical neuroplasticity in carpal tunnel syndrome. *Brain* 135, 3062–3073.
- Draganski, B., Moser, T., Lummel, N., Ganssbauer, S., Bogdahn, U., Haas, F., May, A., 2006. Decrease of thalamic gray matter following limb amputation. *NeuroImage* 31, 951–957.
- Elias, W.J., Zheng, Z.A., Domer, P., Quigg, M., Pouratian, N., 2012. Validation of connectivity-based thalamic segmentation with direct electrophysiologic recordings from human sensory thalamus. *NeuroImage* 59, 2025–2034.
- Ennis, D.B., Kindlmann, G., 2006. Orthogonal tensor invariants and the analysis of diffusion tensor magnetic resonance images. *Magnetic Resonance in Medicine* 55, 136–146.
- Geha, P.Y., Baliki, M.N., Harden, R.N., Bauer, W.R., Parrish, T.B., Apkarian, A.V., 2008. The brain in chronic CRPS pain: abnormal gray-white matter interactions in emotional and autonomic regions. *Neuron* 60, 570–581.
- Green, T.P., Tolonen, E.U., Clarke, M.R., Pathak, P., Newey, M.L., Kershaw, C.J., Kallio, M.A., 2012. The relationship of pre- and postoperative median and ulnar nerve conduction measures to a self-administered questionnaire in carpal tunnel syndrome. *Neurophysiologie Clinique* 42, 231–239.
- Grieve, K.L., Acuna, C., Cudeiro, J., 2000. The primate pulvinar nuclei: vision and action. *Trends in Neurosciences* 23, 35–39.
- Gustin, S.M., Peck, C.C., Wilcox, S.L., Nash, P.G., Murray, G.M., Henderson, L.A., 2011. Different pain, different brain: thalamic anatomy in neuropathic and non-neuropathic chronic pain syndromes. *Journal of Neuroscience* 31, 5956–5964.
- Henderson, L.A., Gustin, S.M., Macey, P.M., Wrigley, P.J., Siddall, P.J., 2011. Functional reorganization of the brain in humans following spinal cord injury: evidence for underlying changes in cortical anatomy. *Journal of Neuroscience* 31, 2630–2637.
- Johansen-Berg, H., Behrens, T., 2009. Diffusion MRI: From Quantitative Measurement to In-vivo Neuroanatomy. Academic Press.
- Kiernan, M.C., Mogyoros, I., Burke, D., 1999. Conduction block in carpal tunnel syndrome. *Brain* 122 (Pt 5), 933–941.
- Lerch, J.P., Yiu, A.P., Martinez-Canabal, A., Pekar, T., Bohbot, V.D., Frankland, P.W., Henkelman, R.M., Josselyn, S.A., Sled, J.G., 2011. Maze training in mice induces MRI-detectable brain shape changes specific to the type of learning. *NeuroImage* 54, 2086–2095.
- Levine, D.W., Simmons, B.P., Koris, M.J., Daltroy, L.H., Hohl, G.G., Fossel, A.H., Katz, J.N., 1993. A self-administered questionnaire for the assessment of severity of symptoms and functional status in carpal tunnel syndrome. *The Journal of Bone and Joint Surgery. American Volume* 75, 1585–1592.
- Lotze, M., Flor, H., Grodd, W., Larbig, W., Birbaumer, N., 2001. Phantom movements and pain. An fMRI study in upper limb amputees. *Brain* 124, 2268–2277.
- Lutz, J., Jager, L., de Quervain, D., Krauseneck, T., Padberg, F., Wichnialek, M., Beyer, A., Stahl, R., Zirngibl, B., Morhard, D., Reiser, M., Schelling, G., 2008. White and gray matter abnormalities in the brain of patients with fibromyalgia: a diffusion-tensor and volumetric imaging study. *Arthritis and Rheumatism* 58, 3960–3969.
- Makris, N., Kennedy, D.N., McInerney, S., Sorensen, A.G., Wang, R., Caviness Jr., V.S., Pandya, D.N., 2005. Segmentation of subcomponents within the superior longitudinal fascicle in humans: a quantitative, in vivo, DT-MRI study. *Cerebral Cortex* 15, 854–869.
- May, A., 2008. Chronic pain may change the structure of the brain. *Pain* 137, 7–15.
- Metz, A.E., Yau, H.J., Centeno, M.V., Apkarian, A.V., Martina, M., 2009. Morphological and functional reorganization of rat medial prefrontal cortex in neuropathic pain. *Proceedings of the National Academy of Sciences of the United States of America* 106, 2423–2428.
- Mondelli, M., Reale, F., Sicurelli, F., Padua, L., 2000. Relationship between the self-administered Boston questionnaire and electrophysiological findings in follow-up of surgically-treated carpal tunnel syndrome. *Journal of hand surgery (Edinburgh, Scotland)* 25, 128–134.
- Mori, S., Zhang, J., 2006. Principles of diffusion tensor imaging and its applications to basic neuroscience research. *Neuron* 51, 527–539.
- Napadow, V., Kettner, N., Ryan, A., Kwong, K.K., Audette, J., Hui, K.K., 2006. Somatosensory cortical plasticity in carpal tunnel syndrome — a cross-sectional fMRI evaluation. *NeuroImage* 31, 520–530.
- Napadow, V., Liu, J., Li, M., Kettner, N., Ryan, A., Kwong, K.K., Hui, K.K., Audette, J.F., 2007. Somatosensory cortical plasticity in carpal tunnel syndrome treated by acupuncture. *Human Brain Mapping* 28, 159–171.
- Radwin, R.G., Sesto, M.E., Zachary, S.V., 2004. Functional tests to quantify recovery following carpal tunnel release. *The Journal of Bone and Joint Surgery. American Volume* 86-A, 2614–2620.
- Seiler III, J.G., Milek, M.A., Carpenter, G.K., Swiontkowski, M.F., 1989. Intraoperative assessment of median nerve blood flow during carpal tunnel release with laser Doppler flowmetry. *The Journal of hand surgery* 14, 986–991.
- Seminowicz, D.A., Laferriere, A.L., Millicamps, M., Yu, J.S., Coderre, T.J., Bushnell, M.C., 2009. MRI structural brain changes associated with sensory and emotional function in a rat model of long-term neuropathic pain. *NeuroImage* 47, 1007–1014.
- Seminowicz, D.A., Wideman, T.H., Naso, L., Hatami-Khoroushahi, Z., Fallatah, S., Ware, M.A., Jarzem, P., Bushnell, M.C., Shir, Y., Ouellet, J.A., Stone, L.S., 2011. Effective treatment of chronic low back pain in humans reverses abnormal brain anatomy and function. *Journal of Neuroscience* 31, 7540–7550.
- Sherman, S.M., 2007. The thalamus is more than just a relay. *Current Opinion in Neurobiology* 17, 417–422.
- Shinoura, N., Suzuki, Y., Yamada, R., Kodama, T., Takahashi, M., Yagi, K., 2005. Fibers connecting the primary motor and sensory areas play a role in grasp stability of the hand. *NeuroImage* 25, 936–941.
- Song, S.K., Sun, S.W., Ramsbottom, M.J., Chang, C., Russell, J., Cross, A.H., 2002. Demyelination revealed through MRI as increased radial (but unchanged axial) diffusion of water. *NeuroImage* 17, 1429–1436.
- Song, S.K., Sun, S.W., Ju, W.K., Lin, S.J., Cross, A.H., Neufeld, A.H., 2003. Diffusion tensor imaging detects and differentiates axon and myelin degeneration in mouse optic nerve after retinal ischemia. *NeuroImage* 20, 1714–1722.
- Sprenger, T., Seifert, C.L., Valet, M., Andreou, A.P., Foerschler, A., Zimmer, C., Collins, D.L., Goadsby, P.J., Tolle, T.R., Chakravarty, M.M., 2012. Assessing the risk of central post-stroke pain of thalamic origin by lesion mapping. *Brain* 135, 2536–2545.
- Tartaglia, M.C., Zhang, Y., Racine, C., Laluz, V., Neuhaus, J., Chao, L., Kramer, J., Rosen, H., Miller, B., Weiner, M., 2012. Executive dysfunction in frontotemporal dementia is related to abnormalities in frontal white matter tracts. *Journal of Neurology* 259, 1071–1080.
- Taylor, K.S., Anastakis, D.J., Davis, K.D., 2009. Cutting your nerve changes your brain. *Brain* 132, 3122–3133.
- Tecchio, F., Padua, L., Aprile, I., Rossini, P.M., 2002. Carpal tunnel syndrome modifies sensory hand cortical somatotopy: a MEG study. *Human Brain Mapping* 17, 28–36.
- Thomas, C., Baker, C.I., 2012. Teaching an adult brain new tricks: a critical review of evidence for training-dependent structural plasticity in humans. *NeuroImage*. <http://dx.doi.org/10.1016/j.neuroimage.2012.03.069>.
- Tsujimoto, S., Genovesio, A., Wise, S.P., 2010. Evaluating self-generated decisions in frontal pole cortex of monkeys. *Nature Neuroscience* 13, 120–126.
- Xu, T., Yu, X., Perlik, A.J., Tobin, W.F., Zweig, J.A., Tennant, K., Jones, T., Zuo, Y., 2009. Rapid formation and selective stabilization of synapses for enduring motor memories. *Nature* 462, 915–919.
- Zanette, G., Marani, S., Tamburin, S., 2006. Extra-median spread of sensory symptoms in carpal tunnel syndrome suggests the presence of pain-related mechanisms. *Pain* 122, 264–270.