


Contents lists available at [ScienceDirect](http://ScienceDirect.com)

# Gynecologic Oncology Reports

journal homepage: [www.elsevier.com/locate/gore](http://www.elsevier.com/locate/gore)

## Pancreaticoduodenectomy in optimal primary cytoreduction of epithelial ovarian cancer: A case report and review of the literature

Joy M. Beissel<sup>a</sup>, Michael L. Kendrick<sup>b</sup>, Karl C. Podratz<sup>a</sup>, Jamie N. Bakkum-Gamez<sup>a,\*</sup><sup>a</sup> Division of Gynecologic Oncology, Mayo Clinic, Rochester, MN 55905, USA<sup>b</sup> Department of General Surgery, Mayo Clinic, Rochester, MN 55905, USA

### ARTICLE INFO

#### Article history:

Received 3 July 2014

Accepted 21 September 2014

Available online 28 September 2014

#### Keywords:

Ovarian cancer

Pancreaticoduodenectomy

Whipple procedure

Optimal cytoreduction

### Introduction

Aggressive and optimal cytoreduction in the surgical management of primary epithelial ovarian cancer (EOC) has been shown to improve survival outcomes in advanced stage disease (Chi et al., 2006; Eisenhauer et al., 2008; Eisenkop et al., 1998; Aletti et al., 2006). In the upper abdomen, liver resection, diaphragm stripping and resection, splenectomy, distal pancreatectomy, and porta hepatis lymphadenectomy have been described in EOC debulking and are now routinely utilized when indicated (Eisenhauer et al., 2006). We present a case of stage IIIC papillary serous ovarian cancer that required pancreaticoduodenectomy (Whipple procedure) to both relieve a malignant bowel obstruction and achieve optimal cytoreduction.

### Case report

A 58 year old woman with a history of stage I microinvasive infiltrating ductal right breast carcinoma managed with conservative surgery, radiation, and tamoxifen one year prior presented to her primary medical oncologist with early satiety, nausea, bilious vomiting, and abdominal distention. Computed tomography (CT) of the abdomen and pelvis revealed ascites, an omental cake, peritoneal carcinomatosis, and periumbilical lymphadenopathy. Her stomach

was markedly dilated, and malrotation of the small bowel was also identified (Fig. 1). Her CA 125 level was 1850 U/mL. A CT-guided omental fine needle aspiration was initially determined to be consistent with metastatic breast cancer. She received one dose of the first planned cycle of paclitaxel and carboplatin with alleviation of the vomiting. Shortly thereafter on further immunohistological comparison, the omental metastasis showed strong nuclear staining for Wilm's tumor 1 (WT-1) and was negative for gross cystic disease fluid protein 15 (GCDFP 15) and mammoglobin. Her initial breast cancer was negative for WT-1 and focally positive for GCDFP 15 and mammoglobin, supporting the diagnosis of a new ovarian or primary peritoneal carcinoma.

She was referred to gynecologic oncology for consideration of cytoreductive surgery. She was deemed a candidate for primary cytoreduction, underwent an exploratory laparotomy, and was found to have a 4 cm right ovarian cancer, a large omental cake attached to the transverse mesocolon, right diaphragm involvement, and diffusely scattered 1 to 2 mm nodules within the pelvis, on the appendix, and on the small bowel mesentery. Optimal cytoreduction to 1 to 2 mm of residual disease appeared feasible based on these initial findings at exploration. A thickening near the site of bowel malrotation and head of the pancreas was palpable. The etiology of the mass was unclear at the beginning of the procedure.

Surgical cytoreduction included a total abdominal hysterectomy, bilateral salpingo-oophorectomy, omentectomy, appendectomy, liver mobilization with subsequent stripping of the right hemidiaphragm, transverse colocolostomy, and bilateral pelvic and para-aortic lymphadenectomy. Frozen pathology confirmed a high-grade papillary serous carcinoma arising from the right ovary. During the right para-aortic dissection, the proximal gonadal vessels were found to be encased by the palpable paraduodenal thickening. Careful dissection revealed bulky para-aortic lymphadenopathy that involved the head of the pancreas and the second portion of the duodenum. It was intimately attached to the duodenal serosa, causing near-complete luminal stricture, and appeared to be causing a high-grade bowel obstruction. General surgery was consulted intraoperatively and determined that it was not possible to resect the lymphadenopathy and alleviate the obstruction without a pancreaticoduodenectomy. A pylorus-sparing pancreaticoduodenectomy (Whipple procedure) with cholecystectomy was performed. The remaining pancreas was soft and normal; and the pancreatic duct diameter was also normal at 3 mm. Her small bowel was determined to be partially malrotated with nearly the entire duodenum on the right side of the

\* Corresponding author at: 200 1st St. SW, Rochester, MN 55905, USA. Fax: +1 507 266 9300.

E-mail address: [Bakkum.jamie@mayo.edu](mailto:Bakkum.jamie@mayo.edu) (J.N. Bakkum-Gamez).

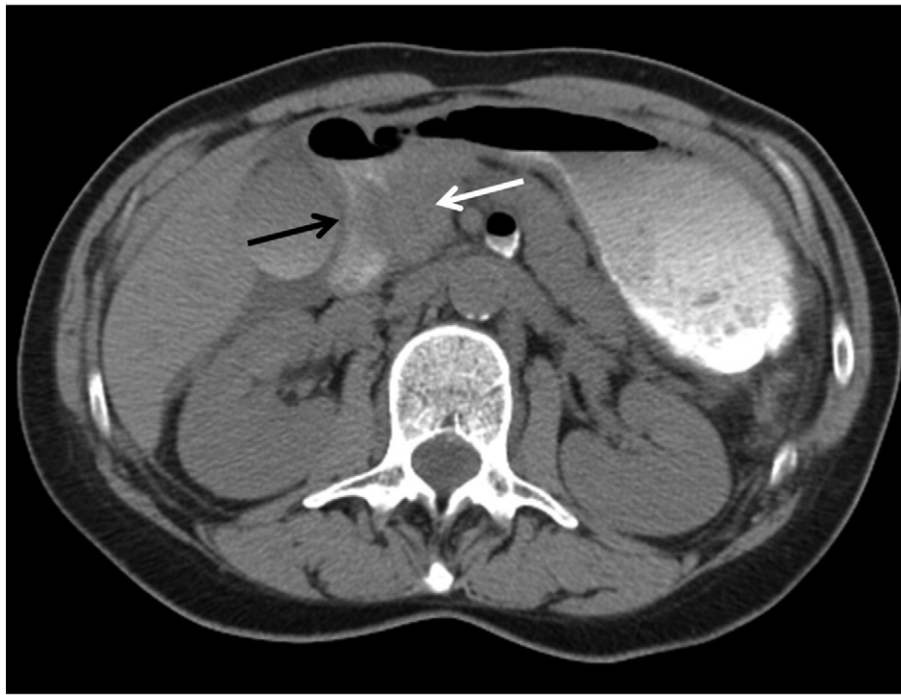

Fig. 1. High grade small bowel obstruction at the level of the duodenum (black arrow) secondary to peripancreatic lymphadenopathy (white arrow).

superior mesenteric vessels. The final diagnosis was stage IIIC, high-grade papillary serous ovarian cancer.

During her initial postoperative hospitalization, she developed a pancreaticojejunostomy anastomotic leak that was controlled with a drain. She was managed with broad-spectrum antibiotics, octreotide, and total parenteral nutrition (TPN) until bowel function returned. She was dismissed home on postoperative day #16. Just over one month after surgery, she was readmitted with a pancreatico-cutaneous fistula communicating through her midline incision. She was managed with bowel rest, TPN, octreotide, a proton-pump inhibitor, broad-spectrum antibiotics, wound debridement with lateralization of the fistula, and a vacuum wound device. During this hospitalization, a pelvic abscess was also diagnosed and managed with CT-guided drainage and antibiotics. She was discharged on hospital day #27.

Her fistula healed, and two weeks after dismissal, she began 6 planned intravenous (IV) cycles of paclitaxel and carboplatin. After each treatment, she had serous drainage from her fistula site for a few days. Nevertheless, she had no interruptions in her planned treatments and had a CA 125 of 2.2 U/mL upon completion of adjuvant therapy.

Given her personal history of breast and ovarian carcinoma, she underwent BRCA testing. She was found to have a deleterious BRCA2 mutation, namely R2336H (7235G > A). Additionally, a BRCA1 variant of unknown significance was identified (IVS11 + 3A > G), which has since been reclassified as a suspected deleterious mutation.

She was disease free for fifteen months after initial diagnosis and for nine months after completion of platinum-based chemotherapy. Abdominal bloating and constipation prompted a CT that demonstrated ascites and mesenteric nodules; her CA 125 was 56 U/mL. She received carboplatin and gemcitabine and, after three cycles, developed a carboplatin allergy and switched to gemcitabine and bevacizumab. During the first cycle, she was admitted for a small bowel obstruction without a clear transition point that was treated conservatively. Shortly thereafter her treatment was interrupted by osteomyelitis associated with a large abscess anterior to the pubic symphysis that required surgical debridement and antibiotics.

She elected not to receive chemotherapy for the next eleven months until she developed progressive disease in an axillary lymph node, the left rectus, and the vaginal cuff. Systemic treatment with various regimens of liposomal doxorubicin, topotecan, bevacizumab, cyclophosphamide, protein-bound paclitaxel, AT-406, carboplatin with desensitization, anastrozole, and capecitabine were administered over the next 43 months with short responses at best. When she developed rectovaginal bleeding secondary to tumor involvement, palliative radiation with 3000 cGy in 10 fractions was administered.

Within two months of radiation, she developed a partial bowel obstruction secondary to a rectosigmoid stricture which was managed conservatively with placement of two colonic stents. After discharge from the hospital, she began ABT-888 on a compassionate use basis, however discontinued it after two months due to weakness and tumor progression. She enrolled in hospice 6.5 years after her primary cytoreduction and passed away shortly thereafter.

## Discussion

Advanced-stage EOC often involves the omentum and can involve contiguous upper abdominal organs such as the spleen, colon, and pancreas (Eisenhauer et al., 2006; Hoffman et al., 2007). The utility of aggressive, multi-organ resection (MOR) has been explored in several primary malignancies that can present with advanced abdominal disease. While morbidity and mortality can be relatively high, aggressive surgical approaches in select patients can lead to prolonged survival (Lygidakis et al., 2007).

Improved survival outcomes in advanced-stage ovarian cancer correlate with increasing completeness of primary cytoreduction (Chi et al., 2006; Eisenhauer et al., 2008; Eisenkop et al., 1998; Aletti et al., 2006). Several aggressive surgical techniques have been described in the management of EOC and are being used more often in the attempts to achieve optimal cytoreduction (Eisenhauer et al., 2006). EOC often involves the retroperitoneum and upper abdomen and can be intimately associated with the pancreas and small bowel. The presence of bulky upper abdominal disease does not appear to portend a worse prognosis

if it is able to be optimally resected (Eisenhauer et al., 2006). Reports on the utility of upper abdominal disease debulking, including distal pancreatectomy for pancreatic tail metastases, have been published with progression-free and overall survival rates similar to optimally-cytoreduced advanced-stage EOC not requiring upper abdominal disease resection (Eisenhauer et al., 2006; Yildirim & Sanci, 2005).

We present a patient with stage IIIC EOC and BRCA 1 and BRCA2 mutations who required pancreaticoduodenectomy to both alleviate a high-grade bowel obstruction and achieve optimal cytoreduction. To our knowledge, pancreaticoduodenectomy has not been previously described as part of the MOR often required for primary cytoreduction of EOC. One recognized complication of pancreaticoduodenectomy is pancreaticojejunostomy anastomotic leak. Bulky lymphadenopathy encasing the second portion of the duodenum and involving the head of the pancreas caused the high-grade bowel obstruction in our patient. Her pancreas was otherwise normal, which increased her risk of pancreaticojejunostomy leak; the incidence of leak increases significantly in patients with a small pancreatic duct ( $\leq 3$  mm) and soft gland texture. Fortunately, the vast majority of these leaks can be managed conservatively (Cullen et al., 1994; Yang et al., 2005).

Despite developing postoperative complications and experiencing a delay in initiating adjuvant chemotherapy, our patient lived for 6.5 years after her initial diagnosis and primary cytoreduction. This case illustrates the impact of aggressive upper abdominal debulking and potential role of pancreaticoduodenectomy in the management of primary EOC.

#### Conflict of interest

The authors have no conflicts of interest to report.

#### References

- Aletti, G.D., et al., 2006. Aggressive surgical effort and improved survival in advanced-stage ovarian cancer. *Obstet. Gynecol.* 107, 77–85.
- Chi, D.S., et al., 2006. What is the optimal goal of primary cytoreductive surgery for bulky stage IIIC epithelial ovarian carcinoma (EOC)? *Gynecol. Oncol.* 103, 559–564.
- Cullen, J.J., Sarr, M.G., Ilstrup, D.M., 1994. Pancreatic anastomotic leak after pancreaticoduodenectomy: incidence, significance, and management. *Am. J. Surg.* 168, 295–298.
- Eisenhauer, E.L., et al., 2006. The addition of extensive upper abdominal surgery to achieve optimal cytoreduction improves survival in patients with stages IIIC–IV epithelial ovarian cancer. *Gynecol. Oncol.* 103, 1083–1090.
- Eisenhauer, E.L., et al., 2008. The effect of maximal surgical cytoreduction on sensitivity to platinum-taxane chemotherapy and subsequent survival in patients with advanced ovarian cancer. *Gynecol. Oncol.* 108, 276–281.
- Eisenkop, S.M., Friedman, R.L., Wang, H.J., 1998. Complete cytoreductive surgery is feasible and maximizes survival in patients with advanced epithelial ovarian cancer: a prospective study. *Gynecol. Oncol.* 69, 103–108.
- Hoffman, M.S., Tebes, S.J., Sayer, R.A., Lockhart, J., 2007. Extended cytoreduction of intraabdominal metastatic ovarian cancer in the left upper quadrant utilizing en bloc resection. *Am. J. Obstet. Gynecol.* 197, 209.
- Lygidakis, N.J., Bhagat, A.D., Vrachnos, P., Grigorakos, L., 2007. Multiorgan resection for advanced abdominal malignancies—is it feasible? *Hepatogastroenterology* 54, 1353–1358.
- Yang, Y.M., et al., 2005. Risk factors of pancreatic leakage after pancreaticoduodenectomy. *World J. Gastroenterol.* 11, 2456–2461.
- Yildirim, Y., Sanci, M., 2005. The feasibility and morbidity of distal pancreatectomy in extensive cytoreductive surgery for advanced epithelial ovarian cancer. *Arch. Gynecol. Obstet.* 272, 31–34.