

Recognition of Immune Reconstitution Syndrome Necessary for Better Management of Patients with Severe Drug Eruptions and Those under Immunosuppressive Therapy

Tetsuo Shiohara¹, Maiko Kurata¹, Yoshiko Mizukawa¹ and Yoko Kano¹

ABSTRACT

The immune reconstitution syndrome (IRS) is an increasingly recognized disease concept and is observed with a broad-spectrum of immunosuppressive therapy-related opportunistic infectious diseases and severe drug eruptions complicated by viral reactivations. Clinical illness consistent with IRS includes tuberculosis, herpes zoster, herpes simplex, cytomegalovirus infections and sarcoidosis: thus, the manifestations of this syndrome are diverse and depend on the tissue burden of the preexisting infectious agents during the immunosuppressive state, the nature of the immune system being restored, and underlying diseases of the hosts. Although IRS has originally been reported to occur in the setting of HIV infection, it has become clear that the development of IRS can also be in HIV-negative hosts receiving immunosuppressive agents, such as prednisolone and tumor necrosis factor α inhibitors, upon their reduction and withdrawal. Drug-induced hypersensitivity syndrome, a life-threatening multiorgan system reaction, is another manifestation of the newly observed IRS. Clinical recognition of the IRS is especially important in improving the outcome for diseases with an otherwise life-threatening prognosis. Clinicians should be aware of the implications of IRS and recognize that relieving the symptoms and signs of immune recovery by anti-inflammatory therapies needs to be balanced with anti-microbial therapies aiming at reducing the amplitude and duration of tissue burden of preexisting microbes.

KEY WORDS

corticosteroids, drug-induced hypersensitivity syndrome, herpesviruses, immune reconstitution, TNF- α inhibitors

INTRODUCTION

Although underlying infections have been suggested to increase infected patients' susceptibility to severe drug eruptions, the relationship between infections and the development of severe drug eruptions has not been extensively explored until the time when we propose the intimate relationship between herpesvirus infections and severe drug eruption.^{1,2} Since then, however, it has become clear that closely related bidirectional pathways exist in which infections and drug allergy are involved. Thus, physicians treating patients with severe drug eruptions need to be aware of

underlying (virus) infections, particularly herpesvirus infections, as one of the most important aspects of management of patients with severe drug eruptions. Because those patients often receive immunosuppressive agents either early or later in the course of their illness, a wealth of information on the interaction between herpesviruses and the immune responses should be gathered to better manage those patients.

Immunocompetent subjects can largely control herpesviruses, such as cytomegalovirus (CMV) and Epstein-Barr virus (EBV), by cellular effector functions based on a repertoire of memory CD4⁺ and CD8⁺ T cells that develop and expand during lifetime.

¹Department of Dermatology, Kyorin University School of Medicine, Tokyo, Japan.

Correspondence: Tetsuo Shiohara, MD, PhD, Department of Dermatology, Kyorin University School of Medicine, 6-20-2 Shin-

kawa, Mitaka, Tokyo 181-8611, Japan.

Email: tpshio@ks.kyorin-u.ac.jp

Received 31 August 2010.

©2010 Japanese Society of Allergy

Defects in these T cells are associated with increased occurrences of opportunistic infections, reactivation of latent viruses and chronic inflammatory and autoimmune disorders. In this setting, disease expression has typically been understood as microbial damage afflicted by these pathogens. However, an intriguing aspect that has received little attention so far is that restoration of host immunity may also have adverse sequelae, particularly when it occurs abruptly and rapidly. Indeed, when the timing of onset of an adverse cutaneous drug reaction was carefully evaluated in patients infected with HIV, the onset of a majority of the eruptions was found to be concentrated within 6-14 days of starting highly active antiretroviral therapy, (HAART),³ coincident with restoration of host CD4 T-cell number and reactivity. Indeed, during the early phase of immune restoration on HAART, a significant proportion of patients (15-25%) develop clinical deterioration due to restoration of the capacity to mount innate and adaptive immune responses against preexisting infectious agents. This clinical deterioration is called immune reconstitution syndrome (IRS). Clinical recognition of this syndrome is especially important in management of patients under immunosuppressive therapy, because this syndrome develops not only in patients with HIV infection but also in non-HIV immunocompetent hosts, such as patients with severe drug eruptions and those on immunosuppressive therapy, upon reduction or withdrawal of immunosuppressive agents or chemotherapy. More recently, the development of IRS has also been observed in lymphopenic and neutropenic patients,^{4,5} and patients receiving tumor necrosis factor (TNF) α inhibitors.⁶⁻⁸ The manifestations of this syndrome are diverse and depend on the tissue burden of the preexisting infectious agents involved under immunosuppressive conditions, the nature of the immune system being restored, and underlying diseases of the hosts. Because some cases with IRS are self-limited within a week while others are fatal or life threatening, it is difficult to predict the prognosis and suggest potential treatment options from the clinical manifestations in the early phase. Thus, management of this syndrome should be decided on an individual basis. In this review, we describe a variety of manifestations of IRS, particularly those associated with severe drug eruptions, and management options. This review also focuses exclusively on the spectrum of clinical manifestations of IRS occurring in the setting of therapy with immunosuppressive agents, whose clinical course is complicated by the development of IRS that is usually associated with the corticosteroid therapy on its reduction or withdrawal. Clinical recognition of the IRS is extremely important in improving the outcome for diseases with an otherwise life-threatening prognosis.

DEFINITION OF IRS

Several different terms other than IRS have been used to describe this syndrome: they include immune reconstitution inflammatory syndrome (IRIS), immune reconstitution disease (IRD), immune recovery disease, immune rebound illness, and steroid-withdrawal disease. IRS is originally defined as a paradoxical deterioration in clinical status attributable to the recovery of the immune response following institution of HAART in HIV patients.⁹⁻¹¹ Within 1-2 weeks of starting HAART therapy, a dramatic reduction (100-fold) in HIV RNA levels can be detected, coincident with the increase in circulating CD4⁺ T cells with a memory phenotype in number. This rapid increase in CD4⁺ T cell numbers is more likely to be due to redistribution of this population to the circulation rather than preferential cell proliferation. Not only the frequency but also functions of these memory CD4⁺ T cells can be also restored to a clinically relevant degree after starting HAART therapy.¹² The numerical rise of CD8⁺ T cells with a memory phenotype and naïve CD4⁺ T cells also occurs within 1 week following the initiation of HAART.¹³

The interval between the start of HAART and the onset of clinical symptoms or signs of IRS is highly variable, ranging from <1 week to several months but the majority of IRS occur within the first 8 weeks after the initiation of HAART therapy.⁵ In addition to the interval, the manifestations of IRS are also widely varied, depending on the particular infectious agent involved and the degree of the recovery of the immune system. Clinical symptoms of IRS is characterized by paradoxical deterioration of a preexisting, although previously unrecognized, microbial infection that is temporally associated with a decrease in the tissue burden of the preexisting pathogens (Fig. 1): this decrease is often reflected in paradoxical deterioration of laboratory findings. Thus, the patients usually present with worsening or new clinical manifestations of a previously preexisting infection that could be either asymptomatic or mildly symptomatic before developing IRS: the infection would be usually unrecognized by clinicians before starting HAART, or reduction or withdrawal of immunosuppressive agents.¹⁴ The target of restored inflammatory reactions is not restricted to infectious pathogens, but also includes inert foreign antigens such as tattoo pigment¹⁵ in the case of sarcoidosis and tumor antigens¹⁶ in the case of Kaposi's sarcoma.

DIAGNOSIS OF IRS

The clinical symptoms of IRS range from a self-limited mild disease to a severely ill, life-threatening disease. Usually, IRS occurs as a paradoxical deterioration in clinical status associated with recovery of the immune response after initiating HAART in patients with HIV infection. Even in the absence of HIV

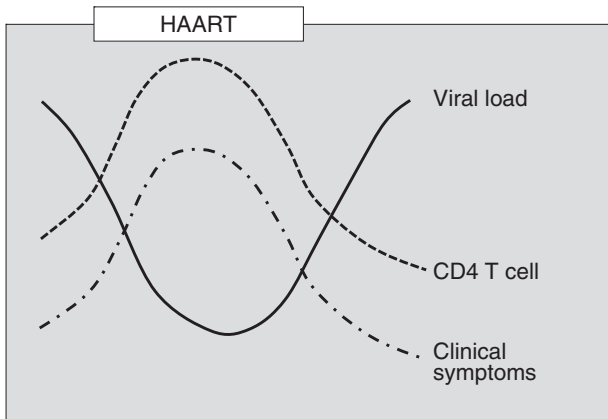


Fig. 1 IRS occurring after starting HAART in HIV-positive patients.

infection, however, IRS has been reported to develop on withdrawal of chemotherapy or reduction of immunosuppressive agents, such as prednisolone.^{9,17} The new onset or exacerbation of the skin diseases known to develop as clinical manifestations of IRS, such as sarcoidosis, has been also reported to occur in association with TNF- α -blocking therapy in patients with rheumatoid arthritis.^{18,19} In view of the fact that a similar sarcoid-like reaction occurred as a consequence of an immune reconstitution under HAART for HIV infection,^{20,21} sarcoidal lesions may appear as clinical symptoms of IRS in these patients during the recovery of immune responses, although these lesions are generally perceived as undesired effects of treatment.

Unfortunately, there has been considerable confusion of the definition of IRS in the literature: some authors have used the strict criteria to define IRS, such as a paradoxical deterioration in clinical symptoms attributable to recovery of the immune system during HAART in HIV-positive patients.²² In contrast, other authors have expanded the spectrum of IRS to include a clinical deterioration induced by reduction or withdrawal of immunosuppressive agents in HIV-negative individuals. To avoid confusion, this article includes both types of reactions, and emphasis is placed on the IRS in HIV-negative individuals. In summary, the clinical characteristics of IRS modified from criteria proposed by Shelburne *et al.*²³ are as follows: (1) paradoxical deterioration of a preexisting infection attributable to the recovery of the immune system; (2) a decrease in viral loads with or without an increase in CD4⁺ T cell counts; (3) clinical symptoms not explained by a newly acquired infection, by the expected clinical course of a previously recognized infectious agent, or by side effect of therapy; and (4) any event occurring after initiation of HAART or after withdrawal or reduction of immunosuppressive agents including biologics, regardless of whether patients are HIV-positive or -negative.

DRUG ERUPTIONS AS A MANIFESTATION OF IRS

Drug-induced hypersensitivity syndrome (DIHS) is a life-threatening multiorgan system reaction caused by a limited number of drugs: they include carbamazepine, phenytoin, phenobarbital, zonisamide, allopurinol, dapsone, salazosulapyridine and mexiletine.^{1,2,24-31} However, this syndrome has several unique clinical features that cannot be solely explained by drug antigen-driven oligoclonal expansions of T cells, which have been implicated in the pathogenesis of other drug eruptions. They include a paradoxical deterioration of clinical symptoms, frequent flare-ups and a step-wise development of several organ system failures after withdrawal of the causative drugs,^{26,30} and unexplained cross-reactivity to multiple drugs with structures totally different from the original causative drugs.^{26,30} Close clinical similarities between DIHS and infectious mononucleosis suggested an additional role of viral infections.^{1,2,26} Indeed, our recent studies have demonstrated that several herpesviruses including herpesvirus 6 (HHV-6), HHV-7, EBV and CMV can be reactivated during the course of this syndrome in a sequential order as in graft-versus-host disease.²⁹ However, several questions have been raised as to why HHV-6 reactivation, which is used as a specific marker for this syndrome,²⁵ occurs generally 2-3 weeks after the onset of this syndrome and why particular virus could not be detected coincident with the onset of severe symptoms. Based on these findings, reactivations of these herpesviruses observed in DIHS was generally thought to be the consequence of disease,²⁴ contrary to our hypothesis³⁰: according to our hypothesis, reactivations of herpesviruses would represent the actual early events that trigger activation of drug antigen-specific T cells: however, this event would occur in an unrecognized fashion far before onset of clinical symptoms. In view of the observations that paradoxical worsening of clinical symptoms associated with reduction in viral loads is typically observed after withdrawal of the causative drug at onset of DIHS,^{2,30} it is attractive to suppose that DIHS is a manifestation of the newly observed IRS (Fig. 2). These clinical observations may be explained by assuming that the rapid restoration of pathogen-specific immunity would reduce viral loads at onset, thereby rendering them undetectable in the blood.

In order to expand the spectrum of IRS to include DIHS, it was important to know to what extent DIHS resembles IRS by demonstrating similarities between both conditions. We analyzed a total of 12 patients (6 male, 6 female; age range 25-70 years, mean age 46.5 \pm 15.3 years), who admitted to our Dermatology Department from 2001 to 2006 and met the criteria for DIHS.²⁵ Clinical status of these patients on day 3-4 was defined as a paradoxical deterioration despite

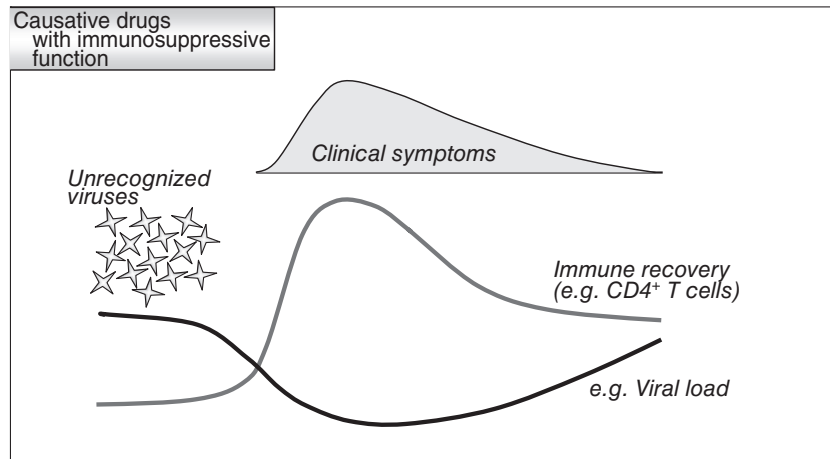


Fig. 2 DIHS is another manifestation of the newly observed IRS. The causative drugs of DIHS have immunosuppressive properties in common^{2,26,30} and their protracted use results in the immunosuppressive state, thereby causing the increase in viral loads in an unrecognized fashion. Upon withdrawal of these drugs, antiviral immune responses are rapidly restored, thereby causing immunopathology and the reduction in viral loads.³⁰

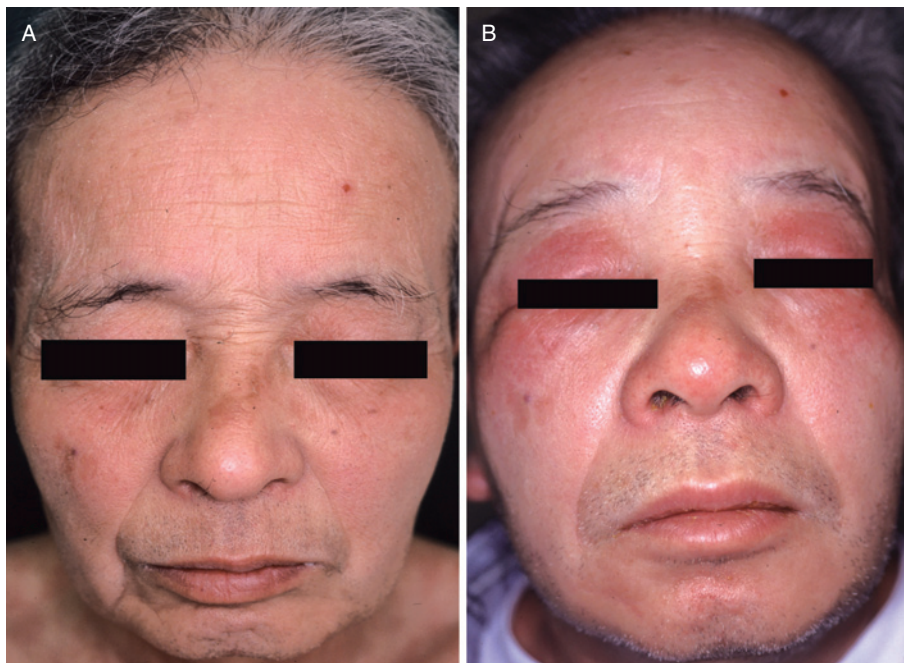

Fig. 3 Paradoxical deterioration of skin lesions in IRS observed after withdrawal of the causative drug. This patient with DIHS exhibited prominent paradoxical deterioration of facial edema and erythema (B) 4 days after the withdrawal, as compared with those at the initial presentation (A).

withdrawal of the causative drug, when the extent of skin involvement as evaluated by the body surface area (BSA) was 2 times more than their initial presentation; and an increase in their body temperature $>1^{\circ}\text{C}$ from that at their initial presentation. According to this definition, 8 out of the twelve patients exhib-

ited a paradoxical deterioration in clinical status despite withdrawal of the causative drug (Fig. 3). In the remaining four patients, oral prednisolone had been started at a dose of 40-60 mg/day at their initial presentation, because their skin lesions had rapidly progressed, in a few days before presentation, to over

Table 1 Reported clinical illness consistent with IRS in HIV-negative hosts

<i>Mycobacterium avium complex</i> infection
Tuberculosis
Cryptococcosis †
Herpes simplex †
Herpes zoster †
Hepatitis C virus infection
Hepatitis B virus infection
Cytomegalovirus infection †
Kaposi sarcoma
Sarcoidosis
Graves disease
Hashimoto thyroiditis †
Drug-induced hypersensitivity syndrome

† Infectious and autoimmune diseases often observed during the course of drug-induced hypersensitivity syndrome or long after its resolution.

60% or more of BSA, probably due to their earlier timing of withdrawal of the causative drugs: unfortunately, however, the exact time frames between withdrawal of the causative drug and their initial presentation was not available in these patients. In these patients, oral prednisolone given as initial therapy had a rapid response. In the eight patients with paradoxical deterioration in clinical symptoms, 5 cases that initially failed to respond to oral prednisolone subsequently improved with intravenous immunoglobulin (IVIG, 0.1 g/kg/day, 5-10 days).

According to the diagnostic criteria for IRS proposed by Shelburne *et al.*,²³ an increase in CD4⁺ T-cell numbers is a prerequisite for the diagnosis of IRS. This prompted us to investigate whether an increase in CD4⁺ T-cell numbers could be observed and onset in these patients. Because CD4⁺ T-cell numbers before onset of DIHS were not available in the vast majority of patients, we sequentially analyzed lymphocyte subsets from the 10 patients at various time points after their initial presentation and compared CD4⁺ T-cell numbers at onset with those on several occasions after onset. As previously described,³¹ a profound decrease in CD19⁺ B-cell numbers and CD56⁺ NK-cell numbers were observed at their initial presentation. In contrast, CD4⁺ T-cell numbers initially increased in 9 of the 10 patients; they were gradually declined, reaching normal values by 2 months after onset. According to the original definition,²³ an increase in CD4⁺ T-cell numbers is diagnostic of IRS and can typically be detected within 1-2 weeks of starting antiretroviral therapy in HIV-infected patients. Consistent with this, our sequential analyses showed that the initial increase in CD4⁺ T-cell numbers was seen in many, if not all, patients with DIHS, followed by the subsequent decrease coincident with improvements in clinical status. In some patients, a

concomitant increase in CD8⁺ T-cell numbers was also noted. These alterations in lymphocyte subsets during the observation period were not related to our use of oral prednisolone for the treatment of DIHS, because similar alterations were observed in patients who never received prednisolone. The degree of the increase in CD4⁺ T-cell numbers best correlated with the severity of clinical symptoms, such as the extent of skin lesions at the acute stage.

SKIN DISEASES AS MANIFESTATIONS OF IRS

The occurrence or recurrence of various infectious diseases and autoimmune diseases has been reported in many patients recently starting HAART, those with severe drug eruptions or those receiving immunosuppressive therapy on a reducing dose or withdrawal of immunosuppressive agents, as shown in Table 1.

HERPES ZOSTER

Herpes zoster (HZ) is caused by reactivation of latent varicella zoster virus (VZV) within a sensory ganglion. HZ is the most common manifestation of IRS in HIV-infected individuals and it counted for 40% of IRS events in one cohort³²: the incidence of HZ is higher than immunocompetent healthy individuals; and the incidence is relatively consistent regardless of the stages of HIV infection.³³ HZ has been reported to occur two- to five-fold more frequently in HIV-infected patients treated with HAART than in those not receiving HAART.³⁴⁻³⁶ The timing of HZ after the initiation of HAART has been highly variable, ranging from 4 weeks to 103 weeks.³⁴⁻³⁶ Onset of HZ in 50% of cases occurred within the first 4 weeks after initiation of HAART and 86% occurred between week 4 and 16.³⁴ There was a significant increase in CD8⁺ T cell numbers and percentages concurrent with HZ episodes, as well as reduction of HIV viral load,³⁵ while in other report, a marked increase in CD4⁺ T cell numbers, but not CD8⁺ T cells, was also observed during HZ episodes.³⁶ These results indicate that vigorous expansion of CD4⁺ T cells may contribute to either the development of IRS or the decrease in HIV viral load. This effect may be mediated by IL-6 or IFN- α , both of which have been shown to play important roles in IRS events.^{37,38} Alternatively, in view of tropism of VZV for CD4⁺ T cells with a skin-homing phenotype,^{39,40} expansion of CD4⁺ T cells may be directly responsible for the development of HZ in this setting.

HIV-negative patients undergoing bone-marrow or organ transplantation and treated with immunosuppressive agents including corticosteroids, are also at increased risk of developing HZ as a manifestation of IRS. The timing of HZ after starting these treatments was more variable than in those treated with HAART. As compared with the setting of HAART-induced immune reconstitution, it is difficult to estimate when immune reconstitution occurs after starting these

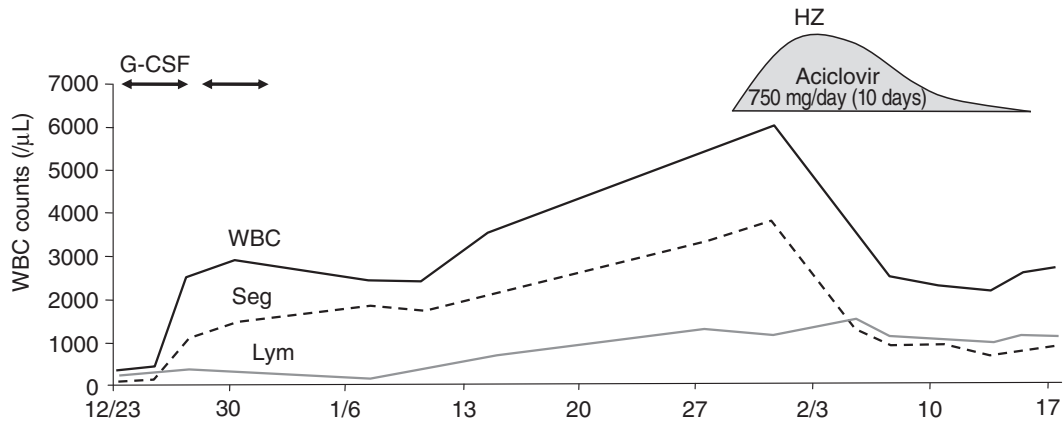


Fig. 4 HZ developing 2 months after the final course of chemotherapy. The onset of HZ is coincident with the restoration of immune responses as evidenced by the increase in neutrophil and lymphocyte counts.

treatments. Although these treatments themselves are thought to place some patients at increased risk of developing HZ, it may be noted that not all patients develop HZ after withdrawal or tapering dose of these immunosuppressive agents if the timing of HZ is carefully checked in relation to these treatments. Unfortunately, however, literature review on this issue is not possible at this time, because little attention has been focused on the timing of HZ in relation to these treatments. Although our series was not large enough to demonstrate the exact timing of HZ onset after the start of these treatments, we found that most cancer patients (35 cases) developed HZ 1 to 3 months after the final course of chemotherapy (Fig. 4) and that patients with rheumatoid arthritis or lupus developed HZ as well, 1 to 3 weeks after tapering dose of oral prednisolone (Kurata, M. *et al.*, unpublished data). Because recent studies have found no significant outcomes, such as HZ, associated with short-term use of prednisolone in advanced HIV infection,⁴¹ short-term prednisolone therapy is unlikely the major cause of HZ in this setting. Interestingly, in the most HIV-negative cases of HZ occurring upon withdrawal or reduction in immunosuppressive agents, the rash generally appears on the trunk and extremities, but not on the face and head. Most cases had uncomplicated dermatomal HZ and none had severe complications, such as fatal disseminated HZ. Thus, VZV reactivation in the setting of immune reconstitution may elicit only a mild inflammatory reaction. Indeed, in the setting of DIHS, patients usually manifest a mild form of HZ before and after onset of DIHS: the onset of HZ is usually 2 to 3 months after onset of DIHS and often associated with the reduction of corticosteroids. There have been case reports of nondermatologic zoster, *zoster sine herpette*: they include stromal keratitis and iritis without concurrent HZ skin lesions. In addition, rare association of severe VZV vasculopathy involving the central nervous

system in the setting of IRS has been also reported.

HERPES SIMPLEX

Frequent reactivations of herpes simplex virus (HSV) serve to increase the level of HIV viral load, with implications for HIV transmission and disease progression.⁴² Although HAART is theoretically thought to have a beneficial effect on HSV reactivation, it remains to be established whether the incidence and severity of HSV disease could be decreased after HAART. Ratnam and colleagues⁴³ reported that HSV accounted for 50% of all IRS events and the onset to be a median of 12 weeks after starting HAART. However, reports regarding the timing and incidence of HSV onset after starting HAART have been diverse depending on the definition of IRS. In this regard, they used strict criteria for IRS: they defined HSV disease as a manifestation of IRS only when the frequency, severity, or poor response to treatment was significantly increased during the 6 months after starting HAART. Severe cases with extensive perianal lesions and fever, severe hemorrhagic nasolabial lesions, or encephalitis, respectively, have been also reported after starting HAART.^{43,44} Some cases have run a chronic course. The clinical course of these cases is likely to indicate that restoration of immune responses to HSV may remain partial despite successful control of HIV replication⁴⁵ thereby causing an imbalance between autoreactive and autoregulatory lymphocytes: this imbalance could result in the development of severe lesions.

Neurologic complications probably induced by reactivations of HSV or HHV-6 have been also reported to occur during the course of DIHS. Masaki *et al.* reported a patient with allopurinol-induced DIHS who developed encephalitis after the reduction of corticosteroids.⁴⁶ The cerebrospinal fluid (CSF) polymerase chain reaction (PCR) assay was positive for HHV-6 in this patient. We also described a patient

Immune Reconstitution Syndrome

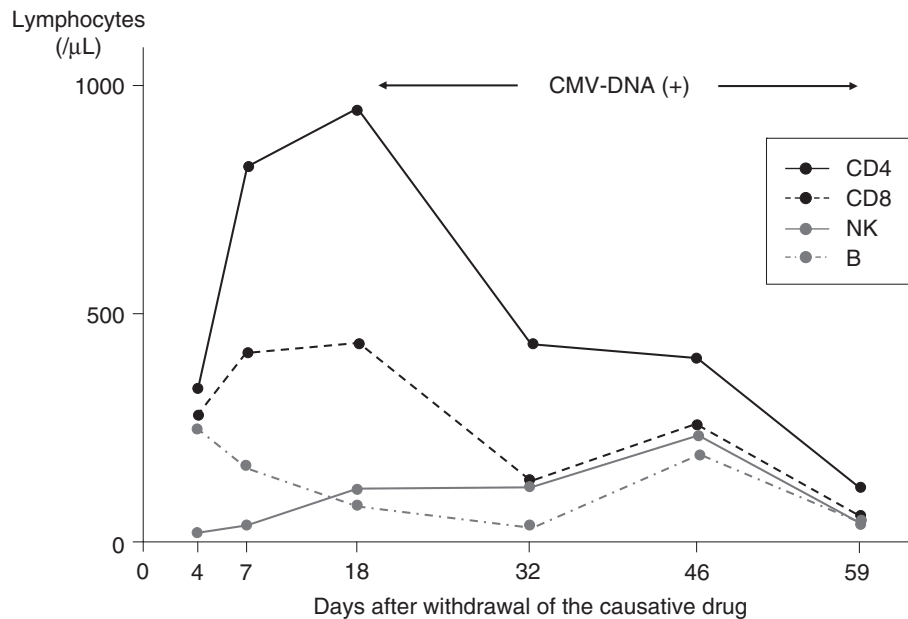


Fig. 5 CMV reactivation coincident with expansions of circulating CD4⁺ T cells in a HIV-negative patient with DIHS.⁵⁹

with phenobarbital-induced DIHS who revealed syndrome of inappropriate secretion of antidiuretic hormone (SIADH) associated with limbic encephalitis.⁴⁷ However, no viral DNA was identified by PCR in CSF specimens repeatedly collected after the onset of encephalitis. Because of suspected herpetic encephalitis, empirical high-dose aciclovir (10 mg/kg every 8h IV) was started for 7 days with some effects. Although it remains to be determined whether SIADH and limbic encephalitis commonly have developed as a result of HHV-6 or HSV reactivation in our case, our failure to detect viral DNA in CSF may be explained by partial restoration of HHV-6 or HSV-specific immunity during the course of DIHS: immune reconstitution to HHV-6 or HSV in the central nervous system was the presumed cause. Interestingly, a similar unusual presentation of limbic encephalitis caused by HHV-6, associated with hyponatremia, has been previously described in several hematopoietic cell transplant recipients who developed a generalized skin rash suggestive of graft-vs.-host disease (GVHD).⁴⁸

CYTOMEGALOVIRUS

CMV usually persists in a latent asymptomatic state after initial infection in the vast majority of individuals. Overt CMV disease predominantly induced by reactivation of latent CMV can be produced in an immunosuppressive host, such as organ transplant recipients, patients with AIDS, and those receiving immunosuppression agents. CMV disease can usually present as visceral diseases ranging from pneumonia to widely disseminated diseases,^{49,50} cutaneous manifestations are rare and very variable, including ulcers,

vesicles, purpuric macules, verrucous lesions, prurigo nodularis-like lesions, erythematous and crusted papules and digital infarct, regardless of whether it is specific or nonspecific.⁵¹⁻⁵⁴ These lesions occur as the late systemic manifestation of CMV infections and usually portend a fatal course.^{55,56}

Regarding CMV infection as a manifestation of IRS in the setting of HIV infection, CMV retinitis is a common complication at the late stage.²³ The severity of clinical symptoms is far greater than that seen in the setting of non-HIV infection, and therefore it was termed "immune recovery retinitis".⁵⁷ CMV infection in the setting of IRS is also characterized by the systemic nature and cutaneous manifestations have been rarely reported. Qazi and colleagues,⁵⁸ however, reported a rare case of extensive CMV cutaneous ulceration occurring in a patient with HIV infection 3 months after starting HAART. Because the onset of CMV ulceration was associated with an increase in CD4⁺ T cell counts and a decrease in HIV viral load and the patient had a history of CMV retinitis, these features have fulfilled the criteria for IRS. This case was very unique in that the extensive CMV ulceration involved the back, both arms, and the left ear, instead of localized in the perianal region; that the patient had received maintenance prophylaxis with oral ganciclovir before the onset of the extensive CMV ulceration, and that the CMV ulcerations improved with addition of intravenous methylprednisolone to the treatment regimen. These features are consistent with CMV infection as a manifestation of IRS and are different from that occurring in immunocompromised patients not receiving HAART.

We have recently reported two HIV-negative patients with DIHS, who developed cutaneous CMV ulcers on the trunk (Fig. 5).⁵⁹ This event was eventually followed by the development of gastrointestinal manifestations which were fatal in one patient but not in another. In one patient, 74-year-old man, the eruption began suddenly, and the papules were distributed mainly over the upper back. There were no concomitant perianal ulcers. Within 2-3 days, the lesions became centrally ulcerated with a rim of erythema: the clinical features of the established lesions mimicked those of Degos' disease. Examination of a biopsy specimen of the ulcer showed eosinophilic intranuclear 'owl's eye' inclusions surrounded by a clear halo in the upper dermis: the CMV infection was confirmed by immunohistochemistry. Because of no improvement in his ulceration on oral prednisolone prescribed for drug eruptions, intravenous immunoglobulin (IVIG) was started with significant improvement in his ulcerations. Treatment with intravenous ganciclovir was also added and oral prednisolone was gradually tapered. Although the ulcers showed gradual signs of healing, the patient developed CMV enterocolitis. He eventually died of respiratory failure. In another case (81-year-old man), scratch dermatitis-like erythema developed on the back after 2 week of therapy with IVIG. Ulcerated erythematous papules were also detected on the shoulder. Histologic examination of the papules showed a few cytomegalic endothelial cells harboring eosinophilic intranuclear inclusions. The CMV infection was confirmed by immunohistochemistry. On the same day, he developed CMV gastritis. The patient was successfully treated with intravenous ganciclovir. Because it is widely believed that cutaneous, CMV disease arises from reactivation of a local latent virus or by autoinoculation in periorificial areas by faecal, urinary or salivary shedding of CMV,⁶⁰ CMV ulcers limited to the unusual sites such as trunk would go unrecognized. These cases indicate that a high index of suspicion and intervention may decrease morbidity and the need for monitoring of CMV reactivation even in immunocompetent patients, particularly when unexplained ulcers suddenly develop in patients with severe drug eruptions. In these cases, drug eruptions *per se* would provide a basis for immune reconstitutions as an etiologic factor.

TREATMENT OF IRS

Before starting treatment, it is important to exclude the possibility that paradoxical worsening of clinical symptoms of a preexisting infection regarded as signs of IRS could be a result of inadequate antimicrobial therapy or superinfection with other microorganisms,⁹ because some individuals with IRS worsen clinical symptoms as a result of sub-optimal immune function associated with inadequate antimicrobial therapy. Although corticosteroids are most fre-

quently used agent, there have not been clear guidelines for how patients with IRS are treated with corticosteroids. Because a mild form of IRS responds to specific treatment for the underlying pathogens, anti-inflammatory therapies are not generally required: thus, the management of patients with IRS is predominantly supportive. In patients with severe forms of IRS, however, anti-inflammatory therapies in addition to anti-microbial therapies are necessary to ameliorate clinical symptoms due to overshooting of immune recovery. Nevertheless, the need for relieving the symptoms and signs of immune recovery by anti-inflammatory therapies should be balanced with antimicrobial therapies aiming at reducing the amplitude and duration of tissue burden of preexisting microbes.

Corticosteroids have been the mainstay of treatment for IRS and are the only treatment for which clinical trial data exist.⁶¹ Significant benefit was demonstrated in terms of symptom improvement in a range of infectious diseases: they include bacterial meningitis, tuberculous meningitis, pneumocystic pneumonia, microbacterial avium complex, leprosy, cryptococcosis, and *Pneumocystis jiroveci*.⁶¹ Indeed, systemic corticosteroids gave promising results in terms of ameliorating vigorous restoration of immune responses to pathogens during the course of DIHS, as a manifestation of IRS. However, once systemic corticosteroids have started, drug dose should be reduced gradually even upon resolution of clinical manifestations in IRS, particularly in DIHS, because patients with DIHS are at greater risk of subsequently developing the wide spectrum of IRS ranging from CMV disease to autoimmune diseases^{29,62,63} and the use of systemic corticosteroids represents an important factor that increases the risk of disease progression to full manifestations of IRS upon the withdrawal or reductions. Given the high risk of sequelae from CMV reactivation in patients with DIHS, the direct anti-CMV medications with stepwise withdrawal of corticosteroids may help to avoid disease progression to full manifestations of IRS.

TNF- α plays a critical role in the initial host response to infection. Although it has been proposed that TNF- α inhibitors may be effective in the treatment of IRS, patients treated with TNF- α inhibitors have been reported to have developed IRS during anti-tuberculous treatment⁶⁴⁻⁶⁷: active tuberculosis occurred after a medium duration of 3.5 months of infliximab use. Mirmirani *et al.* reported that a HIV-infected patient developed active sarcoidosis soon after starting HAART.⁶⁸ Indeed, the histological hallmark of IRS is granuloma formation, which is mediated by Th1 cells⁶⁹ and the formation of granulomas is often observed in the late lesion of DIHS. Thus, TNF- α inhibitors could induce or precipitate sarcoidosis as a manifestation of IRS while they may benefit some patients with IRS.

CONCLUSION

Maintaining a fine balance between host and infectious agents, but not eradication of the latter, is the therapeutic goal of IRS. Although corticosteroids or TNF- α inhibitors may improve the clinical symptoms, one needs to be cautious in determining when a therapy that would abrogate the immune response to the infectious agents can be initiated.

Prompt recognition of DIHS as a new manifestation of IRS could help the physicians to determine the appropriate next step when a complex sequence of events described above occurs, thus improving the morbidity and mortality of otherwise life-threatening disease. Future studies of the appropriate management of IRS will need to establish a diagnostic tool that can distinguish whether clinical symptoms worsen as a result of an overwhelming inflammatory response or they do as a consequence of expansions of an opportunistic organism induced by sub-optimal immune function.

ACKNOWLEDGEMENTS

This work was supported in part by grants from the Ministry of Education, Culture, Sports, Science and Technology, Japan (to T.S. and Y.K.) and the Health and Labour Sciences Research Grants (Research on Intractable Diseases) from the Ministry of Health, Labour and Welfare of Japan (to T.S.).

REFERENCES

1. Suzuki Y, Inagi R, Aono T, Yamanishi K, Shiohara T. Human herpesvirus 6 infection as a risk factor for the development of severe drug-induced hypersensitivity syndrome. *Arch Dermatol* 1998;**134**:1108-12.
2. Shiohara T, Kano Y. A complex interaction between drug allergy and viral infection. *Clin Rev Allergy Immunol* 2007;**33**:124-33.
3. Smith KJ, Skelton HG, Yeager J, Ledsy R, Ng TH, Wagner KF. Increased drug reactions in HIV-1-positive patients: a possible explanation based on patterns of immune dysregulation seem in HIV-1 disease. *Clin Exp Dermatol* 1997;**22**:118-23.
4. Miceli MH, Maertens J, Buvé K *et al.* Immune reconstitution inflammatory syndrome in cancer patients with pulmonary aspergillosis recovering from neutropenia: Proof of principle, description, and clinical and research implications. *Cancer* 2007;**110**:112-20.
5. Legrand F, Lecuit M, Dupont B *et al.* Adjuvant corticosteroid therapy for chronic disseminated candidiasis. *Clin Infect Dis* 2008;**46**:696-702.
6. Garcia Vidal C, Rodriguez Fernández S, Martinez Lacasa J *et al.* Paradoxical response to antituberculous therapy in infliximab-treated patients with disseminated tuberculosis. *Clin Infect Dis* 2005;**40**:756-9.
7. Arend SE, Leyten EM, Franken WP, Huisman EM, van Dissel JT. A patient with de novo tuberculosis during anti-tumor necrosis factor- α therapy illustrating diagnostic pitfalls and paradoxical response to treatment. *Clin Infect Dis* 2007;**45**:1470-5.
8. Belknap R, Reves R, Burman W. Immune reconstitution to *Mycobacterium tuberculosis* after discontinuing infliximab. *Int J Tuberc Lung Dis* 2005;**9**:1057-8.
9. Cheng VC, Yuen KY, Chan WM, Wong SS, Ma ES, Chan RM. Immunorestitution disease involving the innate and adaptive response. *Clin Infect Dis* 2000;**30**:882-92.
10. Manabe YC, Campbell JD, Sydnor E, Moore RD. Immune reconstitution inflammatory syndrome: risk factors and treatment implications. *J Acquir Immune Defic Syndr* 2007;**46**:456-62.
11. Hakim FT, Gress RE. Reconstitution of the lymphocyte compartment after lymphocyte depletion: A key issue in clinical immunology. *Eur J Immunol* 2005;**35**:3099-102.
12. Li TS, Tubiana R, Katlama C, Calvez V, Ait Mohand H, Autran B. Long-lasting recovery in CD4 T-cell function and viral-load reduction after highly active antiretroviral therapy in advanced HIV-1 disease. *Lancet* 1998;**351**:1682-6.
13. Notermans DW, Pakker NG, Hamann D *et al.* Immune reconstitution after 2 years of successful potent antiretroviral therapy in previously untreated human immunodeficiency virus type 1-infected adults. *J Infect Dis* 1999;**180**:1050-6.
14. Hirsch HH, Kaufmann G, Sendi P, Battegay M. Immune reconstitution in HIV-infected patients. *Clin Infect Dis* 2004;**38**:1159-66.
15. Silvestre JF, Albares MP, Ramón R, Botella R. Cutaneous intolerance to tattoos in a patient with human immunodeficiency virus: a manifestation of the immune restoration syndrome. *Arch Dermatol* 2001;**137**:669-70.
16. Bower M, Nelson M, Young AM *et al.* Immune reconstitution inflammatory syndrome associated with Kaposi's sarcoma. *J Clin Oncol* 2005;**23**:5224-8.
17. Vento S, Cainelli F, Mirandola F *et al.* Fulminant hepatitis on withdrawal of chemotherapy in carriers of hepatitis C virus. *Lancet* 1996;**347**:92-3.
18. Kudrin A, Chilvers ER, Ginawi A *et al.* Sarcoid-like granulomatous disease following etanercept treatment for RA. *J Rheumatol* 2007;**34**:648-9.
19. Verschuere K, Van Essche E, Verschuere P, Taelman V, Westhovens R. Development of sarcoidosis in etanercept-treated rheumatoid arthritis patients. *Clin Rheumatol* 2007;**26**:1969-71.
20. El Karoui K, Lanternier F, Brunet A, Blanche P, Guillemin L. Sarcoidosis-like reaction related to *propionibacterium acnes* and immune restoration syndrome in HIV infection. *J Rheumatol* 2007;**34**:2495-6.
21. Lenner R, Bregman Z, Teirstein AS, DePalo L. Recurrent pulmonary sarcoidosis in HIV-infected patients receiving highly active antiretroviral therapy. *Chest* 2001;**119**:978-81.
22. Powderly WG, Landay A, Lederman MM. Recovery of the immune system with antiretroviral therapy: the end of opportunism? *JAMA* 1998;**280**:72-7.
23. Shelburne SA 3rd, Hamill RJ, Rodriguez-Barradas MC *et al.* Immune reconstitution inflammatory syndrome: emergence of a unique syndrome during highly active antiretroviral therapy. *Medicine (Baltimore)* 2002;**81**:213-27.
24. Hashimoto K, Yasukawa M, Tohyama M. Human herpesvirus 6 and drug allergy. *Curr Opin Allergy Clin Immunol* 2003;**3**:255-60.
25. Shiohara T, Iijima M, Ikezawa Z, Hashimoto K. The diagnosis of a DRESS syndrome has been sufficiently established on the basis of typical clinical features and viral reactivations. *Br J Dermatol* 2007;**156**:1083-4.
26. Shiohara T, Inaoka M, Kano Y. Drug-induced hypersensitivity syndrome (DIHS): a reaction induced by a complex

- interplay among herpesviruses and antiviral and antitumor immune responses. *Allergol Int* 2006;**55**:1-8.
27. Kano Y, Shiohara T. The variable clinical picture of drug-induced hypersensitivity syndrome (DIHS)/drug rash with eosinophilia and systemic symptoms (DRESS) in relation to the eliciting drug. *Immunol Allergy Clin North Am* 2009;**28**:481-501.
 28. Kano Y, Ishida T, Hirahara K, Shiohara T. Visceral involvements and long-term sequelae in drug-induced hypersensitivity syndrome. *Med Clin North Am* 2010;**94**:743-59.
 29. Kano Y, Hirahara K, Sakuma K, Shiohara T. Several herpesviruses can reactivate in a severe drug-induced multiorgan reaction in the same sequential order as in graft-versus-host disease. *Br J Dermatol* 2006;**155**:301-6.
 30. Shiohara T, Takahashi R, Kano Y. Drug-induced hypersensitivity syndrome. In: Pichler WJ (ed). *Drug Hypersensitivity*. Basel: Karger, 2007;251-66.
 31. Kano Y, Inaoka M, Shiohara T. Association between anticonvulsant hypersensitivity syndrome and human herpesvirus 6 reactivation and hypogammaglobulinemia. *Arch Dermatol* 2004;**140**:183-8.
 32. Jevtovic DJ, Salemovic D, Ranin J, Pesic I, Zerjav S, Djurkovic-Djakovic O. The prevalence and risk of immune restoration disease in HIV-infected patients treated with highly active antiretroviral therapy. *HIV Med* 2005;**6**:140-3.
 33. Buchbinder SP, Katz MH, Hessel NA *et al*. Herpes zoster and human immunodeficiency virus infection. *J Infect Dis* 1992;**166**:1153-6.
 34. Leohloenya R, Meintjes G. Dermatologic manifestations of the immune reconstitution inflammatory syndrome. *Dermatol Clin* 2006;**24**:549-70.
 35. Martínez E, Gatell J, Morán Y *et al*. High incidence of herpes zoster in patients with AIDS soon after therapy with protease inhibitors. *Clin Infect Dis* 1998;**27**:1510-3.
 36. Tangsinmankong N, Kamchaisatian W, Lujan-Zilbermann J, Brown CL, Sleasman JW, Emmanuel PJ. Varicella zoster as a manifestation of immune restoration disease in HIV-infected children. *J Allergy Clin Immunol* 2004;**113**:742-6.
 37. Domingo P, Torres OH, Ris J, Vazquez G. Herpes zoster as an immune reconstitution disease after initiation of combination antiretroviral therapy in patients with human immunodeficiency virus type-1 infection. *Am J Med* 2001;**110**:605-9.
 38. Morlese JF, Orkin CM, Abbas R *et al*. Plasma IL-6 as a marker of mycobacterial immune restoration disease in HIV-1 infection. *AIDS* 2003;**17**:1411-3.
 39. Ku CC, Padilla JA, Grose C, Butcher EC, Arvin AM. Tropism of varicella-zoster virus for human tonsillar CD4 (+) T lymphocytes that express activation, memory, and skin homing markers. *J Virol* 2002;**76**:11425-33.
 40. Ku CC, Zerboni L, Ito H, Graham BS, Wallace M, Arvin AM. Varicella-zoster virus transfer to skin by T cells and modulation of viral replication by epidermal cell interferon-alpha. *J Exp Med* 2004;**200**:917-25.
 41. Mayanja-Kizza H, Jones-Lopez E, Okwera A *et al*, and Uganda-Case Western Research Collaboration. Immunoadjuvant prednisolone therapy for HIV-associated tuberculosis: a phase 2 clinical trial in Uganda. *J Infect Dis* 2005;**191**:856-65.
 42. Ramaswamy M, Waters A, Smith C *et al*. Reconstitution of herpes simplex virus-specific T cell immunity in HIV-infected patients receiving highly active antiretroviral therapy. *J Infect Dis* 2007;**195**:410-5.
 43. Ratnam I, Chiu C, Kandala NB, Easterbrook PJ. Incidence and risk factors for immune reconstitution inflammatory syndrome in an ethnically diverse HIV type 1-infected cohort. *Clin Infect Dis* 2006;**42**:418-27.
 44. French MA, Lenzo N, John M *et al*. Immune restoration disease after the treatment of immunodeficient HIV-infected patients with highly active antiretroviral therapy. *HIV Med* 2000;**1**:107-15.
 45. Burgess K, Price P, James IR *et al*. Interferon-gamma responses to *Candida* recover slowly or remain low in immunodeficient HIV patients responding to ART. *J Clin Immunol* 2006;**26**:160-7.
 46. Masaki T, Fukunaga A, Tohyama M *et al*. Human herpesvirus 6 encephalitis in allopurinol-induced hypersensitivity syndrome. *Acta Derm Venereol* 2003;**83**:128-31.
 47. Sakuma K, Kano Y, Fukuhara M, Shiohara T. Syndrome of inappropriate secretion of antidiuretic hormone associated with limbic encephalitis in a patient with drug-induced hypersensitivity syndrome. *Clin Exp Dermatol* 2008;**33**:287-90.
 48. Chik KW, Chan PK, Li CK *et al*. Human herpesvirus-6 encephalitis after unrelated umbilical cord blood transplant in children. *Bone Marrow Transplant* 2002;**29**:991-4.
 49. Sissons JG, Carmichael AJ. Clinical aspects and management of cytomegalovirus infection. *J Infect* 2002;**44**:78-83.
 50. Streblow DN, Orloff SL, Nelson JA. Acceleration of allograft failure by cytomegalovirus. *Curr Opin Immunol* 2007;**19**:577-82.
 51. Weigand DA, Burgdorf WH, Tarpay MM. Vasculitis in cytomegalovirus infection. *Arch Dermatol* 1980;**116**:1174-6.
 52. Walker JD, Chesney TM. Cytomegalovirus infection of the skin. *Am J Dermatopathol* 1982;**4**:263-5.
 53. Bhawan J, Gellis S, Ucci A, Chang TW. Vesiculobullous lesions caused by cytomegalovirus infection in an immunocompromised adult. *J Am Acad Dermatol* 1984;**11**:743-7.
 54. Horn TD, Hood AF. Clinically occult cytomegalovirus present in skin biopsy specimens in immunosuppressed hosts. *J Am Acad Dermatol* 1989;**21**:781-4.
 55. Pariser RJ. Histologically specific skin lesions in disseminated cytomegalovirus infection. *J Am Acad Dermatol* 1983;**9**:937-46.
 56. Leshner JL Jr. Cytomegalovirus infections and the skin. *J Am Acad Dermatol* 1988;**18**:1333-8.
 57. Holland GN. Immune recovery uveitis. *Ocular Immunol Inflamm* 1999;**7**:215-21.
 58. Qazi NA, Morlese JF, Walsh JC, Bunker CB, Francis N, Nelson MR. Severe cutaneous ulceration secondary to cytomegalovirus inclusion disease during successful immune reconstitution with HAART. *AIDS Read* 2002;**12**:452-7.
 59. Asano Y, Kagawa H, Kano Y, Shiohara T. Cytomegalovirus disease during the course of severe drug eruptions: report of two cases and retrospective study of 18 patients with drug-induced hypersensitivity syndrome. *Arch Dermatol* 2009;**145**:1030-6.
 60. Daudén E, Fernández-Buezo G, Fraga J, Cardenoso L, García-Diez A. Mucocutaneous presence of cytomegalovirus associated with human immunodeficiency virus infection: discussion regarding its pathogenetic role. *Arch Dermatol* 2001;**137**:443-8.
 61. Marais S, Wilkinson RJ, Pepper DJ, Meintjes G. Management of patients with the immune reconstitution inflammatory syndrome. *Curr HIV/AIDS Rep* 2009;**6**:162-71.
 62. Aota N, Shiohara T. Viral connection between drug rashes and autoimmune diseases: how autoimmune re-

- sponses are generated after resolution of drug rashes. *Autoimmun Rev* 2009;**8**:488-94.
- 63.** Aota N, Hirahara K, Kano Y, Fukuoka T, Yamada A, Shiohara T. Systemic lupus erythematosus presenting with Kikuchi-Fujimoto's disease as a long-term sequela of drug-induced hypersensitivity syndrome. A possible role of Epstein-Barr virus reactivation. *Dermatology* 2009;**218**:275-7.
- 64.** Intalaporn P, Poovorawan Y, Suankratay C. Immune reconstitution syndrome associated with parvovirus B19-induced pure red cell aplasia during highly active antiretroviral therapy. *J Infect* 2006;**53**:e79-82.
- 65.** Garcia Vidal C, Rodríguez Fernández S, Martínez Lacasa J *et al.* Paradoxical response to antituberculous therapy in infliximab-treated patients with disseminated tuberculosis. *Clin Infect Dis* 2005;**40**:756-9.
- 66.** Arend SM, Leyten EM, Franken WP, Huisman EM, van Dissel JT. A patient with de novo tuberculosis during anti-tumor necrosis factor-alpha therapy illustrating diagnostic pitfalls and paradoxical response to treatment. *Clin Infect Dis* 2007;**45**:1470-5.
- 67.** Belknap R, Reves R, Burman W. Immune reconstitution by Mycobacterium tuberculosis after discontinuing infliximab. *Int J Tuberc Lung Dis* 2005;**9**:1057-8.
- 68.** Mirmirani P, Maurer TA, Herndier B, McGrath M, Weinstein MD, Berger TG. Sarcoidosis in a patient with AIDS: a manifestation of immune restoration syndrome. *J Am Acad Dermatol* 1999;**41**:285-6.
- 69.** Co DO, Hogan LH, II-Kim S, Sandor M. T cell contributions to the different phases of granuloma formation. *Immunol Lett* 2004;**92**:135-42.