

## CASE REPORT

# Eosinophilic Esophagitis in an Asymptomatic Chinese

Hsueh-Chieh Lu, Ching-Liang Lu\*, Full-Young Chang

*Division of Gastroenterology, Taipei Veterans General Hospital, and National Yang-Ming University School of Medicine, Taipei, Taiwan, R.O.C.*

Eosinophilic esophagitis is a growing problem in adults in Western countries. It is characterized by nausea, vomiting, dysphagia, food impaction, epigastralgia, heart burn and chest pain. Histologic survey is the most potent diagnostic tool. The diagnostic hallmark is the presence of more than 20 eosinophils per high-powered field on esophageal specimen and the absence of mucosal eosinophilia in the stomach. We herein report an asymptomatic Chinese male with eosinophilic esophagitis, which to the best of our knowledge is the first reported case in Asia. The unusual feature of the current case was the lack of symptoms. This case confirms that a dense infiltration of esophageal eosinophils can occur asymptotically. [*J Chin Med Assoc* 2008;71(7):362–364]

**Key Words:** Asia, asymptomatic, eosinophilic esophagitis

## Introduction

Eosinophilic esophagitis is increasingly common in adults in Western countries and is characterized by nausea, vomiting, dysphagia, food impaction, epigastralgia, heart burn and chest pain. This condition was first identified in 1995 when Kelly et al reported 8 patients with persistent, isolated esophageal inflammation and prominent mucosal eosinophilia unresponsive to acid suppression therapy.<sup>1</sup> The patients were successfully treated with a strict amino acid-based diet. Most cases of eosinophilic esophagitis reported previously involved symptomatic Caucasians. We herein report an asymptomatic Chinese male with eosinophilic esophagitis that was incidentally identified by esophagogastroduodenoscopy (EGD) during screening for gastric cancer.

## Case Report

A 43-year-old male underwent EGD for gastric cancer screening. The subject had no dyspeptic or reflux symptoms. He denied personal or family history of allergy or dermatologic disorder. Physical examination

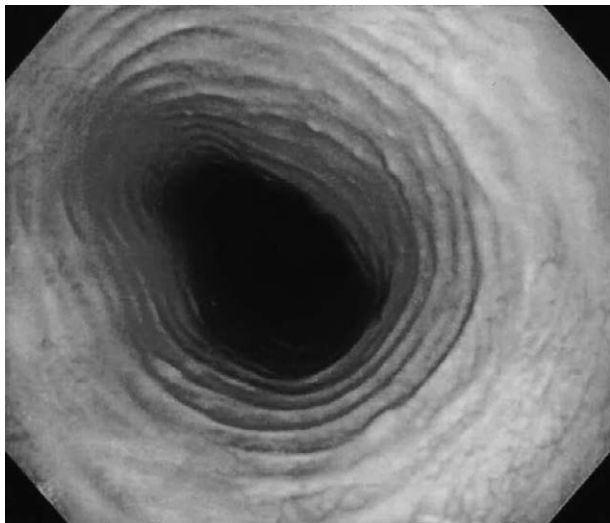
was normal. Blood test showed a normal white blood cell count (4,100/mm<sup>3</sup>) and a normal percentage for eosinophils (2.6%). Multiple concentric rings throughout the esophagus were revealed by EGD, a typical indication of eosinophilic esophagitis (Figure 1). The overlying mucosa was pale, edematous and friable. Biopsy in the distal esophagus disclosed marked eosinophil infiltration in the mucosa (>20 eosinophils/high-powered field) (Figure 2). Biopsy of gastric antrum also revealed histology consistent with chronic gastritis without increased intraepithelial eosinophils. No *Helicobacter pylori* was identified in the gastric mucosa. Since the patient did not have any symptoms, he was asked to undergo regular follow-up without medication. He remained asymptomatic and received EGD with biopsy 1 year later. There were no changes in the endoscopic and histologic features of his esophagus compared with those of the previous year.

## Discussion

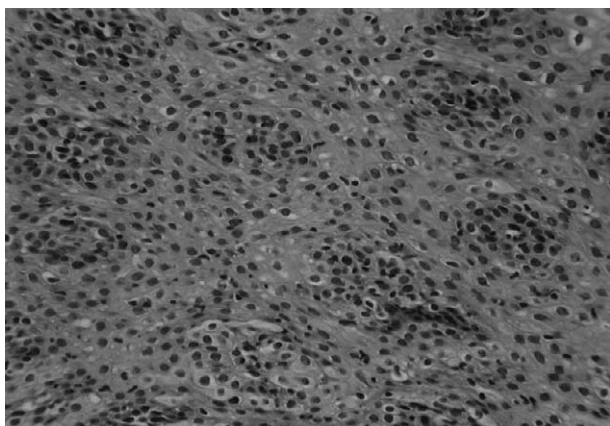
Endoscopy is helpful in the evaluation of eosinophilic esophagitis. Endoscopic findings include mucosal



\*Correspondence to: Dr Ching-Liang Lu, Division of Gastroenterology, Taipei Veterans General Hospital, 201, Section 2, Shih-Pai Road, Taipei 112, Taiwan, R.O.C.  
E-mail: [cllu@vghtpe.gov.tw](mailto:cllu@vghtpe.gov.tw) • Received: October 1, 2007 • Accepted: February 22, 2008



**Figure 1.** Endoscopic survey shows multiple concentric rings throughout the esophagus. The overlying mucosa is pale, edematous and friable.



**Figure 2.** Microscopic appearance of esophageal biopsy specimen reveals mucosal eosinophilia, >20 eosinophils/high-powered field (hematoxylin & eosin, 40 $\times$ ).

edema, fragility, rings, strictures, whitish pinpoint exudates and lumen narrowing.<sup>2</sup> Microscopic analysis of esophageal biopsy specimens is the most effective diagnostic tool. The histologic hallmark is the presence of >20 eosinophils/high-powered field on biopsies from the esophagus and the absence of mucosal eosinophilia in the stomach.<sup>3</sup>

Eosinophilic esophagitis has been reported in Switzerland, Australia, Italy, Spain, England and the United States.<sup>4</sup> This case is, to the best of our knowledge, the first reported in Asia. In a recent population study in Sweden, the prevalence of eosinophilic esophagitis was approximately 0.4%.<sup>5</sup> Eosinophilic esophagitis is apparently rare in Asians, since no similar data are

available for an Asian population. The reason for this regional difference has not been elucidated. A similar geographic variation has also been noted in other gastrointestinal diseases such as gastroesophageal reflux disease (GERD) and inflammatory bowel disease. Genetic and environmental factors have been suggested to be responsible for the discrepancy. In GERD, for example, Asians reportedly have smaller parietal cell mass and lower acid output than Caucasians.<sup>6</sup> The higher prevalence of *Helicobacter pylori* infection in Asia may be an environmental factor protecting Asians from GERD.<sup>7</sup> The growing incidence of GERD in Asia may be attributable to increased intake of dietary fat.<sup>7</sup> Genetic and environmental differences between East and West may also explain the rarity of eosinophilic esophagitis in Asia. In particular, food allergies are a possible etiologic factor in eosinophilic esophagitis. Thus, dietary differences between Asia and the West may also be contributing factors. Further studies are needed to determine the underlying mechanisms.

The unusual feature of our patient was the lack of reflux or dyspeptic symptoms. Reports of Western cases indicate that patients with eosinophilic esophagitis usually present with nausea, vomiting, dysphagia, food impaction, epigastralgia, heart burn and chest pain. Due to chronic inflammation of the esophageal wall, eosinophilic esophagitis can also lead to esophageal stricture and esophageal motility disorders, which may contribute to reflux symptoms. In a study by Ronkainen et al, 4 cases in a random sample of 1,000 Swedish adults met the diagnostic criteria for eosinophilic esophagitis.<sup>5</sup> Three subjects presented with severe reflux symptoms and 1 was asymptomatic. Furthermore, increased epithelial eosinophils in the esophagus were also noted in 48 subjects, and half of the patients had no troublesome dyspeptic symptoms. The current case further confirms that a dense infiltration of esophageal eosinophils can occur without dyspeptic or reflux symptoms.

Eosinophilic esophagitis is treated by improving symptoms and completely resolving the mucosal inflammation to prevent subsequent esophageal dysfunction. Treatment modalities for eosinophilic esophagitis include dietary elimination and elemental diets, use of antihistamines (sodium cromoglycate), systemic and topical corticosteroids, humanized anti-interleukin-5 monoclonal antibody (Mepolizumab), leukotriene receptor modifier (Mepolizumab), as well as esophageal bougienage.<sup>8</sup> However, no evidence-based guidelines for managing eosinophilic esophagitis are currently available.<sup>9</sup> Whether asymptomatic eosinophilic esophagitis should be treated is an open question. Perhaps close observation with regular EGD follow-up is an

alternative strategy for this kind of patient; further investigation is warranted.

## References

1. Kelly KJ, Lazenby AJ, Rowe PC, Yardley JH, Perman JA, Sampson HA. Eosinophilic esophagitis attributed to gastroesophageal reflux: improvement with an amino acid-based formula. *Gastroenterology* 1995;109:1503–12.
2. Remedios M, Campbell C, Jones DM, Kerlin P. Eosinophilic esophagitis in adults: clinical, endoscopic, histologic findings, and response to treatment with fluticasone propionate. *Gastrointest Endosc* 2006;63:3–12.
3. Fox VL, Nurko S, Furuta GT. Eosinophilic esophagitis: it's not just kid's stuff. *Gastrointest Endosc* 2002;56:260–70.
4. Liacouras CA, Ruchelli E. Eosinophilic esophagitis. *Curr Opin Pediatr* 2004;16:560–6.
5. Ronkainen J, Talley NJ, Aro P, Storskrubb T, Johansson SE, Lind T, Bolling-Sternevald E, et al. Prevalence of oesophageal eosinophils and eosinophilic oesophagitis in adults: the population-based Kalixanda study. *Gut* 2007;56:615–20.
6. Fung WP. Gastric acid secretion in Chinese with particular reference to the dose of histamine required for maximal stimulation. *Gut* 1970;11:955–61.
7. Ho KY, Cheung TK, Wong BC. Gastroesophageal reflux disease in Asian countries: disorder of nature or nurture? *J Gastroenterol Hepatol* 2006;21:1362–5.
8. Garrett JK, Jameson SC, Thomson B, Collins MH, Wagoner LE, Freese DK, Beck LA, et al. Anti-interleukin-5 (mepolizumab) therapy for hypereosinophilic syndromes. *J Allergy Clin Immunol* 2004;113:115–9.
9. Richard N, Neelesh T. Eosinophilic esophagitis: a mimic of GERD. *Int J Pediatr Otorhinolaryngol* 2006;70:1147–53.