



Case report

Central-type primitive neuroectodermal tumor of the uterus: Case report of remission of stage IV disease using adjuvant cisplatin/etoposide/bevacizumab chemotherapy and review of the literature



Jorge Novo ^{a,*}, Pincas Bitterman ^a, Alfred Guirguis ^b

^a Rush University Medical Center, Department of Pathology, 1653 West Congress Parkway, 570 Jelke, Chicago, IL 60612, United States

^b Gynecologic Cancer Institute of Chicago, 5716 W 95th Street, Oak Lawn, IL 60453, United States

ARTICLE INFO

Article history:

Received 19 June 2015

Received in revised form 30 August 2015

Accepted 13 September 2015

Available online 16 September 2015

Keywords:

Primitive neuroectodermal tumor

Uterine neoplasm

Uterine PNET

Central-type PNET

cPNET

Bevacizumab

1. Introduction

Primitive neuroectodermal tumors (PNETs) are rare neoplasms that can occur in the female genital tract, among other visceral sites. The most common location within the female genital tract is the ovary, followed by the uterine corpus (Euscher et al., 2008), vagina, and cervix (Snijders-Keilhotz et al., 2005).

PNETs can present in pure form or admixed with other components, including endometrioid adenocarcinoma, adenosarcoma, carcinosarcoma (metaplastic carcinoma), and heterologous sarcomas (Nogales, 2003; Bartosch et al., 2011). When considering PNET as a diagnosis, the differential should include poorly-differentiated endometrioid carcinoma, non-keratinized squamous cell carcinoma, endometrial stromal sarcoma, lymphoma, small cell neuroendocrine carcinoma, and metastasis.

To date, over 58 cases of uterine PNETs have been published in the literature, the largest being a seventeen-patient case series by Euscher et al. (2008). While these cases share the same diagnosis, they vary in

their presentation, management, and outcomes (Table 1). We report an additional case of cPNETs of the uterine corpus, with this being the first case treated with surgical debulking and adjuvant cisplatin, etoposide and bevacizumab, with no evidence of disease recurrence forty-eight months following intervention.

2. Case report

A 26 year-old nulligravid, Hispanic female presented to an outside institution with dysfunctional uterine bleeding for four months. She was treated with oral contraceptives without resolution of her symptoms. A transvaginal ultrasound was performed, which showed an enlarged uterus with a $5.7 \times 7 \times 7$ cm homogenous mass located within the lower uterine segment, as well as an enlarged right ovary. An endometrial biopsy showed endometrial tissue with possible small cell neuroectodermal tumor. The patient was then referred to our institution where a repeat endometrial biopsy showed high-grade malignant tumor infiltrating cervical tissue, favoring PNETs. A computed tomography (CT) study demonstrated a large uterus measuring up to 8.2 cm in width with a 5.8×4.2 cm mass within the myometrium, a 4.1 cm cystic lesion in the right adnexa, ascites, a left-sided pleural effusion, and mildly enlarged para-aortic lymph nodes. Dilatation and curettage were performed, and pathologic examination revealed a high grade malignant tumor, favoring PNETs. The patient then underwent an exploratory laparotomy with radical tumor debulking, total abdominal hysterectomy with pelvic lymphadenectomy, bilateral salpingo-oophorectomy, omentectomy, and removal of tumor from the posterior cul-de-sac. Intra-operative findings were consistent with stage IV uterine cancer. Although the patient was optimally surgically debulked, there was still residual tumor measuring less than 1 cm at the conclusion of the procedure.

2.1. Pathology

On gross examination, the uterus contained an exophytic $7.1 \times 6.0 \times 2.6$ cm white-tan marbled mass with areas of hemorrhage and necrosis, occupying the entirety of the endometrial cavity, and infiltrating the full thickness of the myometrium (2.6 cm). In addition, the mass involved both right ($7.1 \times 5.5 \times 2.5$ cm) and left ovaries ($4.8 \times 2.6 \times 2.4$ cm), with extension from the fallopian tubes.

* Corresponding author.

E-mail address: Jorge_E_Novo@rush.edu (J. Novo).

Table 1
Clinical characteristics, surgical management, adjuvant chemotherapy, and follow-up of reported cases of uterine PNET.

Author	Age	Initial sign/symptom	FIGO stage	Surgery	Chemotherapy	Follow-up
Bartosch et al. (2011)	58	Vaginal bleeding, abdominal pain, weight loss	IV	TAH, BSO, segmental enterectomy, total colectomy, right PLND	Carboplatin Paclitaxel	Died, 11 months with sepsis from pyelonephritis
Celik et al.	32	Abdominal pain, pelvic mass	IIIA	TAH, BSO, PLND, PALND, omentectomy, appendectomy	Cisplatin Ifosfamide Adriamycin Vincristine (PIAV)	NED, 38 months
Bhardwaj et al.	50	Vaginal bleeding, pelvic mass	IIIC	TAH, BSO, omentectomy, PLND	Unknown chemotherapy regimen	NED, 6 months
Odunsi et al. (2004)	66	Vaginal bleeding	I	TAH, BSO, omentectomy, PLND, PALND	Not done	NED, 2 years
Odunsi et al. (2004)	65	Vaginal bleeding	IIIC	TAH, BSO, omentectomy, PLND, PALND, upper vaginectomy	Cisplatin Doxorubicin Etoposide Paclitaxel	Lung metastasis, 3 months AWD, 12 months
Karseladze et al.	16	Vaginal bleeding	I	TAH, BSO, omentectomy	Vincristine Cyclophosphamide Doxorubicin	NED, 4 years
Hendrickson and Scheithauer	12	Vaginal bleeding, pelvic mass	IVB	TAH, LSO	Cyclophosphamide Doxorubicin Vincristine	Pelvic recurrence, 12 months DOD, 2 years
Hendrickson and Scheithauer	57	Vaginal bleeding, uterine mass	IIB	TAH, BSO, PALND	Cisplatin Vinblastine Bleomycin	Lung metastasis, 5 months DOD, 2 years
Rose et al. Ward et al.	17	Vaginal bleeding, pelvic mass	IIIC	RH, PLND, bilateral ovarian wedge biopsy	Vincristine Cisplatin Doxorubicin Dactinomycin Cyclophosphamide Etoposide	NED, >10 years
Daya et al.	67	Vaginal bleeding, enlarged uterus	IIIC	SCH, BSO	Cisplatin Doxorubicin Carboplatin 5-FU	Persistent DOD, 6 months
Daya et al.	68	Vaginal bleeding, enlarged uterus	IVB	TAH, BSO, PLND	Cisplatin	Persistent DOD, 12 months
Daya et al.	69	Vaginal bleeding	I	TAH, BSO, PLND	Not done	NED, 6 years
Daya et al.	68	Vaginal bleeding	I	TAH, BSO	Not done	NED, 5 years
Molyneux et al.	72	Vaginal bleeding	I	TAH, BSO	Not done	DOD, 8 months
Fragetta et al.	78	Vaginal bleeding	IB	TAH, BSO, PLND	Not done	NED, 9 months
Sorenson et al.	62	Vaginal bleeding	I	TAH, BSO	Vincristine Cyclophosphamide Cisplatin	DOD, 18 months
Taieb et al.	36	Uterine enlargement	I	RH, BSO, PLND	Not done	NR
Ng et al.	48	Vaginal bleeding	IIIC	TAH, BSO	Not done	
Blattner et al. (2007)	26	Pelvic mass noted at cesarean section	III	RH, PLND, bilateral ovarian transposition	Vincristine Doxorubicin Cyclophosphamide Etoposide	NED, 16 months
Mittal et al. (2007)	24	Fever, abdominal pain, pelvic mass	II	TAH, BSO, omentectomy	Vincristine Doxorubicin Cyclophosphamide Ifosfamide Etoposide	Recurrence, 1 months
Akbayir et al.	22	Vaginal bleeding, adnexal mass	I	TAH, BSO, PLND, PALND, omentectomy	Cisplatin Doxorubicin	NED, 10 months
Peres et al.	15	Abdominal pain, fever, pelvic mass	I	TAH, PLND	Carboplatin Etoposide	NED, 12 months
Varghese et al. (2006)	43	Vaginal bleeding, uterine enlargement	IIIC	TAH, BSO, PLND	Cytosin Adriamycin Vincristine Etoposide	NED, 2 months
Park et al.	30	Vaginal bleeding, uterine enlargement	IVB	None	Vincristine Doxorubicin Ifosfamide Carboplatin Etoposide	DOD, 16 months
Shah et al. (2009)	59	Vaginal bleeding, pelvic mass	IIIC	TAH, BSO, PLND, PALND, omentectomy	Paclitaxel Carboplatin	AWD, 12 months
Majeed et al.	27	Vaginal bleeding, uterine mass	NR	TAH/BSO	Vincristine + Etoposide + Doxorubicin + Ifosfamide/ Vincristine +	NED, 2 years

(continued on next page)

Table 1 (continued)

Author	Age	Initial sign/symptom	FIGO stage	Surgery	Chemotherapy	Follow-up
Ren et al.	56	Vaginal bleeding	IB	TAH, BSO, PLND	Ifosfamide Ifosfamide Etoposide Cisplatin	NED, 41 months
Fukunaga et al.	54	Unknown	NR	TAH, BSO	Cyclophosphamide Cisplatin Doxorubicin 5-FU	AWD, 3 months
Venizelos et al.	68	Vaginal bleeding	I	TAH, BSO	Not done	NED, 10 months
Euscher et al. (2008)	58	Vaginal bleeding with palpable mass	IIIC	Unknown surgery	Not done	DOD, 2 months
Euscher et al. (2008)	31	Back pain from metastatic disease	IV	Not done	Unknown chemotherapy regimen	DOD, 20 months
Euscher et al. (2008)	72	Vaginal bleeding	IA	Unknown	Unknown	DOD, 11 months
Euscher et al. (2008)	48	Unknown	IIIC	Unknown	Unknown	Unknown
Euscher et al. (2008)	81	Vaginal bleeding	Unknown	Unknown	Unknown	Unknown
Euscher et al. (2008)	66	Pelvic mass	IIIC	Unknown surgery	Letrozole	NED, 41 months
Euscher et al. (2008)	53	Vaginal bleeding	Unknown	Unknown	Unknown	DOD, 22 months
Euscher et al. (2008)	51	Vaginal bleeding	Unknown	Unknown	Unknown	DOD, 12 months
Euscher et al. (2008)	31	Vaginal bleeding	Unknown	Unknown	Unknown	DOD, 26 months
Euscher et al. (2008)	64	Cervical polyp	IIB/ possible IIIC	TAH, BSO	Unknown chemotherapy regimen	NED, 36 months
Euscher et al. (2008)	64	Vaginal bleeding with pain	Unknown	Unknown	Unknown	Unknown
Euscher et al. (2008)	69	Vaginal bleeding	IV by imaging	Unknown	Unknown	Unknown
Euscher et al. (2008)	62	Uterine fibroids	IIIC	Unknown	Unknown	DOD, 22 months
Euscher et al. (2008)	55	Vaginal bleeding with fibroids	IB	TAH, BSO	Unknown chemotherapy regimen	NED, 38 months
Euscher et al. (2008)	52	Unknown	IV	Unknown	Unknown	NED, 6 months
Euscher et al. (2008)	58	Vaginal pressure with passage of tissue	IV	Not done	Unknown chemotherapy regimen	NED, 6 months
Euscher et al. (2008)	57	Unknown	IIIC	Not done	Unknown chemotherapy regimen	NED, 35 months
Stolnicu et al.	12	Vaginal bleeding with passage of tissue	Unknown	Not done	Etoposide, Bleomycin, Cisplatin	NED, 36 months
Vignali et al.	31	Vaginal bleeding, intermittent abdominal pain	IIIC	Unknown	Cisplatin, Etoposide	NED, 24 months
Cate et al.	25	Vaginal bleeding, uterine inversion and prolapse	Unknown	TAH	Not done	NED, 18 months
Dizon et al.	50	Abdominopelvic pain	Unknown	TAH, BSO, omentectomy,	Carboplatin, Etoposide	NED, 16 months
Shimada et al.	63	Constipation	Unknown	TAH, BSO	Cyclophosphamide, Vincristine, Adriamycin	NED, 24 months
Yi et al.	29	Abdominal swelling and pain	IVB	TAH, BSO, PALND, PLND, omentectomy	Neoadjuvant docetaxel and carboplatin. Vincristine, Adriamycin, Cyclophosphamide	AWD, 18 months Liver metastasis
Aminimoghaddam et al.	32	Vaginal bleeding, abdominal pain		TAH, BSO, PLND	Holoxan, Mesna, Cisplatin, Paclitaxol, Carboplatin	AWD, unknown
Current case	26	Vaginal bleeding, uterine mass	IV	TAH, BSO, omentectomy, PLND	Carboplatin Etoposide Avastin	NED, 48 months

TAH, total abdominal hysterectomy; LSO, left salpingo-oophorectomy; DOD, died of disease; BSO, bilateral salpingo-oophorectomy; PALND; pelvic and para-aortic lymph node dissection; RH, radical hysterectomy; PLND, pelvic lymph node dissection; NED, no evidence of disease; SCH, supracervical hysterectomy; AWD, alive with disease; NR, not recorded.

Hematoxylin and eosin microscopic examination showed a proliferation of sheets and nests of cells with round to oval hyperchromatic nuclei, finely granular chromatin, conspicuous multiple nucleoli, and scant cytoplasm. Homer-Wright rosettes and pseudo-rosettes were frequently observed (Fig. 1a). Widespread lymphovascular invasion was present, and mitotic figures were common (48/10 high power fields). Immunohistochemical stains demonstrated that the tumor cells were negative for CK 8/18, CK AE1/3, CD10, CD34, desmin, MSA, Myf-4, GFAP, chromogranin, neurofilament, CD99 and FLI1. Positive stains included vimentin, CD56, NSE, and synaptophysin (Fig. 1b–c). Antibodies against vascular endothelial growth factor (VEGF) (VG1 clone, Novus) showed positive cytoplasmic staining (Fig. 1d). In addition, CD34 and MSA highlighted a prominent network of endothelial cells within the sheets and nests of small hyperchromatic cells (Fig. 1e–f). Fluorescence in situ hybridization (FISH) analysis using a LSI EWSR1 dual color,

break-apart probe (Abbot Molecular) revealed no evidence of EWSR1 gene rearrangement.

2.2. Treatment

Following discussion of the patient's case at our institution's gynecologic oncology tumor board, the decision was made to treat the patient with six cycles of cisplatin and etoposide. Bevacizumab was added to the regimen for the second through sixth cycles given the finding of ascites. Response to treatment was followed with physical examination, serial CA-125 levels, and CT scans of the chest, abdomen and pelvis.

Baseline CA-125 was 372 U/mL. CA-125 levels obtained prior to administration of the second through sixth cycles were 189 U/mL, 31 U/mL, 22 U/mL, 15 U/mL, and 15 U/mL respectively. Three months

following the last cycle, the CA-125 level was 12 U/mL. Her most recent CA-125 was 10 U/mL, sixty-one months post-treatment.

A CT scan following the third cycle of cisplatin/etoposide/bevacizumab showed resolution of ascites and pleural effusion with mildly enlarged retroperitoneal lymph nodes. Three months after completion of chemotherapy, imaging showed stability of the retroperitoneal lymph nodes without evidence of disease. Her most recent scan, performed forty-eight months after completion of therapy, shows no evidence of recurrence.

2.3. Toxicity

The patient tolerated the chemotherapy with resultant Eastern Cooperative Oncology Group (ECOG) Grade 3 nausea and vomiting which required hospitalization three times for IV hydration and IV antiemetics. Because of ECOG Grade 3 neutropenia, she was given pegfilgrastim on day 3 of each subsequent cycle. Given the patient's response to the chemotherapy regimen of cisplatin/etoposide/bevacizumab in treating her stage IV endometrial primitive neuroectodermal tumor, the patient was

placed on surveillance. At sixty-two months following treatment, the patient is disease-free based on tumor markers, physical examination, and CT imaging studies.

3. Discussion

PNETs are small round cell tumors with glial, neural, and ependymal differentiation, thought to be derived from fetal neuroectodermal tissue (Hart & Earle, 1973). PNETs can be further classified based on degree of differentiation, location and genetic signatures into peripheral and central types. Peripheral-type PNET/Ewing sarcoma (pPNET/ES) is believed to originate from neural crest and occur outside of the central nervous system. Immunohistochemically, the great majority of pPNET/ES demonstrate CD99 and FLI1 positivity, and cytogenetics demonstrate the characteristic t(11;22)(q24;q12) translocation and *EWSR1/FLI1* gene fusion (Nogales, 2003; Varghese et al., 2006). cPNET/neuroblastoma are derived from the central neuraxis and involve central structures including the brain and spinal cord, and generally lack the *EWSR1* gene rearrangement (Hart & Earle, 1973). The majority of primary uterine

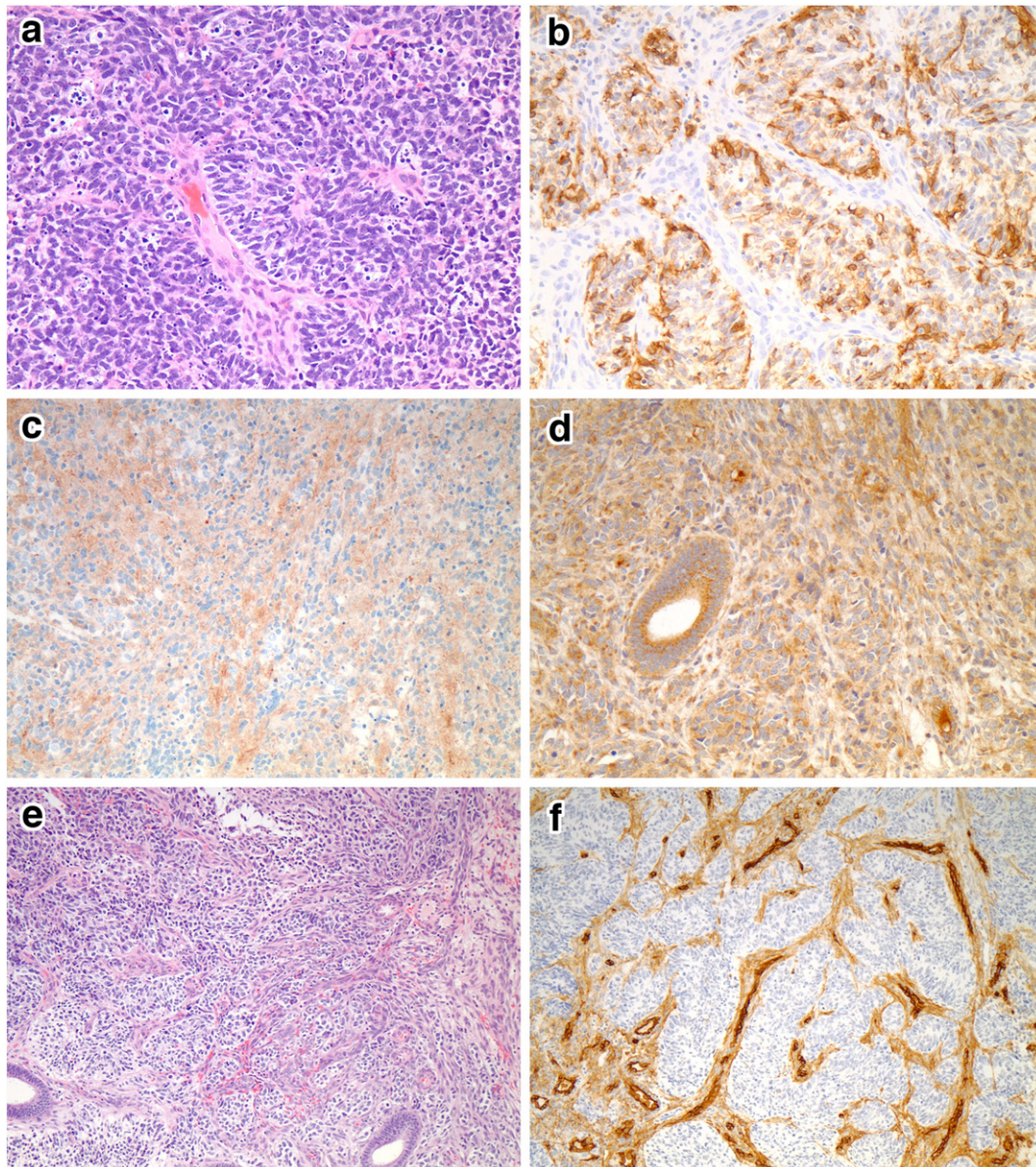


Fig. 1. The tumor was composed of small hyperchromatic cells with scant cytoplasm. Homer-Wright rosettes and pseudo-rosettes were present (a). The tumor cells were positive for CD56 (b), synaptophysin (c), and VEGF (d). A prominent vascular network was present (e), which is highlighted by CD34 (f).

PNETs lack the EWSR1 gene translocation, as in our case, and therefore resemble a cPNET.

Uterine PNETs are rare tumors that typically present in postmenopausal women although a minority present in the second decade, highlighting a bimodal age distribution. Abnormal uterine bleeding is the most common presenting symptom, and a uterine mass the most common finding on exam. Uterine PNETs are frequently diagnosed at an advanced stage, highlighting their aggressive nature. The two-year survival of younger patients and postmenopausal patients has been reported as 75% and 32%, respectively (Odunsi et al., 2004). Factors that portend a poor prognosis for the PNET family of tumors include metastatic disease at presentation (as confirmed by imaging, as well as cytologic and histologic examination of the bone marrow), primary extraosseous tumor, central or pelvic disease, age at diagnosis of 26 or older, tumor size greater than 8 cm, poor response to chemotherapy, absence of EWS-FLI1 fusion gene, and elevated pretreatment LDH (Mittal et al., 2007; Burchill, 2003).

There is no consensus regarding the optimal treatment of uterine PNETs. Patients treated with surgery and radiation have a relapse rate approaching 90% (Blattner et al., 2007). Multimodal therapy improves disease free survival, but the optimal chemotherapeutic regimen has not yet been demonstrated (Shah et al., 2009). Our patient underwent surgical management with optimal debulking as defined by measurable disease less than 1 cm followed by adjuvant chemotherapy alone. We chose to treat this patient with cisplatin and etoposide. Because the patient exhibited a large amount of ascites intraoperatively, as well as pleural effusion on post-operative imaging, the decision was made to add bevacizumab, a humanized monoclonal antibody directed against VEGF, to this regimen. VEGF has been implicated as a stimulator of vascular permeability, a contributing factor to malignant ascites (Mesiano et al., 1998). Because she did not exhibit any evidence of disease following chemotherapy, she did not receive post-operative radiation.

Due to the rare nature of uterine PNET and few case reports in the literature, it is difficult to determine the optimal course of treatment. Because cases of PNET are so rare, it is also problematic to accurately predict rates of survival or recurrence of this particular type of malignant neoplasm. To date there have been no case reports in the literature using the combination of cisplatin/etoposide/bevacizumab for adjuvant treatment of uterine PNET. Bevacizumab has been previously shown to be a potential therapeutic modality in vitro (Dalal et al., 2005), and a case series exploring its therapeutic value in the management of recurrent medulloblastoma have yielded objective response rates (Aguilera et al., 2013). Oberstein et al. reviewed three phase II clinical trials employing bevacizumab in the management of pancreatic neuroendocrine carcinomas, including PNET, showing a partial response rate ranging from 0 to 56% and mean progression-free survival ranging from 4.2 months to 23.7 months (Oberstein & Saif, 2012).

The presence of neoplastic endothelial proliferation and VEGF positivity within the tumor provides a rational explanation to the

effectiveness of this novel chemotherapy modality against uterine cPNET. This treatment option was tolerated by our patient with the side effects of Grade 3 nausea, which was supported with hospitalization and administration of IV fluids and antiemetics, and Grade 3 neutropenia, which was improved by the addition of pegfilgrastim and supportive care. Based on our patient's histopathologic and immunohistochemical features of this particular cPNET, and the favorable response to treatment using cisplatin/etoposide/bevacizumab, prospective clinical trials are required to evaluate the efficacy of this treatment schema in the management of advanced-stage uterine cPNET.

Conflict of interest statement

The authors declare no conflict of interest.

References

- Euscher, E.D., Deavers, M.T., Lopez-Terrada, D., Lazar, A.J., Silva, E.G., Malpica, A., Feb 2008. Uterine tumors with neuroectodermal differentiation: a series of 17 cases and review of the literature. *Am. J. Surg. Pathol.* 32 (2), 219–228.
- Snijders-Keilholz, A., Ewing, P., et al., 2005. Primitive neuroectodermal tumor of the cervix: a case report — changing concepts in therapy. *Gynecol. Oncol.* 98 (3), 516–519.
- Nogales, F.T.F., 2003. Sex cord-like, neuroectodermal and neuroendocrine tumours, lymphomas and leukemias. In: DP, T.G.A. (Ed.), *Pathology and Genetics of Tumours of the Breast and Female Genital Organs: WHO Classification of Tumours*. IARC Press, Lyon, pp. 255–256.
- Bartosch, C., Vieira, J., Teixeira, M.R., Lopes, J.M., 2011. Endometrial endometrioid adenocarcinoma associated with primitive neuroectodermal tumour of the uterus: a poor prognostic subtype of uterine tumours. *Med. Oncol.* (May 29, 2010. e-pub).
- Hart, M.N., Earle, K.M., Oct 1973. Primitive neuroectodermal tumors of the brain in children. *Cancer* 32 (4), 890–897.
- Varghese, L., Arnesen, M., Boente, M., Oct 2006. Primitive neuroectodermal tumor of the uterus: a case report and review of literature. *Int. J. Gynecol. Pathol.* 25 (4), 373–377.
- Odunsi, K., Olatinwo, M., Collins, Y., Withiam-Leitch, M., Lele, S., Spiegel, G.W., Feb 2004. Primary primitive neuroectodermal tumor of the uterus: a report of two cases and review of the literature. *Gynecol. Oncol.* 92 (2), 689–696.
- Mittal, S., Sumana, G., Gupta, M., Gupta, B., Mar–Apr 2007. Primitive neuroectodermal tumor of the uterus: a case report. *Int. J. Gynecol. Cancer* 17 (2), 524–527.
- Burchill, S.A., Feb 2003. Ewing's sarcoma: diagnostic, prognostic, and therapeutic implications of molecular abnormalities. *J. Clin. Pathol.* 56 (2), 96–102.
- Blattner, J.M., Gable, P., Quigley, M.M., McHale, M.T., Aug 2007. Primitive neuroectodermal tumor of the uterus. *Gynecol. Oncol.* 106 (2), 419–422.
- Shah, J.P., Jelsema, J., Bryant, C.S., Ali-Fehmi, R., Malone Jr., J.M., Feb 2009. Carboplatin and paclitaxel adjuvant chemotherapy in primitive neuroectodermal tumor of the uterine corpus. *Am. J. Obstet. Gynecol.* 200 (2), e6–e9.
- Mesiano, S., Ferrara, N., Jaffe, R.B., Oct 1998. Role of vascular endothelial growth factor in ovarian cancer: inhibition of ascites formation by immunoneutralization. *Am. J. Pathol.* 153 (4), 1249–1256.
- Dalal, S., Berry, A.M., Cullinane, C.J., et al., 2005. Vascular endothelial growth factor: a therapeutic target for tumors of the Ewing's sarcoma family. *Clin. Cancer Res.* 11 (6), 2364–2378.
- Aguilera, D., Mazewski, C., Fangusaro, J., et al., 2013. Response to bevacizumab, irinotecan, and temozolomide in children with relapsed medulloblastoma: a multi-institutional experience. *Childs Nerv. Syst.* 29 (4), 589–596.
- Oberstein, P.E., Saif, M.W., 2012. Update on novel therapies for pancreatic neuroendocrine tumors. *JOP* 13 (4), 372–375 <http://www.ncbi.nlm.nih.gov/pubmed/22797392>.