

CASE REPORT

Acute Urinary Retention as the Presentation of Imperforate Hymen

Jei-Wen Chang¹, Ling-Yu Yang^{1*}, Hsin-Hui Wang¹, Jen-Kai Wang², Chui-Mei Tiu³

¹Department of Pediatrics, Taipei Veterans General Hospital, and Institute of Clinical Medicine, National Yang Ming University School of Medicine, ²Department of Pediatrics, Taipei Medical University Hospital, and ³Section of Pediatric Radiology, Taipei Veterans General Hospital, and National Yang-Ming University, Taiwan, R.O.C.

Acute urinary retention is unusual in children and is usually a candidate for visiting the emergency department upon initial discovery. We report a 12-year-old girl who complained of acute urinary retention. Ultrasonography demonstrated a large echogenic mass over the vagina and mild dilation of the uterus. Imperforate hymen associated with hematocolpos and hematometrium was diagnosed. Cruciate hymenotomy was performed. The symptoms resolved after treatment. Adolescent girls who complain of urinary symptoms with no previous menstruation should have their external genitalia examined in order to rule out the possibility of imperforate hymen as the cause of acute urinary retention. [*J Chin Med Assoc* 2007;70(12):559–561]

Key Words: acute urinary retention, imperforate hymen

Introduction

Acute urinary retention (AUR), meaning the inability to pass urine, is an uncommon diagnosis encountered in childhood. The etiology of AUR is age-dependent. The causes of AUR in childhood may be psychogenic, drug-induced with antihistamines or anticholinergic drugs, or related to viral infections, congenital anomalies, neurologic bladders or mechanical compression of the urethra via the mass of pelvis.^{1,2} We report the case of an adolescent girl who complained of AUR due to imperforate hymen.

Case Report

A 12-year-old girl visited the pediatric accident and emergency department of Taipei Veterans General Hospital because she was unable to pass urine for 12 hours, complaining of lower abdominal discomfort. Her medical history was unremarkable. She denied a past history of frequency, dysuria, constipation, and fever. She had not been taking any medications recently, including antihistamines and anticholinergic drugs. No menstruation was noted. She had had monthly lower

abdominal pain for the past 3–4 months. Physical examination showed a pelvic mass extending to the suprapubic region with tenderness. No dimpling or hair over the lumbosacral region was noted. Neurologic examinations were normal. A pelvic examination was not performed in the emergency department. Urethral catheterization was administered for relief of the symptoms. A total of 900 mL of clear urine was drained. Urinalysis was normal. Ultrasonography showed significant echogenic fluid accumulation in the vagina measuring about 10.3 × 6.9 cm in size (Figure 1), mild dilation of the uterus, no hydronephrosis, and no abnormalities of the ureter and bladder.

Subsequent examination of the external genitalia revealed imperforate hymen. Cruciate hymenotomy was performed. The symptoms resolved after treatment and she was discharged later on the same day.

Discussion

The hymen is an embryologic remnant of mesodermal tissue. Failure to perforate during embryonic development results in accumulation of successive menstruation in the vagina and uterus during puberty.

*Correspondence to: Dr Ling-Yu Yang, Department of Pediatrics, Taipei Veterans General Hospital, 201, Section 2, Shih-Pai Road, Taipei 112, Taiwan, R.O.C.

E-mail: ly_yang@vghtpe.gov.tw • Received: May 18, 2007 • Accepted: September 4, 2007

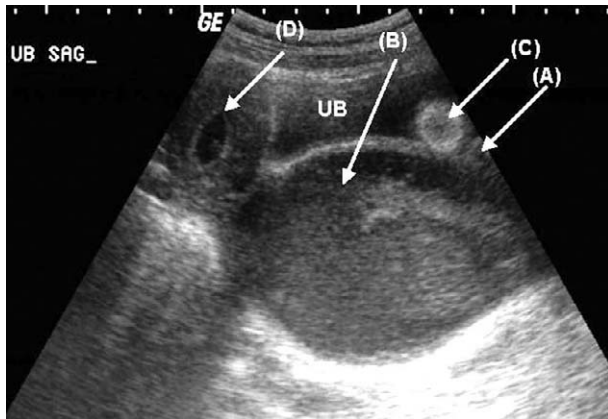


Figure 1. Longitudinal sonogram shows the urethra (A) compressed by hematocolpos (B). The Foley balloon (C) is in place of the urinary bladder (UB). The uterine cavity (D) is filled with fluid, representing hematometra.

Imperforate hymen is usually a congenital anomaly, but has been reported as a result of sexual abuse.³ The incidence of imperforate hymen is estimated to be 0.1%.⁴ Although imperforate hymen usually occurs sporadically, some familial occurrences have been reported. The mode of transmission is thought to be autosomal recessive or autosomal dominant.⁵ An imperforate hymen is almost always an isolated finding, but it may also occur with McKusick–Kaufman syndrome or Bardet–Biedl syndrome.⁶ Other possible associated anomalies include polydactyly, congenital anorectal abnormalities and multicystic dysplastic kidneys. In addition, urinary tract abnormalities have been reported.

The presenting clinical features vary with age at diagnosis. Imperforate hymen has been diagnosed with prenatal ultrasound documented by bladder outlet obstruction due to hydrocolpos or mucocolpos. During the neonatal period, imperforate hymen may present with fetal ascites or acute renal failure.^{7,8} The hematocolpos or hydrocolpos may lead to variable degrees of hydroureter, hydronephrosis and nephronia.⁹ The clinical symptoms of teenagers include cyclic lower abdominal pain, primary amenorrhea, chronic constipation, low back pain, dysuria, and AUR.^{10,11} AUR is unusual in children, and many conditions are associated with it. AUR may result from inadequate bladder contraction due to inflammation, be drug-induced, or as a result of dyssynergia between detrusor contraction and sphincter relaxation in a neurologic bladder. Extrinsic compression of the urethra by an ovarian tumor, vaginal mass or rhabdomyosarcoma of the urinary bladder may also cause AUR in young females. The incidence of patients with imperforate hymen presenting with AUR varies, ranging

from 3% to 46%.^{12,13} The mechanisms of imperforate hymen causing AUR may be due to the retained hematoma in the vagina compressing the urethra or causing irritation of the sacral plexus. In addition, the mechanical effect of the hematoma in the vagina may alter the angle between the bladder neck and urethra, resulting in urinary outflow obstruction. The conservative nature of the local culture in Taiwan makes most doctors reluctant to perform routine genital examinations. Urinary retention is always treated by catheterization. It is convenient and easy to observe the hymen at the time of catheterization. A bulge along the posterior aspect of the introitus is typical. A high index of suspicion makes early diagnosis easier and prevents inappropriate laboratory work or imaging studies.

The classical treatment of imperforate hymen is via surgical hymenectomy. Bleeding, scarring and stenosis of the vaginal orifice are the major complications of this procedure. Less invasive techniques are available including use of carbon dioxide lasers¹⁴ or application of Foley catheters¹⁵ without damaging the structure of the hymen. The optimal timing of operation is based on symptoms. Asymptomatic children diagnosed without mucocele can be treated during puberty before the development of hematocolpos or hematometra to reduce the risk of general anesthesia. The long-term outcome is good. Endometriosis and infertility are the most prominent late complications.

Teenagers with AUR usually visit the emergency department first. Imperforate hymen should be considered in adolescent girls who complain of urinary symptoms with no previous menstruation. Inspection of the external genitalia, along with catheterization and detailed history-taking, including regarding menstruation, can aid in preventing misdiagnosis and commencing with additional appropriate diagnostic examinations.

References

- Gatti JM, Perez-Brayfield M, Kirsch AJ, Smith EA, Massad HC, Broecker BH. Acute urinary retention in children. *J Urol* 2001;165:918–21.
- Peter JR, Steinhardt GF. Acute urinary retention in children. *Pediatr Emerg Care* 1993;9:205–7.
- Peterson-Sweeney KL, Stevens J. 13-year-old female with imperforate hymen. *Nurse Pract* 1996;2:90–4.
- Attaran M, Falcone T, Gidwani G. Obstructive Mullerian anomalies. In: Gidwani G, Falcone T, eds. *Congenital Malformation of the Female Genital Tract: Diagnosis and Management*. Philadelphia: Lippincott Williams & Wilkins, 1999: 145–68.
- Stelling JR, Gray MR, Davis AJ, Cowan JM, Reindollar RH. Dominant transmission of imperforate hymen. *Fertil Steril* 2000;74:1241–4.

6. David A, Bitoun P, Lacombe D, Lambert JC, Nivelon A, Vigneron J, Alain V. Hydrometrocolpos and polydactyly: a common neonatal presentation of Bardet-Biedl and McKusick-Kaufman syndromes. *Med Genet* 1999;36:599-603.
7. Jacquemyn Y, De Catte L, Vaerenberg M. Fetal ascites associated with an imperforate hymen: sonographic observation. *Ultrasound Obstet Gynecol* 1998;12:67-9.
8. Aygun C, Ozkaya O, Ayyıldız S, Gungor O, Mutlu B, Kucukoduk S. An unusual cause of acute renal failure in a newborn: hydrometrocolpos. *Pediatr Nephrol* 2006;21:572-3.
9. Shen MC, Yang LY. Imperforate hymen complicated with pyocolpos and lobar nephronia. *J Chin Med Assoc* 2006;69:224-7.
10. Shen CC, Hsu TY, Huang FJ, Chang HY, Chang SY. Ectrodactyly ectodermal dysplasia-clefting syndrome with hematocolpometra presenting as acute urinary retention. *Acta Obstet Gynecol Scand* 2002;81:894-5.
11. Posner JC, Spandorfer PR. Early detection of imperforate hymen prevents morbidity from delays in diagnosis. *Pediatrics* 2005;115:1008-12.
12. Tompkins P. The treatment of imperforate hymen with hematocolpos: a review of 113 cases in the literature and the report of five additional cases. *JAMA* 1939;113:913.
13. Calvin JK, Nichamin SJ. Hematocolpos due to imperforate hymen. *Am J Dis Child* 1936;51:832-46.
14. Friedman M, Gac D, Peretz B. Management of imperforate hymen with the carbon dioxide laser. *Obstet Gynecol* 1989;74:270-2.
15. Ali A, Cetin C, Nedim C, Kazim G, Cemalettin A. Treatment of imperforate hymen by application of Foley catheter. *Eur J Obstet Gynecol Reprod Biol* 2003;106:3-4.