



Alexandria University Faculty of Medicine
Alexandria Journal of Medicine

<http://www.elsevier.com/locate/ajme>



Clinicopathological review of surgically removed appendix in Central Nigeria



Babatunde M. Duduyemi ^{*,1}

Department of Pathology, Kwame Nkrumah University of Science & Technology, Kumasi, Ghana

Received 8 June 2014; accepted 14 August 2014

Available online 17 September 2014

KEYWORDS

Acute abdomen;
 Appendix;
 Appendectomy;
 Histology

Abstract *Background:* Acute appendicitis is a disease of the young presenting in children and early adolescents although no age group is exempt. It is the most common cause of acute surgical abdomen worldwide. This clinicopathological study aims to determine the various lesions of the surgically removed appendix in our centre and if any, changing trend in this lesion in our environment.

Method: A retrospective study was undertaken to review the histopathology reports of all appendectomy specimens submitted to the Department of Pathology of the Asokoro District Hospital, Abuja; Nigeria from November 2009 to October 2012. Patient's biodata, clinical signs and symptoms were extracted from the request form.

Result: A total of 293 appendices were received during the 3-year study period constituting about 10% of total specimens. The male to female ratio was 1:1.3 with a mean age of 26.33 ± 11.39 years. Acute appendicitis was found in 81.2% of our cases while other lesions constitute 14.7% and negative appendectomy occurred in 4.1% of the cases. No mortality was recorded.

Conclusion: The findings in this study compared favourably with those of our environment and in the developed world although acute appendicitis in this study showed slight female preponderance.

© 2014 Alexandria University Faculty of Medicine. Production and hosting by Elsevier B.V. All rights reserved.

1. Introduction

The diagnosis of acute appendicitis is most commonly a clinical one; many patients present with a typical history and examination findings. The cause of acute appendicitis is unknown but is probably multifactorial; luminal obstruction and dietary

and familial factors have all been suggested.^{1–3} Appendectomy is the treatment of choice and is increasingly done as a laparoscopic procedure.² Acute appendicitis is a disease of the young presenting in children and early adolescents although no age group is exempt. It is the most common cause of acute surgical abdomen worldwide and its incidence varies with geographical location.³

In the United States, a crude estimate of the incidence of acute appendicitis is 11 cases per 10,000 population.⁴ Studies have shown acute appendicitis to be more common in the whites than non whites.⁵ Appendicitis is the most common abdominal emergency and accounts for more than 40,000 hospital admissions in England every year.⁶

* Tel.: +233 541705871.

E-mail address: babsdudu@yahoo.com.

¹ Formerly of: Department of Pathology, Asokoro District Hospital, Abuja, Nigeria.

Peer review under responsibility of Alexandria University Faculty of Medicine.

In Nigeria, incidence of acute appendicitis is relatively low with varying reports of average annual frequencies ranging from 22.1 to 49.8 new cases but in other African countries, annual frequencies are relatively higher ranging from 22.9 to 129 new cases per 100,000 persons.^{7–12} Clinicopathological studies of appendiceal lesions on the African continent are relatively few and this study was conducted to determine the various lesions of surgically removed appendix in our centre and compare our findings with other studies elsewhere.

2. Materials and methods

A retrospective study was undertaken to review the histopathology reports of all appendectomy specimens submitted at the Department of Pathology of the Asokoro District Hospital, Abuja; the capital city of Nigeria from November 2009 to November 2012. The number of cases/year for the 3 years was 93, 95 and 105, respectively. Our laboratory is a referral centre for 12 other government district hospitals and private hospitals in the Federal Capital Territory and its environs. The Federal Capital Territory is an urban community with a population of 1,405,201 people (2006 census). Patient's biodata, clinical signs and symptoms were extracted from the laboratory request form. Routine haematoxylin and eosin (H&E) staining and where necessary histochemical studies were carried out. Alcian blue/Periodic Acid Schiff stain was done for a case of suspected mucocoele. The data were analysed in terms of frequency, age and sex distribution, nature of clinical signs and symptoms as well as histological characteristics of pathologic lesions (normal, acute appendicitis with or without peritonitis, lymphoid hyperplasia, eosinophilic appendicitis and schistosomal appendicitis) using the SPSS version 17. The data for these patients were presented in tables and figures.

3. Result

A total of 293 appendices were received in our laboratory during the 3-year study period constituting about 10% of total specimens. The annual incidence is 8.4 per 100,000 population. There were 128 males and 165 females constituting a male to female ratio of 1:1.3. The age range of patients in this study is 3–57 years with a mean of 26.33 ± 11.39 years.

3.1. Age and sex distribution

The age and sex distribution of the patients is shown in Table 1. The peak age of occurrence in this study is 20–29 years closely followed by 10–19 year age group both constituting over 60%

Table 1 Distribution of cases according to age groups and sex.

Age group (years)	Male	Female	Subtotal	% Age
0–9	7	4	11	3.8
10–19	21	62	83	28.3
20–29	40	54	94	32.1
30–39	34	27	61	20.8
40–49	19	12	31	10.6
50–59	7	6	13	4.4
Total	128	165	293	100

of the cases. The least number of cases (13 patients) were seen in the age group 50–59 years constituting 4.4%.

3.2. Clinical presentation

The most common form of presentation by our patients was right iliac abdominal pain (95%) which later became generalised in 21.8% of cases. The other symptoms include fever (81%), vomiting (56%), and loss of appetite (48%). The mean duration of symptoms was 3.05 days.

Twelve patients had perforation at surgery and 2 out of these presented primarily in shock.

3.3. Histological diagnosis

The distribution of histological diagnosis is as shown in Table 2. Twelve cases (4.1%) were found to be normal. Uncomplicated acute appendicitis was seen in 174 patients constituting 59.4% and acute appendicitis with peritonitis constitutes 21.8%. Submucosal fibrosis, schistosomiasis, lymphoid hyperplasia and subacute appendicitis constitute 5.1%, 2.4%, 3.4% and 1.7%, respectively. Others include eosinophilic appendicitis (0.7%) and mucocoele was seen in one patient (0.3%). The histology of acute appendicitis, acute appendicitis with lymphoid hyperplasia and schistosomal appendicitis is shown in Figs. 1–3. Table 3 shows the distribution of the histological diagnosis according to age groups. Acute appendicitis with peritonitis (Fig. 2) occurs more in males than females with a ratio of approximately 2:1. The peak age of occurrence is 20–29 years, constituting 31.3% and closely followed by age groups 10–19 years and 30–39 years constituting 23.9% each. The distribution of patients with histological diagnosis of acute appendicitis and acute appendicitis with peritonitis is shown in Tables 4 and 5, respectively. Acute appendicitis occurs more in females (63.8%) than males (36.2%) while acute appendicitis with peritonitis occurs more in males (65.7%) than females (34.3%). The peak age of occurrence for both is the 3rd decade of life.

4. Discussion

Acute appendicitis is a very common disease and appendix is a common specimen received in the histopathology laboratory worldwide. The incidence varies widely from region to region with higher incidence among the whites than blacks.

Table 2 Distribution of cases according to histological diagnosis.

Histological diagnosis	No of cases	% Age
Acute appendicitis	174	59.4
Lymphoid hyperplasia	10	3.4
Eosinophilic appendicitis	2	0.7
Subacute appendicitis	5	1.7
Normal	12	4.1
Mucocoele	1	0.3
Appendicitis with peritonitis	67	22.8
Submucosal fibrosis	15	5.1
Schistosomiasis	7	2.4
Total	293	100

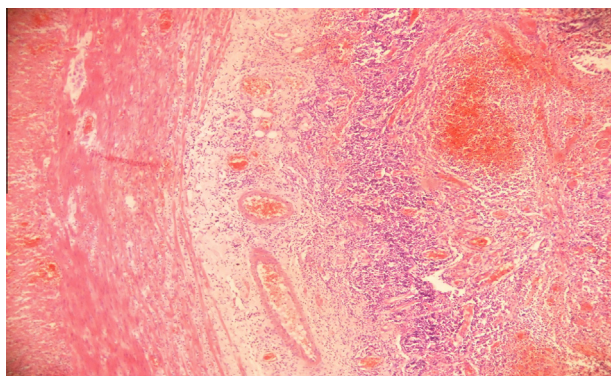


Figure 1 This is a section of the appendix showing transmural infiltration by acute inflammatory cells and dilated and congested vessels (H&E $\times 200$).

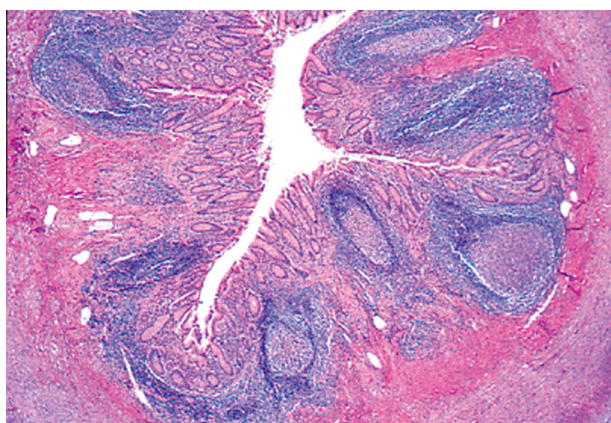


Figure 2 This is a section of the appendix showing lymphoid nodules within the lamina propria that also extend into the submucosa (H&E $\times 40$).

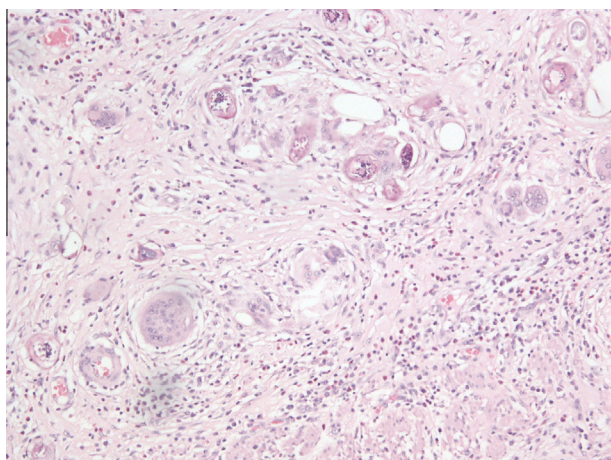


Figure 3 Section of appendix showing schistosomal appendicitis (H&E $\times 100$).

Appendix is one of the most common specimens received in our laboratory during the study period. This is exemplified by the fact that it constituted about 10% of the total histological specimens received in our hospital during the 3 year period. The

annual incidence in our study is 8.4 per 100,000 which is about twice that reported in suburban population of Sagamu, Southwest, Nigeria.¹³ The incidence of acute appendicitis is increasing in our community probably due to urbanisation as Abuja is the capital of Nigeria which is occupied by the affluent in the society. The diet is westernised and consists of low fibre. It is believed that high fibre diet which increases the bowel motion reduces the incidence of acute appendicitis. Therefore in regions (Africa, Southeast Asia) where high fibre diet is the staple food, the incidence of acute appendicitis is less.¹⁴

The male to female ratio of 1:1.3 in this study compares favourably with the studies by Ali et al.¹⁵ in Maiduguri and Blair et al.¹⁶ in Canada where the male to female ratio was 1:1.2 but contrasts most reports within and outside the country in which males predominate.^{7,8,13}

The peak age of occurrence in our centre is the 3rd decade of life. Most of the reports showed peak age of occurrence in the 2nd and 3rd decades of life. Our finding compares with that of Fashina et al.¹⁷ in Lagos, Alatisse et al.¹⁸ in Ile-Ife while Ohene-Yeboah et al.¹⁰ in Ghana and Ali et al.¹⁵ in Maiduguri, Nigeria reported peak age in the 4th decade of life. Some studies especially in the developed world reported peak age in the 2nd decade of life.^{19,20} Humes and Simpson² in a clinical review of acute appendicitis in England reported peak age incidence of occurrence as 10–20 years and male to female ratio of 1.4:1 although they acknowledged variations in incidence across geographical zones as no age is exempt from acute appendicitis. The frequency of occurrence of acute appendicitis decreases with increasing age. This is similar to most studies from within and outside our country.^{8–10,19}

The diagnosis of acute appendicitis is mainly through history and physical examination. The findings in this study concur well with what was obtained in other studies. The mean duration of symptoms in our study was 3.05 days which compares favourably with other reports locally and internationally.^{9,10} Thirty-six patients (12.1%) had perforation at surgery and 2 of these presented in shock. This is probably due to late presentation at the emergency room. Fear of surgical operation and relatively high cost of treatment are the main reasons for late presentation in our environment.¹³ The 2 patients who presented in shock were adequately resuscitated and had appendectomy. The average hospital stay post operation was 6.5 days with a range of 5–14 days. This is comparable with other studies.^{9,10} No mortality was recorded in the patients studied.

This study showed a wide range of histological diagnosis. The negative appendectomy rate of 4.1% is low compared with most studies reviewed which reported a range of 8.6–35.8%.^{8,9,17,21–23} This low rate may not be unconnected with the growing clinical acumen of our surgeons coupled with radiological investigations. The abdominal pains in these patients were mainly due to pelvic inflammatory diseases and urinary tract infection.

Acute appendicitis constituted 82.3% in this study which is comparable with the study of Abudu et al.¹³ in Sagamu, Nigeria. Ojo et al.⁸ and Abdulkareem et al.⁹ reported slightly lower rates of 69.9% and 70.3%, respectively. Most studies from outside Nigeria reported a range of 45.7–82.5% which compared favourably with this study.^{10,20}

Lymphoid hyperplasia constituted 3.4% which compares with the study conducted in the UK by Singhal and Jadhav, 2007 and contrasts that of Abdulkareem (Lagos, Nigeria)

Table 3 Distribution of the histological diagnosis according to age.

Histological diagnosis	0–9	10–19	20–29	30–39	40–49	50–59	Total
Normal	–	3	6	2	1	–	12
Acute appendicitis	7	51	56	38	14	8	174
Acute app. + peritonitis	3	16	21	16	9	2	67
Lymphoid hyperplasia	–	3	4	2	1	–	10
Submucosal fibrosis	–	6	2	3	2	2	15
Eosinophilic appendicitis	–	–	1	–	1	–	2
Subacute appendicitis	1	1	2	–	–	1	5
Schistosomiasis	–	3	2	–	2	–	7
Mucocoele	–	–	–	–	1	–	1
Total	11	83	94	61	31	13	293

Table 4 Age and sex distribution of patients with histological diagnosis of acute appendicitis.

Age groups (years)	Male	Female	Subtotal	Percentage
0–9	5	2	7	4.0
10–19	10	41	51	29.3
20–29	16	40	56	32.2
30–39	20	18	38	21.8
40–49	7	7	14	8.1
50–59	5	3	8	4.6
Total	63	111	174	100.0

Table 5 Age and sex distribution of patients with histological diagnosis of acute appendicitis with peritonitis.

Age groups (years)	Male	Female	Subtotal	Percentage
0–9	2	1	3	4.5
10–19	10	6	16	23.9
20–29	15	6	21	31.3
30–39	9	7	16	23.9
40–49	7	2	9	13.4
50–59	1	1	2	3.0
Total	44	23	67	100.0

and Al-Fujairah (United Arab Emirates) which reported higher frequency of 19% and 25%, respectively. About 70% of these patients are in the 2nd and 3rd decades of life which compares with most studies. The presence of reactive lymphoid hyperplasia in appendix in varying degrees lends credence to the theory that obstruction of the lumen by lymphoid tissue aggregation is important in the pathogenesis of acute appendicitis especially in the 2nd and 3rd decades of life.

Submucosal fibrosis was seen in 5.1% of the cases with peak age in the 2nd decade of life. This compares with the finding of Andreou et al.²⁴ that fibrosis and faecoliths were more common in the older individuals at autopsy than in the younger surgically resected group. Submucosal fibrosis is characterised by deposition of fibrous tissue in the submucosa due to repeated acute or chronic inflammation which does not resolve completely in most cases. This fibrous tissue deposition causes narrowing and obstruction of the lumen and sometimes superimposed infection with resultant acute appendicitis. Submucosal fibrosis could also be seen in conjunction with an infective aetiology or following interval appendicectomy.^{8,25–27}

Schistosomal appendicitis constituted 2.4% of the total patients studied. All these cases were associated with varying degrees of fibrosis in the submucosa. This lends credence to the fact that schistosomal appendicitis is associated with inflammation, repair, deposition of fibro-connective tissue and subsequent obliteration of the appendiceal lumen which will result in the typical presentation of acute abdomen.^{16,27}

The cases of subacute appendicitis seen in this study were from patients who had interval appendicectomy. These patients also had varying degrees of submucosal fibrosis.²⁷

5. Conclusion

The finding in our study compared favourably with those of our environment and in the developed world although we found a slight female preponderance. The incidence in our environment is increasing especially in a very urban area like our study has shown. Acute appendicitis is one of the most common surgical emergencies in our environment therefore prompt and adequate intervention will go a long way in reducing its morbidity and mortality.

Conflict of interest

None declared.

References

- Daniel J, Montgomery E. Inflammatory disorders of the appendix. In: Odze RD, Goldblum JR, editors. *Surgical pathology of the GI tract, liver, biliary tract and pancreas*. 2nd ed. Saunders Elsevier Inc.; 2009. p. 395–408.
- Humes DJ, Simpson J. Acute appendicitis. *BMJ* 2006;**333**:530–4.
- Pieper R, Kager L, Tidefeldt U. Obstruction of appendix vermiformis causing acute appendicitis. An experimental study in the rabbit. *Acta Chir Scand* 1982;**148**(1):63–72.
- Bao PM. Presence or absence of gas in the appendix: additional criteria to rule out or confirm acute appendicitis—evaluation with ultrasound. *Radiology* 2000;**217**:599–600.
- Graffeo CS, Counselman FL. Appendicitis in textbook of GI emergencies, part II. *Emerg Med Clin North Am* 1996;**14**.
- Hospital episode statistics: primary diagnosis summary. Available from: www.hesonline.nhs.uk/Ease/servlet/ContentServer?siteID=sta:summary. = 1937&categoryID=202 accessed 28 Aug 2006.
- Oguntola AS, Adeoti ML, Oyemolade TA. Appendicitis: trend in incidence, age, sex and seasonal variations in South Western Nigeria. *Ann Afr Med* 2010;**9**(4):213–7.

8. Ojo OS, Udeh SC, Odesanmi WO. Review of the histopathological findings in removed appendices for acute appendicitis in Nigerians. *J R Coll Surg Edinb* 1991;**36**(4):245–8.
9. Abdulkareem FB, Awelimobor DI. Surgical pathology of the appendix in a tropical teaching Hospital. *Niger Med Pract* 2009;**55**(3):32–6.
10. Ohene-Yeboah M, Togbe B. An audit of appendicitis and appendectomy in Kumasi, Ghana. *West Afr J Med* 2006;**25**(2):138–43.
11. Edino ST, Mohammed AZ, Ochicha O, Anumah M. Appendicitis in Kano, Nigeria: a 5 year review of pattern, morbidity and mortality. *Ann Afr Med J* 2004;**3**(1):38–41.
12. Chavda SK, Hassan S, Magoha GA. Appendicitis at Kenyatta National Hospital, Nairobi. *East Afr Med J* 2005;**82**(10):526–30.
13. Abudu EK, Oyebadeyo TY, Tade AO, Awolola NA. Surgical pathologic review of appendectomy at a sub urban tropical tertiary hospital in Africa. *J Med Med Sci* 2011;**2**(6):932–8.
14. Black J. Acute appendicitis in Japanese soldiers in Burma: support for the “fibre” theory. *Gut* 2002;**51**(2):297.
15. Ali N, Aliyu S. Appendicitis and its surgical management experience at the University of Maiduguri Teaching Hospital Nigeria. *Niger J Med* 2012;**21**(2):223–6.
16. Blair P, Bugis SP, Turner SJ, MacLeod MM. Review of the pathologic diagnoses of 2216 appendectomy specimen. *Am J Surg* 1993;**165**(5):618–20.
17. Fashina IB, Adesanya AA, Atoyebi OA, Osinowo OO, Atimomo CJ. Acute appendicitis in Lagos: a review of 250 cases. *Niger Postgrad Med J* 2009;**16**(4):268–73.
18. Alatise OI, Ogunweide T. Acute appendicitis: incidence and management in Nigeria. *IFEMED J* 2008;**14**(1):66–70.
19. Addiss DG, Shaffer N, Fowler BS, Tauxe RV. The epidemiology of appendicitis and appendectomy in the United States. *Am J Epidemiol* 1990;**132**:910–25.
20. Al-Omran M, Mamdani M, McLeod RS. Epidemiologic features of acute appendicitis in Ontario, Canada. *Can J Surg* 2003;**46**(4):263–8.
21. Muthuphei MN, Morwamoche P. The surgical pathology of the appendix in South African blacks. *Cent Afr J Med* 1998;**44**(1):9–11.
22. Chamisa I. A clinicopathological review of 324 appendices removed for acute appendicitis in Durban, South Africa: a retrospective analysis. *Ann R Coll Surg Engl* 2009;**91**(8):688–92.
23. Madiba TE, Haffejee AA, Mbete DL, Chaithram H, John J. Appendicitis among African patients at King Edward VIII Hospital, Durban, South Africa: a review. *East Afr Med J* 1998;**75**(2):81–4.
24. Andreou P, Blain S, Du Boulay CE. A histopathological study of the appendix at autopsy and after surgical resection. *Histopathology* 1990;**17**(5):427–31.
25. Meshikhes AW, Chandrashekar CJ, Al-Daolah Q, Al-Saif O, Al-Joaib AS, Al-Habib SS, et al. Schistosomal appendicitis in the Eastern Province of Saudi Arabia: a clinicopathological study. *Ann Saudi Med* 1999;**19**(1):12–4.
26. Lamps LW. Appendicitis and infections of the appendix. *Semin Diagn Pathol* 2004;**21**(2):86–7.
27. Guo G, Greenson JK. Histopathology of interval (delayed) appendectomy specimens: strong association with granulomatous and xanthogranulomatous appendicitis. *Am J Surg Pathol* 2003;**27**(8):1147–51.