



Available online at
ScienceDirect
www.sciencedirect.com

Elsevier Masson France
EM|consulte
www.em-consulte.com/en



REVIEW

All you need to know about the tricuspid valve: Tricuspid valve imaging and tricuspid regurgitation analysis



Tout ce que vous avez toujours voulu savoir sur la valve tricuspide : intérêts de l'imagerie multi-modalités dans l'analyse de la valve et de la fuite tricuspide

Olivier Huttin^a, Damien Voilliot^a, Damien Mandry^b,
Clément Venner^a, Yves Juillière^a,
Christine Selton-Suty^{a,*}

^a Department of Cardiology, University Hospital of Nancy-Brabois, Institut lorrain du Cœur et des Vaisseaux, 54511 Nancy, France

^b Department of Radiology, University Hospital of Nancy-Brabois, Institut lorrain du Cœur et des Vaisseaux, 54511 Nancy, France

Received 1st July 2015; received in revised form 24 August 2015; accepted 27 August 2015

KEYWORDS

Tricuspid valve;
Tricuspid valve
insufficiency;
Echocardiography;
Cardiac imaging;
Heart valve surgery

Summary The acknowledgment of tricuspid regurgitation (TR) as a stand-alone and progressive entity, worsening the prognosis of patients whatever its aetiology, has led to renewed interest in the tricuspid-right ventricular complex. The tricuspid valve (TV) is a complex, dynamic and changing structure. As the TV is not easy to analyse, three-dimensional imaging, cardiac magnetic resonance imaging and computed tomography scans may add to two-dimensional transthoracic and transoesophageal echocardiographic data in the analysis of TR. Not only the severity of TR, but also its mechanisms, the mode of leaflet coaptation, the degree of tricuspid annulus enlargement and tenting, and the haemodynamic consequences for right atrial and right ventricular morphology and function have to be taken into account. TR is functional and is a satellite of left-sided heart disease and/or elevated pulmonary artery pressure

Abbreviations: 2D, two-dimensional; 3D, three-dimensional; CMR, cardiac magnetic resonance; CT, computed tomography; FTR, functional tricuspid regurgitation; PAP, pulmonary artery pressure; PISA, proximal isovelocity surface area; RA, right atrium/atrial; RV, right ventricle/ventricular; TA, tricuspid annulus; TOE, transoesophageal echocardiography; TR, tricuspid regurgitation; TTE, transthoracic echocardiography; TV, tricuspid valve.

* Corresponding author.

E-mail address: c.suty-selton@chu-nancy.fr (C. Selton-Suty).

<http://dx.doi.org/10.1016/j.acvd.2015.08.007>

1875-2136/© 2015 Elsevier Masson SAS. All rights reserved.

most of the time; a particular form is characterized by TR worsening after left-sided valve surgery, which has been shown to impair patient prognosis. A better description of TV anatomy and function by multimodality imaging should help with the appropriate selection of patients who will benefit from either surgical TV repair/replacement or a percutaneous procedure for TR, especially among patients who are to undergo or have undergone primary left-sided valvular surgery.

© 2015 Elsevier Masson SAS. All rights reserved.

MOTS CLÉS

Valve tricuspide ;
Insuffisance
tricuspide ;
Échocardiographie ;
Imagerie cardiaque ;
Chirurgie valvulaire

Résumé Il est maintenant bien admis que l'insuffisance tricuspide (IT) significative est une entité propre qui aggrave le pronostic des patients, quelle que soit son étiologie, et ceci a conduit à un regain d'intérêt pour l'ensemble valve tricuspide-ventricule droit. La valve tricuspide est une structure complexe, dynamique avec une grande variabilité interindividuelle. Les différentes techniques d'imagerie moderne telles que l'échographie tridimensionnelle, l'imagerie par résonance magnétique et le scanner peuvent être utilisés en complément de l'imagerie bidimensionnelle classique pour analyser l'IT. Il est important d'analyser non seulement le degré de sévérité de l'IT, mais aussi les mécanismes à son origine, le mode de coaptation des feuillets valvulaires, le degré d'élargissement de l'anneau tricuspide et l'importance de la traction sur les feuillets valvulaires, ainsi que le retentissement hémodynamique sur l'oreillette et le ventricule droit. L'IT est dans la majorité des cas fonctionnelle et satellite d'une pathologie du cœur gauche et/ou d'une élévation des pressions pulmonaires. L'IT qui persiste et se majore dans les suites d'une chirurgie valvulaire du cœur gauche est une forme particulière à ne pas méconnaître car elle pose des problèmes de prise en charge et aggrave le pronostic des patients. Une description détaillée de l'anatomie et de la fonction de la valve tricuspide et de l'ensemble du cœur droit par l'imagerie multi-modalités devrait permettre d'affiner les critères de sélection des patients chez qui une correction de l'IT doit être envisagée, particulièrement parmi les patients candidats à une chirurgie du cœur gauche. De plus, ces éléments doivent entrer en ligne de compte dans le choix de la modalité thérapeutique optimale, à savoir réparation, remplacement valvulaire ou traitement par voie percutanée.

© 2015 Elsevier Masson SAS. Tous droits réservés.

Background

The differences in anatomy and function between the mitral valve and the tricuspid valve (TV) have been recognized since the anatomical descriptions of the heart by William Harvey in 1628. Tricuspid regurgitation (TR) was first described by T.W. King in 1837, who showed that distension of the right ventricle (RV) with water induced considerable TV reflux. The authors thought that the TV, being weak, could act as a safety valve for the RV, and concluded that "the TV is designed to be(come) incompetent" [1]. This statement was accepted as true, and for a long time the TV and TR were neglected while surgical techniques for treating left heart valvular diseases evolved. Unfortunately, TR turned out not to be as benign and physiological as had been thought. Some patients with progressive TR developed intractable right ventricular (RV) failure, especially those who had been operated on earlier for left heart valve diseases without concomitant TV surgery. These findings led to a renewed interest in the TV and, more globally, in the right heart valvular-ventricular complex. Multimodality imaging helped to better describe the morphology and function of the TV, and to fully assess the cause and impact of TR. This

issue of TR is clinically important because it may presage a poor prognosis, and because surgical management of TR is far less codified than for left heart valves, and has poorer results and frustrating failures. This review will focus on the multimodality imaging of the normal TV, and on the pathophysiology, mechanisms and analysis of TR.

Anatomy

The TV is a complex entity of thin fibrous tissue, with three leaflets, chordae tendineae, papillary muscles and a fibrous annulus located between the right atrium (RA) and the RV [2–4]. The normal area of the TV is 7–9 cm², making it the largest of the four cardiac valves.

Tricuspid valve leaflets

The TV is nearly vertical and is oriented at approximately 45° to the sagittal plane, so that the margins of the valve are anterosuperior, inferior and septal [5]. The three leaflets are the anterior, septal and posterior leaflets, which are thin and membranous, with commissures that appear more like

indentations than true commissures. The anterior leaflet is the largest, with a semi-circular shape, and stretches from the infundibulum anteriorly to the inferolateral wall posteriorly. The posterior leaflet differs because of the presence of multiple scallops; it attaches along the posterior margin of the tricuspid annulus (TA) from the septum to the inferolateral wall. The septal leaflet is the smallest, and arises medially, directly from the annulus above the inter-ventricular septum. The septal leaflet is characteristically inserted ≤ 10 mm more apically than the septal insertion of the anterior mitral valve leaflet.

Tricuspid subvalvular apparatus

The TV apparatus is similar to the mitral valve, but has greater variability. The tricuspid subvalvular apparatus consists of anterior, posterior and septal papillary muscles, and their true chordae tendineae. Each leaflet has chordal attachments to one or more papillary muscles. The anterior papillary muscle, the most prominent, provides chordae to the anterior and posterior leaflets, and the medial papillary muscle provides chordae to the posterior and septal leaflets. The anterior papillary muscle may have attachments to the moderator band. The posterior papillary muscle is smaller, and is missing in 20% of healthy subjects [6]. The septal wall gives chordae directly to the anterior and septal leaflets, without a specific septal papillary muscle. In addition, there may be accessory chordal attachments to the RV free wall and to the moderator band. These multiple chordal attachments are important mediators of TR, as they impair proper leaflet coaptation in the setting of RV dysfunction and adverse remodelling.

Tricuspid annulus

The TV leaflets are attached to a fibrous annulus that is not as easy to define as it is around the mitral valve, although it remains identifiable [7]. The septal leaflet, the least mobile of the three leaflets, has more support from the fibrous trigone than other leaflets. The normal TA is ovoid, and appears approximately one third longer in the mediolateral than in the anteroposterior direction [8]. Furthermore, the TA is non-planar, with an elliptical saddle shape. The posteroseptal portion (close to the coronary sinus) and the anterolateral segments are the closest to the apex and the anteroseptal (close to the RV outflow tract and the aortic valve) and posterolateral segments are the closest to the RA, with a high-low distance of around 7 mm [9]. The mean maximal TA circumference and area in healthy subjects are 12 ± 1 cm and 11 ± 2 cm², respectively. The TA diameter varies according to the site of measurement, with reference values varying between 25 and 39 mm [8,9]. From a dynamic point of view, the TA shows variability during the cardiac cycle, with an approximately 20% reduction in annular circumference with atrial systole [10]. In pathological situations, as the septal leaflet is fixed between the fibrous trigones, the TA can only lengthen and dilate along the attachment of the anterior and posterior leaflets, resulting in a more circular shape; furthermore, it then becomes more planar with decreased high-low distance (< 4 mm) [8,9,11,12].

Echocardiographic imaging of the tricuspid valve complex

Assessment of the TV using transthoracic echocardiography (TTE) is challenging because of its unfavourable retrosternal position, the high variability of the TV anatomy and the difficulty in simultaneously visualizing all three leaflets in standard two-dimensional (2D) views; hence, all existing echocardiographic TV leaflet identification schemes are only partially correct. The use of an en-face view obtained by 2D TTE or, more easily, by transoesophageal echocardiography (TOE) and three-dimensional (3D) imaging is therefore recommended [13,14].

Tricuspid valve morphology

TV morphology can be evaluated by 2D TTE from the standard parasternal and apical RV views: RV inflow, parasternal short-axis, apical four-chamber and subcostal views (Fig. 1). It is important to use all available views in 2D, colour and Doppler modes to obtain a complete evaluation of the valve by 2D TTE, and to rule out and not underestimate a flail leaflet or a localized abnormality. TOE helps to image the TV in multiple views and planes, although the incremental value of TOE is usually less for the TV than for the mitral valve. The deeper gastric view in a longitudinal plane (transgastric RV inflow view) often provides a nice long-axis visualization of the TV and the subvalvular apparatus. An en-face view is also quite easily obtained from the gastric approach (Fig. 2).

Finally, 3D imaging is used mostly in TTE, from either the parasternal or the apical approach, with real-time zoom mode or after acquisition of a full-volume data set; this allows the display of the TV surgical view and visualization of all the components of the TV, enabling assessment of their dynamic spatial relationships and anatomical continuity [14–16] (Fig. 3). In patients with good echogenicity, assessment of TV anatomy and function with 3D TTE is often feasible, even if it is more difficult and requires more experience compared with mitral valve 3D evaluation [14]. 3D TTE has the potential advantage of evaluating complex TV anatomy in organic TR, as may be encountered in Ebstein's anomaly, carcinoid heart disease and TV prolapse [17–19]. Recently, several publications have highlighted the usefulness of 3D TTE for detecting the location of the lead and its relationship to valvular leaflets and significant TR in patients with intracardiac devices [20–22]. 3D TTE also enables us to locate the anatomical regurgitant orifice of TR and to measure the vena contracta, which was found to be more often ellipsoid than circular [23]. Finally, the extent of TV tethering may be quantified with 3D echocardiography, in terms of the tenting volume and tenting angle of the three leaflets [24,25].

Tricuspid annulus

TA size and function play pivotal roles in the genesis of TR, and accurate analysis of the TA is required to determine the need for a combined procedure on the TV in patients undergoing cardiac surgery for left-sided valve diseases. However,

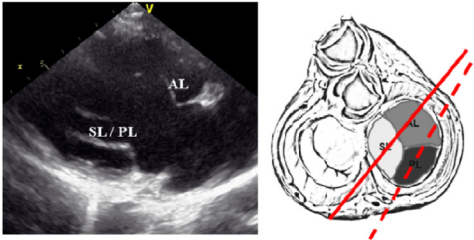
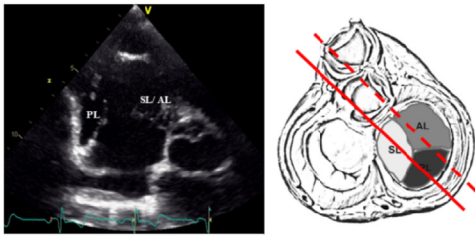
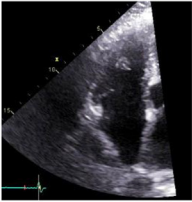

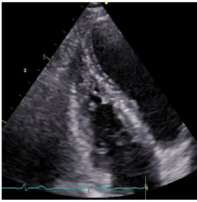
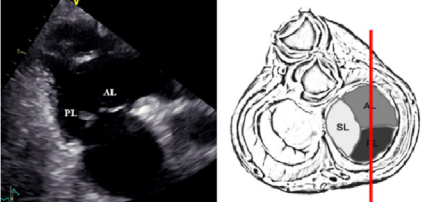
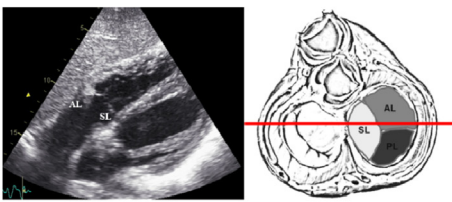
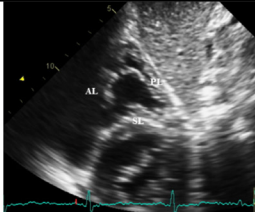
2D TRANSTHORACIC ECHOCARDIOGRAPHY		
PARASTERNAL LONG AXIS VIEW OF THE RV INFLOW 		PARASTERNAL SHORT AXIS VIEW AT THE AORTIC LEVEL 
<ul style="list-style-type: none"> - obtained from the parasternal long axis view by tilting the probe downwards - displays the anterior leaflet and either the septal or posterior leaflet (tilt vertically the probe 15° or more from the initial position) 		<ul style="list-style-type: none"> - displays the posterior leaflet and either (more often) the septal leaflet attached near the RCA trajet or the anterior leaflet
RV FOCUSED (MEDIAL) APICAL 4 CHAMBER VIEW 	APICAL 4 CHAMBER VIEW 	RV MODIFIED (LATERAL) APICAL 4 CHAMBER VIEW 
<ul style="list-style-type: none"> - obtained from the apical 4C view by tilting the probe to the right toward the sternum 	<ul style="list-style-type: none"> - displays anterior and septal leaflet - recommended view for TA diameter measure 	<ul style="list-style-type: none"> -obtained from the apical 4C view by moving the transducer laterally
APICAL 2 CHAMBER VIEW FOCUSED ON THE RV 		RV SUBCOSTAL 4 CHAMBER VIEW 
<ul style="list-style-type: none"> - obtained by rotating the probe 90° counter-clockwise from the 4C view centered on RV - displays posterior and anterior leaflets 		<ul style="list-style-type: none"> - displays anterior and septal leaflets
RV SUBCOSTAL EN FACE VIEW 		RV SUBCOSTAL SHORT AXIS VIEW <p style="text-align: center;">Error! Reference source not found.</p>
<ul style="list-style-type: none"> - obtained by rotating the probe 90° counter-clockwise from the subcostal 4C view centered on RV - displays the 3 leaflets in an en face view 		<ul style="list-style-type: none"> - displays posterior and septal/anterior leaflets - interesting for the measurement of dilated TA

Figure 1. Two-dimensional transthoracic imaging of the tricuspid valve. RV: right ventricle; TV: tricuspid valve; AL: anterior leaflet; PL: posterior leaflet; SL: septal leaflet.

normative data about TA diameter and function are limited, and are still a matter of debate.

As for the description of TV morphological details, 2D TTE has some limitations in the quantification of the TA diameter [26,27]. In fact, the 2D view and the timing during the cardiac cycle of when the TA should be measured

remain controversial [10]. If 2D TTE is the only assessment tool available, the apical four-chamber view seems to be preferred, because of better interobserver agreement compared with other views [28], and it is the method recommended by current guidelines for making a decision about TV repair [29,30]. In this view, the normal TA diameter

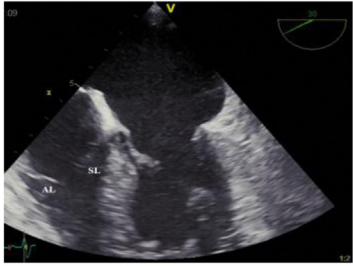
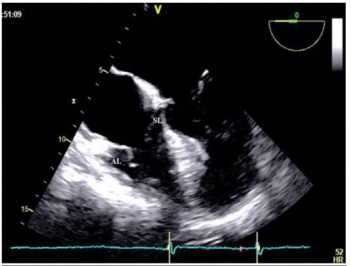
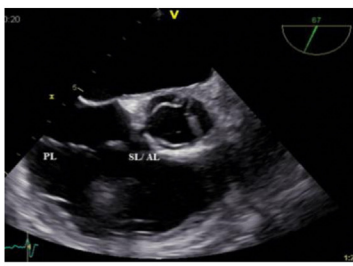
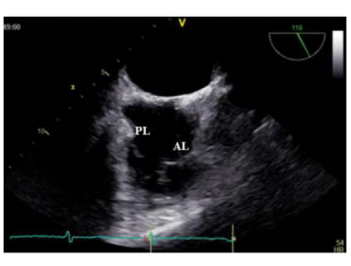
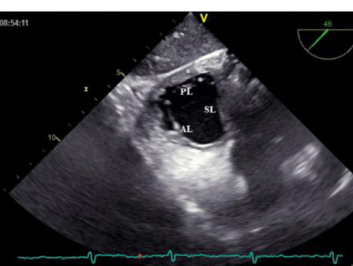
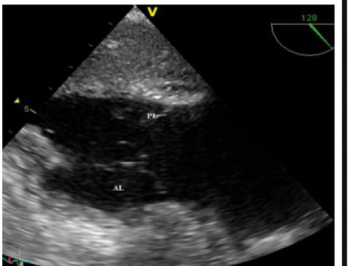
2D TRANSESOPHAGEAL ECHOCARDIOGRAPHY	
MID-ESOPHAGEAL 4 CHAMBER (0- 30°)  <ul style="list-style-type: none"> -probe is turned to the right until the TV is seen - displays anterior and septal leaflets - recommended view for TA diameter measure 	RV-FOCUSED MID-ESOPHAGEAL 4 CHAMBER (0- 30°)  <ul style="list-style-type: none"> - Flex right the transducer to place the right ventricle in the center of the image - displays anterior and septal leaflets
MID-ESOPHAGEAL RV INFLOW-OUTFLOW VIEW (60-90°)  <ul style="list-style-type: none"> -multiplane angle is then rotated forward to 60-90° to develop the aortic short axis view - displays posterior and either anterior (more frequently) or septal leaflets 	LOW-ESOPHAGEAL RV VIEW (90- 150°)  <ul style="list-style-type: none"> -obtained from the bicaval view by pushing slightly the probe - displays anterior and posterior leaflets
TRANSGASTRIC RV BASAL SHORT AXIS (0°-30°)  <ul style="list-style-type: none"> - probe is slightly withdrawn toward the base of the heart until the TV is in the center and multiplane angle is rotated to around 30° - displays en face view with the 3 TV leaflets 	TRANSGASTRIC RV INFLOW (100-120°)  <ul style="list-style-type: none"> - multiplane angle is rotated to 100° until the apex of the RV appears on the left - displays posterior and anterior leaflets - provides the best images of the subvalvular apparatus

Figure 2. Two-dimensional transoesophageal imaging of the tricuspid valve (TV). RV: right ventricle; TV: tricuspid valve; AL: anterior leaflet; PL: posterior leaflet; SL: septal leaflet.

in adults is 28 ± 5 mm, measured in diastole. The TA can also be measured from the mid-oesophageal four-chamber view in 2D TOE (Fig. 4).

To assess cyclic changes in TA diameter during systole and diastole, TA fractional shortening may be calculated from the apical four-chamber view between the insertion sites of the septal and anterior TV leaflets at end-diastolic and end-systolic times; the normal value is around 25% [28].

The analysis of TA geometry and size with the use of 3D echocardiography shows interesting results and has good feasibility [8,9,11,29,31–34] (Fig. 4). Various measurements are reported, including major and minor TA diameters, TA fractional shortening, TA area and TA fractional area change. TA diameter is usually underestimated by 2D TTE compared with 3D TTE, and it seems necessary to re-establish normal TA values with 3D imaging. Furthermore, more complicated analysis of the non-planarity of TA can also be performed from 3D acquisitions, which have potentially important mechanistic and therapeutic implications for TV repair [8,11].

Value of other imaging modalities in the assessment of the tricuspid valve

Electrocardiograph-gated computed tomography (CT) scans and cardiac magnetic resonance (CMR) imaging are interesting adjuncts in the evaluation of the TV.

Computed tomography scans

The dynamic data set acquired in patients who undergo CT scans can be used to assess RV function. The thin slice thickness facilitates increased accuracy of RV delineation, and allows for precise recognition of the valvular borders. For the TV, only static anatomical information is relevant [35]. Measurements of TA diameter and assessment of lack of coaptation of leaflets are generally simple on good-quality four-chamber cardiac CT images (Fig. 5). Evaluation of TV prolapse is easier on coronal views. In functional TR (FTR), CT scans have been used to measure right atrial (RA) and

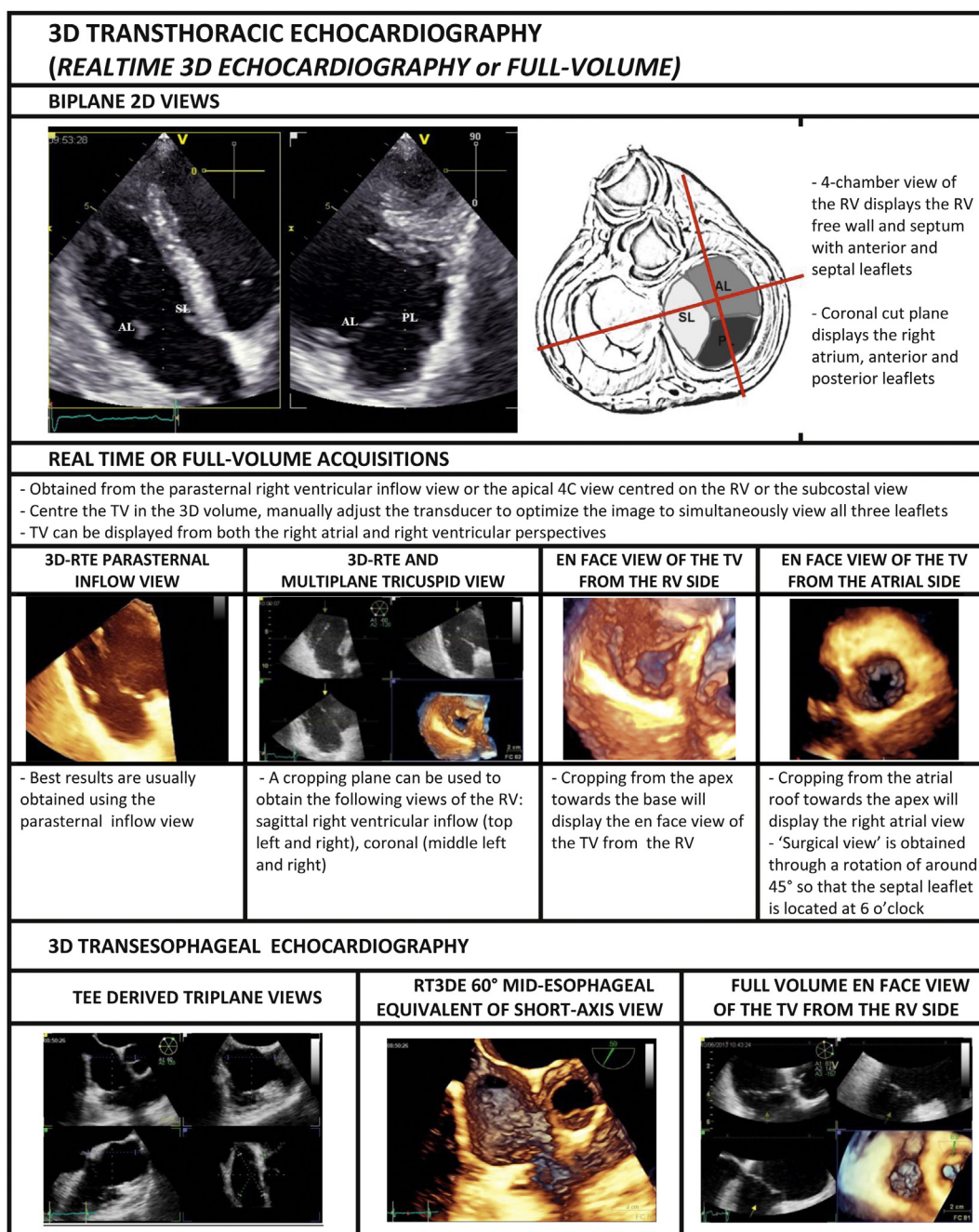


Figure 3. Three-dimensional (3D) imaging of the tricuspid valve (TV). RV: right ventricle; TV: tricuspid valve; AL: anterior leaflet; PL: posterior leaflet; SL: septal leaflet; RT3DE: real-time 3D echocardiography.

RV volumes, TA diameters and areas, the distance between each commissure, the tethering angle of each leaflet and the tethering height, with these various indexes having interesting prognostic value [36,37]. Some other potential benefits of CT scans are the detection of valvular calcifications, the evaluation of TV annuloplasty ring dislodgement and the assessment of the spatial relationship between RV pacemaker leads and related TR [35].

Cardiac magnetic resonance imaging

With its ability to image in any plane, CMR can provide detailed characterization of all valvular structures [38,39].

Most morphological and functional information is obtained using cine CMR sequences, particularly steady-state free precession sequences. In addition to echocardiography, CMR is the technique of choice for evaluating tricuspid abnormality [40]. As for CT scans, 2D measurements of annulus diameter, tethering height and lack of coaptation of leaflets with direct planimetry of the valvular orifice area are feasible using the different sequences focused on the RV (Fig. 5). A semiautomatic algorithm based on cine CMR images and 3D reconstruction can help to assess TA morphology and motion and to better depict its ellipsoid saddle shape [41]. TA dynamics have, in this way, been shown to be minimal in the anteroseptal region and maximal in the posterior region

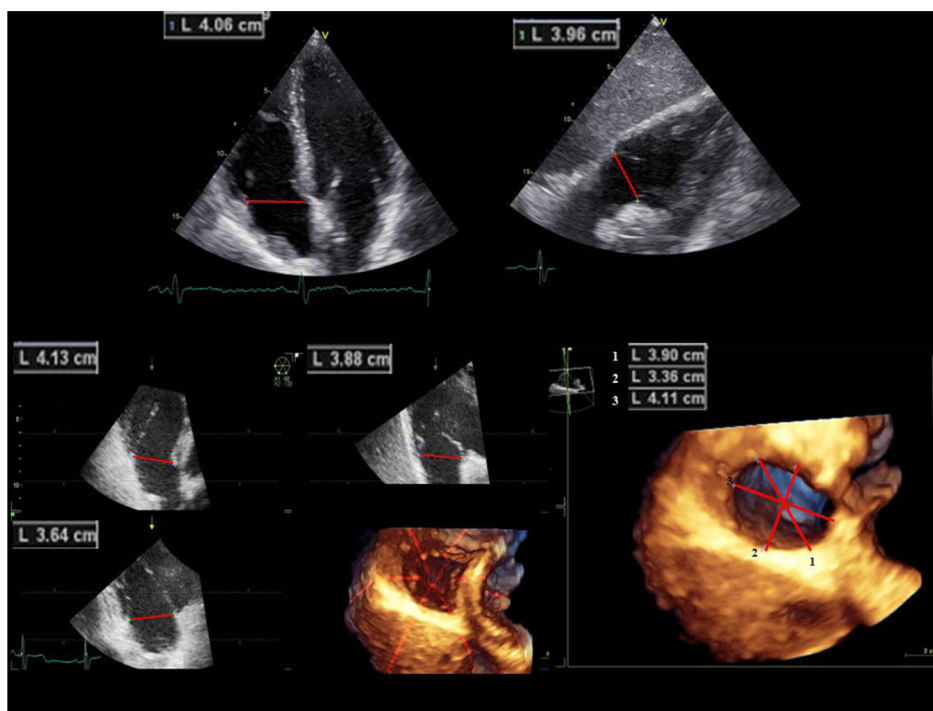


Figure 4. Tricuspid annulus (TA) diameter assessment by two-dimensional (2D) and three-dimensional (3D) transthoracic echocardiography. (Top) 2D apical four-chamber and subcostal long-axis view with end-diastolic TA measurement. (Bottom left) Volume rendering of the TA shown from the right ventricular perspective. The “laser lines” superimposed on the 3D echocardiography rendering indicate the orientation of the corresponding depicted image in the longitudinal 2D views of the tricuspid valve. (Bottom right) Measurements of diameters from the end-diastolic 3D frame of the TA.

[42]. Finally, CMR is currently the gold standard for the assessment of RV morphology and function, and is therefore of great interest in the field of TR.

Tricuspid regurgitation

TV function depends on interactions between the TA, valvular leaflets, papillary muscles, chords, the RA and the RV. Any congenital or acquired abnormality affecting one of these structures leads to TR.

Epidemiology

Mild physiological TR is very frequent and well known by echocardiographers who, by applying the simplified Bernoulli formula, use its maximal velocity to estimate systolic pulmonary artery pressure (PAP) [43]. Depending on the series, physiological TR is reported to be present in 60–90% of people who undergo echocardiography, and its incidence increases with age. TR is mostly trivial or mild. In the Framingham study, the prevalence of mild or greater TR by colour Doppler was 15% in men and 18% in women [44]. In a large database of more than 60,000 echocardiograms, TR was reported to be severe in only 1.2% of patients [45]. It is estimated that moderate-to-severe TR affects approximately 1.6 million patients in the USA [7].

Aetiologies and mechanisms

As for the mitral valve, the aetiology of TR is divided into organic TR (TV pathology) and FTR (secondary to other

cardiac pathology). Some authors also individualize idiopathic TR (normal TV and no aetiology identified for TR) [46]. In a series of 768 cases of severe TR, organic TR and FTR represented 11% and 80% of the cases, respectively, and idiopathic TR accounted for 9%, with these patients being older and having a higher frequency of AF than the others [45]. Carpentier’s classification based on the amplitude of valvular displacement (normal for type 1, excessive for type 2 and restrictive for type 3) can also be applied to describe the mechanisms of TR (Table 1).

Pathophysiology

TR is responsible for progressive RA dilatation, increased pulsatility and dilatation of the inferior vena cava and hepatic veins, coronary sinus dilatation and septal shift towards the left atrium. Whatever the initial mechanism, TR also leads to RV volume overload and increased RV diastolic pressure, septal shift towards the left ventricle and increasing RV dilatation, with displacement of papillary muscles and leaflet tethering, decreased amplitude of leaflet motion and valvular tenting further impairing valvular coaptation. This vicious circle progressively increases TR and decreases cardiac output, leading to final RV failure. In addition, atrial fibrillation, which often complicates all these pathologies, leads to a further annular dilation (Fig. 6).

Symptoms

In advanced stages of TR, there is the progressive appearance of venous dilation, with signs of right-sided heart

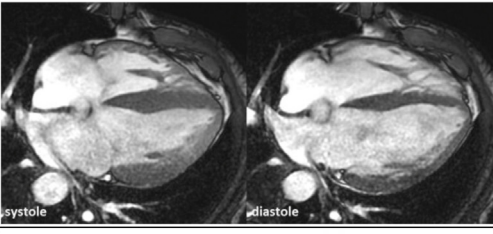
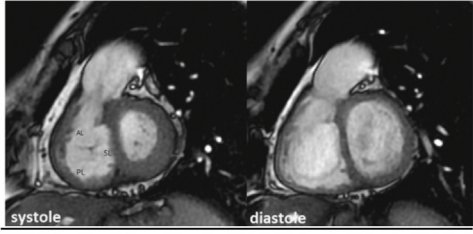
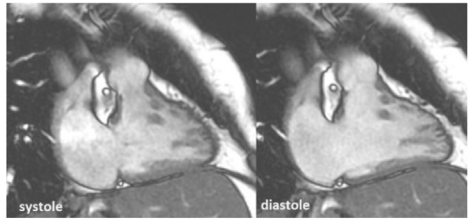
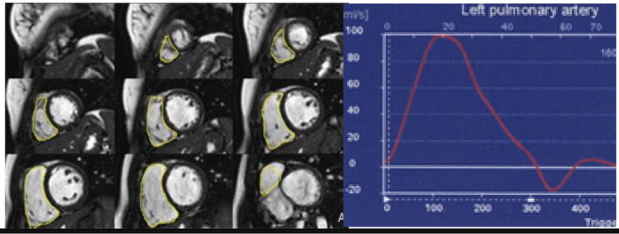
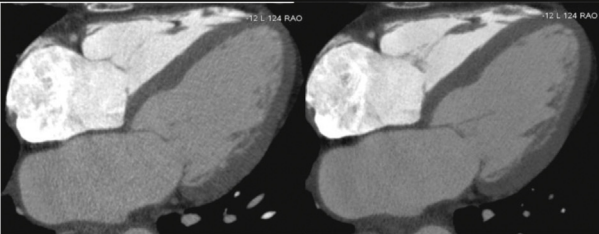
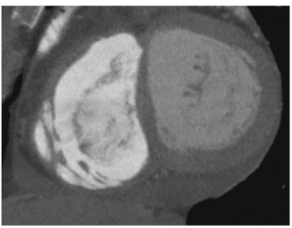
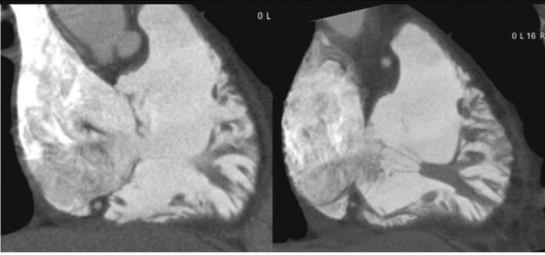
CARDIAC MAGNETIC RESONANCE IMAGING	
CINE IRM (SSFP) HORIZONTAL LONG AXIS	CINE IRM (SSFP) SHORT AXIS
	
- recommended view for TA diameter measurement (diastole)	- Short axis systolic view positioned at the level of TV tips - TR vena contracta shown by cine MRI
CINE IRM (SSFP) RIGHT HEART 2-CHAMBER	STROKE VOLUME METHOD FOR TR QUANTIFICATION
	
- displays anterior and posterior leaflets - allows the diagnosis of TV prolapse	- Total RV SV is calculated from the SSFP images (left) - Forward stroke volume is measured in the pulmonary artery with phase contrast (right) and the difference represents TV regurgitant volume
CARDIAC COMPUTED TOMOGRAPHY SCAN	
CT HORIZONTAL LONG AXIS	CT SHORT AXIS
	
- 0.3mm HLA without (on the left) and 3mm HLA with MinIP (on the right) - minIP is an algorithm allowing detection of low-density structures - Split bolus injection technique is used to improve right heart opacification	- 0.3 mm Short-axis CT image obtained at level of atrioventricular valves - displays an en face view
CT VERTICAL LONG AXIS	
	
- 0.3mm RV 2-chamber (on the left) and 3mm with minIP (on the right) - displays anterior and posterior leaflets and subvalvular apparatus	

Figure 5. Cardiac magnetic resonance (CMR) imaging and computed tomography (CT) scans of the tricuspid valve (TV). RV: right ventricle; TV: tricuspid valve; AL: anterior leaflet; PL: posterior leaflet; SL: septal leaflet; SV: stroke volume; HLA: horizontal long-axis; SSFP: steady-state free precession cine MRI; MinIP: minimal intensity projection.

failure, such as congestive hepatopathy, loss of appetite, ascites, gut congestion with symptoms of dyspepsia or feeling of abdominal fullness and fluid retention with peripheral oedema. Furthermore, the decrease in cardiac output is responsible for fatigue, exertional dyspnoea and decreased functional capacity [27,47,48].

Organic/primary tricuspid regurgitation

Organic TR results from structural abnormalities of the valvular apparatus, which are either congenital or acquired. Table 1 summarizes the main causes and mechanisms of non-congenital organic TR. Some recent reports insist on

with a more planar TA than in healthy subjects [8,11]. Loss of longitudinal flexibility and more restricted movement of the TA have also been shown by CMR in the early stages of FTR, resulting in leaflet tethering even in the absence of RV dilation [51]. Leaflet tethering following displacement of papillary muscles caused by progressive RV distortion and eccentricity also influence the development of FTR [7]. All these mechanisms are variously implicated in the development of FTR. For instance, Topilsky et al. showed that in idiopathic FTR, excess annular and RV inflow enlargement exhausts valvular/annular coverage reserve, and RV conical deformation does not cause notable valvular tenting. Conversely, in pulmonary hypertension, FTR is mostly determined by valvular tethering, with tenting linked to RV elongation and elliptical/spherical deformation [52].

The most common cause of FTR is left heart disease, including advanced mitral, aortic and/or left ventricular myocardial disorder. FTR may also complicate either pulmonary (pulmonary diseases, pulmonary hypertension) or intrinsic (RV cardiomyopathy, arrhythmogenic RV dysplasia, RV infarction, endomyocardial fibrosis, etc.) RV myocardial diseases (Fig. 6). Elevated PAP is a strong determinant of the presence of significant TR and of TR severity, although many patients with pulmonary hypertension do not exhibit significant TR [53]. So, more than just the absolute value of the PAP, remodelling of the right heart in response to elevated PAP and its causes is one of the factors at the origin of FTR. In a large series of more than 2000 patients who had TR-derived estimation of PAP, demographic characteristics (age, female sex), mechanical factors (presence of pacemaker leads), remodelling of the right heart cavities (RA, RV enlargement) and other factors (e.g. organic mitral valve disease, possibly reflecting the presence of atrial fibrillation or occult organic TV disease) were predictive of TR severity in addition to PAP [54]. In a case-control study on the follow-up of patients with mild TR, progressive increase in PAP, atrial fibrillation and coronary artery disease were independent predictive factors of TR progression [55].

Functional tricuspid regurgitation in the follow-up of left heart valve surgery

One peculiar form of FTR complicating left heart diseases is represented by FTR appearing in the follow-up of left-sided valve surgery; this is quite frequent after mitral valve surgery and may occur whatever the type of procedure (repair or replacement) or valvular substitute (biological or mechanical). Until recently, it was believed that surgical correction of left-sided lesions would lead to the disappearance of secondary TR. However, if not treated during the initial surgery, pre-existing FTR may persist and worsen over time. In the presence of severe TR associated with degenerative mitral valve disease, mitral valve repair alone leads to improved TR and RV function; however, this improvement is incomplete and temporary, and TR and RV function worsen toward preoperative levels within 3 years [56]. Moreover, late occurrence of significant TR long after the initial surgical procedure has been shown to be quite common after mitral surgery, and is associated with a poor prognosis in terms of morbidity and mortality [57].

Many factors influencing the occurrence of significant TR during the follow-up of mitral surgery have been reported: older age, female sex, rheumatic fever as the origin of mitral dysfunction, long period of valvular disease before surgery, atrial fibrillation, level of preoperative PAP and preoperative RV dysfunction. Furthermore, preoperative TA dilation [58,59] and the tethering height and tenting volume of TV are important independent predictors of late TR [36].

The type of underlying mitral disease justifying initial surgery probably also plays a role in the occurrence of significant TR. TR seems to be more frequent in case of initial surgery for ischaemic MR, reported as being as high as 74% after 3 years of follow-up [60], than in case of surgery for organic MR, where <20% of patients had severe TR after a 8-year follow-up period [61]. It has even been reported that clinically-silent non-severe TR is unlikely to progress after mitral valve repair for degenerative prolapse [62]. However, these discrepancies between ischaemic and organic origin of initial mitral valve disease are the result of unclear mechanisms [63]; concomitant RV dysfunction in ischaemic diseases probably plays a role in the higher late occurrence of significant TR.

FTR is also seen in patients with aortic stenosis, persisting in a significant degree after valvular replacement in around 15% of the patients, with a further progression in half of these patients. As for the mitral valve, persistent FTR greater than mild was associated with a worse long-term prognosis [64].

Relationship between tricuspid regurgitation and right ventricular function

The relationship between TR and RV function is complex. RV dysfunction mostly influences TR severity through RV remodelling [65]. The influence of severe TR on RV function is less clear.

Experimentally, it has been shown that severe TR in dogs leads to pump failure, but without cellular contractile dysfunction, suggesting a relative preservation of intrinsic RV contractile function despite severe TR [66]. Likewise, old series of tricuspid valvectomy have shown relatively good tolerance at mid-term follow-up in around two-thirds of patients, without signs of congestive heart failure [67,68].

On the other hand, echocardiographic variables of RV function have been shown to alter in parallel with the increase in TR severity [69]. The effect of TR on RV function variables varies according to the mechanisms of TR, but significant TR always leads to increased end-systolic RV size and RV myocardial performance index in both idiopathic FTR and FTR secondary to pulmonary hypertension, with an additional decrease in RV fractional area change in idiopathic FTR, and an increase in RV end-diastolic area in FTR secondary to pulmonary hypertension, suggesting universally reduced RV function with increasing FTR severity [52].

Finally, RV function seems to improve after correction of isolated TR [70], with a reduction in RV volumes [40]; this is also the case when mitral and tricuspid surgery are combined [56]. In the same manner, it has been shown

that the degree of both RV dysfunction and TR severity improves after pulmonary endarterectomy in chronic thromboembolic pulmonary hypertension [71,72]. These studies suggest that severe TR leads to RV dysfunction; however, RV function seems, in some cases, to improve after surgical treatment of either TR or the aetiology of increased RV afterload that is responsible for TR. The real challenge is actually to correctly identify patients whose RV function is deemed good enough for the heart to take advantage of a competent TV [73].

The main issue is that echocardiographic variables of RV function and even CMR-derived RV ejection fraction are well known to be load dependent and not to be a proper reflection of intrinsic RV contractility [74,75]; the real impact of severe TR on intrinsic RV contractile function and on its potential reversibility is therefore difficult to assess. Furthermore, it has been shown that echocardiographic variables of RV function may be altered in the follow-up of cardiac surgery, even in the absence of real RV dysfunction, so that the true impact of TR correction on RV function is also very difficult to comprehend [76,77]. Nevertheless, preserved RV function variables in the presence of significant TR are always associated with a better prognosis than altered ones [56,78,79].

Echocardiographic analysis of tricuspid regurgitation

As for every other valve, the echocardiographic analysis of TR encompasses a description of TV morphology, quantification of TR and the assessment of its haemodynamic consequences.

The quantification of TA enlargement, the mode of leaflet coaptation and the degree of tenting are of utmost importance when making a surgical decision about TV repair or replacement. Significant TA dilatation is defined by a diastolic diameter ≥ 40 mm or > 21 mm/m² in the four-chamber transthoracic view, and is considered as a criterion for concomitant tricuspid procedure in case of left-sided valve surgery [29]. Dreyfus et al. classified the mode of leaflet coaptation as body-to-body in case of normal coaptation, as edge-to-edge or edge-to-body in case of symmetric or asymmetric abnormal coaptation, and as lack of coaptation in case of gaping valve [80]. Quantification of the degree of leaflet tethering needs measurement of the coaptation distance and the tenting area [9]. Coaptation distance > 8 mm and tenting area > 1.6 cm² characterize significant tethering. Measurements of tenting volume and tenting angles from 3D views have also been reported to independently determine residual TR after tricuspid annuloplasty [24].

When quantifying TR, echocardiographers must always remember the marked RV plasticity with inspiratory and loading changes, and bear in mind the resulting potential variations of TR over time, on a short-time scale for respiratory variations and on a longer time scale for variations caused by different loading conditions. Topilsky et al. nicely showed augmentation of TR during inspiration. The inspiratory increase in regurgitant orifice area is explained by inspiratory annular enlargement and RV shape widening, resulting in decreased valvular coverage and increased valvular tenting [81]. In the same manner, RV morphological

changes with preload and afterload variations imply potential variability of TR over time. So, echocardiographic analysis of TR should always take place after medical optimization of loading conditions, and rely on multiple TR measurements averaged over the respiratory cycle.

Grading the severity of TR is not an easy task. There is general agreement about trivial/mild TR seen in different views by colour Doppler as a small central regurgitant blue jet. However, the sole use of colour flow imaging to quantify higher grades of TR is not recommended, as it is limited by several technical and haemodynamic factors. Nevertheless, large eccentric jets, swirling and reaching the posterior wall of the RA, usually indicate significant TR [82]. Scientific societies in Europe and the USA have published recommendations for the quantification of TR [29,30,82,83]. According to the European guidelines and many experts [47,80], TR should be quantified in three grades (mild, moderate and severe) using the classical variables of vena contracta width, regurgitant orifice area and regurgitant volume calculation by the proximal isovelocity surface area (PISA) method, and analysis of anterograde and regurgitant flow profiles and hepatic vein flow. However, all these variables are less robust and have been less validated for TR than for MR. Furthermore, the shape of the regurgitant orifice is more frequently stellar or ellipsoid than circular in TR, and multiple jets are frequent, disqualifying the use of most of these variables. Nevertheless, there is quite a consensus for the definition of severe TR (triangular flow with early peak, E tricuspid velocity > 1 m/s, vena contracta > 7 mm, PISA regurgitant orifice area > 40 mm², regurgitant volume > 45 mL and systolic reversal of hepatic flow), but the boundaries between mild and moderate TR remain poorly defined.

Finally, echocardiography also evaluates the haemodynamic consequences of TR, with the analysis of the inferior vena cava, and RA and RV size and function. However, right heart chamber dilatation and RV dysfunction may not only be the consequence, but also the cause of TR, and must be interpreted with special attention to pulmonary haemodynamics and clinical context.

Cardiac magnetic resonance analysis of tricuspid regurgitation

On in-plane balanced steady-state free precession or phase contrast cine imaging, the regurgitant flow is shown on CMR as a triangular jet into the RA, but the TR jet may be difficult to evaluate because of low turbulence. Obtaining a short-axis image orthogonal to the jet flow is the ideal means of acquiring information about the velocity and direction of flow. Therefore, the jet of regurgitation, especially when it is mild, can be better shown by gradient-recalled echocardiography imaging. TR is best imaged in the four-chamber view and the coronal oblique view displaying the RA and the RV. A vena contracta > 7 mm classifies TR as severe [84–86].

TR can also be quantified in terms of regurgitant volume and fraction in similar ways to mitral regurgitation: the forward stroke volume, as measured in the pulmonary artery with phase contrast, is subtracted from the total RV stroke volumes from the steady-state free precession images or from the difference in right-left ventricular stroke

volumes [87]. However, this method is not applicable in case of irregular rhythms or significant other valve regurgitation.

Natural history and prognostic implications

Many studies have underlined the poor prognosis associated with severe TR. In a recent study of 350 patients with isolated TR, the 10-year survival rate was lower with an regurgitant orifice area >40 mm² vs. <40 mm² (39% vs. 71%), independent of all characteristics, RV size or function, co-morbidity or pulmonary pressure, and was lower than expected in the general population [88]. In the follow-up of 200 patients with mild TR, all-cause mortality at 3 years was 20% for patients without TR progression, 42% for moderate TR and 63% for severe TR, and progression to severe TR independently predicted subsequent mortality [55]. Similar results have been found in the follow-up of left-sided heart valve surgery, with a better prognosis and improved long-term right-sided remodelling in patients who undergo concomitant tricuspid annuloplasty [89], and a poorer prognosis in patients with residual and/or late progression of TR [57,90]. Furthermore, in those patients, there is high morbidity and mortality associated with reoperative open-heart surgery, partly as a result of the unpredictable evolution of the RV [91]. So, a combined procedure on TR at the time of surgery is increasingly supported by published guidelines, despite the lack of randomized data proving its benefit [92].

Conclusion

Increased mortality among patients with TR, regardless of pulmonary pressure, RV function or left heart valve disease has revived interest in the TV. The optimal analysis of the TV should be achieved through a perfect knowledge of its anatomy, function and pathophysiology, and through a thorough evaluation with multimodality imaging. 2D, 3D TTE and TOE, together with CT scans and CMR, allow the accurate morphological description of the TV complex, including leaflets, subvalvular apparatus and the TA, and quantitative evaluation of TR and RV function. However, the selection of patients who will benefit from surgical repair or replacement of the TV, either in isolation or combined with another surgical procedure on the left heart, is a subject of hot debate in the field of heart valve disease, and the development of new percutaneous procedures further adds to the complexity of this issue.

Disclosure of interest

The authors declare that they have no competing interest.

References

- [1] Hollman A. The anatomical appearance in rheumatic tricuspid valve disease. *Br Heart J* 1957;19:211–6.
- [2] Shah PM, Raney AA. Tricuspid valve disease. *Curr Probl Cardiol* 2008;33:47–84.
- [3] Silver MD, Lam JH, Ranganathan N, Wigle ED. Morphology of the human tricuspid valve. *Circulation* 1971;43:333–48.
- [4] Wafae N, Hayashi H, Gerola LR, Vieira MC. Anatomical study of the human tricuspid valve. *Surg Radiol Anat* 1990;12:37–41.
- [5] Martinez RM, O’Leary PW, Anderson RH. Anatomy and echocardiography of the normal and abnormal tricuspid valve. *Cardiol Young* 2006;16(Suppl. 3):4–11.
- [6] Aktas EO, Govsa F, Kocak A, Boydak B, Yavuz IC. Variations in the papillary muscles of normal tricuspid valve and their clinical relevance in medicolegal autopsies. *Saudi Med J* 2004;25:1176–85.
- [7] Taramasso M, Vanermen H, Maisano F, Guidotti A, La Canna G, Alfieri O. The growing clinical importance of secondary tricuspid regurgitation. *J Am Coll Cardiol* 2012;59:703–10.
- [8] Ton-Nu TT, Levine RA, Handschumacher MD, et al. Geometric determinants of functional tricuspid regurgitation: insights from 3-dimensional echocardiography. *Circulation* 2006;114:143–9.
- [9] Fukuda S, Saracino G, Matsumura Y, et al. Three-dimensional geometry of the tricuspid annulus in healthy subjects and in patients with functional tricuspid regurgitation: a real-time, 3-dimensional echocardiographic study. *Circulation* 2006;114:1492–8.
- [10] Miglioranza MH, Mihaila S, Muraru D, Cucchini U, Iliceto S, Badano LP. Dynamic changes in tricuspid annular diameter measurement in relation to the echocardiographic view and timing during the cardiac cycle. *J Am Soc Echocardiogr* 2015;28:226–35.
- [11] Fukuda S, Gillinov AM, McCarthy PM, et al. Determinants of recurrent or residual functional tricuspid regurgitation after tricuspid annuloplasty. *Circulation* 2006;114:1582–7.
- [12] Tei C, Pilgrim JP, Shah PM, Ormiston JA, Wong M. The tricuspid valve annulus: study of size and motion in normal subjects and in patients with tricuspid regurgitation. *Circulation* 1982;66:665–71.
- [13] Muraru D, Badano LP, Sarais C, Solda E, Iliceto S. Evaluation of tricuspid valve morphology and function by transthoracic three-dimensional echocardiography. *Curr Cardiol Rep* 2011;13:242–9.
- [14] Stankovic I, Daraban AM, Jasaityte R, Neskovic AN, Claus P, Voigt JU. Incremental value of the en face view of the tricuspid valve by two-dimensional and three-dimensional echocardiography for accurate identification of tricuspid valve leaflets. *J Am Soc Echocardiogr* 2014;27:376–84.
- [15] Anwar AM, Geleijnse ML, Soliman OI, et al. Assessment of normal tricuspid valve anatomy in adults by real-time three-dimensional echocardiography. *Int J Cardiovasc Imaging* 2007;23:717–24.
- [16] Badano LP, Agricola E, Perez de Isla L, Gianfagna P, Zamorano JL. Evaluation of the tricuspid valve morphology and function by transthoracic real-time three-dimensional echocardiography. *Eur J Echocardiogr* 2009;10:477–84.
- [17] Bhattacharyya S, Toumpanakis C, Burke M, Taylor AM, Caplin ME, Davar J. Features of carcinoid heart disease identified by 2- and 3-dimensional echocardiography and cardiac MRI. *Circ Cardiovasc Imaging* 2010;3:103–11.
- [18] Patel V, Nanda NC, Rajdev S, et al. Live/real time three-dimensional transthoracic echocardiographic assessment of Ebstein’s anomaly. *Echocardiography* 2005;22:847–54.
- [19] van Noord PT, Scohy TV, McGhie J, Bogers AJ. Three-dimensional transesophageal echocardiography in Ebstein’s anomaly. *Interact Cardiovasc Thorac Surg* 2010;10:836–7.
- [20] Addetia K, Maffessanti F, Mediratta A, et al. Impact of implantable transvenous device lead location on severity of tricuspid regurgitation. *J Am Soc Echocardiogr* 2014;27:1164–75.
- [21] Klein AL, Jellis CL. 3D imaging of device leads: “taking the lead with 3D”. *JACC Cardiovasc Imaging* 2014;7:348–50.
- [22] Mediratta A, Addetia K, Yamat M, et al. 3D echocardiographic location of implantable device leads and mechanism of associated tricuspid regurgitation. *JACC Cardiovasc Imaging* 2014;7:337–47.

- [23] Song JM, Jang MK, Choi YS, et al. The vena contracta in functional tricuspid regurgitation: a real-time three-dimensional color Doppler echocardiography study. *J Am Soc Echocardiogr* 2011;24:663–70.
- [24] Min SY, Song JM, Kim JH, et al. Geometric changes after tricuspid annuloplasty and predictors of residual tricuspid regurgitation: a real-time three-dimensional echocardiography study. *Eur Heart J* 2010;31:2871–80.
- [25] Schnabel R, Khaw AV, von Bardeleben RS, et al. Assessment of the tricuspid valve morphology by transthoracic real-time-3D echocardiography. *Echocardiography* 2005;22:15–23.
- [26] Dreyfus GD, Corbi PJ, Chan KM, Bahrami T. Secondary tricuspid regurgitation or dilatation: which should be the criteria for surgical repair? *Ann Thorac Surg* 2005;79:127–32.
- [27] Rogers JH, Bolling SF. The tricuspid valve: current perspective and evolving management of tricuspid regurgitation. *Circulation* 2009;119:2718–25.
- [28] Anwar AM, Geleijnse ML, Ten Cate FJ, Meijboom FJ. Assessment of tricuspid valve annulus size, shape and function using real-time three-dimensional echocardiography. *Interact Cardiovasc Thorac Surg* 2006;5:683–7.
- [29] Joint Task Force on the Management of Valvular Heart Disease of the European Society of Cardiology, European Association for Cardio-Thoracic Surgery, Vahanian A, et al. Guidelines on the management of valvular heart disease (version 2012). *Eur Heart J* 2012;33:2451–96.
- [30] Nishimura RA, Otto CM, Bonow RO, et al. 2014 AHA/ACC Guideline for the Management of Patients With Valvular Heart Disease: a report of the American College of Cardiology/American Heart Association Task Force on Practice Guidelines. *Circulation* 2014;129:e521–643.
- [31] Kwan J, Kim GC, Jeon MJ, et al. 3D geometry of a normal tricuspid annulus during systole: a comparison study with the mitral annulus using real-time 3D echocardiography. *Eur J Echocardiogr* 2007;8:375–83.
- [32] Mahmood F, Kim H, Chaudary B, et al. Tricuspid annular geometry: a three-dimensional transesophageal echocardiographic study. *J Cardiothorac Vasc Anesth* 2013;27:639–46.
- [33] Owais K, Taylor CE, Jiang L, et al. Tricuspid annulus: a three-dimensional deconstruction and reconstruction. *Ann Thorac Surg* 2014;98:1536–42.
- [34] Park YH, Song JM, Lee EY, Kim YJ, Kang DH, Song JK. Geometric and hemodynamic determinants of functional tricuspid regurgitation: a real-time three-dimensional echocardiography study. *Int J Cardiol* 2008;124:160–5.
- [35] Gopalan D. Right heart on multidetector CT. *Br J Radiol* 2011;84(3):S306–23.
- [36] Kabasawa M, Kohno H, Ishizaka T, et al. Assessment of functional tricuspid regurgitation using 320-detector-row multislice computed tomography: risk factor analysis for recurrent regurgitation after tricuspid annuloplasty. *J Thorac Cardiovasc Surg* 2014;147:312–20.
- [37] Nemoto N, Lesser JR, Pedersen WR, et al. Pathogenic structural heart changes in early tricuspid regurgitation. *J Thorac Cardiovasc Surg* 2015;150:323–30.
- [38] Han Y, Peters DC, Salton CJ, et al. Cardiovascular magnetic resonance characterization of mitral valve prolapse. *JACC Cardiovasc Imaging* 2008;1:294–303.
- [39] Masci PG, Dymarkowski S, Bogaert J. Valvular heart disease: what does cardiovascular MRI add? *Eur Radiol* 2008;18:197–208.
- [40] Kim HK, Kim YJ, Park EA, et al. Assessment of haemodynamic effects of surgical correction for severe functional tricuspid regurgitation: cardiac magnetic resonance imaging study. *Eur Heart J* 2010;31:1520–8.
- [41] Anwar AM, Soliman OI, Nemes A, van Geuns RJ, Geleijnse ML, Ten Cate FJ. Value of assessment of tricuspid annulus: real-time three-dimensional echocardiography and magnetic resonance imaging. *Int J Cardiovasc Imaging* 2007;23:701–5.
- [42] Maffessanti F, Gripari P, Pontone G, et al. Three-dimensional dynamic assessment of tricuspid and mitral annuli using cardiovascular magnetic resonance. *Eur Heart J Cardiovasc Imaging* 2013;14:986–95.
- [43] Lavie CJ, Hebert K, Cassidy M. Prevalence and severity of Doppler-detected valvular regurgitation and estimation of right-sided cardiac pressures in patients with normal two-dimensional echocardiograms. *Chest* 1993;103:226–31.
- [44] Singh JP, Evans JC, Levy D, et al. Prevalence and clinical determinants of mitral, tricuspid, and aortic regurgitation (the Framingham Heart Study). *Am J Cardiol* 1999;83:897–902.
- [45] Ong K, Yu G, Jue J. Prevalence and spectrum of conditions associated with severe tricuspid regurgitation. *Echocardiography* 2014;31:558–62.
- [46] Mutlak D, Lessick J, Reisner SA, Aronson D, Dabbah S, Agmon Y. Echocardiography-based spectrum of severe tricuspid regurgitation: the frequency of apparently idiopathic tricuspid regurgitation. *J Am Soc Echocardiogr* 2007;20:405–8.
- [47] Badano LP, Muraru D, Enriquez-Sarano M. Assessment of functional tricuspid regurgitation. *Eur Heart J* 2013;34:1875–85.
- [48] Kim HK, Lee SP, Kim YJ, Sohn DW. Tricuspid regurgitation: clinical importance and its optimal surgical timing. *J Cardiovasc Ultrasound* 2013;21:1–9.
- [49] Spinner EM, Shannon P, Buice D, et al. In vitro characterization of the mechanisms responsible for functional tricuspid regurgitation. *Circulation* 2011;124:920–9.
- [50] Ring L, Rana BS, Kydd A, Boyd J, Parker K, Rusk RA. Dynamics of the tricuspid valve annulus in normal and dilated right hearts: a three-dimensional transoesophageal echocardiography study. *Eur Heart J Cardiovasc Imaging* 2012;13:756–62.
- [51] Maeba S, Taguchi T, Midorikawa H, Kanno M, Sueda T. Four-dimensional geometric assessment of tricuspid annulus movement in early functional tricuspid regurgitation patients indicates decreased longitudinal flexibility. *Interact Cardiovasc Thorac Surg* 2013;16:743–9.
- [52] Topilsky Y, Khanna A, Le Tourneau T, et al. Clinical context and mechanism of functional tricuspid regurgitation in patients with and without pulmonary hypertension. *Circ Cardiovasc Imaging* 2012;5:314–23.
- [53] De Meester P, Van De Bruaene A, Herijgers P, Voigt JU, Budts W. Tricuspid valve regurgitation: prevalence and relationship with different types of heart disease. *Acta Cardiol* 2012;67:549–56.
- [54] Mutlak D, Aronson D, Lessick J, Reisner SA, Dabbah S, Agmon Y. Functional tricuspid regurgitation in patients with pulmonary hypertension: is pulmonary artery pressure the only determinant of regurgitation severity? *Chest* 2009;135:115–21.
- [55] Shiran A, Najjar R, Adawi S, Aronson D. Risk factors for progression of functional tricuspid regurgitation. *Am J Cardiol* 2014;113:995–1000.
- [56] Desai RR, Vargas Abello LM, Klein AL, et al. Tricuspid regurgitation and right ventricular function after mitral valve surgery with or without concomitant tricuspid valve procedure. *J Thorac Cardiovasc Surg* 2013;146:1126e10–32e10.
- [57] Katsi V, Raftopoulos L, Aggeli C, et al. Tricuspid regurgitation after successful mitral valve surgery. *Interact Cardiovasc Thorac Surg* 2012;15:102–8.
- [58] Rajbanshi BG, Suri RM, Nkomo VT, et al. Influence of mitral valve repair versus replacement on the development of late functional tricuspid regurgitation. *J Thorac Cardiovasc Surg* 2014;148:1957–62.
- [59] Shi KH, Xuan HY, Zhang F, et al. Evolution of tricuspid regurgitation after mitral valve surgery for patients with moderate-or-less functional tricuspid regurgitation. *Heart Surg Forum* 2012;15:E121–6.

- [60] Matsunaga A, Duran CM. Progression of tricuspid regurgitation after repaired functional ischemic mitral regurgitation. *Circulation* 2005;112:1453–7.
- [61] Matsuyama K, Matsumoto M, Sugita T, Nishizawa J, Tokuda Y, Matsuo T. Predictors of residual tricuspid regurgitation after mitral valve surgery. *Ann Thorac Surg* 2003;75:1826–8.
- [62] Yilmaz O, Suri RM, Dearani JA, et al. Functional tricuspid regurgitation at the time of mitral valve repair for degenerative leaflet prolapse: the case for a selective approach. *J Thorac Cardiovasc Surg* 2011;142:608–13.
- [63] Thapa R, Dawn B, Nath J. Tricuspid regurgitation: pathophysiology and management. *Curr Cardiol Rep* 2012;14:190–9.
- [64] Jeong DS, Sung K, Kim WS, et al. Fate of functional tricuspid regurgitation in aortic stenosis after aortic valve replacement. *J Thorac Cardiovasc Surg* 2014;148:1328e1–33e1.
- [65] Grapsa J, Gibbs JS, Dawson D, et al. Morphologic and functional remodeling of the right ventricle in pulmonary hypertension by real time three dimensional echocardiography. *Am J Cardiol* 2012;109:906–13.
- [66] Ishibashi Y, Rembert JC, Carabello BA, et al. Normal myocardial function in severe right ventricular volume overload hypertrophy. *Am J Physiol Heart Circ Physiol* 2001;280:H11–6.
- [67] Arbulu A, Holmes RJ, Asfaw I. Tricuspid valvectomy without replacement. Twenty years' experience. *J Thorac Cardiovasc Surg* 1991;102:917–22.
- [68] Robin E, Thomas NW, Arbulu A, Ganguly SN, Magnisalis K. Hemodynamic consequences of total removal of the tricuspid valve without prosthetic replacement. *Am J Cardiol* 1975;35:481–6.
- [69] Hsiao SH, Lin SK, Wang WC, Yang SH, Gin PL, Liu CP. Severe tricuspid regurgitation shows significant impact in the relationship among peak systolic tricuspid annular velocity, tricuspid annular plane systolic excursion, and right ventricular ejection fraction. *J Am Soc Echocardiogr* 2006;19:902–10.
- [70] Mukherjee D, Nader S, Olano A, Garcia MJ, Griffin BP. Improvement in right ventricular systolic function after surgical correction of isolated tricuspid regurgitation. *J Am Soc Echocardiogr* 2000;13:650–4.
- [71] Ishida K, Masuda M, Imamaki M, Katsumata M, Maruyama T, Miyazaki M. Improvement of tricuspid regurgitation after pulmonary thromboendarterectomy. *Asian Cardiovasc Thorac Ann* 2010;18:229–33.
- [72] Li YD, Zhai ZG, Wu YF, et al. Improvement of right ventricular dysfunction after pulmonary endarterectomy in patients with chronic thromboembolic pulmonary hypertension: utility of echocardiography to demonstrate restoration of the right ventricle during 2-year follow-up. *Thromb Res* 2013;131:e196–201.
- [73] Petterson GB, Rodriguez LL, Blackstone EH. Severe tricuspid valve regurgitation is not an innocent finding to be ignored! *JACC Cardiovasc Imaging* 2014;7:1195–7.
- [74] Haddad F, Hunt SA, Rosenthal DN, Murphy DJ. Right ventricular function in cardiovascular disease, part I: anatomy, physiology, aging, and functional assessment of the right ventricle. *Circulation* 2008;117:1436–48.
- [75] Selton-Suty C, Juilliere Y. Non-invasive investigations of the right heart: how and why? *Arch Cardiovasc Dis* 2009;102:219–32.
- [76] Alam M, Wardell J, Andersson E, Nordlander R, Samad B. Assessment of left ventricular function using mitral annular velocities in patients with congestive heart failure with or without the presence of significant mitral regurgitation. *J Am Soc Echocardiogr* 2003;16:240–5.
- [77] Hyllen S, Nozohoor S, Ingvarsson A, Meurling C, Wierup P, Sjögren J. Right ventricular performance after valve repair for chronic degenerative mitral regurgitation. *Ann Thorac Surg* 2014;98:2023–30.
- [78] Chan DT, Lam WW, Tsang FH, Ho CK, Au TW, Cheng LC. Late tricuspid surgery: predicting outcome with computed tomography. *Asian Cardiovasc Thorac Ann* 2011;19:128–32.
- [79] Park K, Kim HK, Kim YJ, et al. Incremental prognostic value of early postoperative right ventricular systolic function in patients undergoing surgery for isolated severe tricuspid regurgitation. *Heart* 2011;97:1319–25.
- [80] Dreyfus GD, Martin RP, Chan KM, Dulguerov F, Alexandrescu C. Functional tricuspid regurgitation: a need to revise our understanding. *J Am Coll Cardiol* 2015;65:2331–6.
- [81] Topilsky Y, Tribouilloy C, Michelena HI, Pislaru S, Mahoney DW, Enriquez-Sarano M. Pathophysiology of tricuspid regurgitation: quantitative Doppler echocardiographic assessment of respiratory dependence. *Circulation* 2010;122:1505–13.
- [82] Lancellotti P, Moura L, Pierard LA, et al. European Association of Echocardiography recommendations for the assessment of valvular regurgitation. Part 2: mitral and tricuspid regurgitation (native valve disease). *Eur J Echocardiogr* 2010;11:307–32.
- [83] Lancellotti P, Tribouilloy C, Hagendorff A, et al. Recommendations for the echocardiographic assessment of native valvular regurgitation: an executive summary from the European Association of Cardiovascular Imaging. *Eur Heart J Cardiovasc Imaging* 2013;14:611–44.
- [84] Helbing WA, Niezen RA, Le Cessie S, van der Geest RJ, Ottenkamp J, de Roos A. Right ventricular diastolic function in children with pulmonary regurgitation after repair of tetralogy of Fallot: volumetric evaluation by magnetic resonance velocity mapping. *J Am Coll Cardiol* 1996;28:1827–35.
- [85] Roes SD, Hammer S, van der Geest RJ, et al. Flow assessment through four heart valves simultaneously using 3-dimensional 3-directional velocity-encoded magnetic resonance imaging with retrospective valve tracking in healthy volunteers and patients with valvular regurgitation. *Invest Radiol* 2009;44:669–75.
- [86] Westenberg JJ, Roes SD, Ajmone Marsan N, et al. Mitral valve and tricuspid valve blood flow: accurate quantification with 3D velocity-encoded MR imaging with retrospective valve tracking. *Radiology* 2008;249:792–800.
- [87] Koskenvuo JW, Jarvinen V, Parkka JP, Kiviniemi TO, Hartiala JJ. Cardiac magnetic resonance imaging in valvular heart disease. *Clin Physiol Funct Imaging* 2009;29:229–40.
- [88] Topilsky Y, Nkomo VT, Vatury O, et al. Clinical outcome of isolated tricuspid regurgitation. *JACC Cardiovasc Imaging* 2014;7:1185–94.
- [89] Chikwe J, Itagaki S, Anyanwu A, Adams DH. Impact of Concomitant tricuspid annuloplasty on tricuspid regurgitation, right ventricular function, and pulmonary artery hypertension after repair of mitral valve prolapse. *J Am Coll Cardiol* 2015;65:1931–8.
- [90] Yeates A, Marwick T, Deva R, et al. Does moderate tricuspid regurgitation require attention during mitral valve surgery? *ANZ J Surg* 2014;84:63–7.
- [91] Umehara N, Miyata H, Motomura N, Saito S, Yamazaki K. Surgical results of reoperative tricuspid surgery: analysis from the Japan Cardiovascular Surgery Database. *Interact Cardiovasc Thorac Surg* 2014;19:82–7.
- [92] Filsoufi F, Chikwe J, Carpentier A. Rationale for remodelling annuloplasty to address functional tricuspid regurgitation during left-sided valve surgery. *Eur J Cardiothorac Surg* 2015;47:1–3.