



Pan African Urological Surgeons' Association

African Journal of Urology

www.ees.elsevier.com/afju
www.sciencedirect.com



Ameliorative potential of gemfibrozil and silymarin on experimentally induced nephrotoxicity in rats

A.M. Kabel^{a,*}, H.A. Mahmoud^a, S.S. El Kholly^b

^a Pharmacology Department, Faculty of Medicine, Tanta University, Egypt

^b Physiology Department, Faculty of Medicine, Tanta University, Egypt

Received 16 February 2013; received in revised form 5 April 2013; accepted 5 April 2013

KEYWORDS

Gemfibrozil;
Silymarin;
Nephrotoxicity;
Rats;
Cisplatin

Abstract

Introduction: Acute nephrotoxicity is a frequent complication of critical illness especially in the inpatient setting. Cisplatin is one of the most active anticancer drugs. Nephrotoxicity is the most common side effect associated with cisplatin treatment. Silymarin is widely used for hepatic disorders due to its antioxidant and anti-inflammatory properties. Gemfibrozil, a hypolipidemic drug, has also antioxidant and anti-inflammatory properties.

Objective: To detect the effect of gemfibrozil and silymarin either alone or in combination on cisplatin-induced nephrotoxicity in rats.

Subjects and methods: Fifty albino rats were divided into 5 equal groups: Control untreated group, cisplatin treated group, gemfibrozil + cisplatin treated group, silymarin + cisplatin treated group, gemfibrozil + silymarin + cisplatin treated group. Blood urea, serum creatinine, creatinine clearance, urinary N-acetyl beta-D-glucosaminidase, urinary protein, tissue superoxide dismutase, malondialdehyde, reduced glutathione, tumour necrosis factor alpha and mitochondrial complex I activity were determined. Kidneys were excised for histopathological examination.

Results: Gemfibrozil and/or silymarin efficiently attenuated cisplatin-induced nephrotoxicity evidenced by significant decrease in blood urea, serum creatinine, urinary N-acetyl beta-D-glucosaminidase, urinary protein, tissue malondialdehyde and tissue tumour necrosis factor alpha with significant increase in creatinine clearance, tissue reduced glutathione, tissue superoxide dismutase and mitochondrial complex I activity simultaneous with reduction of the necrotic damage and progressively increasing apoptotic index assessed by renal histopathological examination compared to the cisplatin treated group.

* Corresponding author at: El-Geish Street, Faculty of Medicine, Tanta University, Department of Pharmacology, Tanta 31527, Egypt.

Tel.: +20 1009041488.

E-mail address: drakabel@gmail.com (A.M. Kabel).

Peer review under responsibility of Pan African Urological Surgeons' Association.



Production and hosting by Elsevier

1110-5704 © 2013 Pan African Urological Surgeons' Association.

Production and hosting by Elsevier B.V. Open access under [CC BY-NC-ND license](https://creativecommons.org/licenses/by-nc-nd/4.0/).

<http://dx.doi.org/10.1016/j.afju.2013.04.002>

Conclusion: The combination of gemfibrozil and silymarin has protective effects against cisplatin-induced nephrotoxicity in rats better than each of these drugs alone due to anti-inflammatory and antioxidant properties of the used drugs.

© 2013 Pan African Urological Surgeons' Association. Production and hosting by Elsevier B.V.
Open access under [CC BY-NC-ND license](#).

Introduction

Kidneys are vulnerable to damage by toxins, infection, immune reactions and ischaemia. Acute renal failure is a frequent complication of critical illness especially in the inpatient setting [1]. The prognosis of acute renal failure is complicated by secondary injuries induced by free radicals formed during ischaemia/reperfusion injury of the kidney [2].

Cisplatin, anticancer drug, is one of the most active drugs used in treatment of tumours such as testicular, bladder, lung, stomach and ovarian cancers [3]. Cisplatin can be used as a model for nephrotoxicity [4]. The mechanisms of cisplatin nephrotoxicity are still not fully understood. The nephrotoxicity of cisplatin seems to be due to cell membrane peroxidation, mitochondrial dysfunction, inhibition of protein synthesis, DNA damage, changes in the pro-apoptotic Bax protein and inhibition of the antioxidant system by pro-oxidant damage to the renal tissue [5,6]. Previous reports have demonstrated protective roles for antioxidants and free radical scavengers such as vitamin E, lipoic acid and N-acetylcysteine in cisplatin-induced acute nephrotoxicity [7].

Silymarin is the active ingredient of milk thistle. Several studies proved that silymarin has antioxidant and anti-inflammatory properties [8,9]. Silymarin is widely used for hepatic and biliary disorders and is under trial for treatment of renal disorders [10].

Gemfibrozil is a fibrate medication considered as one of peroxisome proliferator-activated receptors alpha (PPAR- α) agonists used along with a proper diet to lower triglycerides and cholesterol in the blood [11]. Li et al. [12] reported that PPAR- α inhibit fatty acid oxidation. Some trials have been performed by Li et al. [13] showed that fibrates have antioxidant and anti-inflammatory properties that help in healing and wound repair. For all these reasons, study of the effects of gemfibrozil and silymarin on experimentally induced nephrotoxicity is of particular interest. The aim of this work was to detect the effect of gemfibrozil and silymarin either alone or in combination on cisplatin-induced nephrotoxicity in rats.

Subjects and methods

Drugs used

- **Cisplatin** vial 10 mg/10 ml (Merck); was administered intraperitoneally in a dose of 20 mg/kg body weight [13].
- **Gemfibrozil** tablets (Lopid, Alkan pharma); was administered orally in a dose of 100 mg/kg body weight, prepared as 10 mg/ml in 0.5% Carboxy methyl cellulose solution [14].
- **Silymarin** powder (Sedico, Egypt); was administered orally as a suspension in a dose of 100 mg/kg body weight, prepared as 10 mg/ml in 0.5% Carboxy methyl cellulose solution [15].

Animals used and experimental design

In this work, we used 50 albino rats of both sexes weighting 150–200 g. All the experiments were conducted according to the National Research Council's guidelines. Animal handling was followed according to the principles of laboratory animal care (NIH publication #85-23, revised in 1985). Rats were housed in animal laboratory room, had free access to water and food all over the period of the work. The duration of the experiment was 18 days. The animals were divided into 5 equal groups as follows:

- Group (1): Control untreated group.
- Group (2): Nephrotoxicity induced group, received cisplatin intraperitoneally in a dose of 20 mg/kg body weight (single dose).
- Group (3): Received gemfibrozil orally in a dose of 100 mg/kg body weight once daily for 14 days then received cisplatin intraperitoneally in a dose of 20 mg/kg body weight (single dose).
- Group (4): Received silymarin orally in a dose of 100 mg/kg body weight once daily for 14 days then received cisplatin intraperitoneally in a dose of 20 mg/kg body weight (single dose).
- Group (5): Received gemfibrozil orally in a dose of 100 mg/kg body weight once daily concomitant with silymarin orally in a dose of 100 mg/kg body weight once daily for 14 days then received cisplatin intraperitoneally in a dose of 20 mg/kg body weight (single dose).

At the end of the experimental period (3 days after cisplatin injection), the animals were kept in individual metabolic cages for 24-h urine collection. The collected urine was analyzed for protein content according to the sulfosalicylic acid colorimetric method [16], N-acetyl beta-D-glucosaminidase (NAG) activity according to the method of Price [17], and creatinine concentration according to the method of Henry [18].

In the following day, blood samples were taken by retro-orbital method to estimate blood urea according to the method of Patton and Crouch [19] and serum creatinine according to the method of Henry [18]. According to the 24 h urine volume, urinary creatinine and serum creatinine concentration, creatinine clearance was calculated by applying the following formula [20]:

$$\text{Creatinine clearance (ml/min)} = \frac{\text{mg creatinine/dl urine} \times \text{ml urine 24 h}}{\text{mg creatinine/dl serum} \times 1440}$$

Rats were sacrificed by decerebration and both kidneys were removed and sectioned for histopathological analysis [21]. The remaining kidney tissue was homogenized for determination of malondialdehyde (MDA) according to the method based on the reaction with thiobarbituric acid [22], superoxide dismutase (SOD) activity according to the method of Marklund and Marklund [23], reduced glutathione (GSH) according to the method of Beutler et al. [24],

total protein content according to the method of Lowry et al. [25] and tissue TNF- α using ELISA kits supplied by RayBiotech, Inc.

Preparation of the rat kidney mitochondria

A part of the kidney was collected in a special medium obtained by dissolving 10.94 g sucrose, 1.21 g Tris-HCl, and 0.38 g EGTA in 100 ml distilled water and pH was adjusted to 7.8. Homogenization was done in 9 volumes of this cold medium with three or four strokes. Then, the homogenate was centrifuged at $700 \times g$ for 10 min at 4°C , the supernatant was centrifuged for 20 min at $1000 \times g$ to obtain mitochondria pellets that were washed with the previous collecting buffer to remove microsomal and cellular contamination. Then, mitochondria were resuspended in 9 volumes of the collecting buffer [26]. Mitochondrial protein was determined using Lowry method [25]. Then, mitochondrial complex I activity was measured according to the method of Birch-Machin et al. [27].

Measurement of the apoptotic index

Apoptotic index (AI) was defined as aggregate percentages of apoptotic cells and/or apoptotic bodies per total number of cells (1000 cells counted) in 10 randomly selected high power fields ($400\times$). The counting was performed by one pathologist, and in 20% of randomly selected cases the counting was repeated by another pathologist. In cases with significant disagreement between results, the counting was performed at the multiheaded microscope by both pathologists. The morphological criteria for apoptotic bodies were applied in our study according to Staunton and Gaffney [28] as follows: (1) a single rounded mass with condensed, strongly eosinophilic cytoplasm with a single clump of strongly basophilic material representing chromatin condensation; (2) a similar to the previously mentioned structure but with condensed chromatin, fragmented into more than one piece; (3) fragments of condensed chromatin without surrounding cytoplasm. The apoptotic bodies most frequently appear as single structures separated from the surrounding intact cells by a clear halo. Clusters of minute apoptotic bodies were counted as one. Apoptotic bodies were not counted in necrotic areas. Equivocal apoptotic bodies were not counted.

Statistical analysis

Data were presented as mean \pm SEM. Data were statistically analyzed by computer SPSS 15 software. Data were analyzed by one way analysis of normality of variance (ANOVA). Independent sample *t*-test and Covariate test were used as statistical tests. Differences

between the means of different groups were considered significant at a level of *P*-value less than 0.05.

Results

Effect of different treatments on blood urea, serum creatinine and creatinine clearance (Table 1)

- Administration of cisplatin to rats resulted in significant increase in blood urea and serum creatinine with significant decrease in creatinine clearance compared to the control untreated group.
- Administration of silymarin and/or gemfibrozil to rats before cisplatin administration resulted in significant decrease in blood urea and serum creatinine with significant increase in creatinine clearance compared to cisplatin treated group.
- The decrease in blood urea and serum creatinine and the increase in creatinine clearance were more significant in silymarin and gemfibrozil combination group compared to the use of each drug individually.

Effect of different treatments on urinary NAG and urinary protein (Table 1)

- Administration of cisplatin to rats resulted in significant increase in urinary NAG and urinary protein compared to the control untreated group.
- Administration of silymarin and/or gemfibrozil to rats before cisplatin administration resulted in significant decrease in urinary NAG and urinary protein compared to cisplatin treated group.
- The decrease in urinary NAG and urinary protein was more significant in silymarin and gemfibrozil combination group compared to the use of each drug individually.

Effect of different treatments on the antioxidant status (Table 2)

- Administration of cisplatin to rats resulted in significant increase in tissue MDA with significant decrease in tissue GSH and tissue SOD compared to the control untreated group.
- Administration of silymarin and/or gemfibrozil to rats before cisplatin administration resulted in significant decrease in tissue MDA with significant increase in tissue GSH and tissue SOD compared to cisplatin treated group.
- The decrease in tissue MDA and the increase in tissue GSH and tissue SOD were more significant in silymarin and gemfibrozil combination group compared to the use of each drug individually.

Table 1 Effect of administration of gemfibrozil, silymarin and their combination on blood urea, serum creatinine, creatinine clearance, urinary protein and urinary NAG and urinary in cisplatin treated rats.

	Control	Cisplatin	Gemfibrozil + cisplatin	Silymarin + cisplatin	Gemfibrozil + silymarin + cisplatin
Blood urea (mg/dl)	20.2 \pm 0.67	77.12 \pm 2.83*	52.41 \pm 2.77#	47.64 \pm 2.23#	37.4 \pm 1.15#,\$,\bullet
Serum creatinine (mg/dl)	0.25 \pm 0.01	1.23 \pm 0.04*	0.69 \pm 0.02#	0.57 \pm 0.03#	0.47 \pm 0.02#,\$,\bullet
Creatinine clearance (ml/min/day)	1.24 \pm 0.03	0.44 \pm 0.01*	0.68 \pm 0.02#	0.73 \pm 0.02#	0.87 \pm 0.04#,\$,\bullet
Urinary NAG (U/L)	0.23 \pm 0.01	1.26 \pm 0.02*	0.76 \pm 0.02#	0.65 \pm 0.02#	0.49 \pm 0.01#,\$,\bullet
Urinary protein (mg/dl)	0.56 \pm 0.02	1.69 \pm 0.07*	1.19 \pm 0.06#	0.98 \pm 0.03#	0.86 \pm 0.04#,\$,\bullet

Values were represented as mean \pm SEM. Number of rats in each group = 10.

* Significant compared to the control group (*P* value less than 0.05).

Significant compared to cisplatin group (*P* value less than 0.05).

\$ Significant compared to gemfibrozil + cisplatin group (*P* value less than 0.05).

\bullet Significant compared to silymarin + cisplatin group (*P* value less than 0.05).

Table 2 Effect of administration of gemfibrozil, silymarin and their combination on different oxidative stress biomarkers (Renal SOD, GSH, MDA), tissue TNF- α and mitochondrial complex I activity in cisplatin treated rats.

	Control	Cisplatin	Gemfibrozil + cisplatin	Silymarin + cisplatin	Gemfibrozil + silymarin + cisplatin
Renal SOD (U/g protein)	742.3 \pm 8.5	287.15 \pm 4.4*	486.2 \pm 8.21#	544.11 \pm 6.08#	595.51 \pm 6.2#.S.●
Renal GSH (μ mol/g)	4.3 \pm 0.04	2.44 \pm 0.07*	3.54 \pm 0.06#	3.41 \pm 0.05#	3.82 \pm 0.04#.S.●
Renal MDA (nmol/mg protein)	0.35 \pm 0.02	1.51 \pm 0.02*	0.63 \pm 0.03#	0.72 \pm 0.01#	0.58 \pm 0.02#.S.●
Renal TNF- α (pg/g tissue)	216.01 \pm 6.75	1320.5 \pm 22.5*	813.65 \pm 9.03#	740.65 \pm 9.76#	604.7 \pm 16.2#.S.●
Mitochondrial complex I activity (nmol NADH/min/mg protein)	94.7 \pm 2.13	36.92 \pm 1.45*	62.78 \pm 2.4#	53.62 \pm 3.2#	71.54 \pm 1.8#.S.●

Values were represented as mean \pm SEM. Number of rats in each group = 10.

* Significant compared to the control group (P value less than 0.05).

Significant compared to cisplatin group (P value less than 0.05).

§ Significant compared to gemfibrozil + cisplatin group (P value less than 0.05).

● Significant compared to silymarin + cisplatin group (P value less than 0.05).

Effect of different treatments on tissue TNF- α (Table 2)

- Administration of cisplatin to rats resulted in significant increase in tissue TNF- α compared to the control untreated group.
- Administration of silymarin and/or gemfibrozil to rats before cisplatin administration resulted in significant decrease in tissue TNF- α compared to cisplatin treated group.
- The decrease in tissue TNF- α was more significant in silymarin and gemfibrozil combination group compared to the use of each drug individually.

Effect of different treatments on mitochondrial complex I activity (Table 2)

- Administration of cisplatin to rats resulted in significant decrease in mitochondrial complex I activity compared to the control untreated group.
- Administration of silymarin and/or gemfibrozil to rats before cisplatin administration resulted in significant increase in mitochondrial complex I activity compared to cisplatin treated group.
- The increase in mitochondrial complex I activity was more significant in silymarin and gemfibrozil combination group compared to the use of each drug individually.

Histopathological findings

The kidneys of the control rats had normal morphology with normal appearance of the glomeruli, tubules and interstitium (Fig. 1). Pathological evidence of kidney damage was observed in all rats treated with cisplatin (Fig. 2) as indicated by diffuse tubular degeneration, focal necrosis, diffuse cellular infiltration and haemorrhage. This picture was significantly improved in rats given gemfibrozil alone or silymarin alone or both as evidenced by decrease in the number of infiltrated cells, haemorrhage, tubular degeneration and necrosis (Figs. 3–5) with progressively increasing apoptotic index (Table 3).

Discussion

Cisplatin is a chemotherapeutic drug that is widely used for cancer treatment. However, cisplatin-induced nephrotoxicity is one of the most common side effects. More than 25% of patients develop acute nephrotoxicity after receiving cisplatin due to its accumulation within the proximal tubular cells of the kidney [6,29,30]. Several

factors including inflammation, toxic damage and cell cycle arrest had been incriminated in the pathogenesis of cisplatin nephrotoxicity [31]. Oxidative stress caused by increased generation of reactive oxygen species (ROS) had been suggested to play the major role in cisplatin nephrotoxicity [32,33].

Many studies reported that inflammation plays an important role in the pathophysiology of cisplatin-induced nephrotoxicity [34,35]. In particular, alterations in renal haemodynamics with vasoconstriction leading to decreased renal blood flow after cisplatin administration

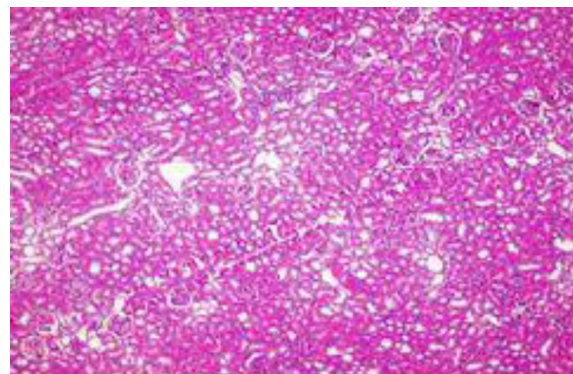


Figure 1 H&E stained sections from the kidney of control untreated group with normal appearance of the glomeruli, tubules and interstitium.

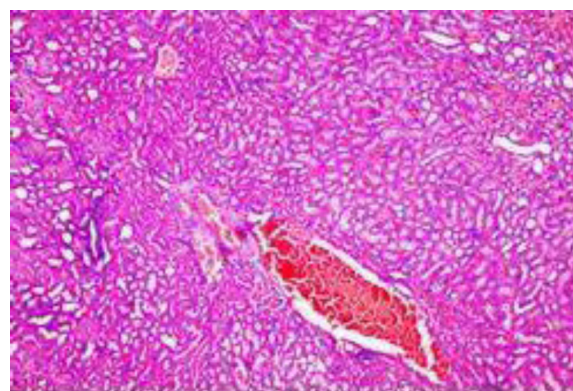


Figure 2 H&E stained sections from the kidney of cisplatin treated group with diffuse tubular degeneration, necrosis and haemorrhage.

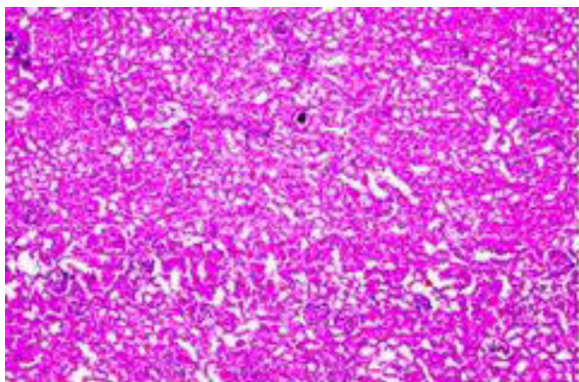


Figure 3 H&E stained sections from the kidney of gemfibrozil + cisplatin treated group with apparently normal glomeruli, focal tubular degeneration and minimal tubular necrosis.

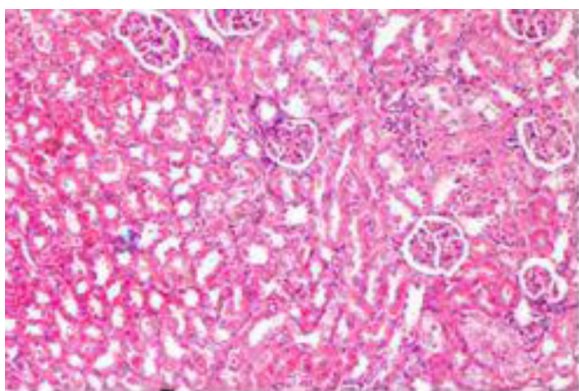


Figure 4 H&E stained sections from the kidney of silymarin + cisplatin treated group with apparently normal glomerul, mild dilatation and necrosis of the tubules.

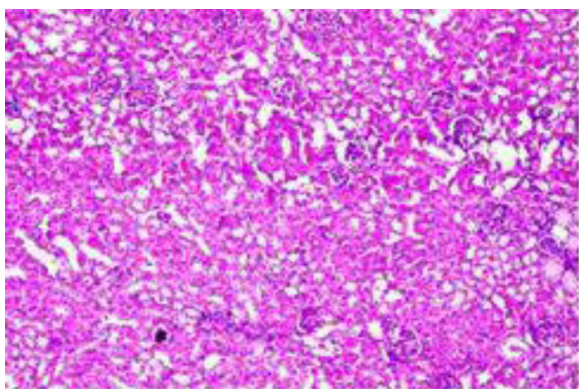


Figure 5 H&E stained sections from the kidney of gemfibrozil + silymarin + cisplatin treated group with apparently normal glomeruli and mild dilatation of the tubules.

[36]. Li et al. [13] showed that cisplatin increased the expression of proinflammatory cytokines such as TNF- α and interleukin-6 (IL-6), which are involved in various forms of inflammatory responses which agree with the results of this current work where there was significant increase in TNF- α associated with cisplatin induced nephrotoxicity.

Table 3 Apoptotic indices for kidney sections from rats treated with gemfibrozil alone or silymarin alone or their combination.

Group	Apoptotic index (%)
Cisplatin	1.4 \pm 0.09
Gemfibrozil + cisplatin	4.3 \pm 0.23 [#]
Silymarin + cisplatin	3.9 \pm 0.17 [#]
Gemfibrozil + silymarin + cisplatin	5.3 \pm 0.27 ^{#,•,\$}

Apoptotic index (%) was calculated for sections of the kidney (values presented as the mean \pm SEM of an average of 10 fields).

[#] Significant compared to cisplatin group (*P* value less than 0.05).

^{\$} Significant compared to gemfibrozil + cisplatin group (*P* value less than 0.05).

[•] Significant compared to silymarin + cisplatin group (*P* value less than 0.05).

Many studies had suggested that free radicals and oxidative stress were involved in cisplatin-induced nephrotoxicity due to depletion of glutathione and decreased activities of the antioxidant enzymes in the kidney [37]. These results were in agreement with the results of this work where there was significant decrease in tissue SOD and GSH with significant increase in tissue MDA with severe tubular necrosis as evidenced by renal histopathological examination. Treatment with antioxidants such as vitamin E before and after the cisplatin could significantly prevent the depletion of the renal antioxidant systems [38].

In the present study, it was observed that cisplatin induced significant increase in blood urea, serum creatinine, urinary NAG, urinary protein, tissue MDA and tissue TNF- α with significant decrease in creatinine clearance, tissue GSH, tissue SOD and mitochondrial complex I activity compared to the control untreated group. These results were in agreement with those of Mora et al. [39], Karimi et al. [40], Li et al. [13] and İşeri et al. [41]. They attributed this significant increase in blood urea, serum creatinine, urinary NAG and urinary protein and the significant decrease in creatinine clearance to the decrease in glomerular filtration rate and renal blood flow and tubular necrosis.

Gemfibrozil is one of fibrates that increases the activity of peroxisome proliferator-activated receptor- α (PPAR- α), a receptor which is involved in the metabolism of carbohydrates and fats, as well as adipose tissue differentiation [13]. Daynes and Jones [42] suggested that PPAR plays an important role in the modulation of inflammatory responses. The role of PPAR- α in the control of inflammation was suggested from the observation that the inflammatory response induced by leukotriene B₄ was prolonged in PPAR- α deficient mice [43]. In another study, the administration of fibrates to patients with moderate hyperlipidemia decreased plasma concentrations of proinflammatory cytokines such as IL-6, TNF- α and acute-phase proteins [44].

Attallah et al. [45] had shown that prophylactic administration of statins, which also are considered as PPAR- α agonists, resulted in less contrast nephropathy in patients that received a contrast agent. On the other hand, Broeders et al. [46] showed that treatment with fenofibrate, bezafibrate, and ciprofibrate might induce renal dysfunction while gemfibrozil appeared to be an exception of this side-effect. Krey et al. [47] reported that gemfibrozil, in contrast to the other fibrates, fails to bind and activate peroxisome proliferator-activated receptors. These receptors, once bound by fibrates, down-regulate the expression of the inducible

cyclooxygenase-2 enzyme which may be the cornerstone for the maintenance of the vasodilator prostaglandins in the kidneys. In support of this hypothesis, clofibrate and ciprofibrate, but not gemfibrozil, were found to inhibit the production of the vasodilator prostaglandins [48,49].

In the present study, treatment of rats with gemfibrozil before cisplatin administration efficiently attenuated acute nephrotoxicity induced by cisplatin evidenced by significant decrease in blood urea, serum creatinine, urinary NAG, urinary protein, tissue MDA and tissue TNF- α with significant increase in creatinine clearance, tissue GSH, tissue SOD and mitochondrial complex I activity compared to cisplatin treated group. Also, there was reduction of the necrotic damage and induction of apoptosis assessed by renal histopathological examination.

These results were in agreement with those of Portilla et al. [50], Li et al. [12] and Li et al. [13] who attributed this significant improvement in the disturbed biochemical parameters and reduction of necrotic damage assessed by histopathological examination to that gemfibrozil is one of PPAR- α ligands which were shown to reduce the cisplatin-mediated increase in the inflammatory response and NF- κ B binding activity which results in suppression of NF- κ B-mediated target gene activation including cytokines (TNF- α , IL-6), adhesion molecules and enzymes (Inducible nitric oxide synthase and cyclooxygenase) [51,52]. PPAR- α ligands can also repress transcription of interleukin-6 promoter activity. So, PPAR- α interferes with different steps of the inflammatory response induced by cisplatin and prevents neutrophil infiltration, suggesting that this could represent a mechanism for cytoprotection in cisplatin-mediated nephrotoxicity.

Nagothu et al. [53] suggested that pretreatment with bezafibrate, one of PPAR- α ligands prevented both the inhibition of PPAR- α activity and the accumulation of nonesterified free fatty acids induced by cisplatin. Also, bezafibrate prevented cisplatin-induced release of cytochrome-C from the mitochondria to the cytosol.

Li et al. [12] suggested that PPAR- α ligands ameliorate cisplatin nephrotoxicity by inhibition of medium chain fatty acid oxidation and pyruvate dehydrogenase complex activity in the kidney tissue due to reduction of mRNA levels and enzyme activity of mitochondrial medium chain acyl-CoA dehydrogenase and pyruvate dehydrogenase complex.

Silymarin is a flavonoid that is used clinically to treat chronic inflammatory liver disease and hepatic cirrhosis. The hepatoprotective effect of silymarin can be attributed to its antioxidant properties by scavenging free radicals and increasing intracellular concentration of glutathione [54]. Silymarin also has anti-inflammatory properties that regulate inflammatory mediators such as TNF- α [8], nitrous oxide and interleukins [55]. Fortunately, Turgut et al. [15] observed that therapy with silibinin, the main constituent of silymarin, had no effect on renal functions of normal rats but improves renal functions in the diseased kidney.

In the present study, treatment of rats with silymarin before cisplatin administration efficiently attenuated acute nephrotoxicity induced by cisplatin evidenced by significant decrease in blood urea, serum creatinine, urinary NAG, urinary protein, tissue MDA and tissue TNF- α with significant increase in creatinine clearance, tissue GSH, tissue SOD and mitochondrial complex I activity compared

to cisplatin treated group. This was concomitant with reduction of the necrotic damage and induction of apoptosis assessed by histopathological examination.

These results were in agreement with those of Gaedeke et al. [56], Karimi et al. [40], Turgut et al. [15] and Abdel-Gawad and Mohamed [10]. They attributed this significant improvement in the disturbed biochemical parameters and reduction of necrotic damage to the anti-oxidant effect of silymarin and membrane-stabilizing properties that have already been proved in kidney cells challenged with a variety of radical-generating drugs. Silymarin may inhibit lipid peroxidation by scavenging free radicals and increasing intracellular concentration of glutathione. Soto et al. [57] reported that the protective effect of silymarin on pancreatic damage induced by alloxan may be due to an increase in the activity of antioxidant enzymes. Oliveira et al. [58] reported that silymarin protects liver against ischaemia/reperfusion injury by induction of the antioxidant enzyme system. In agreement with these previous studies, the present study observed that silymarin has antioxidant effect and protect kidney against cisplatin induced nephrotoxicity.

It was indicated that superoxide anions inactivate nitric oxide and that nitric oxide-dependent vascular relaxation is enhanced by superoxide dismutase. Silymarin maintained renal blood flow as a result of preserved nitric oxide through scavenging of the superoxide anions [59]. Manna et al. [8], Saliou et al. [60] and Toklu et al. [9] observed that silymarin has anti-inflammatory properties by blocking TNF- α -induced activation of the transcription factor NF- κ B.

Treatment of rats with silymarin simultaneously with gemfibrozil before cisplatin administration efficiently attenuated cisplatin nephrotoxicity as evidenced by significant decrease in blood urea, serum creatinine, urinary NAG, urinary protein, tissue MDA and tissue TNF- α with significant increase in creatinine clearance, tissue GSH, tissue SOD and mitochondrial complex I activity and significant reduction of tubular necrosis and cellular infiltration together with induction of apoptosis compared to the use of gemfibrozil or silymarin alone. The mechanism of this synergistic nephroprotective effect seems to be due to anti-inflammatory and antioxidant properties of the used drugs.

In conclusion, the results of this work indicated that the combination of gemfibrozil and silymarin had protective effects against cisplatin nephrotoxicity in rats better than each of these drugs alone. This might provide a basis for the development of novel therapeutic strategies for protection against damage caused by cisplatin administration.

Conflict of interest

There is no conflict of interest.

References

- [1] Parker MR, Willattes SM. A pilot study to investigate the effects of an infusion of aminophylline on renal function following major abdominal surgery. *Anaesthesia* 2001;7:670–5.
- [2] Molitoris BA, Sutton TA. Endothelial injury and dysfunction: role in the extension phase of acute renal failure. *Kidney International* 2004;66:496–9.
- [3] Tayem Y, Johnson TR, Mann BE, Green CJ, Motterlini R. Protection against cisplatin-induced nephrotoxicity by a carbon

- monoxide-releasing molecule. *American Journal of Physiology: Renal Physiology* 2006;290:F789–94.
- [4] Arany I, Safirstein RL. Cisplatin nephrotoxicity. *Seminars in Nephrology* 2003;23:460–4.
- [5] Liu X, Li J, Li Q, Ai Y, Zhang L. Protective effects of ligustrazine on cisplatin-induced oxidative stress, apoptosis and nephrotoxicity in rats. *Environmental Toxicology and Pharmacology* 2008;26(1):49–55.
- [6] Humanes B, Lazaro A, Camano S, Moreno-Gordaliza E, Lazaro JA, Blanco-Codesido M, et al. Cilastatin protects against cisplatin-induced nephrotoxicity without compromising its anticancer efficiency in rats. *Kidney International* 2012;82:652–63.
- [7] Davis CA, Nick HS, Agarwal A. Manganese superoxide dismutase attenuates cisplatin-induced renal injury: importance of superoxide. *Journal of the American Society of Nephrology* 2001;12:2683–90.
- [8] Manna SK, Mukhopadhyay A, Van NT, Aggarwal BB. Silymarin suppresses TNF-induced activation of NF- κ B, c-Jun N-terminal kinase, and apoptosis. *Journal of Immunology* 1999;163:6800–6800.
- [9] Toklu HZ, Tunali-Akbay T, Erkanli G, Yuksel M, Ercan F, Sener G. Silymarin, the antioxidant component of *Silybum marianum*, protects against burn-induced oxidative skin injury. *Burns* 2007;33:908–16.
- [10] Abdel-Gawad SK, Mohamed A. Silymarin administration protects against cisplatin-induced nephrotoxicity in adult male albino rats (Histological and Immunohistochemical Study). *Egyptian Journal of Histology* 2010;33(4):683–91.
- [11] Michalik L, Wahli W. Involvement of PPAR nuclear receptors in tissue injury and wound repair. *Journal of Clinical Investigation* 2006;116(3):598–606.
- [12] Li S, Wu P, Yarlagaadda P, Vadjunec NM, Proia AD, Harris RA, et al. PPAR α ligand protects during cisplatin induced acute renal failure by preventing inhibition of renal FAO and PDC activity. *American Journal of Physiology: Renal Physiology* 2004;286:F572–80.
- [13] Li S, Gokden N, Okusa MD, Bhatt R, Portilla D. Anti-inflammatory effect of fibrates protects from cisplatin-induced ARF. *American Journal of Physiology* 2005;289:469–80.
- [14] Calkin AC, Giunti S, Jandeleit-Dahm KA, Allen TJ, Cooper ME, Thomas M.C. PPAR- α and - γ agonists attenuate diabetic kidney disease in the apolipoprotein E knockout mouse. *Nephrology, Dialysis, Transplantation* 2006;21(9):2399–405.
- [15] Turgut F, Bayrak O, Catal F, Bayrak R, Atmaca AF, Koc A, et al. Antioxidant and protective effects of silymarin on ischemia and reperfusion injury in the kidney tissues of rats. *International Urology and Nephrology Journal* 2008;40(2):453–60.
- [16] Salant DJ, Ybulsky AV. Experimental glomerulonephritis. *Methods in Enzymology* 1988;162:421–61.
- [17] Price RJ. Urinary N-acetyl- β -D-glucosaminidase (NAG) as an indicator of renal disease. *Current Problems in Clinical Biochemistry* 1979;9:150–63.
- [18] Henry RJ. Determination of serum creatinine. In: *Clinical chemistry principles and techniques*. 2nd ed. Hagerstown, MD, USA: Harper and Row; 1974. p. 525.
- [19] Patton CJ, Crouch SR. Spectrophotometric and kinetic investigation of the Berthelot reaction for the determination of ammonia. *Analytical Chemistry* 1977;49:464–9.
- [20] Cockcroft DW, Gault MH. Prediction of creatinine clearance from serum creatinine. *Nephrology* 1976;16(1):31–41.
- [21] Hammersen F, editor. *Histology*. Munich: Urban and Schwarzenberg; 1985. p. 1–4.
- [22] Ohkawa H, Ohishi N, Yagi K. Assay for lipid peroxides in animal tissues by thiobarbituric acid reaction. *Analytical Biochemistry* 1979;95:351–8.
- [23] Marklund S, Marklund G. Involvement of the superoxide anion radical in the autooxidation of pyrogallol and convenient assay for superoxide dismutase. *European Journal of Biochemistry* 1974;47:469–74.
- [24] Beutler E, Durom O, Kelly BM. Improved method for the determination of blood glutathione. *Journal of Laboratory and Clinical Medicine* 1963;61:882–8.
- [25] Lowry OH, Rosebrough NJ, Farr AL, Randall RJ. Protein measurement with Folin phenol reagent. *Journal of Biological Chemistry* 1951;193:265–75.
- [26] Turpeenoja L, Villa R, Magri G, Stella G. Changes of mitochondrial membrane proteins in rat cerebellum during aging. *Neurochemical Research* 1988;13:859–65.
- [27] Birch-Machin MA, Briggs HL, Saborido AA, Bindoff LA, Turnbull DM. An evaluation of the measurement of the activities of complexes I–IV in the respiratory chain of human skeletal muscle mitochondria. *Biochemical Medicine and Metabolic Biology* 1994;51(1):35–42.
- [28] Staunton MJ, Gaffney EF. Tumor type is a determinant of susceptibility to apoptosis. *American Journal of Clinical Pathology* 1995;103:300–7.
- [29] Gonzalez R, Borrego A, Zamora Z, Romay C, Hernandez F, Menéndez S, et al. Reversion by ozone treatment of acute nephrotoxicity induced by cisplatin in rats. *Mediators of Inflammation* 2004;13:307–12.
- [30] Ramesh G, Reeves WB. P38 MAP kinase inhibition ameliorates cisplatin nephrotoxicity in mice. *American Journal of Physiology: Renal Physiology* 2005;289:F166–74.
- [31] Price PM, Safirstein RL, Megyesi J. Protection of renal cells from cisplatin toxicity by cell cycle inhibitors. *American Journal of Physiology: Renal Physiology* 2004;286:F378–84.
- [32] Shimeda Y, Hirotani Y, Akimoto Y, Shindou K, Ijiri Y, Nishihori T, et al. Protective effect of capsaicin against cisplatin-induced nephrotoxicity in rats. *Biological and Pharmaceutical Bulletin* 2005;28:1635–8.
- [33] Behling EB, Sendao MC, Francescato HDC, Antunes LMG, Costa RS, Bianchi MP. Comparative study of multiple dosage of quercetin against cisplatin-induced nephrotoxicity and oxidative stress in rat kidneys. *Pharmacological Research* 2006;58:526–32.
- [34] Bonventre JV. Pathophysiology of ischemic acute renal failure. Inflammation, lung–kidney cross-talk, and biomarkers. *Contributions to Nephrology* 2004;144:19–30.
- [35] Friedewald JJ, Rabb H. Inflammatory cells in ischemic acute renal failure. *Kidney International* 2004;66:486–91.
- [36] Luke DR, Vadie K, Lopez-Berestein G. Role of vascular congestion in cisplatin-induced acute renal failure in the rat. *Nephrology, Dialysis, Transplantation* 1992;7:1–7.
- [37] Cetin R, Devrim E, Kilicoglu B, Avei A, Candir O, Durak I. Cisplatin impairs antioxidant system and causes oxidation in rat kidney tissues: possible protective roles of natural antioxidant foods. *Journal of Applied Toxicology* 2006;26:42–6.
- [38] Ajith TA, Usha S, Nivitha V. Ascorbic acid and α -tocopherol protect anticancer drug cisplatin induced nephrotoxicity in mice: a comparative study. *Clinica Chimica Acta* 2006;375:82–6.
- [39] Mora L, Antunes LM, Francescato HD, Bianchi M. The effects of oral glutamine on cisplatin-induced nephrotoxicity in rats. *Pharmacological Research* 2003;47:517–22.
- [40] Karimi G, Ramezani M, Tahoorian Z. Cisplatin nephrotoxicity and protection by milk thistle extract in rats. *Evidence-Based Complementary and Alternative Medicine* 2005;2(3):383–6.
- [41] İşeri S, Ercan F, Gedik N, Yüksel M, Alican İ. Simvastatin attenuates cisplatin-induced kidney and liver damage in rats. *Toxicology* 2006;230:256–64.
- [42] Daynes DC, Jones RA. Emerging roles of PPARs in inflammation and immunity. *Nature Reviews Immunology* 2002;2:748–59.
- [43] Duval C, Fruchart JC, Staels B. PPAR, fibrates, lipid metabolism and inflammation. *Archives des Maladies du Coeur et des Vaisseaux* 2004;97:665–72.
- [44] Despres JP, Lemieux I, Pascot A, Almeras N, Dumont M, Nadeau A, et al. Gemfibrozil reduces plasma C-reactive protein levels in abdominally obese men with the atherogenic dyslipidemia of the metabolic syndrome. *Arteriosclerosis, Thrombosis, and Vascular Biology* 2003;23:702–3.
- [45] Attallah N, Yassine L, Musial J, Yee J, Fisher K. The potential role of statins in contrast nephropathy. *Clinical Nephrology* 2004;62:273–8.
- [46] Broeders N, Knoop C, Antoine M, Tielemans C, Abramowicz D. Fibrate-induced increase in blood urea and creatinine: is

- gemfibrozil the only innocuous agent? *Nephrology, Dialysis, Transplantation* 2000;15:1993–9.
- [47] Krey G, Braissant O, Horset F. Fatty acids, eicosanoids and hypolipidemic agents identified as ligands of peroxisome proliferators by coactivator-dependent receptor ligand assay. *Molecular Endocrinology* 1999;11:779–91.
- [48] Ledwith BJ, Pauley CJ, Wagner LK, Rokos CL, Alberts DW, Manam S. Induction of cyclooxygenase-2 expression by peroxisome proliferators and non-tetradecanoylphorbol 12, 13-myristate-type tumor promoters in immortalized mouse liver cells. *Journal of Biological Chemistry* 1997;272:3707–14.
- [49] Yoshinari M, Asano T, Kaori S, Shi AH, Wakisaka M, Iwase M, et al. Effect of gemfibrozil on serum levels of prostacyclin and precursor fatty acids in hyperlipidemic patients with type 2 diabetes. *Diabetes Research and Clinical Practice* 1998;42:149–54.
- [50] Portilla D, Dai G, McClure T, Bates L, Kurten R, Megyesi J, et al. Alterations of PPAR alpha and its coactivator PGC-1 in cisplatin-induced acute renal failure. *Kidney International* 2002;62:1208–18.
- [51] Delerive P, De Bosscher K, Besnard S, Vanden Berghe W, Peters JM, Gonzalez FJ, et al. Peroxisome proliferator-activated receptor alpha negatively regulates the vascular inflammatory gene response by negative cross-talk with transcription factors NF- κ B and AP-1. *Journal of Biological Chemistry* 1999;274:32048–54.
- [52] Vanden Berghe W, Vermeulen L, Delerive P, De Bosscher K, Staels B, Haegeman G. Paradigm for gene regulation: inflammation, NF- κ B and PPAR. *Advances in Experimental Medicine and Biology* 2003;544:181–96.
- [53] Nagothu K, Bhatt R, Kaushal G, Portilla D. Fibrate prevents cisplatin-induced proximal tubule cell death. *Kidney International* 2005;68(6):2680–93.
- [54] Zhao B. Natural antioxidants for neurodegenerative diseases. *Molecular Neurobiology* 2005;31:283–94.
- [55] Tager M, Dietzmann J, Thiel U, Hinrich Neumann K, Ansorge S. Restoration of the cellular thiol status of peritoneal macrophages from CAPD patients by the flavonoids silibinin and silymarin. *Free Radical Research* 2001;34:137–51.
- [56] Gaedeke J, Fels LM, Bokemeyer C, Mengs U, Stolte H, Lentzen H. Cisplatin nephrotoxicity and protection by silibinin. *Nephrology, Dialysis, Transplantation* 1996;11(1):55–62.
- [57] Soto C, Recoba R, Barron H, Alvarez C, Favari L. Silymarin increases antioxidant enzymes in alloxan-induced diabetes in rat pancreas. *Comparative Biochemistry and Physiology Part C: Toxicology & Pharmacology* 2003;136:205–12.
- [58] Oliveira CP, Lopasso FP, Laurindo FR, Leitao RM, Laudanna AA. Protection against liver ischemia-reperfusion injury in rats by silymarin or verapamil. *Transplantation Proceedings* 2001;33:3010–4.
- [59] Modlinger PS, Wilcox CS, Aslam S. Nitric oxide, oxidative stress, and progression of chronic renal failure. *Seminars in Nephrology* 2004;24:354–65.
- [60] Saliou C, Valacchi G, Rimbach G. Assessing bioflavonoids as regulators of NF- κ B activity and inflammatory gene expression in mammalian cells. *Methods in Enzymology* 2001;335:380–6.