901-46 Principal Component Analysis of Repolarization: A Novel Index of Complexity of Ventricular Repolarization in the Long QT Syndrome

Silvia G. Priori, Carlo Napolitano, Livia Diehl, Vincenzo Paganini, Maurizio Fumagalli, David Mortara, Peter J. Schwartz. *Clin Med Gen, Univ of Milan, Cardiology, Univ of Pavia, Italy*

It is well known that dishomogeneous repolarization is arrhythmogenic; however techniques to quantify complexity of repolarization are scanty. Principal components analysis is a method to assess the degree of correlation between a family of waveforms. When applied to T waves, it defines the components of repolarization. Usually, the first component accounts for most of repolarization, whereas a dishomogeneous repolarization is indicated by a relevant contribution of the second and other components. We applied principal component analysis to algorithmically defined JT intervals in 491 ECG recordings obtained during 12-leads Holter monitoring (Mortara Inst.), in controls (ctrls;n = 8) and in Long QT Syndrome pts (LQTS:n = 13). A mean of 24 ± 3 ECG traces taken hourly during monitoring were used for each subject. The second/first component ratio (complexity) was 17 ± 5% in ctrls and 41 ± 15% in LQTS ($p < 0.001$). Dynamic measurement of JT interval complexity showed that in LQTS the 24 hrs Standard Deviation of second component was much higher than in control individuals (3 vs 13%; $p < 0.001$). For LQTS, multiple regression analysis showed no correlation between complexity of T wave and QTc interval or QTc dispersion. These data show that principal component analysis identifies large differences between LQTS and ctrls. LQTS pts present a higher complexity of repolarization and a larger circadian variability. This new index of dishomogeneity of ventricular repolarization is observer-independent and provides novel information not redundant with QT and QT dispersion.

ECHOCARDIOGRAPHY – NEW INSTRUMENTATION

901-47 Dynamic 3-Dimensional Echocardiographic Reconstruction of the Left Ventricle Using Color Doppler Myocardial Tissue Imaging Technique. In Vivo Experimental and Clinical Study

José Azevedo, Miguel Garcia-Fernandez, Pablo Puerta, Mar Moreno, Daniel SanRoman, Esteban Torrecilla, Esteban Lopez de Sa, Jose Vallejo, Juan Luis Delcan. *Laboratorio de Ecocardiografia, Servicio de Cardiologia, Hospital Universitario "Gregorio Marañon", Madrid, España*

Color Doppler Tissue Imaging (DTI) of the left ventricle (LV) is a recently developed technique with lower attenuation from the chest wall. Transthoracic (TTE) three-dimensional echocardiography (3-DE) is a non invasive technique that quantitates volumetric and functional data of the LV cavity. The aim of our study was to apply the new color DTI technique to a 3-DE computerized reconstruction methodology in order to obtain dynamic 3-DE images of the LV and to calculate volumetric and functional data. Using a TTE approach, first we performed an "in vivo" experimental study in a open chest pig model (n = 8). Than we applied this same TTE methodology in a clinical setting, in 25 pts with a variety of cardiovascular pathologies. The 2-DE images were then transferred to a conventional computer with 3-DE capabilities and a dedicated software with a polyhedral surface algorithm. LV volumes were calculated at end systole (ESVol/ml), endiastole (EDVol/ml) as well as the derived stroke volume (StVol/ml) and ejection fraction (LV% EF/%). LV parameters were calculated using both conventional TTE 3-DE and color DTI 3-DE. Mean values of these parameters, intra- (ObVar/%) and inter-observer variability (IOb Var/%) were obtained and are showed in the following chart:

	ESVol	EDVol	StVol	LV%EF	IObVar	ObVar
TTE 3-DE	92 ± 21	188 ± 25	96 ± 16	51 ± 10	9 ± 6	8 ± 4
DTI 3-DE	95 ± 20	194 ± 23	99 ± 16	51 ± 10	6 ± 4	4 ± 3
% Var	3%	4%	3%	1%	–	–
p Value	ns	ns	ns	ns		

We conclude that three-dimensional echocardiographic reconstruction of the left ventricle can be performed using the new color Doppler tissue imaging technique of the myocardial wall. The color Doppler three-dimensional reconstruction technique is done with a lower intra- and inter-observer variability for both ventricular volumetric and functional data.

901-48 Assessment of Transmural Velocity Gradients in Hypertrophic Hearts-A New Diagnostic Index for Hypetrophic Cardiomyopathy

Przemyslaw Palka, Aleksandra Lange, Alan D. Fleming, Lynn N. Fenn, Thomas R.D. Shaw, Ian R. Starkey, Keith A.A. Fox, W. Norman McDicken, George R. Sutherland. *University of Edinburgh, UK*

The aim of the study was to use Doppler myocardial imaging for the assessment of intramural function to subdivide patients with different aetiologies of left ventricular (LV) hypertrophy. Thus, we studied 19 subjects with hypertrophic cardiomyopathy (HCM), 21 with LV hypertrophy due to hypertension (HTN) and 25 age matched (mean 51 ± 11 years) normal subjects (N). The velocity gradient (VG) across the LV posterior wall was measured during the following sequential phases of the cardiac cycle: ventricular ejection (VE), isovolumic relaxation (IR), rapid ventricular filling (RVF) and atrial contraction (AC). *Results:* are expressed as mean ± SD ($cm/s^{-1}/cm^{-1}$).

	VE	IR	RVF	AC
HCM	−1.9 ± 1.5*†	−1.1 ± 0.7‡	1.5 ± 0.9*†	2.0 ± 0.9‡§
HTN	4.5 ± 2.0	−1.0 ± 0.5‡	3.8 ± 1.8	3.1 ± 1.4
N	5.0 ± 2.3	−0.5 ± 0.4	4.1 ± 1.6	2.8 ± 1.4

*$p < 0.001$ vs. N; †$p < 0.001$ vs. HTN; ‡$p < 0.05$ vs. N; §$p < 0.05$ vs. HTN.

In HCM hearts, during VE, RVF and AC, the VG was significantly lower then in HTN patients and N. During these phases despite the presence of hypertrophied myocardium in the HTN group there was no difference in VG when compared to the non-hypertrophied myocardium in N. *Conclusions:* These findings suggest that VG measurement should prove to be a useful new diagnostic index which consistently identifies HCM patients within the spectrum of hypertrophied myocardium.

901-49 Harmonic Imaging and Single Frame "Triggered Mode" Data Acquisition Enhance Delineation of Myocardial Perfusion Defects by Volume-Rendered 3-Dimensional Echocardiography

Qi-Ling Cao, Navroz Masani, Alain Delabays, Giuseppina Magni, Philippe Acar, Cleo Laskari, Jiefen Yao, Stefano De Castro, Natesa Pandian. *Tufts-New England Medical Center, Boston, Mass*

Voxel-based 3-D echocardiography (3DE) can aid in accurate measurement of myocardial (contrast) perfusion defects. Ultrasound energy may reduce the "lifespan" of microbubbles attenuating the 3DE contrast defect. Triggered mode (TR) is a new way of image acquisition in which ultrasound energy is emitted and received for a single frame at specified time-point in the cardiac cycle. We examined whether TR enhances 3DE depiction of perfusion defects with both conventional (C) and harmonic (H) imaging. After coronary occlusion in 11 dogs, contrast 3DE was performed using both intravenous (IV) and aortic injections (AO) of 3 agents (FS069, Levovist and EchoGen). 3DE data was acquired (rotational method) using a H imaging scanner with a 2.5/5 MHz emit/receive transducer (Hewlett-Packard), designed to function in TR. Reconstructed 3D images were analyzed in 10 paraplane slices in each dog. *Results:* after 3DE with C imaging, AO but not IV defects could be visualized. Using H imaging both IV and AO defects were clearly visible but their borders could not be demarcated. The addition of TR (end-diastolic frame) to H imaging further enhanced delineation of defects permitting quantitation of the hypoperfused myocardial mass (range: 11.4 to 21 gms). From the IV approach 9/11 defects were accurately delineated using TR compared with 2/11 with non-TR ($p < 0.005$, Fishers exact). Further, the transmural extent of contrast defects could be seen. We conclude that TR is ideally suited to contrast 3DE by IV injections and, with harmonic imaging, enhances accurate depiction of contrast defects.

ECHOCARDIOGRAPHY – TRANSESOPHAGEAL IMAGING/DOPPLER

901-50 Mitral Regurgitant Jet Impingement Promotes the Reduction of Systolic Pulmonary Venous Flow: Computer Simulations

Randall Y. Grimes, Robert A. Levine, Maurice E. Sarano, Ajit P. Yoganathan. *Georgia Institute of Technology, Atlanta, GA; Mayo Clinic, Rochester, MN; Massachusetts General Hospital, Boston, MA*

Recent studies have demonstrated that pulmonary venous (PV) flow is only partially dependent on the degree of mitral regurgitation (MR). The role of local factors and in particular, perivenous jet impingement is not well know. Fluid dynamics informs us that as a jet impinges on a wall, its momentum is recovered as pressure. However it is unknown how close the jet must impinge

before it has a local effect on PV flow. *Methods:* Using an elastance model of the atrium and PV tree, (previously demonstrated to reliably reproduce PV flow), mitral regurgitation was simulated (regurgitant volume = 16 cc). Using equations from fluid mechanics that describe the spatial distribution of pressure recovery created as a jet impinges on a wall, the distance between the jet impact site and a given PV was varied from 4 to 0.5 cm and systolic PV flow was plotted. *Results:* Without regurgitation, the model generated systolic PV flow consistent with clinical measurements. With regurgitation, systolic PV velocity was reduced. At 4 and 1 cm impingement distances, the effect was minimal, but at 0.75–0.5 cm, PV flow rapidly became diminished and reversed.

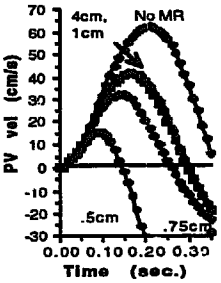

Conclusions: Pressure is recovered in a small disk around the site of jet impingement. If the jet impinges > 1 cm from a PV, it has no local effect. For impingement at < 1 cm, the local pressure is significantly higher than the global pressure and systolic PV flow in that vein is markedly reduced. Therefore, local perivenous jet interactions may explain, in part, the wide clinical variations in PV flow that are observed for comparable grades of MR.

901-51 Should All Patients With Unexplained Cerebral Ischemia Undergo Transesophageal Echocardiography?

Harald Lethen, Rainer Hoffmann, Ulrich Sliwka[1], Johannes Noth[1], Frank P. Job, Frank A. Flachskampf, Peter Hanrath. *Med. Clinic I, RWTH Aachen, Germany;* [1] *Dept. Neurology, RWTH Aachen, Germany*

Transesophageal echo (TEE) has shown higher sensitivity for detecting potential cardiac sources of embolism than transthoracic echo (TTE) and is therefore routinely performed in patients (pts) with cerebral ischemia if a cardiac source of embolism is suspected. However, compared to TTE it has not been clearly defined in which patients with suspected cardiogenic embolism TEE findings alter patient management and if there are subgroups of pts which benefit more from TEE than others. We prospectively studied 210 pts with suspected cardiogenic cerebral ischemia with transthoracic and biplane transesophageal contrast echo. Additional pathologic findings by cTEE regarding spontaneous echo contrast (SEC), LA/LV-Thrombi (TH), patent foramen ovale (PFO), atrial septal aneurysm and defect (ASA, ASD) and complex aortic atheroma (CAA) were compared with pts in sinus rythm (SR) showing completely normal cTTE (NORM) and with pts with atrial fibrillation or pathologic finding by cTTE (PATH). *Results:* cTEE, findings in NORM/PATH:

	n	SEC	PFO/ASD	ASA	TH	CAA
NORM	90	1 (1%)	6 (7%)	1 (1%)	0 (0%)	3 (3%)
PATH	115	18 (15%)	6 (5%)	12 (10%)	8 (7%)	3 (3%)
p value		< 0.01	n.s.	< 0.01	< 0.01	n.s.

All PFO detected in NORM showed only small shunts and pt management was not influenced by cTEE in this group.

Conclusion: Additional value and influence on further pt management of cTEE is small if cTTE shows completely normal results in pts with SR (NORM) compared to PATH.

901-52 Positive and Negative Effects of Transesophageal Echocardiography on the Duke Criteria for Infective Endocarditis

Matthew T. Roe, Murray Abramson, Daniel J. Sexton, Jennifer Li, G. Ralph Corey, Sheila K. Heinle, Joseph Kisslo. *Duke University Medical Center, Durham, NC*

To test the added effect of transesophageal echo (TEE) for the diagnosis (DX) of infective endocarditis (IE) by the Duke Criteria (DC), records of 68 patients (original cohort) with transthoracic (TTE) and TEE performed within 7 days of initial evaluation for IE were reviewed. The new DC for diagnosing IE were developed incorporating TTE findings as a major criterion. Results were positive (oscillating endocardial or valvular (V) mass lesions, intracardiac abscess or new partial dehiscence of a prosthetic V), suggestive (non-oscillating masses, nodular V thickening or new V fenestrations) or negative (none of the above). Definite, possible or rejected DX (Table) of IE were made on echo as well as multiple microbiologic and clinical findings (MBCF). As a result of TEE added to TTE (and MBCF), 13% (9/68) moved up a category, increasing sensitivity. Of these, 8 moved from possible to definite and 1 moved from rejected to possible. On the other hand, if TEE were used without TTE (and MBCF), 4% (3/68) would have dropped from definite to possible, a negative effect on sensitivity. These data indicate that TEE increases the sensitivity for positive DX of IE by the DC. The use of TEE data alone, however, does not appear indicated as it may have a negative effect on sensitivity.

	TEE	Definite (n = 45)	Possible (n = 19)	Rejected (n = 4)
Pos TTE	Positive	18	2	0
	Suggestive	1	2	0
	Negative	0	2	0
Sugg TTE	Positive	6	1	1
	Suggestive	3	1	0
	Negative	0	0	0
Neg TTE	Positive	12	3	0
	Suggestive	3	1	0
	Negative	3	8	2

ECHOCARDIOGRAPHY – TRANSTHORACIC IMAGING/DOPPLER

901-53 Acute Hemodynamic Benefit of Enhanced External Counterpulsation.

Krishnamurthy Suresh, Susan Simandl, William E. Lawson, John C.K. Hui, Tong Guo, Lynn Burger, Harry Soroff, Peter F. Cohn. *SUNY Health Sciences Center, Stony Brook, NY*

While the demonstrable clinical benefits of enhanced external counterpulsation (EECP) are thought to be hemodynamically mediated and analogous to the intra-aortic balloon pump (IABP), this has not been previously demonstrated. Using Doppler echocardiography of the descending aorta the acute effects of EECP on heart rate, systolic time velocity integral (STVI), and diastolic time velocity integral (DTVI) were studied in 10 outpatients at rest and during EECP. Results are expressed as mean ± standard deviation and compared using a paired two tailed t-test:

	Baseline	During EECP	p
HR (beats/min)	64.3 ± 6.8	69.2 ± 7.5	NS
STVI (cm)	14.2 ± 6.5	21.5 ± 8.7	< 0.05
DTVI (cm)	1.7 ± 1.5	8.3 ± 3.8	< 0.001
D/S TVI	0.17 ± 0.16	0.40 ± 0.11	< 0.001

Cardiac output increased on an average by *63%*, due primarily to an increased stroke volume. In addition, retrograde aortic diastolic flow increased by *135%*, reflecting effective diastolic augmentation. EECP thus has acute hemodynamic effects qualitatively similar to the IABP. Due to its additional action of increasing venous return, the effect of EECP on the cardiac output may be superior to the IABP.

901-54 Myocardial Contrast Versus Dobutamine Echocardiography as Predictors of Late Functional Recovery in Acute Myocardial Infarction Treated With Primary PTCA

Leonardo Bolognese, Daniele Rovai, Piergiovanni Buonamici, Giampaolo Cerisano, David Antoniucci, Giovanni Maria Santoro, Cecilia Marini, Alessandro Distante, Antonio L'Abbate, Pier Filippo Fazzini. *Division of Cardiology, Careggi Hospital, Florence, Italy; CNR Clinical Physiology, Pisa, Italy*

The aim of the study was to compare the ability of myocardial contrast echocardiography (MCE) and dobutamine echocardiography (DE) to predict late functional recovery in patients with acute myocardial infarction (AMI) treated with primary PTCA. Fourteen patients with AMI treated with successful PTCA (TIMI flow grade 3) underwent: a) MCE before and shortly after PTCA, b) DE for viability (3–5 days after the admission) and c) 2-D echo for the evaluation of regional wall motion after 1 month. MCE effect was scored as 0 (absent), 0.5 (intermediate) or 1 (homogeneous contrast effect). Regional wall motion was scored from 1 (normal) to 4 (dyskinesia) according to a 16 segments model. A segment was considered to be viable by DE when resting asynergy showed an improvement ≥ 1 grade. Before PTCA, all patients showed myocardial perfusion deficits which involved 30