



## Original article

# Modified Mathieu repair for failed surgery for hypospadias: Perimeatal-based flap with a subdermal vascular dartos pedicle



A.Z.M. Anwar\*, A. Hussein, A.M. Shaaban, M. Abdel-Malek

Department of Urology, Faculty of Medicine, El-Minia University, El-Minia, Egypt

Received 24 June 2014; received in revised form 3 August 2014; accepted 31 August 2014

## KEYWORDS

Penis;  
Hypospadias;  
Mathieu;  
Urethroplasty;  
Reoperation

## Abstract

**Objectives:** To present our experience with the use of modified Mathieu urethroplasty for failed hypospadias repair.

**Patients and methods:** Thirty-eight patients aged between 2 and 10 (mean 5) years underwent modified Mathieu urethroplasty for salvage hypospadias repair. Modifications included a wide subdermal vascular dartos pedicle attached to the perimeatal-based flap, running subcuticular urethral sutures and coverage of the urethroplasty using a redundant dartos flap. Twenty patients presented with complete dehiscence after previous hypospadias repair, while a coronal fistula was present in 18. The meatal position was coronal in 22 patients and anterior penile in 16. Twenty-six patients underwent a single operation and 12 underwent multiple operations. The urethral plate was supple in 28 patients but altered in 10. The length of the flap was  $\leq 20$  mm in 23 patients and  $\geq 20$  mm in 15.

**Results:** Follow-up ranged from 3 to 9 years (mean 64 months). Overall success was achieved in 31/38 patients (82%). Meatal stenosis occurred in one patient (3%), while urethrocutaneous fistulas developed in six (16%). A history of previous surgery for hypospadias, an altered urethral plate and associated distal stenosis were associated with an increased incidence of postoperative fistulas, whereas the meatal location and the length of the flap had no effect on fistula formation.

**Conclusions:** Our modified Mathieu urethroplasty proved to be excellent in repairing failed hypospadias surgery. However, a proper patient selection is mandatory to achieve satisfactory results.

© 2015 Pan African Urological Surgeons' Association. Production and hosting by Elsevier B.V. All rights reserved.

## Introduction

Major advances in hypospadias surgery have been achieved in the last few years, resulting in excellent outcomes of primary repair. However, the repair of hypospadias is not always a single-stage surgical procedure, and complications necessitating reoperation

\* Corresponding author.

E-mail address: [zakiuro67@yahoo.com](mailto:zakiuro67@yahoo.com) (A.Z.M. Anwar).

Peer review under responsibility of Pan African Urological Surgeons' Association.

<http://dx.doi.org/10.1016/j.afju.2014.08.008>

1110-5704/© 2015 Pan African Urological Surgeons' Association. Production and hosting by Elsevier B.V. All rights reserved.

**Table 1** Preceding hypospadias procedures.

Technique	Number
MAGPI	3
Mathieu	5
TIP	7
Island flaps	8
Unidentified	15
Total number	38

are common. Treatment of failed hypospadias repair represents a dilemma because of deficient penile skin, the presence of scarred tissue, a suboptimal blood supply and associated fistulas [1]. There is no universal technique for hypospadias reoperation. Instead, a technique that is most suitable for the local penile conditions must be selected. Local hairless penile skin is the best option for repair whenever available [2].

In 1932, Mathieu first introduced the meatal-based flap technique as a one-stage procedure for repairing distal hypospadias [3]. Since then, various modifications of the original technique have been reported. Rabinowitz was the first to use continuous subcuticular urethral closure together with Mathieu repair [4]. De Jong and Boemers left a perimeatal-based flap attached to the dartos tunica to bypass a long urethral gap [5]. The versatility of Mathieu urethroplasty as a primary [6–9] and salvage [10–14] operation for treating hypospadias has been confirmed in the literature.

In the present study, we extended the previous modifications to be used in conjunction with Mathieu repair for the treatment of failed hypospadias surgery. Our modified Mathieu urethroplasty included creation of a wide subdermal vascular dartos pedicle attached to the perimeatal-based flap. Urethroplasty was accomplished using running inverted subcuticular sutures, and the urethral suture lines were covered by fanning out the redundant dartos pedicle to cover the repair.

## Patients and methods

### Patient population

Between 2004 and 2010, 38 patients aged between 2 and 10 (mean 5) years underwent a modified Mathieu procedure for the repair of failed hypospadias surgery at our institution. Informed consent with a guarantee of confidentiality was obtained from the guardians of all our patients. The preceding hypospadias procedures are listed in Table 1.

The indication for reoperation was complete dehiscence after previous hypospadias repair in 20 patients. The remaining 18 patients had a coronal fistula which was separated from the meatus by a bridge of glandular tissue in 12 patients and was associated with distal stenosis in 6. In these patients, the previous repair was laid open, converting it into a coronal hypospadias. All patients had been circumcised. Only patients with sufficient ventral penile skin with excellent mobility and absence of any chordee or major scarred tissue were included in the study.

The meatal position was coronal in 22 patients and anterior penile in 16. Twenty-six patients had undergone a previous single-stage operation, while there was a history of multiple operations in 12.

The urethral plate was supplanted in 28 patients and altered in 10. The length of the flap was  $\leq 20$  mm in 23 patients and  $\geq 20$  mm in 15.

Preoperative testosterone treatment was used in all cases in the form of intramuscular injections at a dose of 2 mg/kg body weight. The injections were given two to three times before surgery at 3-week intervals. The time interval between the initial procedure and reintervention was at least 6 months.

### Surgical technique

Optical magnification (3 $\times$ ) was used during surgery in all cases. A tourniquet and bipolar diathermy were the methods of choice to achieve hemostasis. Polyglactin 7-0 sutures were used throughout. The preliminary skin incision and outlining of the perimeatal-based flap were done as reported in the literature [4].

Our modifications of the Mathieu repair procedure started with modified penile degloving. As the ventral shaft skin was dissected free from the perimeatal-based flap, the plane of dissection was modified to lie between the skin and the dartos fascia instead of being superficial to Buck's fascia. Thus, a wide subdermal vascular dartos pedicle attached to the perimeatal-based flap was created. Urethroplasty was performed using running inverted subcuticular 7-0 polyglactin sutures. The urethral suture lines were covered by fanning out the redundant dartos flap to cover the repair. Glanuloplasty and skin covering were performed as described in the literature [4]. A sterile dressing was applied and diversion was maintained using a urethral stent that was removed after 1 week. The modified Mathieu salvage procedure is illustrated in Fig. 1.

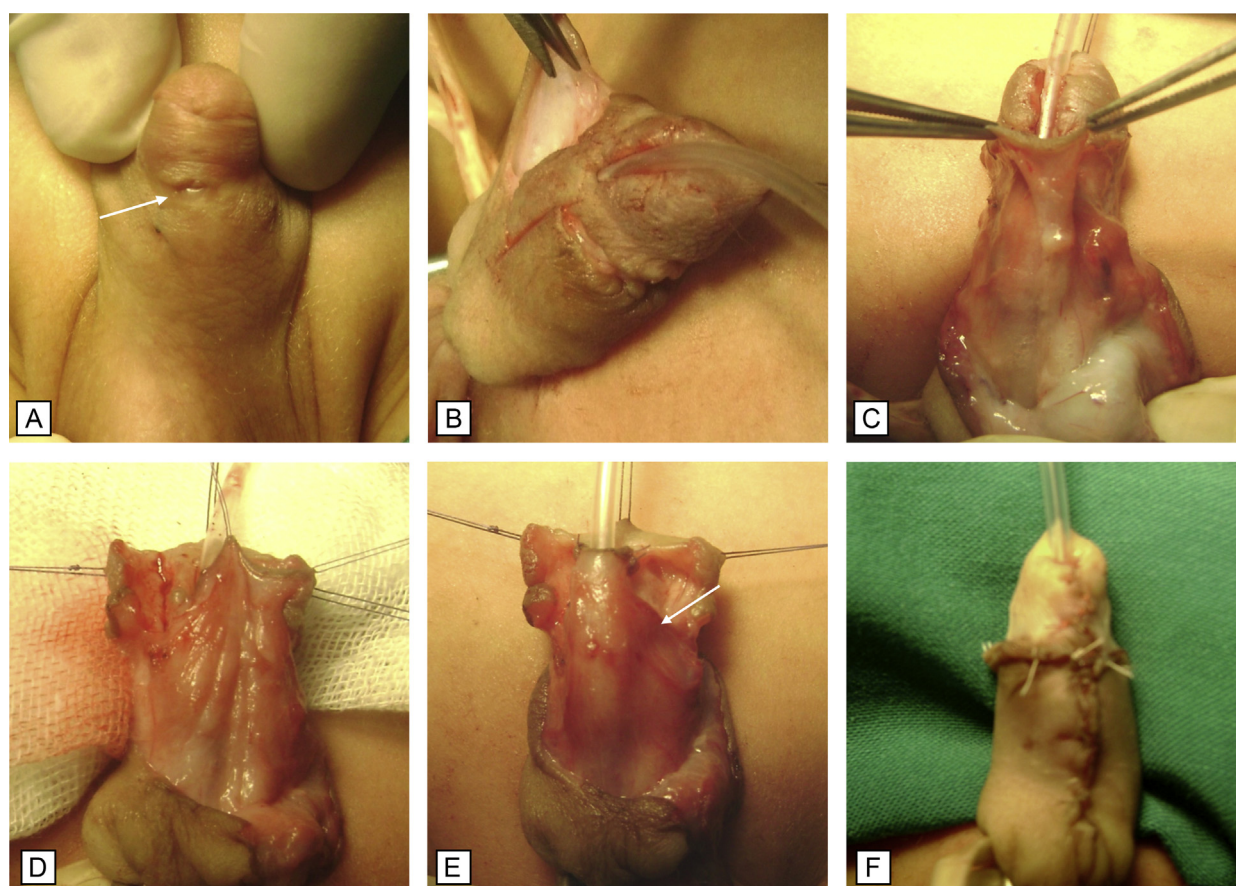
Follow-up visits were scheduled after 1, 3 and 6 months, and yearly thereafter. Cosmetic results were evaluated in terms of meatal position and appearance, glans configuration and overall genital appearance. Functional evaluation included observation of the urinary stream, meatal calibration and uroflowmetry in selected older patients.

## Results

Follow-up ranged from 3 to 9 years (mean 64 months). The overall cosmetic and functional results were excellent, also in the opinion of most of the boys' parents. However, 8/38 (21%) parents had concerns about the appearance of the meatus. The procedure proved to be successful in 31/38 (82%) patients. Meatal stenosis occurred in one patient (3%) and was relieved by external meatotomy. Urethrocutaneous fistulas developed in six patients (16%); the associated preoperative parameters are listed in Table 2.

## Discussion

There are conflicting opinions about decision-making in cases of failed hypospadias surgery. The optimal choice of a salvage procedure depends on the meatal position, the condition of the urethral plate, the quality and mobility of the genital skin and the presence or absence of chordee. Many surgical techniques are available for hypospadias reoperation including Mathieu repair [10–14], the Snodgrass technique [15,16], onlay flaps [1,17] and grafts [18,19]. Basic surgical skills should be strictly applied also to salvage procedures; optical magnification is essential; tissue handling should be minimal; skin flaps should be created with special care, taking



**Figure 1** Modified secondary Mathieu urethroplasty. (A) Preoperative appearance showing a coronal fistula separated from the meatus by a bridge of glandular tissue; the arrow points to the fistula. (B) Skin design and modified degloving. (C) Perimeatal-based flap with a subdermal dartos pedicle dissected to the base of the penis. (D) Advancement of the flap. (E) Urethroplasty completed with fanning out of the redundant dartos pedicle to cover the suture lines. (F) Skin closure.

**Table 2** Preoperative parameters and postoperative fistula.

Patient's parameters	No. of patients	No. of fistula (%)
<b>Prior operation</b>		
One operation	26	2 (7.7)
Multiple operations	12	4 (33.3)
<b>Urethral plate</b>		
Supple	28	1 (3.6)
Altered	10	5 (50)
<b>Flap length</b>		
≤20 mm	25	2 (8)
≥20 mm	13	4 (30.8)
<b>Meatal position</b>		
Coronal	22	3 (13.6)
Anterior penile	16	3 (18.8)
<b>Preoperative urethral stenosis</b>		
Present	6	2 (33.3)
Absent	32	4 (12.5)

into consideration their blood supply, and bipolar diathermy should be used with caution [1].

In the literature, there is some controversy as to the use of the Mathieu repair technique as a salvage procedure [2,10–14]. Secret

et al. [2] pointed out that certain conditions encountered after failed hypospadias, such as impaired vascularity, crossed suture lines and scarring, might impede the use of the Mathieu procedure as a salvage operation. However, this is not always the case, as a secondary perimeatal-based flap will have a good vascular supply following previous ventral transfer of the high-quality dorsal preputial skin during primary repair [20]. In the current study, we applied the modified Mathieu procedure in 38 patients who had undergone failed hypospadias surgery. All the patients had sufficient ventral penile skin and no major scars or chordee. Creation and mobilization of the secondary perimeatal-based flap was feasible. In addition, creation of a wide subdermal vascular dartos flap attached to the perimeatal-based flap ensured vascular integrity and allowed for longer flaps.

The reported success rate after salvage Mathieu repair varies from 53% [2] to 92% [10].

Teague et al. [20] reported a success rate of 89%; Hayashi et al. [10] attained the highest success rate of 92% in a small series of 13 boys. The largest series were presented by Emir and Erol [11] and Bar-Yosef et al. [12] who achieved success rates of 75% and 74% in 55 and 40 cases, respectively. Recently, Chen et al. [14] reported a 79% success with the use of a modified Mathieu procedure. In the present study, 38 patients underwent a modified Mathieu procedure

and success was achieved in 31 of them (82%); this is comparable to the aforementioned reports.

There are many variables affecting the success rate of secondary Mathieu repair including the number of previous operations [7,11,13], the length of the flap [7] and the type and size of sutures [7]. There is an inverse relation between the number of previous operations and the success rate of secondary Mathieu repair [7,11,13]. The use of monofilament sutures and 6-0 sutures provided significantly better results than multifilament and 5-0 sutures [7]. Flaps longer than 20 mm were associated with a higher incidence of fistula formation [7].

In the current study, we evaluated preoperative parameters in relation to the occurrence of a fistula. Multiple previous operations, an altered urethral plate and preoperative distal stenosis were associated with an increased incidence of postoperative fistulas, whereas the location of the meatus or flap length had no effect on fistula formation. In our modified Mathieu procedure, maintaining a subdermal vascular dartos pedicle attached to the perimeatal-based flap preserved the blood supply to the flap and allowed for longer flaps; similar observations were described in a previous report [5].

The use of a second layer of coverage after primary Mathieu repair is an important adjunct to prevent the occurrence of urethrocutaneous fistulas. Retik et al. [21] used a dorsal subcutaneous flap, while Yesildağ et al. [22] reported the use of a dartos patch support. However, in cases of failed hypospadias surgery, penile skin can be deficient and circumcision can make additional coverage difficult. In the current study, all the boys had been circumcised, so the subdermal dartos pedicle attached to the perimeatal-based flap ensured vascular integrity. In addition, the urethral suture lines were covered using a second layer of the fanned redundant dartos flap.

The cosmetic appearance of the penis after the Mathieu procedure may be suboptimal as the meatus may appear rounded with a “bucket handle” configuration. Modifications have been adopted to improve this problem, including hinging of the urethral plate [23] and the Mathieu and “V” incision sutured (MAVIS) technique [24]. In the present study, 21% of the parents had concerns about the postoperative appearance of the meatus as we did not yet apply the aforementioned modifications [23,24] for an improvement of the cosmetic outcome. Such modifications in conjunction with our modified Mathieu procedure will be evaluated in future studies.

The benefits of the use of parenteral administration of testosterone prior to hypospadias surgery have been documented. These include an increased glans circumference and penile length in addition to an improved vascularity, which are associated with trivial side effects [25,26]. The use of testosterone before attempting salvage hypospadias repair has been recommended by some authors as a method to improve local penile conditions [18,25,27], while others believe that another form of repair should be used, if the local penile tissue is inappropriate [12]. In the current study, we applied preoperative testosterone in all cases to increase glans and penile length and to improve vascularity. However, we did not measure pretreatment penile length or glans circumference. Data determining the exact preoperative penile and glans criteria before applying preoperative testosterone are still lacking, and for now the administration of testosterone depends on subjective assessment [27]. Recently, Gorduza et al. [28] published a paper discussing wound healing disorders following the use of preoperatively administered

androgens. Although it is a preliminary study on a small number of cases, it draws attention to possible complications. The authors suggest further prospective studies to define the optimal protocol of penile stimulation using androgens.

Postoperative urinary diversion after primary Mathieu urethroplasty has been a matter of debate. Rabinowitz [6] and Hakim et al. [29] reported similar results for stented versus unstented repair. Nevertheless, Buson et al. [30] reported an increased incidence of adverse events following unstented Mathieu repair. For salvage Mathieu urethroplasty, postoperative diversion has been used in most of the literature [10–14]. In the present study, we used urethral stenting in all cases in order to avoid postoperative edema and meatal obstruction. A large prospective study to evaluate salvage Mathieu urethroplasty without diversion still needs to be done.

One of the well-established techniques for redo hypospadias is tubularized incised plate (TIP) urethroplasty [15,16]. It provides very good functional and cosmetic results with reported success rates of 77% and 81%, respectively [15,16]. In our institute we use more than one technique for hypospadias reinterventions, including TIP and buccal mucosal graft. In the present study, we presented the modified Mathieu repair as an alternative good option with satisfactory results that are comparable to those of other techniques. Our selection criteria included patients with sufficient ventral skin, adequate mobility and no major scarring.

## Conclusions

Re-treatment of hypospadias repair needs surgical expertise and should be individualized according to the penile conditions of each patient. In our patient cohort the modified Mathieu repair procedure provided an excellent option for treating failed hypospadias repair. However, a proper patient selection is mandatory to achieve satisfactory results.

## Conflict of interest

None of the contributing authors has any conflict of interest, including specific financial interests or relationships and affiliations relevant to the subject matter or materials discussed in the manuscript.

## References

- [1] Jayanthi VR, McLorie GA, Khoury AE, Churchill BM. Can previously relocated penile skin be successfully used for salvage hypospadias repair? *J Urol* 1994;152:740–3.
- [2] Secrest CL, Jordan GH, Winslow BH, Horton CE, McCraw JB, Gilbert DA, et al. Repair of the complications of hypospadias surgery. *J Urol* 1993;150:1415–8.
- [3] Mathieu P. Traitement en un temps de l'hypospadias balanique ou juxtabalanique. *J Chir* 1932;39:481–6.
- [4] Rabinowitz R. Outpatient catheterless modified Mathieu hypospadias repair. *J Urol* 1998;138:1074–6.
- [5] De Jong TP, Boemers TM. Improved Mathieu repair for coronal and distal shaft hypospadias with moderate chordee. *Br J Urol* 1993;72:972–4.
- [6] Gonzales ET, Veeraraghavan KA, Delaune J. The management of distal hypospadias with meatal-based vascularized flaps. *J Urol* 1983;129:119–20.
- [7] Uygur MC, Erol D, Germiyanoglu C. Lessons from 197 Mathieu hypospadias repairs performed at a single institution. *Pediatr Surg Int* 1998;14:192–4.

- [8] Minevich E, Pecha BR, Wacksman JY, Sheldon CA. Mathieu hypospadias repair: experience in 202 patients. *J Urol* 1999;162:2141–3.
- [9] Wilkinson DJ, Farrelly P, Kenny SE. Outcomes in distal hypospadias: a systematic review of the Mathieu and tubularized incised plate repairs. *J Pediatr Urol* 2012;8:307–12.
- [10] Hayashi Y, Sasaki S, Kojima Y, Maruyama T, Tozawa K, Mizuno K, et al. Primary and salvage urethroplasty using Mathieu meatal-based flap-flap technique for distal hypospadias. *Int J Urol* 2001;8:10–6.
- [11] Emir L, Erol D. Mathieu urethroplasty as a salvage procedure: 20-year experience. *J Urol* 2003;169:2325–7.
- [12] Bar-Yosef Y, Binyamini J, Matzkin H, Ben-Chaim J. Salvage Mathieu urethroplasty: reuse of local tissue in failed hypospadias repair. *J Pediatr Urol* 2005;65:1212–5.
- [13] Karabulut A, Sunay M, Erdem K, Emir L, Erol D. Retrospective analysis of the results obtained by using Mathieu and TIP urethroplasty techniques in recurrent hypospadias repairs. *J Pediatr Urol* 2008;4:359–63.
- [14] Chen JB, Yang TQ, Luo YG, Wang H, Tang XM. Modified Mathieu urethroplasty for failed hypospadias repair. *Zhonghua Nan Ke Xue* 2013;19:923–6.
- [15] Nguyen MT, Snodgrass WT. Tubularized incised plate hypospadias re-operation. *J Urol* 2004;171:2404–6.
- [16] Snodgrass WT, Bush N, Cost N. Algorithm for comprehensive approach to hypospadias reoperation using 3 techniques. *J Urol* 2009;182:2885–92.
- [17] Emir L, Erol D, Kuyumcuoglu U, Germiyanoğlu C. Which procedure should be chosen as a salvage operation in anterior hypospadias cases, meatal-based or onlay island flap? A comparative analysis. *Pediatr Surg Int* 2004;20:460–3.
- [18] Amukele SA, Stock JA, Hanna MK. Management and outcome of complex hypospadias repair. *J Urol* 2005;174:1540–3.
- [19] Schwentner C, Gozzi C, Lunacek A, Rehder P, Bartsch G, Oswald J, et al. Interim outcome of the single stage inlay skin graft for complex hypospadias reoperation. *J Urol* 2006;175:1872–7.
- [20] Teague JL, Roth DR, Gonzales ET. Repair of hypospadias complications using the meatal-based flap urethroplasty. *J Urol* 1994;151:470–2.
- [21] Retik AB, Mandell J, Bauer SB, Atala A. Meatal based hypospadias repair with the use of dorsal subcutaneous flap to prevent urethrocutaneous fistula. *J Urol* 1994;152:1229–31.
- [22] Yesilda E, Tekant G, Sarimurat N, Buyukunal SN. Do patch procedures prevent complications of the Mathieu technique? *J Urol* 2004;171:2623–5.
- [23] Rich MA, Keating MA, Snyder HM, Duckett JW. Hinging the urethral plate in hypospadias meatoplasty. *J Urol* 1989;142:1551–3.
- [24] Boddy SA, Samuel BS. Mathieu and ‘V’ incision sutured (MAVIS) results in a natural glanular meatus. *J Pediatr Surg* 2000;35:494–6.
- [25] Gearhart JP, Jeffs RD. The use of parenteral testosterone therapy in genital reconstructive surgery. *J Urol* 1987;138:1077–80.
- [26] Luo CC, Lin JN, Chiu CH, Lo FS. Use of parenteral testosterone prior to hypospadias surgery. *Pediatr Surg Int* 2003;19:82–4.
- [27] Snodgrass W, Cost N, Nakonezny PA, Bush N. Analysis of risk factors for glans dehiscence after tubularized incised plate hypospadias repair. *J Urol* 2011;185:1845–51.
- [28] Gorduza DB, Gay CL, De Mattos E, Silva E, Demède D, Hameury F, et al. Does androgen stimulation prior to hypospadias surgery increase the rate of healing complications? A preliminary report. *J Pediatr Urol* 2011;7:158–61.
- [29] Hakim S, Mergurerian PA, Rabinowitz R, Shortliffe LD, McKenna PH. Outcome analysis of the modified Mathieu hypospadias repair: comparison between stented and unstented. *J Urol* 1996;156:836–8.
- [30] Buson H, Samiley D, Reinberg Y, Gonzalez R. Distal hypospadias repair without stents: is it better? *J Urol* 1994;151:59–60.