



International Journal of Surgery Case Reports

journal homepage: www.casereports.com

Report of a case with a spontaneous mesenteric hematoma that ruptured into the small intestine



Daichi Shikata^a, Hiroshi Nakagomi^{a,*}, Atsushi Takano^a, Takahiro Nakagomi^a, Hideki Watanabe^a, Masahiro Maruyama^a, Haruka Nakada^a, Atsushi Yamamoto^a, Kazushige Furuya^a, Masao Hada^a, Yoshiaki Miyasaka^a, Masao Omata^b, Toshio Oyama^c

^a Department of Surgery, Yamanashi Prefectural Central Hospital, Japan^b Internal Medicine, Yamanashi Prefectural Central Hospital, Japan^c Pathology, Yamanashi Prefectural Central Hospital, Japan

ARTICLE INFO

Article history:

Received 13 May 2016

Received in revised form 20 May 2016

Accepted 20 May 2016

Available online 24 May 2016

Keywords:

Spontaneous mesenteric hematoma

Anal bleeding

Ruptured into the jejunum

Etiology

ABSTRACT

INTRODUCTION: A spontaneous mesenteric hematoma is a rare condition. Furthermore, it is extremely rare that the mesenteric hematoma caused gastrointestinal bleeding with an unknown etiology. We experienced a case with a spontaneous mesenteric hematoma that ruptured into the jejunum.

PRESENTATION OF CASE: A 75-year-old man was referred to our hospital because of anal bleeding and anemia. Abdominal computed tomography (CT) showed a low density mass measuring 3.0 cm in diameter, including an enhanced spot. This finding suggested that a pseudo-aneurysm or mesenteric hematoma caused active bleeding into the jejunum. He underwent emergent laparotomy and partial resection of the jejunum and the mesentery including the tumor. A histological examination of the jejunum indicated no pathogenic findings causing active bleeding. And there were no findings suggesting the mesenteric aneurysm had developed.

The patient had no history related to the development of a mesenteric hematoma, such as trauma, labor, surgery, or anticoagulant treatment. Therefore, we finally diagnosed that a spontaneous mesenteric hematoma had ruptured into the jejunum.

DISCUSSION AND CONCLUSION: We reported extremely rare condition that the mesenteric hematoma was developed and ruptured into the jejunum without definitive etiology.

© 2016 The Author(s). Published by Elsevier Ltd on behalf of IJS Publishing Group Ltd. This is an open access article under the CC BY-NC-ND license (<http://creativecommons.org/licenses/by-nc-nd/4.0/>).

1. Introduction

A spontaneous mesenteric hematoma is a rare condition that occurs due to localized bleeding in the mesenteric vascular tree of a bowel segment with an unknown etiology [1]. It was first reported in 1909 as a symptom associated with labor [2]. In the 20th century, 110 cases with a mesenteric hemorrhage in the literature were summarized [3]. The main cause of a mesenteric hemorrhage is trauma [4] including postoperative complications [5], and non-traumatic causes are considered to be caused by rupture of visceral artery aneurysm [6].

If these events were not identified in the personal history, clinical examination or examination of operative specimens, then a diagnosis of a “spontaneous” or “idiopathic” mesenteric hematoma can be made.

We herein report an operative case with a spontaneous mesenteric hematoma that ruptured into the small intestine. Although a

detailed pathological examination had been performed, the cause of mesenteric hematoma and penetration was not elucidated.

2. Presentation of case

A 75-year-old man consulted his general practitioner for sudden onset of anal bleeding and was referred to our hospital. He had no symptoms of abdominal pain or melena. He had been well with no medication and no allergies. He had taken an alcohol with 28 units/week, and a non-smoking. He had histories of duodenal ulcer and acute pancreatitis and no family history of bleeding diathesis.

Initial bloods examinations showed a hemoglobin level of 8.2 g/dl, white blood cells of $7.9 \times 100/L$, a platelet $132 \times 100/L$ and a normal amylase level. The patient was given 4 units in Japan, equivalent to 560 ml, of packed red blood cell transfusion. Nevertheless, the hemoglobin level decreased to 6.7 g/dl even after the blood transfusion.

Gastro-duodenal endoscopy and colonoscopy showed no findings causing anal bleeding. Contrast abdominal computed tomography (CT) revealed a low density mass measuring 3.0 cm in diameter suggested a hematoma or an aneurysm (Fig. 1). It

* Correspondence to: 1-1-1 Fujimi, Kofu, Yamanashi 400-8506, Japan.
E-mail address: h-nakagomi@ych.pref.yamanashi.jp (H. Nakagomi).

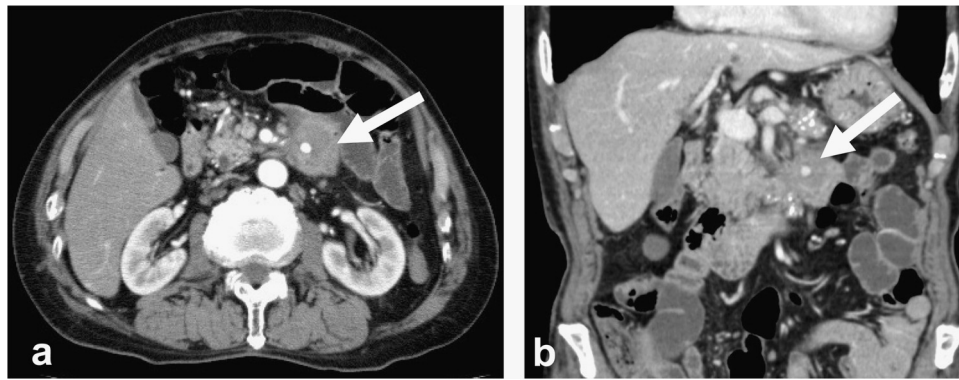


Fig. 1. Contrast-enhanced abdominal computed tomography (CT) indicated a low density mass measuring 3.0 cm in diameter, including an enhanced spot (arrow); (a) (transverse view) and (b) (coronal view).

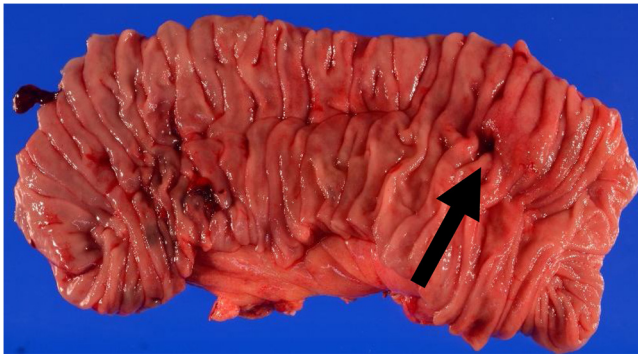


Fig. 2. Macroscopic finding of the resected jejunum. Black arrow indicated a pin hole penetrating to the hematoma.

was uncertain that the hematoma caused gastrointestinal bleeding. Therefore, we selected an emergent laparotomy rather than interventional mesenteric angiography and embolization. Exploratory findings were as follows, intraperitoneal hemorrhage was not seen, and the dilated jejunum containing bloods was associated with mesenteric tumor, indicated the relation of gastrointestinal bleeding with mesenteric tumor. We performed the partial resection of the jejunum accompanied with the mesentery including the hematoma-like tumor (Fig. 2).

The patient's postoperative course was uneventful and he was discharged 11 days after the operation. He has complained no symptoms of anal bleeding until now.

The histological examination of the jejunum indicated no pathogenic findings except for a mesenteric hematoma causing active bleeding. There were no findings, suggesting that mesenteric

aneurysm had developed (Fig. 3). Additionally, capsular formation with fibrous tissue and hemosiderin deposits around the hematoma were observed (Fig. 4), which indicated the chronic development of the hematoma.

The patient had no history related to the development of a mesenteric hematoma, such as trauma, labor, surgery, or anticoagulant treatment. Therefore, we finally diagnosed that a spontaneous mesenteric hematoma had ruptured into the jejunum.

3. Discussion and conclusion

A mesenteric hematoma is most frequently caused by trauma [4], including postoperative complications [5], and non-traumatic causes, which rarely occur in associated with mesenteric vascular disease such as aneurysm [7,8] and vasculitis [9]. A spontaneous (or idiopathic) mesenteric hematoma is diagnosed if any clinical and pathological findings were not seen during the development of this condition.

The potential causes of a spontaneous mesenteric hematoma include anticoagulant therapy [10,11], connective tissue disease [12], acute pancreatitis [13], and other diseases including Crohn's disease [14], duodenal stenosis [15], and incarcerated inguinal hernia [15]. There are a few reports of a spontaneous mesenteric hematoma without associated diseases.

However, the several compiled series of world literature for the mesenteric hematoma suggested bleeding vessels were not identified around 40% of cases at exploration [3,16]. We have possibility of missing to find bleeding vessels even in the pathological examinations.

Suzuki et al. reviewed 36 reported cases with spontaneous mesenteric hematoma in Japan [17]. The majority of patients were over 50 years of age. And the location of the hematoma is mesen-

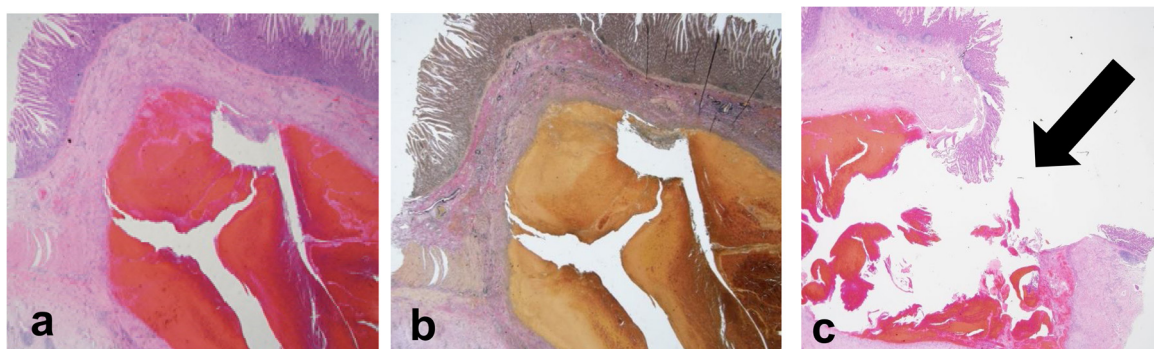


Fig. 3. Histological findings of mesentery. (a and c) Hematoxylin and eosin (HE), (b) Elastica van Gieson (EVG) staining. These pictures showed hematoma was developed under muscularis propria and subserosa. (c) Hematoma had ruptured into the lumen (arrow).

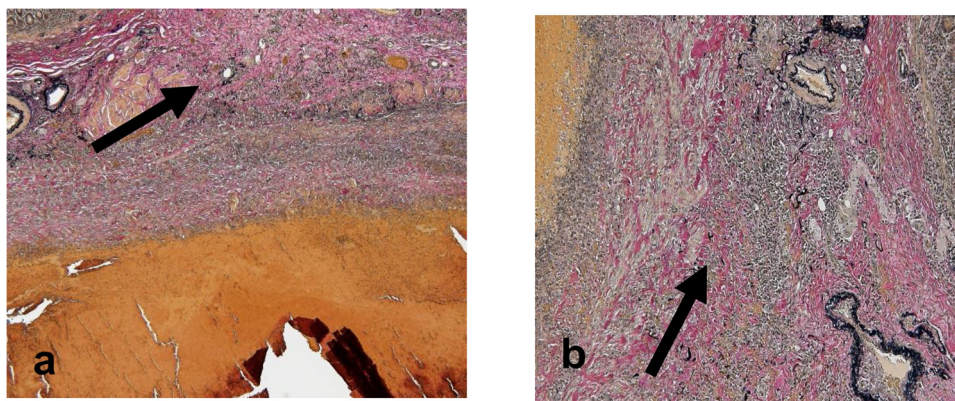


Fig. 4. The pathological findings by Elastica van Gieson (EVG) staining. The capsular formation by fibrous tissue (a) and hemosiderin deposits around the hematoma (b) (arrows) indicated the chronic development of a hematoma.

tery supplied by the superior mesenteric artery, inferior mesenteric artery or unknown in 61% (22/36), 19% (7/36) and 19% (7/36) of cases, respectively. There were no descriptions in the literatures for the patients developed gastrointestinal bleeding due to the mesenteric hematomas [3,16,17].

The symptoms varied and included abdominal pain, vomiting, abdominal mass, and hypotension due to bleeding. These symptoms are not specific for a mesenteric hematoma, thus we need to distinguish a hematoma from related disease with a mesenteric ischemia or intraperitoneal hemorrhage [18]. Intestinal bleeding found in this case is not a common symptom of the patients with mesenteric hematomas.

The hematoma is usually identified by CT, ultrasound, or MRI. If the hemorrhage is controlled, the patients can be treated by non-operative management [1]. However, the diagnosis for the hematoma may be difficult to confirm in some cases. In fact, 86% (31/36) of Japanese cases were operated due to the diagnosis of mesenteric tumor (such as mesenteric lymphangioma), abscess or aneurysm [17].

We could not find any previous reports on a mesenteric hematoma that ruptured into the small intestine as described before. The pathological findings of our case showed capsular formation by fibrous tissue and hemosiderin deposits around the hematoma, indicating the chronic development of a hematoma (Fig. 4). We speculated a mysterious, but interesting condition as follows, repeated hemorrhage increased the pressure of the hematoma enough to rupture into the small intestine. The pathological findings indicated no vulnerable sites of the small intestine related to perforation of the jejunum.

We concluded that a spontaneous mesenteric hematoma ruptured into the jejunum. The etiology of this condition was not revealed by detailed pathological examinations.

Conflict of interest

The authors declare no conflicts of interest.

Funding

We report no involvement of sponsors.

Ethical approval

The case report was approved by the institutional review board at Yamanashi Prefectural Central Hospital.

Consent

Written Informed Consent was obtained from the patient for publication of this case and any accompanying images. A copy of the written consent is available upon request.

Authors' contribution

DS, HN, MO and TO conceived of this case presentation and drafted the manuscript. AT, TN, HW, MM, HN, AY KF, MH, and YM participated in the treatment of this case. All authors read and approved the final manuscript.

Guarantor

Hiroshi Nakagomi and Masao Omata have accept full responsibility for this work and controlled the decision to publish.

Acknowledgement

The work has been reported in line with the CARE criteria.

References

- [1] S.G. Parker, Thompson, J.N., Spontaneous mesenteric haematoma; diagnosis and management, *BMJ Case Rep.* (2012) 1–3, <http://dx.doi.org/10.1136/bcr-2012-006624>.
- [2] M.C. Barber, Intra-Abdominal haemorrhage associated with labour, *Br. Med. J.* 2 (2534) (1909) 203–204.
- [3] C. Carmeci, N. Munfakh, J.W. Brooks, Abdominal apoplexy, *South. Med. J.* 91 (3) (1998) 273–274.
- [4] M.W. Meissnitzer, S. Stattner, T. Meissnitzer, Small mesenteric hematoma following blunt abdominal trauma as early sign in computed tomography of occult small bowel perforation—report of 2 cases, *Emerg. Radiol.* 21 (6) (2014) 647–650.
- [5] K.S. Karam, S.N. Hajj, Mesenteric hematoma—meckel's diverticulum: a rare laparoscopic complication, *Fertil. Steril.* 28 (9) (1977) 1003–1005.
- [6] P.A. Skudder Jr., W.L. Craver, Mesenteric hematoma suggests rupture of visceral artery aneurysm, *Arch. Surg.* 119 (7) (1984) 863.
- [7] Y. Gunduz, S. Sipahi, R. Kara, A. Tamer, A rare cause of intraabdominal hematoma: rupture of mesenteric artery branch aneurysm, *JBR-BTR* 96 (6) (2013) 354–356.
- [8] E.R. Garwood, A.S. Kumar, E. Hirvela, Spontaneous hemoperitoneum from a ruptured mesenteric branch arterial aneurysm: report of a case, *Surg. Today* 39 (8) (2009) 721–724.
- [9] B.A. Parent, S.W. Cho, D.G. Buck, M.A. Nalesnik, T.C. Gamblin, Spontaneous rupture of hepatic artery aneurysm associated with polyarteritis nodosa, *Am. Surg.* 76 (12) (2010) 1416–1419.
- [10] P. De Brito, M.A. Gomez, M. Besson, B. Scotto, D. Alison, Mesenteric hematoma: unusual complication of a long term oral anticoagulation therapy, *Ann. Chir.* 131 (9) (2006) 529–532.
- [11] A. Becker, Y. Berlin, J. Sayfan, Spontaneous rupture of mesenteric hematoma with hemorrhagic shock as a complication of oral anticoagulant treatment, *IMAJ* 1 (3) (1999) 196–197.

- [12] A. Hosaka, T. Miyata, H. Shigematsu, J.O. Deguchi, H. Kimura, H. Nagawa, O. Sato, T. Sakimoto, T. Mochizuki, Spontaneous mesenteric hemorrhage associated with Ehlers-Danlos syndrome, *J. Gastrointest. Surg.* 10 (4) (2006) 583–585.
- [13] T. Toyonaga, S. Nagaoka, K. Ouchida, M. Nagata, T. Shirota, T. Ogawa, J. Yoshida, M. Sinozara, K. Matuo, K. Sumitomo, M. Akao, Case of a bleeding pseudoaneurysm of the middle colic artery complicating acute pancreatitis, *Hepatogastroenterology* 49 (46) (2002) 1141–1143.
- [14] H. Ashrafian, J.H. Manfield, A. Mitra, D.J. Boyle, P. Mathur, Spontaneous mesenteric hematoma complicating an exacerbation of Crohn's disease: report of a case, *BMC Surg.* 14 (2014) 35.
- [15] E. Sutton, V. Emuakhagbon, V.M. Jones, K. McMasters, Spontaneous mesenteric hematoma associated with recurrent incarcerated inguinal hernia, *Am. Surg.* 81 (1) (2015) E3–5.
- [16] S.R. Carr, R.C. Dinsmore, N.W. Wilkinson, Idiopathic spontaneous intraperitoneal hemorrhage: a clinical update on abdominal apoplexy in the year 2001, *Am. Surg.* 67 (4) (2001) 374–376.
- [17] T. Suzuki, T. Okamoto, N. Funamizu, R. Ito, S. Fujioka, K.A. Yanaga, Case of spontaneous mesenteric hematoma of the small intestine, *J. Jap. Coll. Surg.* 39 (2014) 921–925.
- [18] C.Y. Tseng, Y.H. Chiu, J.L. Chuang, J.D. Chen, H.H. Huang, C.K. How, D.H. Yen, M.S. Huang, How to differentiate spontaneous intramural intestinal hemorrhage from acute mesenteric ischemia, *Am. J. Emerg. Med.* 31 (11) (2013) 1586–1590.

Open Access

This article is published Open Access at [sciencedirect.com](https://www.sciencedirect.com). It is distributed under the [IJSCR Supplemental terms and conditions](#), which permits unrestricted non commercial use, distribution, and reproduction in any medium, provided the original authors and source are credited.