

CASE REPORT

High-output Heart Failure Resulting from an Obscure Traumatic Arteriovenous Fistula

Chi-Feng Weng, Jeng Wei, Yung-Tsai Lee, Sung-How Sue, Yi-Cheng Chuang,
Chung-Yi Chang, Kuo-Chen Lee*

Division of Cardiovascular Surgery, Cheng Hsin Rehabilitation and Medical Center, Taipei, Taiwan, R.O.C.

Traumatic arteriovenous fistula (AVF) is not an uncommon disorder, but late discovery and the presentation of high-output heart failure is very rare. This patient did not know that he had traumatic AVF after a gunshot injury in the left thigh 14 years ago. The major presentation of the AVF was signs of heart failure. We performed surgical repair after making the diagnosis. The patient recovered with an uneventful course. This report stresses the importance of history-taking and physical examination in making the diagnosis of traumatic AVF. [*J Chin Med Assoc* 2008;71(8):428–430]

Key Words: arteriovenous fistula, heart failure, trauma

Introduction

Traumatic arteriovenous fistula (AVF) is one of the curable causes of congestive heart failure.¹ Although the history of trauma is clear, the development of AVF is insidious and sometimes not obvious; thus, the detection of shunt is crucial for treatment. We present a patient who suffered from gunshot injury complicated with traumatic AVF. The diagnosis of AVF was made 14 years after the injury, despite a history of congestive heart failure for 4 years.

Case Report

A 59-year-old man complained of effort dyspnea and heart palpitations of 10 years' duration. He had suffered from a penetrating gunshot injury in the left thigh 14 years ago; he had received no treatment except for dressing and wound compression. In the last 4 years, his symptoms had become exaggerated and he began to have orthopnea. He had been admitted to other hospitals under the impression of congestive heart failure and received repeated chest tapping for pleural effusion. Due to the uncontrollable heart failure, he was referred to our hospital for further

study. Echocardiography revealed cardiomegaly with 4-chamber dilatation (LVEDD, 67 mm; LVESD, 43 mm), moderate mitral regurgitation, and compromised left ventricular function (ejection fraction, 40%). The patient was treated with diuretics at the outpatient department. Two years before this admission, he had been admitted to our hospital for chest pain. Thallium-201 myocardial perfusion scans revealed ischemia over the inferior wall, anterior basal wall and inferior septum. The following coronary angiography was normal, but there was left-to-right shunt with Qp/Qs of 3.18. Magnetic resonance angiography (MRA) of the thorax did not reveal structural anomaly, and he was discharged without a definite diagnosis. Exercise intolerance, dyspnea, and palpitation persisted until our urologist found gross hematuria. Abdominal sonography showed an aneurysmal dilatation of the vein over the left pelvis, just beside the urinary bladder, measuring 7 cm in diameter (Figure 1). A markedly dilated femoral artery and its communication to the vein were also demonstrated by multiple-detector computed tomography (MDCT) angiography (Figure 2). The diagnosis of traumatic AVF was thus made and we operated without delay.

Surgery was performed with an incision on the medial side of the left thigh. The wound was deepened



*Correspondence to: Dr Kuo-Chen Lee, Division of Cardiovascular Surgery, Cheng Hsin Rehabilitation and Medical Center, 45, Cheng-Hsin Street, Taipei 112, Taiwan, R.O.C.

E-mail: cvs.lee@msa.hinet.net • Received: July 30, 2007 • Accepted: February 19, 2008

and the fistula was found between the femoral artery and vein, 10 cm above the popliteal fossa. Further dissection was made to isolate the femoral artery and vein. With occlusion of the proximal and distal ends of the vessels, the artery and vein were separated and the fistula was closed with 5-0 Prolene sutures. The aneurysmal dilatation of the iliac vein was left alone. The postoperative course was very smooth and the patient's symptom of orthopnea became much improved.

Six months later, the patient's heart function had returned to normal (New York Heart Association functional class I). Echocardiography showed a reduction in heart size (LVEDD, 55 mm; LVESD, 37 mm) and minimal mitral regurgitation. MRA showed that the size of the venous aneurysm was also much diminished (Figure 3).

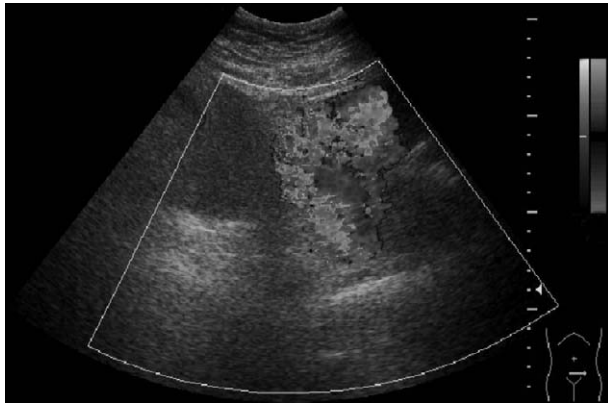


Figure 1. Abdominal sonogram shows an aneurysmal dilatation of the pelvic vein beside the urinary bladder.

Discussion

Trauma, especially low-velocity trauma from a knife or small-caliber missile, is a major cause of acquired AVF. Only approximately 2% of post-traumatic AVFs spontaneously resolve.² Increased sheer force from shunt flow in the artery proximal to the fistula will stimulate secretion of endothelium-derived relaxation factor, which results in vasodilatation by its action on

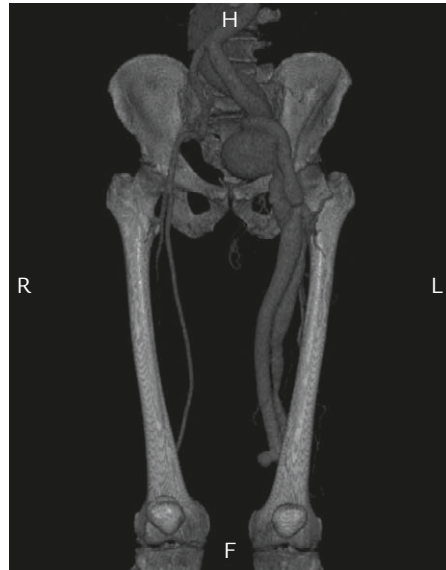


Figure 2. Multiple-detector computed tomography angiography of the arteriovenous fistula reveals dilatation of the femoral and iliac veins of the left lower limb, indicating arteriovenous fistula at the level above the left knee.

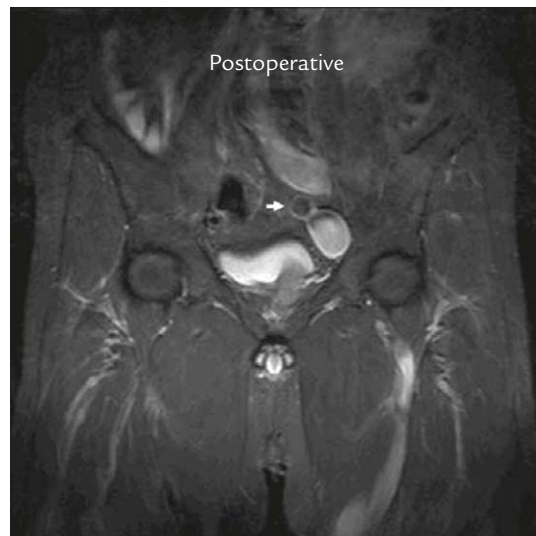
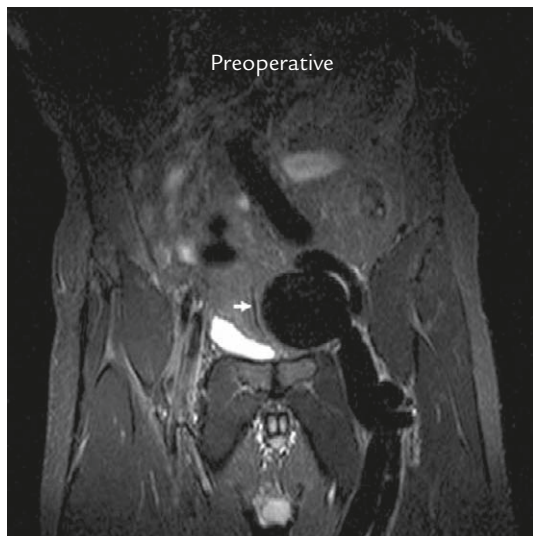

Figure 3. Comparison of preoperative and postoperative magnetic resonance angiography. The arrows show the diminished venous aneurysm.

arterial wall smooth muscle. Longstanding increased blood flow will increase the diameter of the vessel and enhance fracture of the elastic fibers, which further dilates the vessel and increases shunt flow.³ With the enlarging left-to-right shunt, chronic volume overload of the heart leads to remodeling, ventricular dilatation and heart failure.

In this high-tech era, numerous imaging tools lead to a common occurrence: thorough history-taking and physical examinations are neglected. In this case, the patient had received all kinds of studies relevant to heart failure, but none of them had led to the correct diagnosis of AVF. Without the incidental finding of a pelvic venous aneurysm during abdominal sonography, we might not have taken a further look at the patient's extremities, and the presence of this AVF would have remained obscure. During physical examination, the bruit could be easily auscultated at the left inguinal area. It was not until this time that the gunshot history was retrieved.

Though digital subtraction arteriography remains the gold standard for diagnosing AVF, recently-introduced less invasive tools such as MDCT and MRA provide quick but also accurate diagnosis.^{2,4}

Post-traumatic fistula should be obliterated surgically as soon as possible.⁵ Untreated fistula results in complications including rennin-mediated hypertension (40–50%) and high-output heart failure (50%).⁶ Recent development of stent graft provides a less invasive choice for repairing AVF, especially for patients with unstable hemodynamic status.^{7,8}

Rapid reduction in heart size and normalization of cardiac output have been reported in the literature.^{3,9} However, there were exceptions. Nara et al presented a case with aggravated heart failure after closure of long-standing AVF.¹⁰ Abrupt increase in systemic vascular resistance occurred and resulted in deterioration of heart failure. Their patient required inotropes and vasodilators and took some time to recover. Considering the possible deterioration of heart failure, we kept our patient in the intensive care unit for postoperative care. We tapered off the inotropes slowly with careful monitoring of his hemodynamic status. There was no immediate improvement in cardiomegaly in our case, but exercise intolerance was much improved soon after the operation.

Large aneurysm of the iliac vein might lead to life-threatening pulmonary thromboembolism, and some

authors suggest aggressive surgical correction.¹¹ In our case, the dilatation of the iliac vein was secondary to AVF and was not a true venous aneurysm. We did not perform venorrhaphy or use anticoagulatory therapy after the operation. During the follow-up period, there was no thromboembolic complication. Follow-up MRA study also revealed an obvious reduction in the diameter of the left iliac vein. We do not suggest performing any further intervention on the AVF to avoid other complications.

Traumatic AVF is a treatable cause of heart failure. Surgical obliteration may lead to immediate and full recovery. Careful history-taking and physical examination is as important as other advanced diagnostic tools. Critical postoperative care is necessary for patients complicated with chronic heart failure.

References

1. Ingram CW, Satler LF, Rackley CE. Progressive heart failure secondary to a high output state. *Chest* 1987;92:1117–8.
2. Perry MO. Complications of missed arterial injuries. *J Vasc Surg* 1993;17:399–407.
3. Hartung O, Garcia S, Alimi YS, Juhan C. Extensive arterial aneurysm developing after surgical closure of long-standing post-traumatic popliteal arteriovenous fistula. *J Vasc Surg* 2004;39:889–92.
4. Chen JK, Johnson PT, Fishman EK. Diagnosis of clinically unsuspected posttraumatic arteriovenous fistulas of the pelvis using CT angiography. *AJR Am J Roentgenol* 2007;188: 269–73.
5. Ilijevski N, Radak D, Radevic B, Sagic D, Kronja G, Misovic S, Simic A, et al. Popliteal traumatic arteriovenous fistulas. *J Trauma* 2002;52:739–44.
6. Wang KT, Hou JY, Hsieh JJ, Chou YS, Tsai CH. Late development of renal arteriovenous fistula following gunshot trauma. *Angiology* 1998;49:415–8.
7. Kendrick AS, Sprouse LR. Repair of a combined femoral pseudoaneurysm and arteriovenous fistula using a covered stent graft. *Am Surg* 2007;73:227–9.
8. O'Brien J, Buckley O, Torreggiani W. Hemolytic anemia caused by iatrogenic arteriovenous iliac fistula and successfully treated by endovascular stent-graft placement. *AJR Am J Roentgenol* 2007;188:306.
9. Steinmetz OK. Acquired arteriovenous fistula. *N Engl J Med* 2004;350:2180.
10. Nara T, Yoshikawa D, Saito S, Kadoi Y, Morita T, Goto F. Perioperative management of biventricular failure after closure of a long-standing massive arteriovenous fistula. *Can J Anaesth* 2001;48:588–91.
11. Banno H, Yamanouchi D, Fujita H, Nagata J, Kobayashi M, Matsushita M, Nishikimi N, et al. External iliac venous aneurysm in a pregnant woman: a case report. *J Vasc Surg* 2004;40:174–8.