



Spontaneous endometriosis associated with an umbilical hernia: A case report and review of the literature



Hishaam Ismael*, Yury Ragoza, Angela Harden, Steven Cox

The University of Texas Health Science Center at Tyler, Tyler, TX, USA

ARTICLE INFO

Article history:

Received 14 October 2016

Accepted 13 November 2016

Available online 15 November 2016

Keywords:

Endometriosis

Umbilical hernia

Spontaneous umbilical

Endometriosis

Umbilical reconstruction

ABSTRACT

INTRODUCTION: Umbilical endometriosis occurring in the presence of an underlying hernia is extremely rare and presents a diagnostic challenge for the general surgeon. We present an interesting case and perform a comprehensive review of the literature.

METHODS: Medline and PubMed were queried for all cases of spontaneous umbilical endometriosis associated with an umbilical hernia. Data was analyzed and is presented along with an interesting case.

RESULTS: Only 7 cases have been reported in the literature. Median age was 38 years. Time to presentation was long (up to 5 years) and the majority had cyclical symptoms related to menstruation. All patients, including our case, were treated surgically.

DISCUSSION: Spontaneous umbilical endometriosis with an underlying hernia is often missed pre-operatively. Preoperative suspicion warrants axial imaging for better operative planning and patient counseling. Surgery consists of enbloc excision of the umbilicus, implant and the hernia sac to avoid residual disease and reduce recurrence. The hernia defect can be repaired primarily or using mesh and the umbilicus reconstructed using skin flaps if necessary.

CONCLUSIONS: Surgery is the mainstay of therapy for umbilical endometriosis associated with an underlying hernia. Clinical suspicion warrants preoperative imaging, and follow-up with a gynecologist is essential to address any pelvic disease.

© 2016 Published by Elsevier Ltd on behalf of IJS Publishing Group Ltd. This is an open access article under the CC BY-NC-ND license (<http://creativecommons.org/licenses/by-nc-nd/4.0/>).

1. Introduction

Endometriosis, defined as the presence of functional endometrial glands and stroma outside the uterine cavity, is a common gynecologic condition affecting up to 22% of women [1,2]. It usually affects pelvic organs causing dysmenorrhea, dyspareunia, pain and infertility [3]. Extra-pelvic endometriosis is less common, but has been described in almost every area of the female body including the bowel, lungs brain, umbilicus and surgical scars [3,4].

Umbilical endometriosis is a rare condition accounting for 0.5–1% of endometrial ectopia. It usually develops in previous surgical scars but very rarely presents as primary or spontaneous umbilical endometriosis [5]. The first description of an umbilical endometrioma is credited to Villar in 1886, hence the term “Villar’s nodule” [6].

The pathogenesis of endometriosis is widely debated but the most accepted theory is the “hypothesis of migration”. This explains that the dispersion of endometrial tissue occurs by direct extension, vascular and lymphatic channels, and surgical manipulation [3,7]. While surgery can result in the direct inoculation and implantation

of endometrial tissue in surgical incisions, the pathogenesis of primary cutaneous endometriosis is less clear. Lymphatics connecting the peritoneal cavity and the umbilicus course along the obliterated umbilical vessels. It has been postulated that the umbilicus serves as a physiologic scar with a predilection to implantation as endometrial cells course these lymphatic channels [8].

Umbilical hernias account for 3–8.5% of abdominal wall hernias [9]. The occurrence of a primary umbilical endometrioma in the presence of an underlying hernia is extremely rare and can present a diagnostic challenge to the general surgeon. We present a case of spontaneous endometriosis associated with an umbilical hernia along with a comprehensive literature review.

2. Case report

The patient is a 35 year old morbidly obese female who presented to clinic complaining of a 7 months history of cyclical umbilical bleeding. The bleeding would start 2 days before and last throughout her menses. She denied umbilical pain, dysmenorrhea, dyspareunia, infertility or a history of endometriosis. Her past surgical history included 2 caesarean sections through a lower abdominal (Pfannenstiel) incision. Her blood work was unremarkable except for iron-deficiency anemia (Hemoglobin of 11.4 g/dl). She had central obesity (Body Mass Index of 45.5 kg/m²) making

* Corresponding author.

E-mail address: Hishaamismael@gmail.com (H. Ismael).

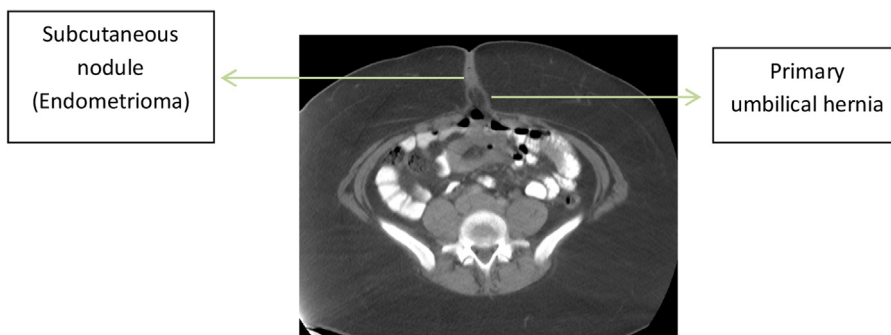


Fig. 1. CT scan demonstrating the subcutaneous nodule with an underlying umbilical hernia.

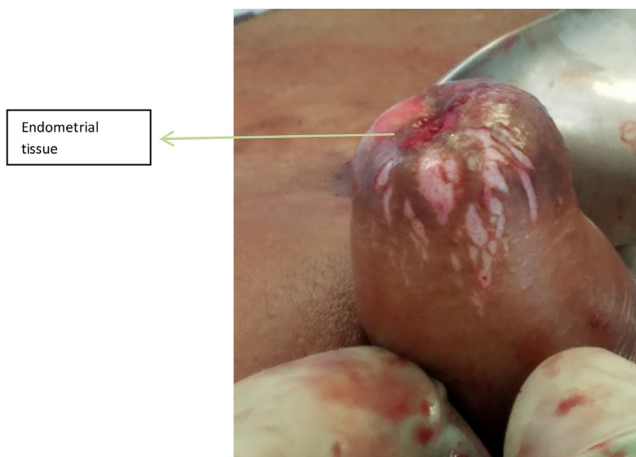
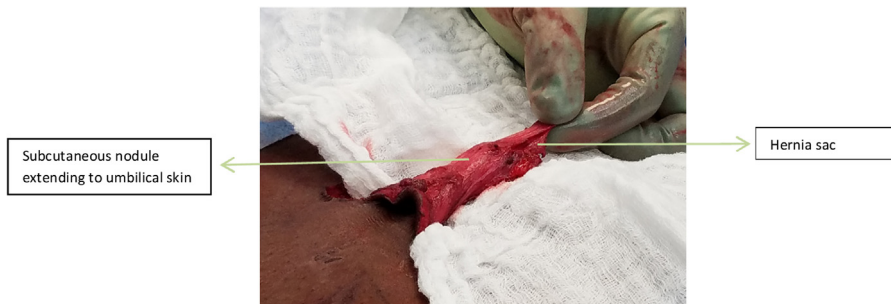

Fig. 2. Intraoperative images of endometrial tissue, subcutaneous mass and hernia sac.

the assessment of an umbilical nodule, mass or hernia difficult by physical exam. A CT scan was ordered to help with the differential diagnosis and demonstrated a subcutaneous nodule with an underlying umbilical hernia (Fig. 1). The nodule measured 1.9 × 1.67 mm. The patient was taken to the operating room and underwent a primary hernia repair with excision of the subcutaneous mass and umbilical reconstruction.

A vertical incision was made around the umbilicus and the wound was deepened using electro-cautery down to the abdominal wall fascia. The hernia sac was dissected and divided at the level of the fascia leaving it attached to the overlying subcutaneous nodule. The umbilicus was inverted and red-purple endometrial tissue was seen implanted at its base (Fig. 2). An incision was made to include the involved skin and the specimen (skin, endometrioma and hernia sac) was pulled through and sent to pathology (Fig. 3).

The hernia was fixed using interrupted # 1 Polydioxanone sutures. The umbilical skin was reconstructed using interrupted subcuticular 4-0 Monocryl sutures and then tacked down to the fascia using 3-0 Vicryl. The patient tolerated the procedure well and was discharged home from the recovery unit. The pathology demonstrated endometriosis (Fig. 4). She was referred for a gynecologic evaluation which was unremarkable. There was no disease or hernia recurrence at her 6 month visit.

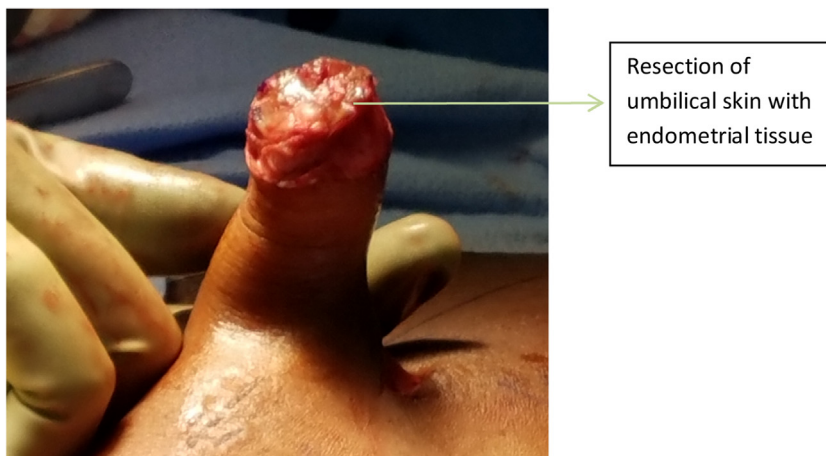
3. Discussion

Primary cutaneous endometriosis is rare and poses a diagnostic challenge when associated with an underlying hernia. A comprehensive review of the English literature using PubMed and Medline was performed and only 7 of these cases have been described

Table 1
Literature review of primary spontaneous endometriosis with an underlying umbilical hernia.

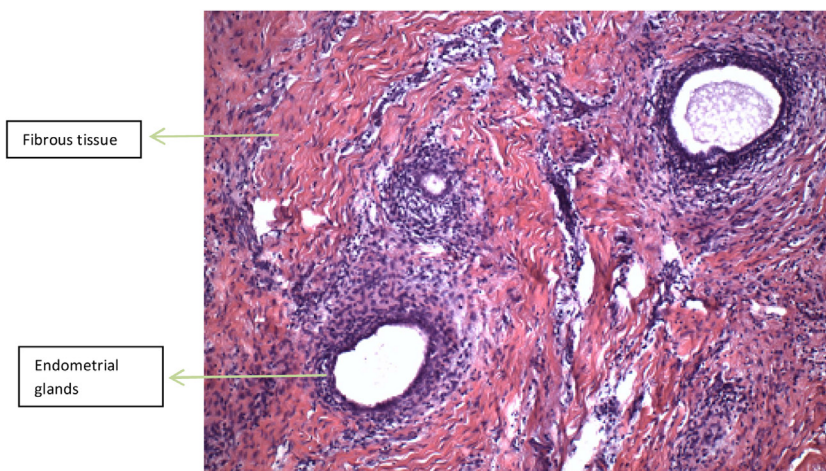
Author	Age (years)	Obstetric history	Symptoms	Time prior to presentation	Previous surgeries	Pathology	Other information
[14]	47	G2P2	Cyclical umbilical pain and swelling along with menorrhagia and dysmenorrhea	5 months	None	Adipocytes, fibrous tissue, endometrial glands and surrounding stroma	14 week, irregularly enlarged uterus and bilateral ovarian endometriomas. Total abdominal hysterectomy and bilateral salpingo-oophorectomy, excision of umbilical nodule and mesh repair of hernia performed.
[10]	38	G1P1	Large irreducible umbilical hernia associated with a painful secretory lump, worse during menstruation	5 years	None	Endometrial glands surrounded by compact stroma	Normal uterus and adnexa, no symptoms of pelvic endometriosis. Umbilical hernia was repaired with Polypropylene mesh.
[16]	18	G0P0	Pain and swelling at umbilicus, unrelated to menstrual cycle	5 months	None	Endometriosis	0.2-0.3 cm nodule at the top of hernia sac. Placed on Danazol after surgery
[13]	42	N/A	Intense pain and umbilical bleeding during menstruation	1 year	None	Endometrial tissue in close contact with skin	Normal pelvic exam and ultrasound. Umbilical ultrasound and MRI identified a 2 cm nodule. FNA performed. Umbilicus resected with nodule and hernia sac. Hernia repaired without mesh and umbilicus reconstructed.
[11]	43	Not specified but had at least 1 previous C-section	Umbilical pain, worse during menstruation	2 months	C-section 9 years prior to presentation	Dilated glands forming cysts lined by columnar epithelium with surrounding stromal cells.	Patient was thought to have an incarcerated umbilical hernia and underwent emergent exploratory laparotomy. A purplish lesion was found attached to the hernia sac. A Mayo repair of the hernia was performed.
[19]	33	G9P9	Umbilical lump that enlarges and becomes tender before onset of menstruation	2 years	None	Stratified squamous epithelium and underlying connective tissue with prominent areas of endometriosis	Examination revealed a firm, round, cherry red nodule at the umbilicus with an underlying umbilical hernia. A Mayo repair was used to fix the hernia. No pelvic endometriosis.
[12]	30		Cyclical umbilical pain and bleeding	18 months	None	Endometriosis with chronic inflammation, hemosiderin, and fibrosis	The lesions were well delineated on MRI and showed evidence of prior hemorrhage.

G – Gravidity.
P – Parity.
N/A – Not available.
C-section – Caesarean section.
MRI – Magnetic resonance imaging.
FNA – Fine needle aspiration.



Resection of umbilical skin with endometrial tissue

Fig. 3. Resection of umbilical skin and pathology specimen.



Fibrous tissue

Endometrial glands

Fig. 4. Histology demonstrating fibrous tissue with numerous benign endometrial glands.

(Table 1). Umbilical endometriosis is of interest to the general surgeon as it may be mistaken for a melanoma, cyst, abscess, suture granuloma or a metastatic deposit from a systemic malignancy [10]. Endometriosis should be suspected in all pre-menopausal women presenting with umbilical swelling and cyclical symptoms [11]. An underlying hernia is easy to diagnose by physical exam; however, as with our case, morbid obesity may make its identification difficult. As many of these patients will have concomitant pelvic endometriosis, it is recommended to perform preoperative imaging prior to elective repair. Magnetic resonance imaging has been shown to be the modality of choice as it is useful in delineating the size and location of extra-pelvic endometriosis and excluding intra-abdominal extension of the disease [11,12]. Although ultrasound guided biopsy and hormonal therapy have been described, surgical resection and hernia repair are the mainstay of therapy [13]. Superficial therapies like thermo-coagulation can lead to relapse and are not recommended [14]. Both laparoscopic and open approaches have been described for wide excision of the umbilical lesion and hernia repair. Laparoscopy has the added advantage of evaluating and treating pelvic disease [15]. The principles of surgery include a wide resection without spillage to avoid disease recurrence.

Review of the literature indicates that the median age of presentation was 38 years (18–47 years). The majority of patients had cyclical symptoms, although pain and swelling unrelated to the menstrual cycle have been described [16]. Time to presentation was usually long (2 months–5 years) suggesting that the symp-

toms are difficult to interpret and the diagnosis of primary umbilical endometriosis can be elusive. All patients were treated surgically with resection and hernia repair.

Our patient had cyclical symptoms and preoperative imaging demonstrating an umbilical nodule and an underlying hernia. Rather than attempting to separate the nodule from the hernia sac, we recommend resecting them en-bloc along with the umbilicus to reduce the chance of spillage and disease recurrence. The hernia defect was repaired primarily as it was less than 2 cm in diameter. Mesh repair is recommended for larger or recurrent hernias especially in obese patients [17]. There are several approaches to umbilical reconstruction depending on the size of the defect. Larger defects can be closed using flaps [18], while smaller defects as in our case can be closed using interrupted absorbable sutures. Referral to a gynecologist is always recommended when endometriosis is suspected.

4. Conclusions

Spontaneous umbilical endometriosis with an underlying hernia is extremely rare and often missed preoperatively. Preoperative suspicion warrants imaging for better operative planning and patient counseling. Surgery is the mainstay of treatment and consists of en-bloc excision of the umbilicus, implant and the hernia sac to avoid residual disease and reduce recurrence. The hernia defect can be repaired primarily or using mesh and the umbilicus recon-

structed using skin flaps if necessary. Follow-up with a gynecologist is essential to address pelvic disease.

Conflict of interest

None of the authors have any disclosures or conflict of interests.

Funding

none.

Author contribution

Hishaam Ismael MD – Study concept and data collection.
Yury Ragoza DO – data collection.
Angela Harden – Writing the paper.
Steven Cox MD – data interpretation and review.

Consent

Written consent has been given.

Guarantor

Hishaam Ismael MD.

Ethical approval

Approval has been given by the University of Texas Northeast ethics committee.

References

- [1] A. Agrawal, Y.F. Fong, Cutaneous endometriosis, *Singapore Med. J.* 49 (9) (2008) 704.
- [2] K. Kyamidis, Lora Viviana, J. Kanitakis, Spontaneous cutaneous umbilical endometriosis: report of a new case with immunohistochemical study and literature review, *Dermatol. Online J.* 17 (7) (2011) 5.
- [3] P.V. Bagade, M.M. Guirguis, Menstruating from the umbilicus as a rare case of primary umbilical endometriosis: a case report, *J. Med. Case Rep.* 3 (2009) 9326.
- [4] S.M. Markham, S.E. Carpenter, J.A. Rock, Extrapelvic endometriosis, *Obstet. Gynecol. Clin. North Am.* 16 (1989) 193–219.
- [5] L.S. Mann, W.R. Clarke, Endometriosis of the umbilicus, *IMJ III Med. J.* 125 (1964) 335–336.
- [6] R.A. Skidmore, J.T. Woosley, V.L. Katz, Decidualized umbilical endometriosis, *Int. J. Gynaecol. Obstet.* 52 (1996) 269–273.
- [7] P. Chatzikokkinou, J. Throfinn, K. Angelidis, et al., Spontaneous endometriosis in an umbilical skin lesion, *Acta Dermatovenerol. Alp. Pannonica Adriat.* 18 (3) (2009) 126–130.
- [8] U. Zollner, G. Girschick, T. Steck, et al., Umbilical endometriosis without previous pelvic surgery: a case report, *Arch. Gynecol. Obstet.* 267 (2003) 258–260.
- [9] N. Dabbas, K. Adams, K. Pearson, et al., Frequency of abdominal wall hernias: is classical teaching out of date? *JRSM Short Rep.* 2 (1) (2011) 5.
- [10] M. Stojanovic, M. Radojkovic, L. Jeremic, et al., Umbilical endometriosis associated with large umbilical hernia. Case report, *Chirurgia (Bucur)* 109 (2014) 267–270.
- [11] J.S.P. Yuen, P.K.H. Chow, H.N. Koong, et al., Unusual sites (thorax and umbilical hernia sac) of endometriosis, *J. R. Coll. Surg. Edinb.* 46 (5) (2001) 313–315.
- [12] C.Y. Yu, M. Perez-Reyes, J.J. Brown, et al., MR appearance of umbilical endometriosis, *J. Comput. Assist. Tomogr.* 18 (2) (1994) 269–271.
- [13] F. Iovino, R. Ruggiero, E. Irlandese, et al., Umbilical endometriosis associated with umbilical hernia: management of a rare occurrence, *Chir. Ital.* 59 (6) (2007) 895–899.
- [14] D. Pandey, R. Sharma, S. Salhan, Catamenial pain in umbilical hernia with spontaneous reduction: an unusual presentation of a rare entity, *J. Clin. Diagn. Res.* 9 (8) (2015) 9–11.
- [15] L. Fedele, G. Frontino, S. Bianchi, et al., Umbilical endometriosis: a radical excision with laparoscopic assistance, *Int. J. Surg.* 8 (2) (2010) 109–111.
- [16] S. Sinha, R. Sinha, Umbilical endometriosis associated with umbilical hernia, *Apollo Med.* 6 (3) (2009) 276–277.
- [17] J.A. Halm, J. Heisterkamp, H.F. Veen, et al., Long-term follow-up after umbilical hernia repair: are there risks for recurrence after simple and mesh repair, *Hernia* 9 (4) (2005) 334–337.
- [18] S. Mechsner, J. Bartley, M. Infanger, et al., Clinical management and immunohistochemical analysis of umbilical endometriosis, *Arch. Gynecol. Obstet.* 280 (2) (2009) 235–242.
- [19] A. Ramsanahie, S.K. Giri, S. Velusamy, et al., Endometriosis in a scarless abdominal wall with underlying umbilical hernia, *Ir. J. Med. Sci.* 169 (1) (2000) 67.

Open Access

This article is published Open Access at [sciencedirect.com](https://www.scienceopen.com). It is distributed under the [IJSCR Supplemental terms and conditions](#), which permits unrestricted non commercial use, distribution, and reproduction in any medium, provided the original authors and source are credited.