

Radiology Case Reports

Volume 5, Issue 1, 2010

Primary breast lymphoma

Pooja Voria, MD, MBA; Peter R. Eby, MD; and Kimberly Allison, MD

We report a case of primary breast lymphoma in a 75-year-old woman who noticed a lump in her right breast after trauma. Mammographic, ultrasonographic, and pathologic correlations are provided. The typical appearance of primary breast lymphoma on mammography is a solitary, uncalcified, circumscribed, or indistinctly marginated mass with adjacent lymphadenopathy. On ultrasound, primary breast lymphoma is usually hypoechoic with circumscribed or microlobulated margins demonstrating increased vascularity. The differential diagnosis for a mass with this appearance is discussed in detail and includes hematoma, abscess, primary breast lymphoma, invasive ductal carcinoma, phyllodes tumor, and metastatic disease.

Case report

A 75-year-old female noticed a lump in her right breast after mild trauma. She complained of warmth and pruritis but denied associated pain, bruising, erythema, or nipple discharge. She had a history of stroke, hypertension, hyperlipidemia, and atrial fibrillation that was treated with long-term warfarin. There was no family history of breast, ovarian, or colon cancer. Her screening mammogram from one year ago was normal. Physical examination revealed a firm, mobile 3-cm mass in the upper inner quadrant without skin changes. There was no palpable axillary lymphadenopathy. A diagnostic mammogram and subsequent ultrasound were performed.

The diagnostic mammogram (Fig. 1), revealed a large, new, oval, isodense mass with indistinct margins at 1 o'clock extending from anterior to posterior depth without associated calcifications. Ultrasound demonstrated a 44 x 20 x 44-mm heterogeneous, hypoechoic oval mass parallel to the chest wall with circumscribed and microlobulated margins and increased vascularity, at 1 o'clock 3 cm from the nipple

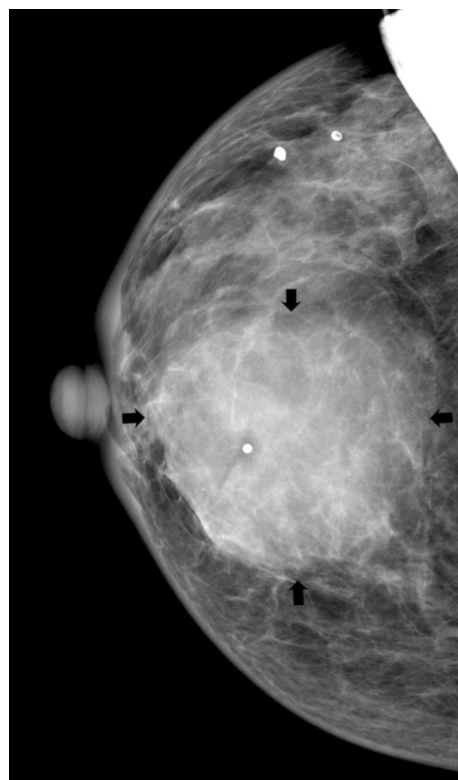


Figure 1A. 75-year-old woman with primary breast lymphoma. Mammogram of the right breast, CC view. Note a large oval isodense mass (arrows) with indistinct margins at 1 o'clock extending from anterior to posterior depth without associated calcifications. A BB marks the site of palpable abnormality.

Citation: Voria P, Eby PR, Allison K. Primary breast lymphoma. *Radiology Case Reports*. [Online] 2010;5:351.

Copyright: © 2010 The Authors. This is an open-access article distributed under the terms of the Creative Commons Attribution-NonCommercial-NoDerivs 2.5 License, which permits reproduction and distribution, provided the original work is properly cited. Commercial use and derivative works are not permitted.

Dr. Voria is a radiology resident, Dr. Eby is an Assistant Professor in the Department of Radiology, and Dr. Allison is an Assistant Professor in the Department of Pathology, all at the University of Washington, Seattle WA.

Competing Interests: The authors have declared that no competing interests exist.

DOI: 10.2484/rcr.v5i1.351

Primary breast lymphoma

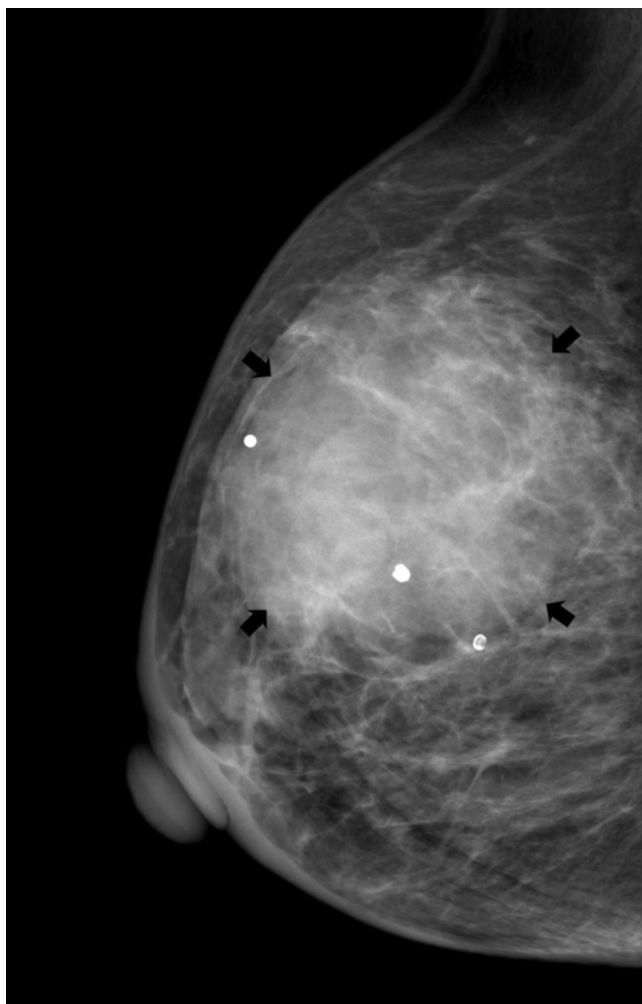


Figure 1B. 75-year-old woman with primary breast lymphoma. Mammogram of the right breast, ML view. Note a large oval isodense mass (arrows) with indistinct margins at 1 o'clock extending from anterior to posterior depth without associated calcifications. A BB marks the site of palpable abnormality.

(Fig. 2). This mass was given a BI-RADS assessment category of 4c because of the significant change on mammography, microlobulated margins, and increased vascularity. Ultrasound-guided biopsy of the mass was recommended. Given the high level of suspicion for this mass, an ultrasound of the axilla was also performed to evaluate the lymph nodes. In this case, there was a single, large axillary lymph node with an abnormal appearance, as demonstrated by loss of the normal reniform shape and development of eccentric, bulbous, cortical thickening with slitlike configuration of the hilum, multiple feeding vessels, and marked cortical vascularity (Fig. 3). Ultrasound-guided biopsy of the lymph node was also recommended.

When evaluating a breast mass, the first step is to characterize the morphologic appearance according to the

American College of Radiology Breast Imaging Reporting and Data System (BI-RADS) (1). The morphologic features influence the level of suspicion, BI-RADS category and recommendations. Changes in the imaging findings or physical examination are critical to assessing the level of suspicion. In this case, the combination of a large solid

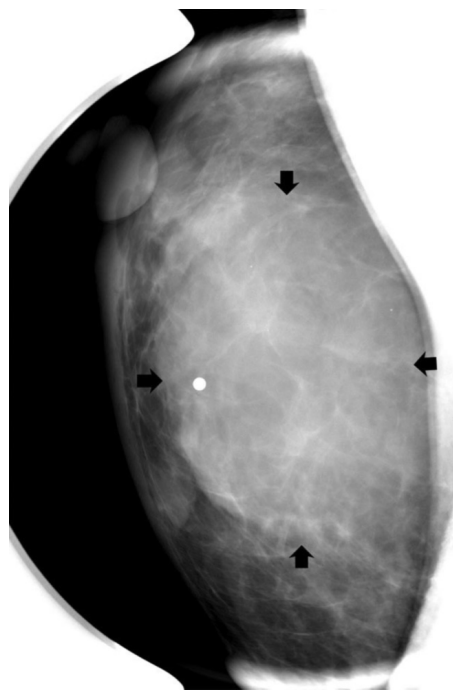


Figure 1C. 75-year-old woman with primary breast lymphoma. Mammogram of the right breast, spot magnification, CC view. Note a large oval isodense mass (arrows) with indistinct margins at 1 o'clock extending from anterior to posterior depth without associated calcifications. A BB marks the site of palpable abnormality.

mass with increased vascularity and indistinct margins is suspicious for malignancy and deserves a BI-RADS 4c assessment.

Ultrasound of the axilla can have an impact on patient management when a suspicious mass is identified. Evaluation of lymph nodes can be important for diagnosis, staging, and treatment in those with potential cancer. If the tumor is resectable and if an axillary lymph node is positive for malignancy on biopsy, a full axillary-node dissection is performed instead of a sentinel-node biopsy at the time of tumor resection.

Abnormal lymph nodes have many sonographic features, such as loss of the normal reniform appearance, a thick bulbous cortex, and round shape. In some cases, there is loss of the fatty hilum as well (2). Size is considered the least useful criteria to stratify the risk of metastasis. The short axis of normal lymph nodes elsewhere in the body typically should not exceed 1 cm. However, normal lymph nodes in the axilla may exceed 1 cm (3). Distinguishing between

Primary breast lymphoma

reactive, inflammatory lymph nodes and neoplastic lymph nodes can be more difficult. Metastatic lymph nodes are favored when there is eccentric cortical thickening with or

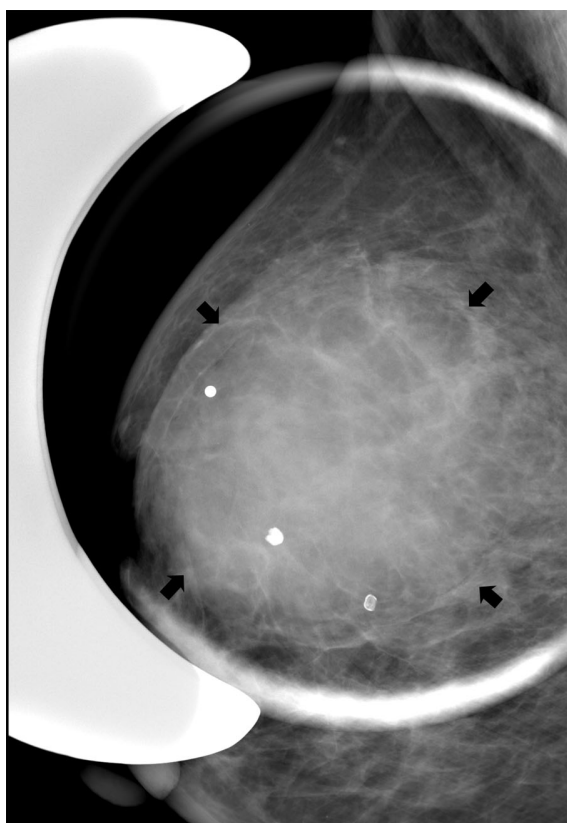


Figure 1D. 75-year-old woman with primary breast lymphoma. Mammogram of the right breast, spot magnification, ML view. Note a large oval isodense mass (arrows) with indistinct margins at 1 o'clock extending from anterior to posterior depth without associated calcifications. A BB marks the site of palpable abnormality.

without convex indentations on the fatty hilum, round appearance with complete loss of the fatty hilum, displacement of the hilum to the edge, and perinodal invasion with angular margins (3). Reactive lymph nodes usually enlarge uniformly in an elliptical configuration. A slitlike configuration of the hilum can occur with metastatic or severely inflamed lymph nodes. Color Doppler imaging may also be useful in differentiating between reactive and malignant lymph nodes. There are multiple feeding vessels due to the formation of new arteries in lymph nodes with metastatic foci. Cortical flow can also be seen. There is dilation of the existing single hilar artery in a reactive lymph node without formation of new arterial flow (3). The lymph node in this case demonstrated eccentric, bulbous cortical thickening with slitlike configuration of the hilum with multiple feeding vessels and marked vascularity. Together, these features are suspicious for malignancy.

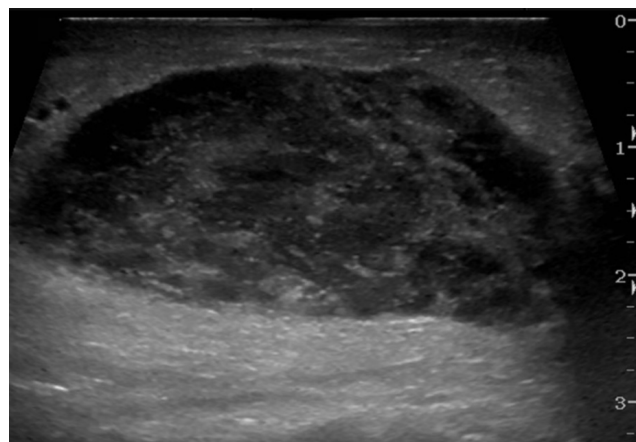


Figure 2A. 75-year-old woman with primary breast lymphoma. Ultrasound image of the palpable area demonstrates a 44 x 20 x 44 mm heterogeneous, hypoechoic oval mass parallel to the chest wall with circumscribed and microlobulated margins and increased vascularity.

The recommendation, pursuant to a BI-RADS 4c assessment, was to perform an ultrasound-guided biopsy of the breast mass and axillary lymph node.

In this case, the core-needle biopsies of the breast mass and the axillary lymph node both contain diffuse areas with sheets of cytologically malignant cells and no underlying

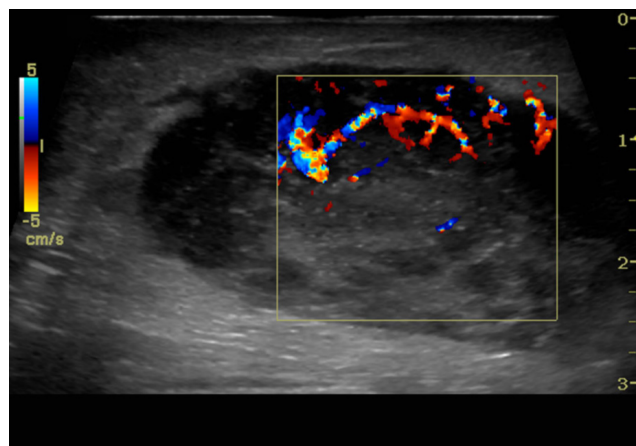


Figure 2B. 75-year-old woman with primary breast lymphoma. Ultrasound image of the palpable area demonstrates a 44 x 20 x 44 mm heterogeneous, hypoechoic oval mass parallel to the chest wall with circumscribed and microlobulated margins and increased vascularity at 1 o'clock 3 cm to the nipple.

normal lymph node architecture. In the breast biopsy, there are rare normal ductal structures identified that are engulfed by the neoplastic process. The malignant cells have scant cytoplasm, large vesicular nuclei with prominent nucleoli, and irregular nuclear membranes (Fig. 4). After im-

Primary breast lymphoma

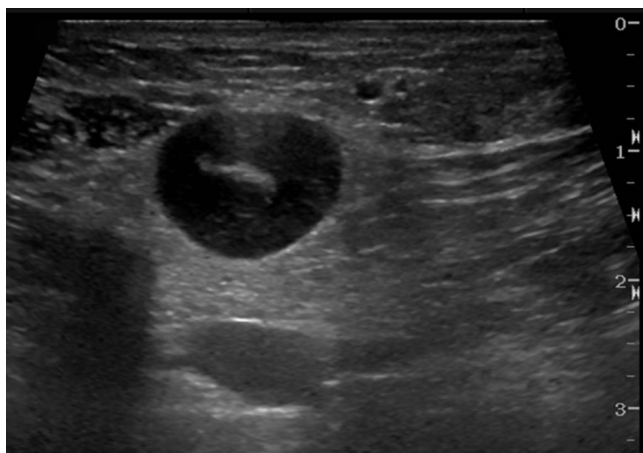


Figure 3A. 75-year-old woman with primary breast lymphoma. Ultrasound image of an axillary lymph node reveals loss of the normal reniform appearance with eccentric, bulbous cortical thickening with slitlike configuration of the hilum.

Immunohistochemistry studies, the malignant cells uniformly expressed B-cell antigen, CD20, and B-cell lymphoma marker, BCL-6, without expression of CD10, CD3, or CD21. There was a high cell-turnover rate of 70%, based

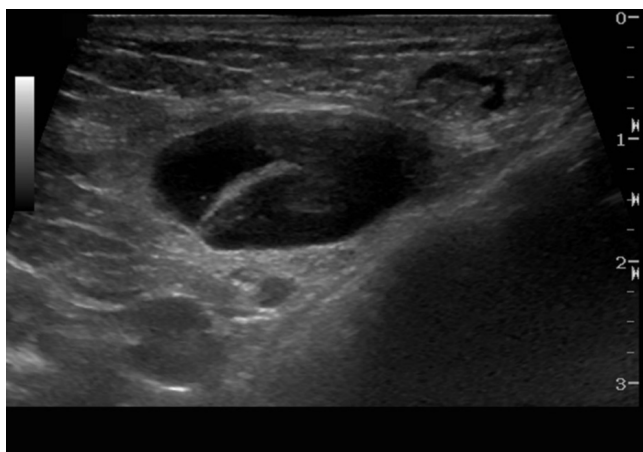


Figure 3B. 75-year-old woman with primary breast lymphoma. Ultrasound image of an axillary lymph node reveals loss of the normal reniform appearance with eccentric, bulbous cortical thickening with slitlike configuration of the hilum.

on a Ki-67 proliferative index stain. These morphologic and immunohistochemical findings were interpreted as diffuse large-cell lymphoma involving the breast and axillary lymph node.

Discussion

Primary breast lymphoma (PBL) is an uncommon neoplasm of the breast with an incidence of less than 0.6% of primary breast malignancies (4, 5). Its low incidence is attributed to the relatively small amount of lymphoid tissue in the breast compared to other organs (6). It is thought to develop from the lymphatics or intramammary lymph nodes (4). Most affected women present with this condition in the sixth or seventh decade of life, but patients as young as 12 years have been reported (7, 8).

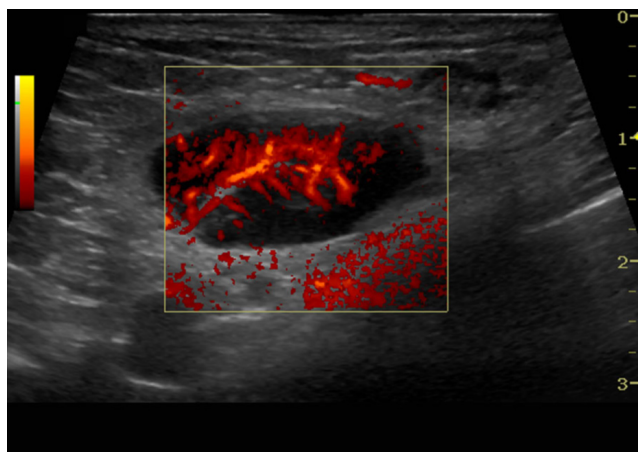


Figure 3C. 75-year-old woman with primary breast lymphoma. Color Doppler image of the same axillary lymph node demonstrates increased vascularity with increased cortical flow.

The diagnostic criteria for PBL, established by Wiseman and Lao in 1972, require a technically adequate specimen, close association of breast and lymphoid tissue, no evidence of spread of disease, and no previous diagnosis of extramammary lymphoma (6, 9). Most cases of PBL are of the B-cell lineage, with 60% being the diffuse large B-cell type (10-13). Those of T-cell origin have been associated with breast implants (4).

The typical appearance of PBL on mammography is a solitary, uncalcified, circumscribed, or indistinctly margined mass with adjacent lymphadenopathy (14). On ultrasound, the mass is hypoechoic, with circumscribed or microlobulated margins demonstrating increased vascularity (15). MRI demonstrates a heterogeneously enhancing mass which is isointense and slightly hyperintense to breast parenchyma on T1- and T2-weighted images, respectively. There is rapid initial enhancement with washout (6, 16).

Imaging findings, history, and patient age should guide us to the appropriate diagnosis. The differential diagnosis for a mass with this appearance includes hematoma, abscess, PBL, invasive ductal carcinoma (IDC), phyllodes tumor, and metastatic disease.

Abscess and hematoma have similar mammographic and sonographic appearances (17). Since the patient was on warfarin for anticoagulation and had reported trauma to

Primary breast lymphoma

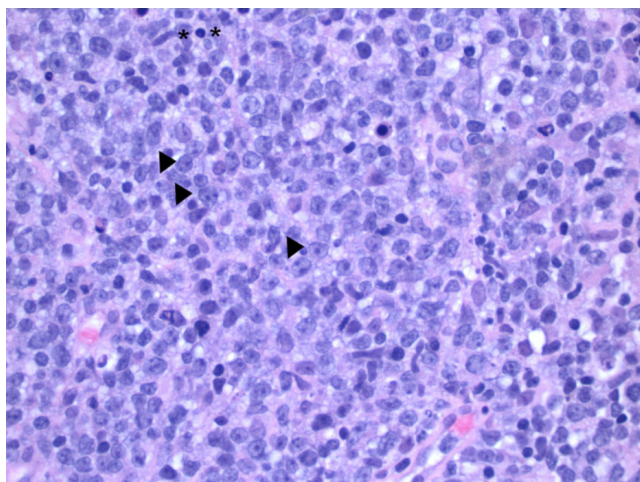


Figure 4. Medium power view of the breast biopsy contains a diffuse infiltrate of malignant cells, invading in a sheet-like growth pattern (H&E stain, 200X). The cytologic features of the malignant cells are apparent at higher power. The cells have scant to inapparent cytoplasm with large atypical nuclei containing prominent nucleoli, vesicular chromatin, and irregular nuclear membranes (arrowheads). A normal lymphocyte is bracketed (asterisks) for comparison.

the breast, hematoma could not be excluded on the mammographic appearance alone. The level of suspicion for abscess was low, as the patient did not exhibit signs or symptoms of infection. The characteristic that distinguished between these two entities and PBL was the lack of vascularity within an abscess or hematoma (3).

Invasive ductal carcinoma (IDC), which is much more common than PBL, usually presents with a mass but also demonstrates one or more of the following: calcification, architectural distortion, and spiculated margins. These features are rarely seen in PBL (14). Of the various subtypes of IDC, papillary, mucinous, and “medullary-like” carcinomas can present as relatively circumscribed masses without calcifications. Papillary carcinomas usually occur around menopause and, as with all papillary lesions, commonly occur with bloody nipple discharge (18). Papillary carcinoma can present as a single round solitary mass or a group of masses within one quadrant of the breast, with solid appearance on ultrasound. There may or may not be cystic components (19). Mucinous carcinoma is a slow-growing neoplasm with a typical heterogeneous “salt-and-pepper” appearance on ultrasound (3, 20). While the term “medullary carcinoma” has fallen out of favor, many “basal-like” carcinomas, especially in association with BRCA-1 mutation carriers, have features that were associated with the diagnosis of medullary carcinoma, including a solid but circumscribed high-grade cancer with areas of central necrosis or cystic degeneration (21). These subtypes grow rapidly and demonstrate increased acoustic enhancement, usually with at least one angular margin, one area with loss

of the thin, echogenic capsule, or a thick, ill-defined, echogenic halo (3).

Phyllodes tumor appears in women ages 30 to 70, with a mean age of 52 years (22). On mammography, phyllodes tumor appears as a noncalcified, circumscribed mass with a round, oval, or lobular shape. On ultrasound, it is hypoechoic and heterogeneous, containing slitlike clefts and fluid-filled, elongated cystic spaces, which are not typical ultrasound features of PBL (22, 23). Metastatic involvement of axillary lymph nodes by phyllodes tumor is rare.

Metastatic disease to the breast, such as melanoma, lymphoma, sarcoma, lung cancer, and gastric carcinomas, although rare, should also be considered (24). Metastases can have a similar appearance to PBL but are usually multiple and bilateral, whereas primary lesions of the breast are single and unilateral. In this case, metastatic disease was a quite low possibility in the differential diagnosis, as this mass was single and unilateral (23).

PBL is the leading diagnosis in this case, based on the combination of clinical and imaging findings. Image-guided needle biopsy is required to confirm the diagnosis. When lymphoma is a high possibility in the differential diagnosis, sending fresh tissue for flow cytometry during the biopsy procedure should also be considered.

The treatment for PBL includes radiation and chemotherapy, depending on the stage and histologic grade of disease (8, 23). It is important to make an accurate diagnosis, as surgical resection is generally not needed (23).

The patient is currently undergoing chemotherapy, with successful decrease in size of the mass on physical exam to approximately 1 cm. She will be referred to radiation therapy following completion of her chemotherapy regimen.

References

1. D'Orsi C, Bassett L, Berg W, et al. *Breast Imaging Reporting and Data System: ACR BI-RADS-Mammography*. 4 ed. Reston, VA: American College of Radiology, 2003.
2. Alvarez S, Anorbe E, Alcorta P, Lopez F, Alonso I, Cortes J. Role of sonography in the diagnosis of axillary lymph node metastases in breast cancer: a systematic review. *AJR Am J Roentgenol*. 2006;186(5):1342-8. [\[PubMed\]](#)
3. Stavros AT. *Breast ultrasound*. Philadelphia, PA: Lippincott Williams & Wilkins, 2004.
4. Wong AK, Lopategui J, Clancy S, Kulber D, Bose S. Anaplastic large cell lymphoma associated with a breast implant capsule: a case report and review of the literature. *Am J Surg Pathol*. 2008;32(8):1265-8. [\[PubMed\]](#)
5. Espinosa LA, Daniel BL, Jeffrey SS, Nowels KW, Ikeda DM. MRI features of mucosa-associated lymphoid tissue lymphoma in the breast. *AJR Am J Roentgenol*. 2005;185(1):199-202. [\[PubMed\]](#)
6. Woo OH, Yong HS, Shin BK, Park CM, Kang EY. Synchronous bilateral primary breast lymphoma: MRI and pathologic findings. *Breast J*. 2007;13(4):429-30. [\[PubMed\]](#)

Primary breast lymphoma

7. Jeanneret-Sozzi W, Taghian A, Epelbaum R, et al. Primary breast lymphoma: patient profile, outcome and prognostic factors. A multicentre Rare Cancer Network study. *BMC Cancer*. 2008;8:86. [\[PubMed\]](#)
8. Wong WW, Schild SE, Halyard MY, Schomberg PJ. Primary non-Hodgkin lymphoma of the breast: The Mayo Clinic Experience. *J Surg Oncol*. 2002;80(1):19-25; discussion 6. [\[PubMed\]](#)
9. Wiseman C, Liao KT. Primary lymphoma of the breast. *Cancer*. 1972;29(6):1705-12. [\[PubMed\]](#)
10. Vasei M, Kumar PV, Malekhosseini SA, Amirghofran Z. Primary T-cell lymphoma of the breast with lymphoepithelial lesion. A case report. *Apmis*. 1997;105(6):445-8. [\[PubMed\]](#)
11. Topalovski M, Crisan D, Mattson JC. Lymphoma of the breast. A clinicopathologic study of primary and secondary cases. *Arch Pathol Lab Med*. 1999;123(12):1208-18. [\[PubMed\]](#)
12. Tan PH, Sng IT. Breast lymphoma--a pathologic study of 14 cases. *Ann Acad Med Singapore*. 1996;25(6):783-90. [\[PubMed\]](#)
13. Vignot S, Ledoussal V, Nodiot P, et al. Non-Hodgkin's lymphoma of the breast: a report of 19 cases and a review of the literature. *Clin Lymphoma*. 2005;6(1):37-42. [\[PubMed\]](#)
14. Liberman L, Giess CS, Dershaw DD, Louie DC, Deutch BM. Non-Hodgkin lymphoma of the breast: imaging characteristics and correlation with histopathologic findings. *Radiology*. 1994;192(1):157-60. [\[PubMed\]](#)
15. Lyou C, Yang S, Choe D, Lee B, Kim K. Mammographic and sonographic findings of primary breast lymphoma. *Clin Imaging*. 2007;31(4):234-8. [\[PubMed\]](#)
16. Darnell A, Gallardo X, Sentis M, Castañer E, Fernandez E, Villajos M. Primary lymphoma of the breast: MR imaging features. A case report. *Magn Reson Imaging*. 1999;17(3):479-82. [\[PubMed\]](#)
17. Wicks J, Silver T, Bree R. Gray scale features of hematomas: an ultrasonic spectrum. *AJR Am J Roentgenol*. 1978;131(6):977-80. [\[PubMed\]](#)
18. Soo M, Williford M, Walsh R, Bentley R, Kornguth P. Papillary carcinoma of the breast: imaging findings. *AJR Am J Roentgenol*. 1995;164(2):321-6. [\[PubMed\]](#)
19. Schneider J. Invasive papillary breast carcinoma: mammographic and sonographic appearance. *Radiology*. 1989;171(2):377-9. [\[PubMed\]](#)
20. Cardenosa G, Doudna C, Eklund G. Mucinous (colloid) breast cancer: clinical and mammographic findings in 10 patients. *AJR Am J Roentgenol*. 1994;162(5):1077-9. [\[PubMed\]](#)
21. Subhawong A, Subhawong T, Nassar H, et al. Most basal-like breast carcinomas demonstrate the same Rb-/p16+ immunophenotype as the HPV-related poorly differentiated squamous cell carcinomas which they resemble morphologically. *Am J Surg Pathol*. 2009;33(2):163-75. [\[PubMed\]](#)
22. Lifshitz O, Whitman G, Sahin A, Yang W. Radiologic-pathologic conferences of the University of Texas M.D. Anderson Cancer Center. Phyllodes tumor of the breast. *AJR Am J Roentgenol*. 2003;180(2):332. [\[PubMed\]](#)
23. Feder J, de Paredes E, Hogge J, Wilken J. Unusual breast lesions: radiologic-pathologic correlation. *Radiographics*. 1999;19 Spec No:S11-26; quiz S260. [\[PubMed\]](#)
24. Toombs BD, Kalisher L. Metastatic disease to the breast: clinical, pathologic, and radiographic features. *AJR Am J Roentgenol*. 1977;129(4):673-6. [\[PubMed\]](#)