

The Effect of Patent Foramen Ovale Closure on Visual Aura Without Headache or Typical Aura With Migraine Headache

Hamidreza Khessali, MD,* M. Khalid Mojadidi, MD,* Rubine Gevorgyan, MD,*
Ralph Levinson, MD,† Jonathan Tobis, MD*

Los Angeles, California

Objectives The aim of this study was to assess the prevalence of right-to-left (R to L) shunt in patients with visual aura and evaluate the effect of shunt closure on resolution of aura.

Background Right-to-left shunting is associated with migraine headache (MH) with aura. Some patients present with visual aura without headaches. It is unclear whether visual aura without headache is a form of migraine or a transient neurologic dysfunction.

Methods Of patients referred to the University of California, Los Angeles for suspected patent foramen ovale (PFO), 225 had visual aura with or without MH. Patients were assessed for a shunt and evaluated for MH and/or visual aura. They were divided into 3 groups: 1) visual aura associated with MH; 2) visual aura unrelated in time to MH; and 3) visual aura without MH. The frequency of R to L shunt was compared with a control group of 200 patients. Eighty patients underwent PFO closure. Residual shunts, MH, and visual aura were reassessed after 3 and 12 months.

Results The prevalence of R to L shunt in Groups A, B, and C was 96%, 72%, and 67%, respectively, versus 18% in the control group ($p < 0.0001$). The frequency of shunting was similar in Group B versus Group C, but much higher in all 3 groups compared with control subjects. Twelve months after PFO closure, symptoms of aura were resolved in 52%, 75%, and 80% of patients in Groups A, B, and C, respectively ($p = \text{NS}$).

Conclusions The similar distribution of R to L shunting in all 3 patient groups and the correlation between PFO closure and improvement of aura suggests a similar pathophysiology between the presence of PFO and the visual aura phenomenon, whether or not headache is present in the symptom complex. (J Am Coll Cardiol Intv 2012;5:682–7) © 2012 by the American College of Cardiology Foundation

From the *Program in Interventional Cardiology, Division of Cardiology, David Geffen School of Medicine, University of California, Los Angeles, California; and the †Jules Stein Eye Institute, University of California, Los Angeles, California. Dr. Levinson has received support from the McDonald Foundation and the Research to Prevent Blindness Fund. AGA Medical, Inc., provided the transcranial Doppler system and an unrestricted grant to support this research; Dr. Tobis is a consultant for AGA Medical, Inc., W.L. Gore, Inc., and Coherex, Inc. and he is on the steering committee for PREMIUM Trial, AGA Medical. All other authors have reported that they have no relationships relevant to the contents of this paper to disclose.

Manuscript received October 4, 2011; revised manuscript received February 23, 2012, accepted March 16, 2012.

Transient visual disturbances are associated with migraine headache (MH) in 20% of people with migraine (1,2). When these visual symptoms precede or occur during a headache, they are recognized as visual aura associated with migraine. However, there are some patients who develop visual aura that is not associated with a headache. In these cases, the patient or the physician might be concerned that there is a primary ocular problem, such as a retinal tear, transient ischemic event, or a cortical stroke.

There is an association of migraine with aura and intracardiac or pulmonary shunting of blood from the venous to systemic arterial circulation. Right-to-left (R to L) shunting of blood, commonly through a patent foramen ovale (PFO), is present in 20% of the general population (3–5). This proportion increases to 50% to 60% in people who have migraine associated with visual aura (6–9).

The purpose of this study was: 1) to determine the frequency of R to L shunting in people who have visual aura, either with or without migraine headaches; and 2) to assess whether visual aura resolves after closure of R to L shunt in patients who have these visual symptoms with or without headache.

Methods

This study was approved by the Institutional Review Board. The study population consisted of 590 patients referred to the Interventional Cardiology program at UCLA between 2001 and 2011 for the assessment of conditions associated with PFO, including cryptogenic stroke, migraines, decompression illness, and orthodeoxia. Patients were assessed for the presence of migraine headaches and visual aura and specifically whether the transient visual symptoms occurred with or without headaches. Patients were screened for the presence of an R to L shunt by performing a transcranial Doppler (TCD) study with a power M-mode Terumo 150 PMD machine (Spencer Technologies, Seattle, Washington). A mixture of 8 ml normal saline combined with 0.5 ml of air and 1 ml of blood was agitated between 2 syringes connected by a 3-way stopcock and injected into the brachial vein; embolic tracks were then counted over the middle cerebral arteries. The degree of R to L shunt was evaluated by TCD at rest and with the Valsalva maneuver at 40 mm Hg, aided by visual feedback with a manometer device (10). The Spencer logarithmic scale was used to grade the results, where Grade 3 and higher (≥ 31 embolic tracks/60 s) was considered positive for a significant shunt (11).

For the purpose of this study, visual aura was defined as transient visual disturbance consisting of symptoms, including positive features (e.g., flickering lights, spots, or lines) and/or negative features (i.e., loss of vision). These symptoms were usually characterized by gradual development, duration of no longer than 1 h, a mix of positive and

negative features, and complete reversibility (1). The responses of the patients were used to classify patients into 3 groups (Table 1):

Group A) Visual aura associated with migraine headache: in this group of patients, the visual aura fulfilled the diagnostic criteria of the International Classification of Headache Disorders-2 (ICHD-2) for “typical aura with migraine headaches.”

Group B) Visual aura not associated in time with migraine headache: in this group, patients had both visual aura and migraine headaches but without a temporal association between them. Migraine headaches are present but are consistent with the ICHD-2 definition of: “Headache does not occur during aura nor follow aura within 60 minutes.”

Group C) Visual aura without a history of migraine: in this group, patients were characterized by the presence of typical visual aura that is commonly observed with migraine, but these patients were distinguished by having no history of headaches (1).

There were 80 patients with a history of stroke or severe debilitating migraines who had their PFO closed percutaneously. Post-closure assessment consisted of clinical evaluation and a transesophageal echocardiogram and TCD at 3 months. If there was a residual shunt by TCD \geq Grade 3, then the TCD was repeated at 3-month intervals up to 1 year or until complete resolution of the shunt, as evidenced by a negative TCD (Grade 0 to 2). After PFO closure, the visual symptoms and migraines of the patients were categorized under 4 subgroups: 1) “Resolved”: complete resolution of visual aura (and headache where applicable); 2) “Improved”: $\geq 50\%$ reduction in the number of aura events (and headache days/month where applicable); 3) “Worse”: $\geq 50\%$ increase in the number of aura (and headache days/month where applicable); and 4) “No Change”: symptoms remained the same ($< 50\%$ change) after PFO closure.

Control population. The control population consisted of 200 patients (49% men) who were referred to the cardiac catheterization laboratory for diagnostic catheterization that was unrelated to the presence of a PFO. Patients who had cardiac transplants were excluded from the control group, because they might have had their PFO closed at the time of surgery. Adults with a congenital heart disease known to be associated with a shunt were also excluded from the control group. The patients were asked to undergo a TCD either before or after their catheterization procedure while

Abbreviations and Acronyms

ICHD = International Classification of Headache Disorders

MH = migraine headache

PFO = patent foramen ovale

R to L = right-to-left

TCD = transcranial Doppler

Table 1. Definitions of Relationship Between Migraine and Visual Aura

Group A MH + aura	MH after visual aura or within 60 min
Group B MH + aura (unrelated)	Migraine and visual aura but temporally unrelated (i.e., not occurring within 60 min of each other)
Group C Aura only	No history of migraine headache; only visual aura
MH = migraine headache.	

they were waiting in the recovery area. They signed the Institutional Review Board-approved informed consent. The prevalence of R to L shunt in the control group was 18%. The demographic data of the control group are shown in Table 2. A history of migraine headaches was present in 11% of the control group, which is the expected prevalence in a population of mixed sex (in large population studies, 18% of women and 6% of men have migraine). There was only 1 patient in the control group who had a history of visual aura without migraines.

Statistical analysis. Continuous variables were expressed as mean ± SD. Nominal and dichotomous variables were expressed as frequency percentage. The SPSS statistical software (version 17.0, SPSS, Chicago, Illinois) was used for 2-tailed Student *t* test comparison between the groups and control population; *p* value ≤0.05 was considered statistically significant. Odds ratio with 95% confidence interval (CI) was used to compare the probability of having R to L shunt between the 3 study groups.

Results

Of the 590 patients screened, there were 225 patients (38%) who had visual aura with or without migraine; 91 (15%) patients had migraine headache without aura. Table 2 provides the clinical descriptors of the 3 patient populations and the control group. Table 3 further demonstrates the number of patients with visual aura who tested positive for an R to L shunt, the number of these patients who underwent PFO closure, as well as the device used.

Although the prevalence of R to L shunting was similar in Groups B versus C (*p* = 0.66), Group A patients had a significantly higher frequency of R to L shunting when compared with the other 2 groups. The prevalence of R to L shunt in Groups A, B, and C was significantly higher than the prevalence of R to L shunt in the control group (36 of 200 [18%]) (*p* < 0.0001). Compared with the control subjects, the odds ratio of having a PFO was 11.9 in Group B (95% CI: 4.9 to 29.1) and 9.1 in Group C (95% CI: 3.4 to 24.2). All 3 groups were highly selected, since most of these patients were referred to the interventional cardiology department because of a pre-existing suspicion of a PFO, whether due to an initial presentation with cryptogenic stroke or to a previously positive agitated saline bubble study on transthoracic echocardiogram.

Among the 225 patients with visual aura, PFO closure was performed in 80 patients (36%). This includes 67 of 168 (40%) patients in Group A, 8 of 21 (38%) patients in Group B,

Table 2. Clinical Descriptors of 3 Groups of Patients With Visual Aura

	Group A MH + Aura	Group B MH + Aura (Unrelated in Time)	Group C Aura Only	Combined Study Groups (Group A+B+C)	Control Subjects	<i>p</i> Value*
n	175	29	21	225	200	
Age, yrs	48 ± 13	49 ± 15	44 ± 14	48 ± 13	54 ± 17	0.0001
Male	56 (32%)	10 (35%)	12 (57%)	78 (35%)	98 (49%)	0.003
Reason for referral						
Stroke	121 (69.1%)	9 (31.0%)	6 (28.6%)	136 (60.4%)	—	—
Migraine	15 (8.6%)	1 (3.4%)	0 (0%)	16 (7.1%)	—	—
Transient neurologic symptoms	6 (3.5%)	3 (10.3%)	2 (9.5%)	11 (4.9%)	—	—
Decompression	3 (1.7%)	1 (3.4%)	0 (0%)	4 (1.8%)	—	—
Orthodeoxia	2 (1.1%)	0 (0%)	0 (0%)	2 (0.9%)	—	—
Embolic event other than stroke	9 (5.2%)	2 (6.9%)	0 (0%)	11 (4.9%)	—	—
More than one reason	16 (9.1%)	6 (20.7%)	0 (0%)	22 (9.8%)	—	—
Other	3 (1.7%)	7 (2.4%)	13 (50%)	23 (10.2%)	—	—
Hypertension	27 (15%)	8 (28%)	5 (24%)	40 (18%)	72 (36%)	0.0001
Hyperlipidemia	27 (15%)	7 (24%)	3 (14%)	37 (17%)	90 (40%)	0.0001
Diabetes mellitus	7 (4%)	0 (0%)	0 (0%)	7 (3%)	28 (14%)	0.0001
Hypercoagulability†	36 (21%)	7 (24%)	5 (24%)	48 (21%)	10 (5%)	0.0001

Values are n, mean ± SD, or n (%). **p* value comparing combined study groups versus control subjects. †Hypercoagulability states include use of oral contraceptive pill/hormone replacement therapy, pregnancy, factor V Leiden, prothrombin G20210A mutation, antiphospholipid antibodies, homocysteinemia, protein S deficiency, protein C deficiency, elevated lipoprotein A, antithrombin III deficiency, anticardiolipin AB, factor VIII activity, B2-glycoprotein-1 AB, and thrombocytosis.

MH = migraine headache.

Table 3. Frequency of R to L Shunt in 3 Groups of Patients With Visual Aura and Number of PFOs Closed Versus Control Subjects

	Group A MH + Aura	Group B MH + Aura (Unrelated)	Group C Aura Only	Control Subjects
n	175	29	21	200
Positive for R to L shunt	168 (96%) (p < 0.0001)*	21 (72%) (p < 0.0001)*	14 (67%) (p < 0.0001)*	36 (18%)
R to L shunts that were closed	67 (40%)	8 (38%)	5 (36%)	0 (0%)
PFO closure device used	9/34/24	0/3/5	1/0/4	—
CardioSEAL/Amplatzer/Helex				

Values are n or n(%). *p value comparing each group versus control subjects.
 MH = migraine headache; PFO = patent foramen ovale; R to L = right-to-left.

and 5 of 14 (36%) patients in Group C. Table 4 demonstrates the distribution of PFO closure and the outcomes of this procedure in these patients, both at the 3- and 12-month follow-up, respectively.

3-month follow-up (post-PFO closure). At 3 months after PFO closure, 60%, 25%, and 40% of patients in Groups A, B, and C, respectively, experienced an improvement of symptoms of migraine and visual aura (Fig. 1). Furthermore, 25%, 50%, and 40% of patients in Groups A, B, and C, respectively, experienced complete resolution of symptoms by 3 months. Combining these values, the fraction of patients who experienced either complete or partial (>50%) resolution of visual aura in Groups A, B, and C were 85%, 75%, and 80%, respectively, at 3-month follow-up (p = ns, comparing the 3 groups). The observed improvement or resolution of symptoms coincided with the disappearance of the R to L shunt.

12-month follow-up (post-PFO closure). Symptoms of migraine aura and headache continued to improve over time after closure of the PFO (Fig. 2). The observed resolution or improvement of symptoms coincided with resolution of the R to L shunt.

In Groups A, B, and C, 75%, 100%, and 100% of patients, respectively, who experienced an improvement in symptoms by 3 months were completely free from visual aura at the 12-month follow-up. This was true if the visual aura was either associated with migraine or was independent of the presence of headache. The improvement/resolution of visual aura coincided with improvement/resolution of migraine headache in every patient except in 2 cases.

By the 12-month follow-up, 52%, 75%, and 80% of patients in Groups A, B, and C, respectively, had complete resolution of symptoms.

The proportion of patients who experienced either complete or partial resolution of their symptoms by the 12-month mark was 76% in Group A, 75% in Group B, and 80% in Group C (p = NS, comparing all 3 groups).

Discussion

Migraine headache, present in approximately 12% of the general population, is one of the most frequent causes of disability in the United States (4). Among people with migraine, 20% describe transient visual deficits or aura that usually precede the headache but can occur simultaneously with the head pain (1,2). Our patient population had a higher proportion of migraine with aura (38%) as opposed to migraine without aura (15%). This might be due to selection bias of our patient population toward PFO-positive patients, which is consistent with prior observations that PFO is associated with typical migraine with aura (6-9).

Some migraineurs describe visual aura as a phenomenon that occurs independently in time from their headache. According to the ICHD, the headache and the aura must be separated at least by 1 h to fit this category. It is much less common to encounter people who deny ever having a headache but describe the same visual disturbances as reported in the migraineurs with aura. Because it is difficult to measure a

Table 4. Effect of PFO Closure on Patients With Visual Aura

	Group A (MH + Aura)		Group B (MH Unrelated to Aura)		Group C (Aura Only)	
	3-Month	12-Month	3-Month	12-Month	3-Month	12-Month
PFO closed, n	67		8		5	
Resolved	17 (25%)	35 (52%)	4 (50%)	6 (75%)	2 (40%)	4 (80%)
Improved	40 (60%)	16 (24%)	2 (25%)	0 (0%)	2 (40%)	0 (0%)
No change	3 (4.5%)	1 (1.5%)	1 (12.5%)	1 (12.5%)	0 (0%)	0 (0%)
Worse	4 (6.0%)	3 (4.5%)	1 (12.5%)	0 (0.0%)	0 (0%)	0 (0%)
Data unavailable	3 (4.5%)	12 (18%)	0 (0%)	1 (12.5%)	1 (20%)	1 (20%)

Values are n or n (%).
 Abbreviations as in Table 3.

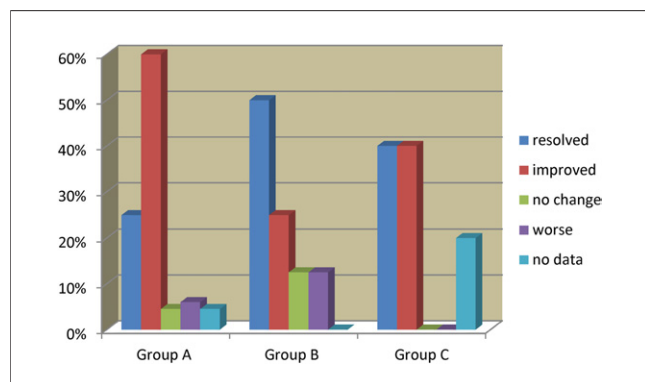


Figure 1. Effect of PFO Closure at 3-Month Follow-Up

Significant improvement (Group A) and resolution (Group B and Group C) of visual aura symptoms observed 3 months after patent foramen ovale (PFO) closure.

headache, it is unknown whether these 3 types of visual aura are due to the same mechanism of cortical spreading depression. Many headache specialists assume that they are similar and call the isolated visual auras “visual migraines.” Migraine visual aura without headache is present in 3.2% of the general population (2). This is similar to the frequency of people in our study population who presented with symptoms of visual migraines without headaches, 3.6% (21 of 590).

In this study, we observed:

1. Right-to-left shunting is present in approximately 18% of a control population as represented by adults without congenital heart disease who are referred for cardiac catheterization.
2. Right-to-left shunting occurs at a higher frequency than in control subjects ($p < 0.0001$) in patients with visual aura referred for evaluation of PFO. The frequency of R to L shunting is similar among the 3 categories of patients who present with visual aura ($p = ns$).
3. Patent foramen ovale closure results in a similar degree of improvement of visual aura among patients presenting with visual aura associated with migraine headache, visual aura unrelated in time to headache, and migraine visual aura without headache. The resolution of symptoms of aura coincided with the absence of a residual shunt on TCD. Although the magnitude of improvement could be due to a placebo effect, the outcome of PFO closure was similar in all 3 groups. Only a randomized double-blind trial would be able to distinguish the true effect of PFO closure in these patients.

The purpose of this study was to determine the prevalence of R to L shunt in patients with visual aura with and without migraine headaches and to assess whether the aura resolves after transcatheter PFO closure. Because a link between PFO and acephalgic migraines has never been documented in prior studies, a link between the 2 conditions would be a novel

observation. The common descriptor of R to L shunting indicates a similar pathophysiology for the 3 groups of people who have visual aura with or without headache.

Prior studies document an association between PFO and migraine headache with aura (6–9). This study extends this observation to include all visual auras, regardless of the presence of headache. We suspect that many transient neurologic deficits— with or without headache— in patients who have a PFO, may be manifesting a similar phenomenon as these patients with visual aura. We hypothesize that there is a spectrum of migraine cortical spreading depression that induces transient neurologic deficits, which may have visual, sensory, or motor components. These auras are due to chemical stimulants that pass through a PFO and bypass metabolism in the lung vasculature. These episodes may be difficult to distinguish clinically from transient ischemic attacks (which presumably are due to emboli) since both conditions are transient and leave no trace on magnetic resonance imaging.

The agreement on association between R to L shunt and migraine headache with aura is not unanimous (12–14). Garg et al. (12) determined the presence of PFO in patients with a well-defined history of migraine headaches. According to their results, not only was there no association between migraines and PFO but also no association between migraines and either the severity of shunting or presence of aura.

The MIST (Migraine Intervention with STARFlex Technology) trial was a randomized, double-blinded, sham-controlled trial that was undertaken to determine the benefit of PFO device closure compared with a sham procedure (15). In this controversial study, no significant difference was noted in the primary outcome of headache cessation between the 2 groups. Some investigators do not consider the MIST results to be conclusive, due to possible incomplete closure of the interatrial shunt in up to 35% of these patients (16). Separate reports demonstrate a residual shunt in over 28% of patients after PFO closure when devices similar to STARFlex (such as

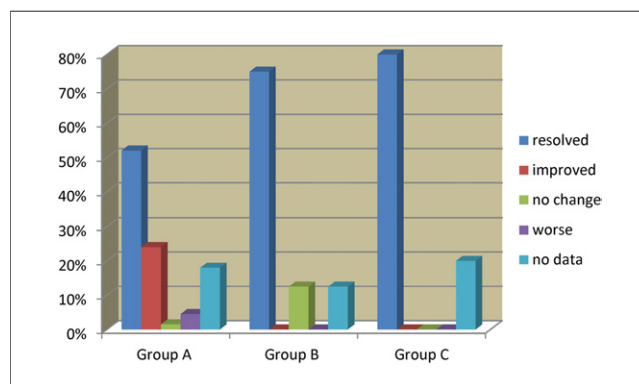


Figure 2. Effect of PFO Closure at 12-Month Follow-Up

Observed resolution of the visual aura symptoms at 12-month follow-up. PFO = patent foramen ovale.

CardioSEAL and BioStar [Nitinol Medical Technologies, Boston, Massachusetts]) are used (17). Furthermore, the MIST trial included patients with severe refractory migraine with no other indication for PFO closure; this population was different from our observational study.

Study limitations. The prevalence of R to L shunt was higher than expected, due to the study population being selected for PFO-related conditions—be it due to cryptogenic stroke, decompression illness, or debilitating migraines. Furthermore, significant loss of data occurred, especially at the 12-month follow-up. Of 80 patients who had their PFO closed, 14 (17.5%) were lost to follow-up at the 12-month interval. There might have been more patients whose visual aura resolved after PFO closure. Thus, the number of patients who benefited from PFO closure might have been underestimated.

Conclusions

These observations support the hypothesis that the phenomenon of migraine aura without headache might be causally linked to R to L shunting in most cases. However, R to L shunting of blood is not the only mechanism that produces visual aura, because we observed 7 of 21 (33%) people who had visual aura without headache but no evidence for R to L shunting. But the high prevalence of R to L shunting in this population, 3× the observed frequency in the control group, is consistent with the hypothesis that intermittent R to L shunting through a PFO permits chemical substances that are usually cleared by the lungs, to bypass the metabolism in the lungs and reach the brain at a higher concentration via direct entry into the arterial circulation (12). The mechanism is consistent with the high correlation between PFO and migraine with aura and might explain why visual aura symptoms are frequently alleviated after PFO closure.

Reprint requests and correspondence: Dr. Jonathan Tobis, Department of Medicine, UCLA Medical Center, B976 Factor Building CHS, 10833 Le Conte Avenue, Los Angeles, California 90095. E-mail: jtobis@mednet.ucla.edu.

REFERENCES

1. Headache Classification Subcommittee of the International Headache Society. The International Classification of Headache Disorders, 2nd edition. *Cephalalgia* 2004;24 Suppl 1:9-160.
2. Aiba S, Tatsumoto M, Saisu A, et al. Prevalence of typical migraine aura without headache in Japanese ophthalmology clinics. *Cephalalgia* 2010;30:962-7.
3. Hagen PT, Scholz DG, Edwards WD. Incidence and size of patent foramen ovale during the first 10 decades of life: an autopsy study of 965 normal hearts. *Mayo Clin Proc* 1984;59:17-20.
4. Schwarczman M, Nedelstshev K, Lager F, et al. Prevalence in size of directly detected patent foramen ovale in migraine with aura. *Neurology* 2005;65:1415-8.
5. Anzola GP, Magoni M, Guendani M, Rozzini L, Dalla Volta G. Potential source of cerebral embolism in migraine with Aura: a transcranial Doppler study. *Neurology* 1999;52:1622-5.
6. Lipton RB, Bigal ME, Diamond M, et al., for the AMPP Advisory Group. Migraine prevalence, disease burden and the need for preventive therapy. *Neurology* 2007;68:343-9.
7. Azarbal B, Tobis JM, Suh W, Chan V, Dao C, Gaster R. Association of interatrial shunts and migraine headaches: impact of transcatheter closure. *J Am Coll Cardiol* 2005;45:489-92.
8. Dalla Volta G, Guindani M, Zavarise P, Griffini S, Pezzini A, Padovani A. Prevalence of patent ovale in large series of patients with migraines with aura, migraine without aura and cluster headache, and relationship with clinical phenotype. *J Headache Pain* 2005;6:328-30.
9. Domitrz I, Mieszkowski J, Kamińska A. Relationship between migraine and patent foramen ovale: a study of 121 patients with migraine. *Headache* 2007;47:1311-8.
10. Van H, Poommipanit P, Shalaby M, Gevorgyan R, Tobis JM. Sensitivity of transcranial Doppler versus intracardiac echocardiography in the detection of right-to-left shunt. *J Am Coll Cardiol Img* 2010;3:343-8.
11. Spencer MP, Moehring MA, Jesurum J, Gray WA, Olsen JV, Reisman M. Power M-mode transcranial Doppler for diagnosis of patent foramen ovale and assessing transcatheter closure. *J Neuroimaging* 2004;14:342-9.
12. Garg P, Servoss SJ, Wu JC, et al. Lack of association between migraine headache and patent foramen ovale: results of a case-control study. *Circulation* 2010;121:1406-12.
13. Rundek T, Elkind MS, Di Tullio MR, et al. Patent foramen ovale and migraine: a cross-sectional study from the Northern Manhattan Study (NOMAS). *Circulation* 2008;118:1419-24.
14. Dowson A, Mullen MJ, Peatfield R, et al. Migraine intervention with STARFlex technology (MIST) trial: a prospective, multicenter, double-blind, sham-controlled trial to evaluate the effectiveness of patent foramen ovale closure with STARFlex septal repair implant to resolve refractory migraine headache. *Circulation* 2008;117:1397-404.
15. Tobis JM. Management of patients with refractory migraine and PFO: is MIST I relevant? *Catheter Cardiovasc Interv* 2008;72:60-4.
16. Van den Branden BJ, Luermans JG, Post MC, Plokker HW, Ten Berg JM, Suttrop MJ. The BioStar(r) device versus the CardioSEAL(r) device in patent foramen ovale closure: comparison of mid-term efficacy and safety. *EuroIntervention* 2010;6:498-504.
17. Tobis JM, Azarbal B. Does patent foramen ovale promote cryptogenic stroke and migraine headaches? *Tex Heart Inst J* 2005;32:362-5.

Key Words: migraine headache ■ patent foramen ovale (PFO) ■ right-to-left shunt ■ visual aura without headache.