

Contents lists available at ScienceDirect

Trauma Case Reports

journal homepage: www.elsevier.com/locate/tcr

Case Report

Blunt pharyngeal trauma detected by ultrasound sonography: A case report

Tadao Kubota ^{*}, Mayu Shimaguchi, Hideki Katagiri, Ken Mizokami

Todaijima 3-4-32, Urayasu, Chiba 279-0001, Japan

ARTICLE INFO

Article history:

Accepted 28 May 2016

Available online 1 July 2016

Keywords:

Blunt neck trauma

Pharyngeal perforation

Ultrasound sonography

ABSTRACT

Pharyngeal perforation related to blunt neck trauma is a rare clinical entity. Here in, we report a case of pharyngeal perforation secondary to minor blunt neck trauma. A 46 year old female was brought to our emergency room with neck pain. She fell down and hit her neck directly to the edge of a bed. There was no crepitation in physical examination. Neck ultrasound showed a small amount of air in her deep neck space. Followed CT and nasopharyngeal scope supported the presence of pharyngeal perforation. So emergency exploration was done. We found a laceration of hypopharynx and it was repaired. She could discharged without any complication on day 7. The indirect finding of pharyngeal perforation is subcutaneous emphysema. However if the air is localized only in deep cervical space, physical assessment is difficult. Although CT scan is potent modality to find air in the deep organs, ultrasound may be alternatives. Emphasis is based on the suspicion that minor blunt neck trauma may cause pharyngeal perforation.

© 2016 The Authors. Published by Elsevier Ltd. This is an open access article under the CC BY-NC-ND license

(<http://creativecommons.org/licenses/by-nc-nd/4.0/>).

Background

Blunt pharyngeal perforation is rare. It is under 2% of all pharyngeal lesions [1]. Most of them occurred due to high energy injury such as motor vehicle accidents [2], so surgically important pharyngeal injury secondary to minor trauma is extremely rare. We report a case of pharyngeal perforation related to low energy injury. Delay to diagnosis of this condition may lead to severe retro-mediastinal infection which needs long time hospitalization or sometimes causes death. Early diagnosis and surgical repair are critical. In our case, we detected suspicious pharyngeal perforation using ultrasound sonography.

^{*} Corresponding author. Tel.: +81 47 351 3101; fax: +81 47 352 6237.

E-mail address: tadaokubota@mac.com (T. Kubota).

Case report

A 46 year old female was referred from the emergency department with a neck pain and difficulty to swallow. According to a witness, she fell down in her room and hit her neck directly to the edge of a bed. She had mental retardation and epilepsy. Her mother said that she often fell down because of uncontrolled general convulsion. There were mixed old bruises and new ones in her face. She had already lost all her front teeth. Primary survey was done with no abnormality. In the secondary survey, her neck was swollen with a fresh bruise on the left side (Fig. 1). On physical examination there was localized tenderness on her neck, crepitation was unclear. She was unable to swallow saliva at all, so she constantly spat out bloody saliva. We thought she might have pharyngeal injury. At first, we had tried to see her pharyngeal mucosa using nasopharyngeal scope to get a direct finding. However it failed with poor examination. The left side of the pharyngeal mucosa was bleeding and edematous, so we could suspect the presence of a pharyngeal injury but couldn't get an evidence of the perforation. Next, we examined her neck using ultrasound sonography. It revealed some hyperechoic spots which meant extraluminal air in the deep neck space (Fig. 2). Air was distributed mainly around the pharynx and cervical esophagus rather than larynx and trachea. Finally neck CT scan was done, it showed deep cervical emphysema which was definitive evidence of the perforation in either the air way or alimentary tract (Fig. 3). There were no fractures of the cartilages. According to these findings, she should have symptomatic pharyngeal perforation, so we decided to do emergent neck exploration. Under general anesthesia, a standard neck oblique incision was made. Larynx and trachea were intact. We found a small amount of hematoma and a laceration, 1 cm in diameter on the left inferior pharyngeal muscle (Fig. 4). The laceration was closed by interrupted suture with polyfilament absorbable stitch. The retrocervical space was drained with a closed suction system. The day after surgery, she could swallow saliva. One week after surgery she discharged without any complications.

Discussion

The most common cause of pharyngeal injury is iatrogenic, especially after difficult endotracheal intubation [3]. Surgically repaired pharyngeal perforation secondary to blunt trauma is rare [2,4]. She must be unconscious at that time because of general convulsion, so her body weight was concentrated on her neck. The force of blow might be relatively high. Even so, isolated blunt neck trauma with pharyngeal perforation caused by low energy is extremely rare. When we encounter an isolated minor blunt neck trauma patient, we rarely think that patient may have pharyngeal perforation. In that situation, CT scan is not ordered routinely. It is easy for us to suspect it if we find crepitation around the neck of a patient. But if a patient is asymptomatic, most physicians tend to think that further examination is unnecessary.

On the other hand, delayed diagnosed pharyngeal perforation is known as a source of severe retropharyngeal or mediastinal infection which sometimes needs aggressive drainage and long time intensive care [5]. Its mortality and morbidity rates remain high. In abdominal trauma, ultrasound sonography is

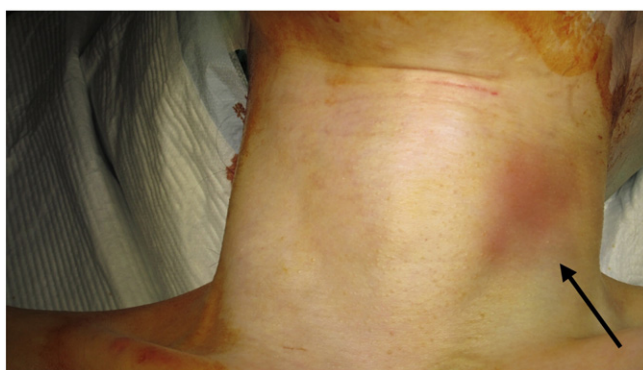

Fig. 1. Neck bruise. An arrow showed a bruise on left side of the neck.

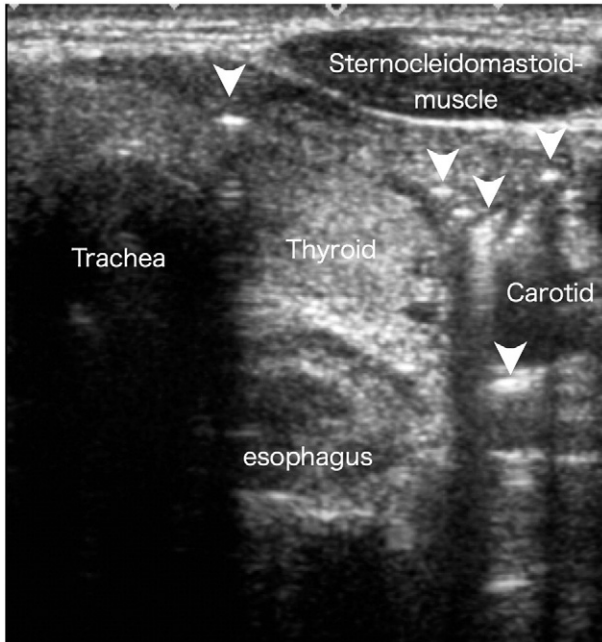


Fig. 2. Ultrasound. Each arrow head showed air in the deep neck space, which was detected as high echoic spots with shadow. The air was distributed around the pharyngoesophagus lesion rather than trachea.

established as an absolutely necessary modality. The significance of FAST (Focused Assessment with Sonography in Trauma) is common understanding. Some authors reported the usefulness of ultrasound for thoracic injury to detect traumatic pneumothorax [6]. Recently the application of chest ultrasound has been spreading to the non-traumatic situation in the field of critical care [7]. However, the neck ultrasound as a modality for trauma evaluation has been rarely published except for the insertion of catheters. In this case, we showed its possibility. The resolution of ultrasound is higher than that of CT scan, so each anatomical structure is clearly visualized. Air in the tissue is detected as high echoic spots with shadow. So its sensitivity and specificity are very high that we can get it even if very small amount. In general, it is thought that ultrasound is good to evaluate small parts and soft tissues. The management of pharyngeal perforation related to blunt trauma is controversial. There are several reports of non-operatively improved minor hypopharyngeal

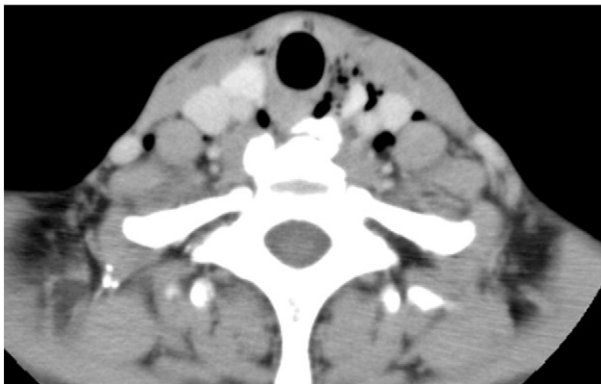


Fig. 3. CT scan. Neck CT showed some air in the deep neck space.

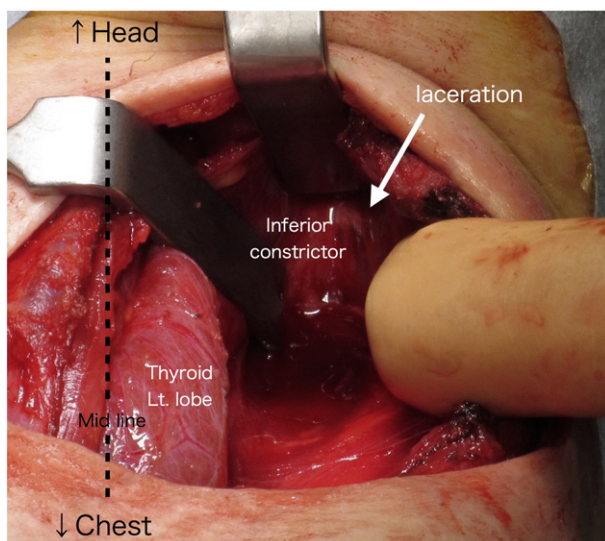


Fig. 4. Intraoperative view. An arrow showed a laceration of left pharyngeal muscle.

perforation [8,9]. Niezgoda and colleagues reviewed the literature and divided these eleven cases into 2 categories depending on the management either surgical or non-surgical [10]. They said non-surgical treatment is reserved for patients with small laceration, less than 2 cm in diameter and limited to the pharynx. The case with large laceration or extended to esophagus should be surgically repaired. In our case, the size of laceration was under 2 cm. The reason why we decided to go to operating room was that she had serious dysphagia. Symptomatic injury is another indication.

Conclusion

We learned two things from this patient. When the patient gets a pin point blow on one's neck, pharyngeal perforation is one of differential diagnosis even if it is a low energy injury. To evaluate extraluminal air in one's deep neck space, ultrasound sonography is a potent modality. We think its worth to be tried by all emergency physicians and trauma surgeons.

References

- [1] B.E. Berry, J.L. Ochsner, Perforation of the esophagus: 30 year review, *J. Thorac. Cardiovasc. Surg.* 65 (1973) 1–7.
- [2] K.D. Hagra, R. Tabah, Pharyngeal perforation caused by blunt trauma to the neck, *Can. J. Surg.* 46 (2003) 57–58.
- [3] T. Lee, J. Jordan, Pyriform sinus perforation secondary to traumatic intubation in a difficult airway patient, *J. Clin. Anesth.* 6 (1996) 152–155.
- [4] B. Pathak, D.C. Yu, B.C. Linden, Transoral closure of a perforation of the hypo pharynx from blunt trauma, *J. Pediatr. Surg.* 44 (2009) 2402–2405.
- [5] S.M. Selbst, J.A. Fein, J. Friday, et al., Retropharyngeal abscess after blunt trauma in an adolescent, *Pediatr. Emerg. Care* 14 (1998) 406–408.
- [6] S.R. Williams, P. Perera, L. Gharahbaghian, The FAST and E-FAST in 2013: trauma ultrasonography: overview, practical techniques, controversies and new frontiers, *Crit. Care Clin.* 30 (2014) 119–150.
- [7] N. Xirouchanki, E. Magkanas, K. Vaporidi, et al., Lung ultrasound in critically ill patients: comparison with bedside chest radiography, *Intensive Care Med.* 37 (2011) 1488–1493.
- [8] D. Smith, S. Woolley, Hypopharyngeal perforation following minor trauma: a case report and literature review, *Emerg. Med. J.* 23 (2006), e7.
- [9] N.S. Salemis, C. Georgiou, E. Alogdianakis, et al., Hypopharyngeal perforation because of blunt neck trauma, *Emerg. Radiol.* 16 (2009) 71–74.
- [10] J.A. Niezgoda, P. Mc Menamin, G.M. Graeber, Pharyngoesophageal perforation after blunt neck trauma, *Ann. Thorac. Surg.* 50 (1990) 615–617.