

Contents lists available at [ScienceDirect](http://www.sciencedirect.com)

# American Journal of Ophthalmology Case Reports

journal homepage: <http://www.ajocasereports.com/>

## Case report

# Chemotherapy-induced anterior necrotising scleritis: A case report



Achini K. Makuloluwa\*, Shafiulla Khaji, Zahra Bile, Vikas Shankar

Ophthalmology Department, Burnley General Hospital, Casterton Avenue, Burnley, Lancashire BB10 2PQ, United Kingdom

## ARTICLE INFO

### Article history:

Received 24 January 2016

Accepted 1 June 2016

Available online 3 June 2016

### Keywords:

Anterior necrotising scleritis

Chemotherapy

Adverse event

Gemcitabine

Carboplatin

## ABSTRACT

**Purpose:** We describe a case of anterior necrotising scleritis secondary to Gemcitabine and Carboplatin chemotherapy agents in a patient with metastatic breast cancer, which has not been previously reported. **Observations:** A 50-year-old lady with recurrent metastatic breast cancer presented with unilateral subconjunctival haemorrhage secondary to severe thrombocytopenia eight days following palliative chemotherapy in the form of Gemcitabine and Carboplatin. Twelve days following the initial presentation, the subconjunctival haemorrhage had resolved, however there was evidence of anterior necrotising scleritis with anterior chamber reaction and hypotony with choroidal effusion. This resolved with three days of intravenous Methylprednisolone along with topical steroids and the area of necrosis remained stable.

**Conclusions and importance:** Due to the chronological order of events, we infer a Gemcitabine and Carboplatin-induced anterior necrotising scleritis, which has not been previously reported.

© 2016 The Authors. Published by Elsevier Inc. This is an open access article under the CC BY-NC-ND license (<http://creativecommons.org/licenses/by-nc-nd/4.0/>).

## 1. Introduction

We describe here a case of anterior necrotising scleritis secondary to combination of Gemcitabine and Carboplatin chemotherapy, which following extensive literature search has not been previously reported.

## 2. Case report

A 50-year old lady with recurrent breast cancer (ER/PR/HER-2 negative) and brain, supraclavicular, mediastinal and lung metastases presented with one-day history of right eye subconjunctival haemorrhage and epistaxis. She had Gemcitabine (1786 mg) and Carboplatin (400 mg) as part of palliative chemotherapy eight days previously. The patient was formally also admitted with pancytopenia and haemo-dynamically unstable epistaxis eight days following Gemcitabine and Carboplatin chemotherapy and subsequently had the doses reduced.

When this patient was diagnosed with right breast carcinoma, she had a mastectomy, axillary node clearance and completed six cycles of Fluorouracil, Epirubicin hydrochloride and Cyclophosphamide chemotherapy combination with Neulasta cover. She did not have life-threatening side effects during this period.

On the current presentation, BCVA was OD 6/36 and OS 6/12. Patient had a known visual field defect secondary to the brain metastases. On examination, there was a dense right subconjunctival haemorrhage and associated proptosis with mild restriction of ocular movements in all gazes. Examination of cornea, pupil and fundus were unremarkable. The patient was diagnosed with extensive subconjunctival haemorrhage and epistaxis secondary to severe thrombocytopenia of  $5 \times 10^9/L$ , and she was referred to the medical team for management of the global pancytopenia.

On day 4, she developed lid oedema and was treated with intravenous Tazocin with Teicoplanin for probable pre-septal cellulitis. Orbital cellulitis and metastases were ruled out with CT and MRI scans respectively.

On day 6, both pre-septal component and subconjunctival haemorrhage improved. However, patient developed corneal oedema and anterior chamber cells with fibrin and posterior synechiae. Treatment was started as hourly prednisolone 1%, two-hourly Exocin and once-a-day atropine 1% eye drops with lubricants. The patient continued on 8 mg Dexamethasone orally as part of her chemotherapy regime.

On day 12, there were signs of anterior necrotising scleritis, measuring  $10 \times 10$  mm nasally at limbus with persistent corneal oedema, anterior chamber fibrin and choroidal effusion (kissing choroidals) with intra-ocular pressure (IOP) of 0 mmHg (Fig. 1). Intravenous Methylprednisolone 1 g for three days was initiated in addition to the above treatment. Following two doses of

\* Corresponding author.

E-mail address: [achini.makuloluwa@gmail.com](mailto:achini.makuloluwa@gmail.com) (A.K. Makuloluwa).

intravenous Methylprednisolone, IOP improved to 10 mmHg and choroidal effusion resolved.

By day 15, right eye vision improved to 6/60 from hand movements. Cornea was clearer and did not show signs of anterior chamber reaction or fibrin with the area of necrosis remaining stable. The disc and macula remained healthy.

Since the above chemotherapy regime was poorly tolerated regardless of the partial response, it was discontinued and changed to oral Vinorelbine along with 8 mg oral Dexamethasone by her oncology team. At present, right eye vision is 6/60 and the eye is quiet. There is an area of deep pigmentation nasally with conjunctival loss representing the necrotising scleritis. Topically, the patient continues on prednisolone 1% eye drops twice per day along with lubricants.

### 3. Discussion

Extensive database search did not reveal any reported cases of anterior necrotising scleritis secondary to Gemcitabine and Carboplatin chemotherapy regime.

Globally, breast cancer remains the commonest cancer affecting the female population. Gemcitabine and platinum agents have synergistic effects as described below by their mechanisms of action. Both Gemcitabine and Carboplatin potentiate myelosuppression, including thrombocytopenia and that due to Carboplatin is both dose-, and exposure-dependent.<sup>1,2</sup>

Gemcitabine is a deoxycytidine nucleoside analogue, which is phosphorylated once entering the cell to active metabolites, namely gemcitabine diphosphate and triphosphate.<sup>1</sup> The latter compound acts as a fraudulent base and integrates with DNA instead of deoxycytidine triphosphate (dCTP).<sup>1</sup> This results in cessation of DNA synthesis secondary to masked chain termination.<sup>1</sup> The gemcitabine diphosphate metabolite inactivates ribonucleotide reductase which catalyses dCTP.<sup>1</sup> Reduction in dCTP potentiates gemcitabine phosphorylation and integration of gemcitabine triphosphate with DNA, hence preserving the active metabolites in tumour cells.<sup>1</sup>

Carboplatin is a cisplatin analogue, which interacts with water molecules once entering the cell.<sup>2</sup> Carboplatin forms intrastrand adducts and interstrand cross-links via covalent bonds with nucleophilic sites on guanine and adenine purines.<sup>2</sup> These adducts impede DNA transcription and replication resulting in miscoding and breaks in DNA.<sup>2</sup> Henceforth, apoptosis is induced via

regulators, such as p53<sup>2</sup>. Consequently, there is an increased demand for DNA repair molecules such as dCTPs, production of which is inhibited by gemcitabine as described above.<sup>2</sup>

A review of the role of platinum agents in breast cancer has stated that carboplatin was associated with an acute hypersensitivity reaction usually with repeated exposure, which in turn may permit ‘immune reconstitution’.<sup>2</sup> This may explain the inflammatory process described in our patient as an anterior necrotising scleritis, which rapidly responded to immunosuppression. We ruled out other causes of infectious and non-infectious causes of anterior scleritis with the use of blood tests. Our patient’s ACE levels were low, which may be secondary to steroid therapy, whilst urate levels were just above the normal range, which was likely to be secondary to chemotherapy. She tested negative for ANCA, Rheumatoid factor, Syphilis IgG and IgM. Although screening for ANA’s showed a homogenous staining pattern with positive antibodies to Ro, antibodies to dsDNA, La, Sm tested negative. Although the patient was not tested for herpes simplex and herpes zoster viruses, given that the inflammatory process settled with steroids without the use of antivirals insinuate them as an unlikely culprit. Previously it has been noted that especially in scleritis associated with seropositive connective tissue disorders, capillaries become under-perfused and eventually obstructed by thrombi with sustained inflammation leading to areas of avascular tissue.<sup>3</sup> However, our patient is unlikely to have had avascular necrotising scleritis, again because of immediate response to the immunosuppression as well as insufficient immunology screening result to suggest an underlying seropositive disease.

There have been previous reports of drug-induced scleritis, largely secondary to bisphosphonate use. A case series reported intravenous pamidronate-induced unilateral scleritis, 16 of 17 which were anterior and one of which was posterior scleritis.<sup>4</sup> They postulated that cytokines released from a discrete class of T cells inhibiting bone resorption resulted in an immunological reaction.<sup>4</sup> Drug discontinuation led to resolution of scleritis.<sup>4</sup> Another case series showed scleritis associated with alendronate.<sup>5</sup> Two patients developed posterior scleritis and lid oedema with or without myositis ten days and three weeks following alendronate therapy respectively.<sup>5</sup> There was a dramatic improvement with steroids.<sup>5</sup> One patient developed anterior nodular scleritis and lid oedema five months after alendronate therapy and this resolved with diclofenac, a non-steroidal anti-inflammatory agent.<sup>5</sup> Alendronate was implicated due to the temporal relationship with the ocular manifestations and was discontinued.<sup>5</sup> Furthermore, there has been a reported case of symmetrical polyarthropathy, orbital myositis and posterior scleritis ten days following administration of 1993 Fluvirin vaccine.<sup>6</sup> There was significant resolution of symptoms with 40 mg of oral prednisolone.<sup>6</sup> The authors implicated the flu vaccine due to the sequential association of symptoms and suggested possible formation of immune complexes in type III hypersensitivity as the underlying process.<sup>6</sup>

### 4. Conclusions

Due to the chronological order of events with an immediate response to immunosuppression, we infer a Carboplatin, and possibly Gemcitabine-induced anterior necrotising scleritis.

### 5. Patient consent

The patient consented orally to the publication of this case report.

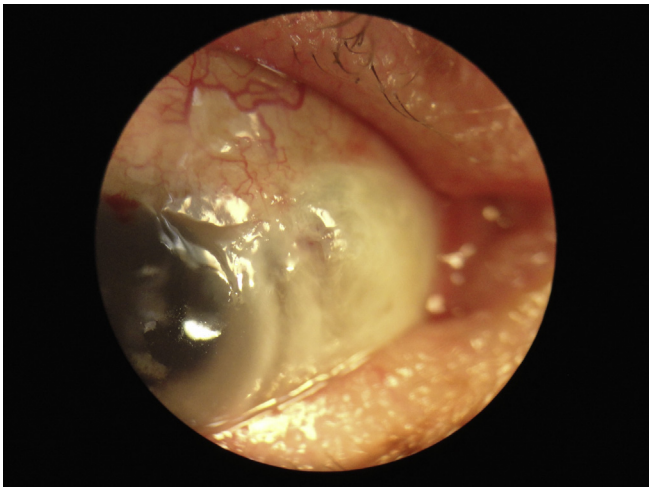


Fig. 1. Nasal aspect of sclera representing the anterior necrotising scleritis.

**References**

- [1] V. Heinemann, Role of gemcitabine in the treatment of advanced and meta-static breast cancer, *Oncology* 64 (2003) 191–206.
- [2] W.M. Sikov, Assessing the role of platinum agents in aggressive breast cancers, *Curr Oncol Rep* 17 (2015) 3.
- [3] P.G. Watson, B.L. Hazleman, et al., *The Sclera and Systemic Disorders*, third ed., JP Medical Ltd, London, 2012.
- [4] F.W. Fraunfelder, F.T. Fraunfelder, B. Jensvold, Scleritis and other ocular side effects associated with pamidronate disodium, *Am J Ophthalmol* 135 (2003) 219–222.
- [5] J.N. Mbekeani, T.L. Slamovits, B.H. Shwartz, et al., Ocular inflammation associated with alendronate therapy, *JAMA Ophthalmol* 117 (1999) 837–838.
- [6] G. Thurairajan, M.W. Hope-Ross, R.D. Situnayake, et al., Polyarthropathy, myositis and posterior scleritis: an unusual adverse reaction to influenza vaccine, *Br J Rheumatol* 36 (1997) 120–123.