

# Contemporary Stent Treatment of Coronary Bifurcations

Ioannis Iakovou, MD, Lei Ge, MD, Antonio Colombo, MD

Milan, Italy

Treatment of coronary bifurcation lesions represents a challenging area in interventional cardiology. The introduction of drug-eluting stents (DES) reduced restenosis in the main branch (MB). However, restenosis at the ostium of the side branch (SB) remains a problem. Although stenting the MB with provisional SB stenting seems to be the prevailing approach, in the era of DES various two-stent techniques emerged (crush) or were re-introduced (V or simultaneous kissing stents, crush, T, culottes, Y, skirt) to allow stenting in the SB when needed. This review describes in detail various techniques used for implantation of two stents by intention to treat. (J Am Coll Cardiol 2005;46:1446–55) © 2005 by the American College of Cardiology Foundation

Recent advances in percutaneous coronary interventions and lately the introduction of drug-eluting stents (DES) have led to the dramatic increase in the number of patients treated percutaneously (1–5). Bifurcation lesions are one of the complex lesion subsets that are now being confronted more frequently. Bifurcation interventions, when compared with nonbifurcation interventions, have a lower rate of procedural success and a higher rate of restenosis (6–8). Various techniques with the use of one or two stents have been developed to optimize the treatment of this subset of lesions (6–15). Paradoxically, although stenting of individual lesions has been shown to be superior to balloon angioplasty, stenting of both branches seems to offer no advantage over stenting of the main branch (MB) alone (8). The recent introduction of DES has resulted in a lower event rate and reduction of MB restenosis in comparison with historical controls (16). However, side branch (SB) ostial restenosis remains a problem.

## ANATOMICAL CONSIDERATIONS

Bifurcations have been classified previously according to the angulation between the main and the SB and according to the location of the plaque burden. Regarding the former, the bifurcations are classified as Y-shaped lesions, when the angulation is  $<70^\circ$  and access to the SB is usually easy but plaque shifting is more pronounced, and T-shaped lesions, when the angulation is  $>70^\circ$  and access to the SB is usually more difficult but plaque shifting is often minimal. This angulation is modified after wiring both branches. Regarding plaque distribution, there have been four major attempts to categorize bifurcations, which chronologically are the Duke (Fig. 1A) (17), the Sanborn (Fig. 1B) (18), the Safian (Fig. 1C) (19), and the Lefevre (Fig. 1D) classifications (20). The above attempts are very commendable but suffer the limitations of coronary angiography (different plaque distribution and extent of disease when evaluated by intravascular ultrasound), and they do not take into account what happens to the SB on dilatation of the MB. Therefore, each

lesion must be approached therapeutically in the context of its own anatomy.

## DES AND BIFURCATIONS

Until now, there have been only two randomized studies and some observational reports that specifically addressed the issue of bifurcational lesion treatment with DES (16,21–23). The recently published sirolimus-eluting stent (SES) bifurcational study emphasized the persistent limitations related to the routine stenting of the SB (16). In another study, stenting for the MB and balloon dilatation for the SB was compared with stenting for both branches. Similar to the previous study, there were no statistically significant differences between the two strategies (22).

## THROMBOTIC ISSUES AFTER DES IMPLANTATION IN BIFURCATIONS

Pathologic studies have suggested that arterial branch points are foci of low shear and low flow velocity and are sites predisposed to the development of atherosclerotic plaque, thrombus, and inflammation (24–26). The two or even three layers of struts (with crush) of DES apposed to the vessel wall initially raised concerns about possible increased thrombogenicity. Furthermore, delayed endothelialization associated with DES may extend the risk of thrombosis beyond 30 days (27). In the SES bifurcational study, the rate of stent thrombosis was 3.5%. Recently we reported in a prospective observational cohort study a rate of 3.6% of cumulative stent thrombosis at nine-month follow-up after DES implantation in bifurcations (28).

## ONE OR TWO STENTS?

Is the SB large enough (2.5 mm in the U.S., and 2.25 mm where smaller DES stents are available) with a sufficient territory of distribution to justify stent implantation? This initial question must be answered before going into further detail. There are also rare circumstances in which the SB is important and cannot be wired. In this situation the operator must consider alternative solutions, such as bypass

From the Centro Cuore Columbus and San Raffaele Hospital, Milan, Italy.  
Manuscript received March 17, 2005; revised manuscript received April 23, 2005,  
accepted May 23, 2005.

#### Abbreviations and Acronyms

DES = drug-eluting stent  
MB = main branch  
SB = side branch  
SES = sirolimus-eluting stent

surgery if the bifurcation in question is the left main or the left anterior descending vessel and a large diagonal vessel.

In general, we try not to stent the SB, but if needed, we plan an effective strategy for stenting both branches. The decision to use one or two stents, or sometimes even three (in case of a trifurcation), should be made as early as possible. An appropriate and timely taken decision will affect the results, save time, lower costs, and lower the risk of complications. If we decide to use one stent (at the MB), there is almost always the possibility of placing a second stent on the SB in case the result is not optimal or adequate. This condition is defined as provisional stenting.

#### SELECTION OF GUIDING CATHETER

The selection of the size (6-F, 7-F, or 8-F) of the guiding catheter occurs after deciding whether or not to stent the SB. Treatment of bifurcations frequently requires simultaneous insertion of two balloons or two stents; therefore, some specific considerations regarding the selection of an appropriate guiding catheter are important. With the currently available low-profile balloons (e.g., Maverick, Boston Scientific, Natick, Massachusetts), it is possible to insert two balloons inside a large-lumen 6-F guiding catheter. If two stents are needed, some limitations should be understood. The two stents can only be inserted one after the other, not simultaneously, in a 6-F guiding catheter. The standard crush and the V or simultaneous kissing stents technique cannot be performed unless a guiding catheter of at least 7-F, with an internal lumen diameter of 0.081 inches (2.06 mm) for the Taxus stent (Boston Scientific) or 8-F with an internal lumen diameter of 0.088 inches (2.2 mm) for the Cypher (Cordis, Johnson and Johnson, Warren, New Jersey) stent, is used. A 6-F guiding catheter can be used if the operator performs a provisional stenting technique with a second stent (for the SB) that is advanced after positioning the first stent in the MB. Techniques such as the T, the reverse crush, and the step crush (see later for a description of each technique) can all be used with a 6-F guiding catheter. The modified T technique requires at least a 7-F guiding catheter, and the culottes, Y, and skirt techniques require at least 8-F guiding catheters.

#### ONE STENT BY INTENTION TO TREAT

The most common approach in the treatment of bifurcations is stenting only the MB.

The first step is to decide whether a wire is needed in the SB. We propose that a wire is needed in the following circumstances: 1) the operator is undecided regarding

whether or not to place a wire, 2) the SB has a narrowing at its ostium, 3) the MB has severe stenosis with a large plaque burden and the SB originates with an angle of  $\leq 45^\circ$ , or 4) the ostium of the SB deteriorates after pre-dilatation of the MB.

The second step is to decide whether pre-dilatation of the MB and/or the SB is required.

The third step is to place a stent in the MB. The stent should be deployed at low pressure (8 atm) so as not to damage the trapped wire in the SB or to deteriorate the ostium of a SB without a wire across the stent struts of the MB.

The fourth step is to place a wire into the SB; this procedure can be performed with the wire trapped behind the stent serving as a marker. Regarding the wire of choice for re-entering the SB, we prefer first to use a floppy wire such as the Balance Universal (Guidant, Temecula, California); if not successful, we would then try an intermediate wire or a Rinato wire (Asahi Intecc [Thailand] Co. Ltd., Pathumthani, Thailand), and in rare cases we may use a hydrophilic wire such as the Pilot 50 or 150 (Guidant).

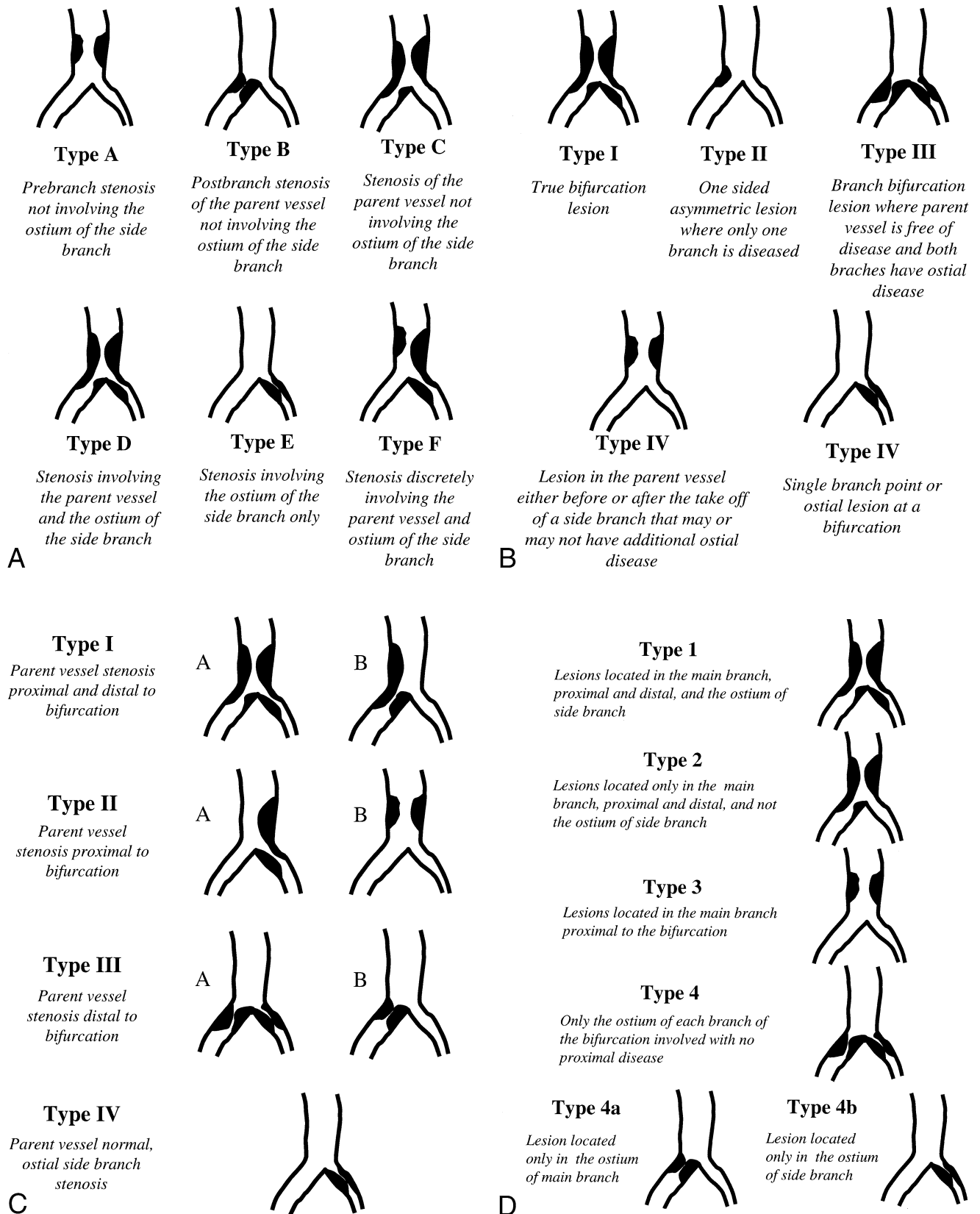
The fifth step, after having rewired the SB, is to post-dilate the MB stent at high pressure. We may use the same balloon for stent delivery, or if we are concerned about distal or proximal dissections, we will use a short balloon, usually noncompliant. If we think that the stent may be underdeployed, especially in its proximal part, it is important to perform sequential step inflations with the short balloon.

In the sixth step, the results are evaluated. At the level of the MB, the results should be optimal, or higher-pressure dilatation should be performed. If the result at the level of the SB is satisfactory, the procedure is considered complete.

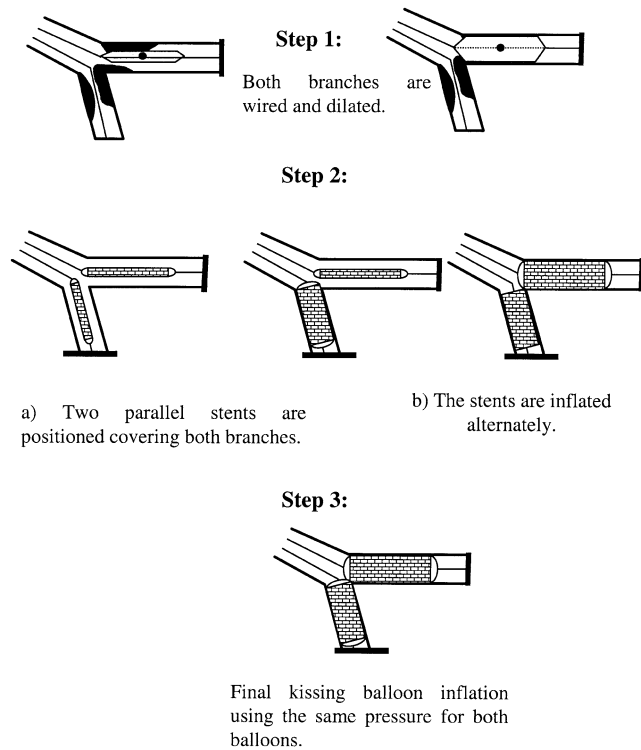
The seventh step is performed only if the operator considers the result at the SB not satisfactory. In this case, dilatation of the SB and kissing balloon inflation (usually at 8 atm) between the main and the SB is performed. If the result is acceptable after kissing balloon inflation, the procedure is considered complete.

The eighth step occurs only if the result at the SB is unsatisfactory. At this point the operator can still decide to stop because the SB is not ideal for stenting because of difficulty in positioning a stent, size, distal runoff, complexity of the procedure, and so on. If the operator thinks that the result at the level of the SB needs to be improved, then stenting is performed according to the reverse crush or T approach.

**Impossible SB access.** Even if rare, there are some circumstances in which due to the location of the plaque in the MB and/or the angulation of the SB, the wire cannot be advanced at the SB. A further high-pressure dilatation of the stent at the MB may better open the stent struts and facilitate the access toward the SB. Although rare, after attempting different types of wires with all types of curves and techniques, it may still be impossible to advance a wire in the SB. At this point few options are available: 1) stop the procedure because the risk of losing the SB will be too high, considering also the size and distribution of the branch (typically an angulated circumflex artery when stenting the



**Figure 1.** Classifications of bifurcations according to plaque burden: Duke (A) (17), Sanborn (B), Safian (C), and Lefevre (D) classifications.



**Figure 2.** The V stenting technique.

distal bifurcation of an unprotected left main); 2) perform directional atherectomy on the MB with the intent of removing the plaque that prevents entry toward the SB; and 3) dilate the MB with a balloon with the rationale that the plaque modification to a favorable plaque shift will facilitate access toward the SB.

**Isolated ostial lesions involving the MB or the SB.** With isolated ostial lesions, it is important to accurately place a stent to cover the lesion entirely without protruding into the other branch. Some operators use intravascular ultrasound to facilitate appropriate stent placement. In our practice, we approach these lesions as follows:

**ISOLATED OSTIAL LESION OF MB.** There are two approaches for treating these lesions: 1) placement of a stent at the ostium of the MB with a balloon protecting the SB and with inflation of the SB balloon and kissing balloon only if plaque shift occurs, and 2) placement of a stent in the MB covering the origin of the SB and then wiring the SB and performing kissing balloon inflation in case the ostium of the SB deteriorates.

Some operators, especially if the ostial lesion involves the left anterior descending vessel, may perform directional atherectomy with or without stenting at the ostium of the left anterior descending vessel.

**ISOLATED OSTIAL LESIONS OF SB.** The most common approach to treating these lesions is to place a stent at the ostium of the SB, frequently with a balloon placed but not inflated in the MB. If after stent placement there is deterioration of the MB at the site of the bifurcation, the

balloon in the MB is inflated, protecting the stent by a simultaneous inflation of the stent delivery balloon (T with a stent and a balloon).

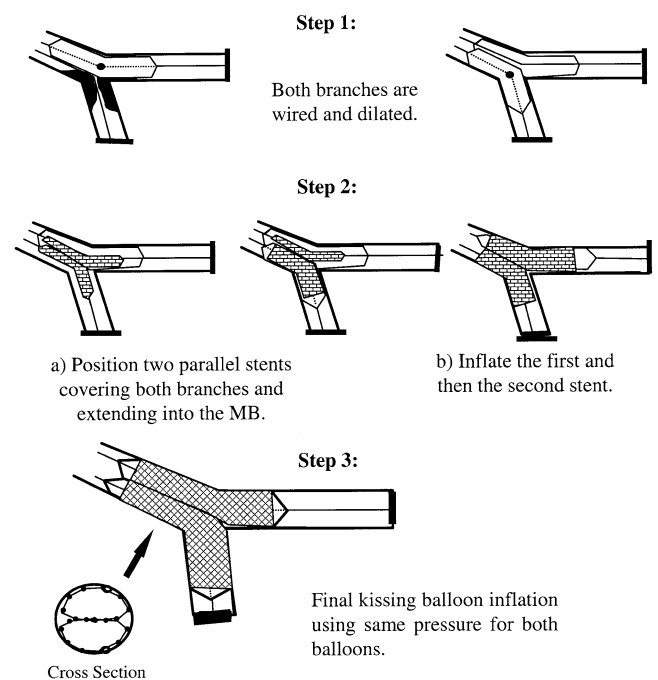
## TWO STENTS BY INTENTION TO TREAT

A number of two-stent techniques are available, with various levels of complexity and indications: the V, the simultaneous kissing stents, crush and its variations (reverse and step), T and its variation (modified), culottes, Y, and skirt. These techniques are described in detail in the following text.

## THE V AND THE SIMULTANEOUS KISSING STENTS TECHNIQUES

The V technique consists of the delivery and implantation of two stents together. One stent is advanced in the SB, the other in the MB, and the two stents touch each other, forming a proximal carina (Fig. 2) (29,30). When the carina extends a considerable length (usually 5 mm or more) into the main vessel, this technique is called simultaneous kissing stents (Fig. 3) (31). The type of lesion we consider most suitable for this technique is a very proximal lesion such as a bifurcation lesion located at the left main stem with a left main artery that is short or free of disease. Ideally the angle between the two branches should be less than 90°. The V technique is also suitable for other bifurcations provided the portion of the vessel proximal to the bifurcation is free of disease and there is no need to deploy a stent more proximally.

**Advantages.** The main advantage of these techniques is that the access to either of the two branches is never lost. In



**Figure 3.** The simultaneous kissing stents technique.

addition, when a final kissing inflation is performed, there is no need to re-cross any stent.

**Disadvantages.** It is intuitive how problematic may be the need to position a stent proximal to the double barrel. There is an inevitable bias toward one of the two branches and the high likelihood of leaving a gap. If there is a need to place a stent at the proximal segment of a vessel treated with V stenting, there are two options: 1) a stent is placed proximally, leaving a small gap between the kissing stents and the proximal stent, and 2) the kissing stent technique is converted into a crush technique, with the stent in the MB compressing the other stent (one arm of the V) in the SB. A wire will then cross the struts into the SB, and a balloon will be inflated toward the SB. After wire removal from the SB, the proximal stent will be advanced toward the MB. In this case we are left with a short segment of the MB proximal to the bifurcation, which has four layers of struts. Because of the complexity of this maneuver, it is clear how important it is to select lesions for the V technique in which there is a very low risk of performing proximal stenting.

## THE CRUSH TECHNIQUE

The crush technique (13) was introduced at the time of DES introduction and is described schematically in Figure 4. Two stents are placed in the MB and the SB, with the former more proximal than the latter. The stent of the SB is deployed, and its balloon and wire are removed. The stent subsequently deployed in the MB flattens the protruding

cells of the SB stent, hence the name crushing or crush technique. Wire re-crossing and dilatation of the SB with a balloon of a diameter at least equal to that of the stent (32), and then final kissing balloon inflation, is recommended (21,23). The implementation of final kissing balloon inflation was done to allow better strut contact against the ostium of the SB and therefore better drug delivery (21,32). The crush technique therefore became a sort of simplified culottes technique. The positive aspect is that whenever restenosis occurs, this narrowing is very focal (<5 mm in length) and most of the time is not associated with symptoms or ischemia. An important element to keep in mind when planning to perform the crush technique is that the two available DES will reach different maximal openings of their cells (21,33). The maximal cell diameter will be 3.0 mm for the Cypher stent and 3.7 mm for the Taxus stent. This information should be kept in mind when the SB has a diameter >3.0 mm.

**Advantages.** The main advantage of the crush technique is that the immediate patency of both branches is assured. This is important when the SB is functionally important or difficult to be wired. In addition, this technique provides excellent coverage of the ostium of the SB.

**Disadvantages.** The main disadvantage is that the performance of the final kissing balloon inflation makes the procedure more laborious because of the need to re-cross multiple struts with a wire and a balloon.

## THE REVERSE CRUSH

The main indication for performing the reverse crush is to allow an opportunity for provisional SB stenting. A stent is deployed in the MB, and balloon dilatation with final kissing inflation toward the SB is performed. It is assumed that the result at the ostium or at the proximal segment of the SB is suboptimal for deploying a stent at this site. A second stent is advanced into the SB and left in position without being deployed. Then a balloon sized according to the diameter of the MB is positioned at the level of the bifurcation, making sure to stay inside the stent previously deployed in the MB. The stent in the SB is retracted about 2 to 3 mm into the MB and deployed, the deploying balloon is removed, and an angiogram is obtained to verify that a good result is present at the SB (no further distal stent in the SB is needed). If this is the case, the wire from the SB is removed and the balloon in the MB is inflated at high pressure (12 atm or more). The other steps are similar to the ones described for the crush technique and involve re-crossing into the SB, performing SB dilatation, and final kissing balloon inflation.

**Advantages.** The main advantages of the reverse crush technique are that the immediate patency of both branches is assured and that the technique can be performed using a 6-F guiding catheter.

**Disadvantages.** This technique has the same disadvantages as the standard crush and is even more laborious.

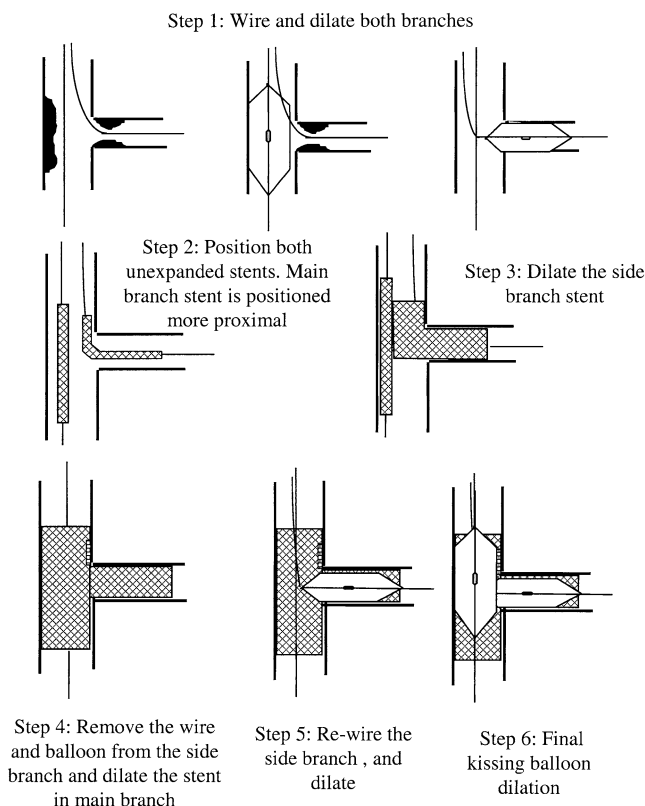


Figure 4. The crush technique.



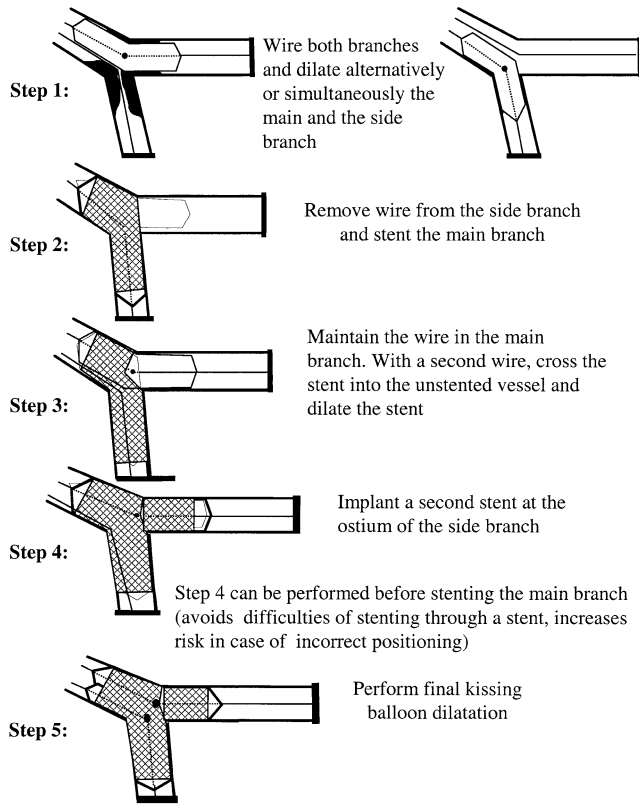


Figure 5. The T stenting technique.

### THE STEP CRUSH TECHNIQUE

The only difference from the standard crush technique is that each stent is advanced and deployed separately. First, a stent is advanced in the SB protruding into the MB a few millimeters. A balloon is then advanced in the MB over the bifurcation. Then the stent in the SB is deployed, the balloon is removed, and an angiogram is performed: if the result is adequate, the wire is also removed. The MB balloon is then inflated to crush the protruding SB stent and is removed. Subsequently, a stent is advanced in the main branch and is deployed (usually at 12 atm or more). The next steps are similar to those of the crush technique and involve recrossing into the SB, performing SB stent dilatation, and final kissing balloon dilatation.

**Advantages.** The main reason to use this technique is to perform the crush technique with a 6-F guiding catheter. Operators who perform the radial approach may be particularly interested in this technique.

**Disadvantages.** This technique has the same disadvantages as the standard crush technique.

### T TECHNIQUE

The classic T technique consists of positioning a stent first at the ostium of the SB, being careful to avoid stent protrusion into the MB (Fig. 5). Some operators leave a balloon in the MB to help to further locate the MB. After deployment of the stent and removal of the balloon and the

wire from the SB, a second stent is advanced in the MB. A wire is then re-advanced into the SB, and final kissing balloon inflation is performed. Modified T stenting is a variation performed by simultaneously positioning stents at the SB and the MB (Fig. 6). The SB stent is deployed first, and then after wire and balloon removal from the SB, the MB stent is deployed.

**Advantages.** This technique is less laborious than the crush technique. Unlike the V technique, it can be used for the coverage of lesions located proximal to the bifurcation.

**Disadvantages.** In almost all cases, this technique will lead to incomplete coverage of the ostium of the SB. Currently this technique has been discontinued in our practice, and there are two reasons to perform the T technique: 1) to place a stent at the ostium of a SB after placement of a stent in the MB because the result at the SB ostium was evaluated as unsatisfactory (provisional SB stenting), and 2) to perform stenting at the ostium of the SB when there is isolated SB ostial stenosis.

### THE CULOTTES TECHNIQUE

The culottes technique uses two stents and leads to full coverage of the bifurcation at the expense of an excess of metal covering of the proximal end (7) (Fig. 7). Both branches are pre-dilated. First a stent is deployed across the most angulated branch, usually the SB. The non-stented branch is then rewired through the struts of the stent and dilated. A second stent is advanced and expanded into the non-stented branch, usually the MB. Finally, kissing balloon inflation is performed.

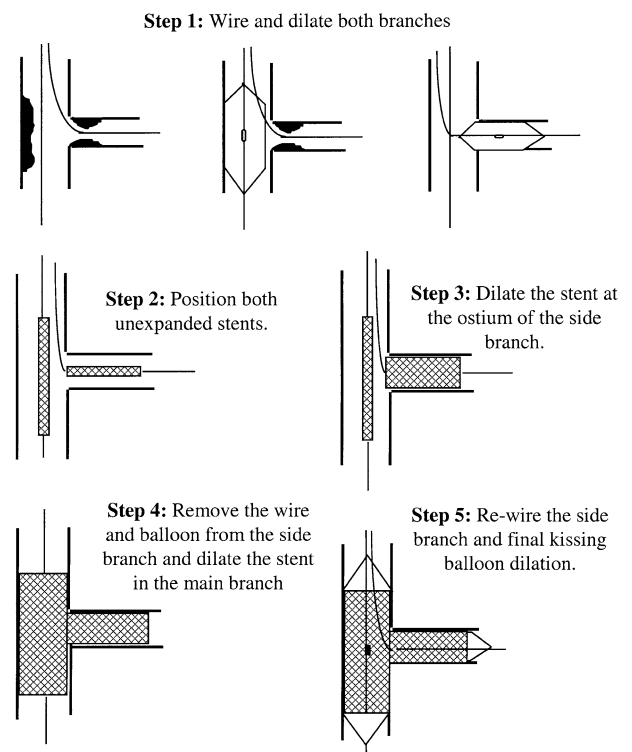


Figure 6. The modified T stenting technique.

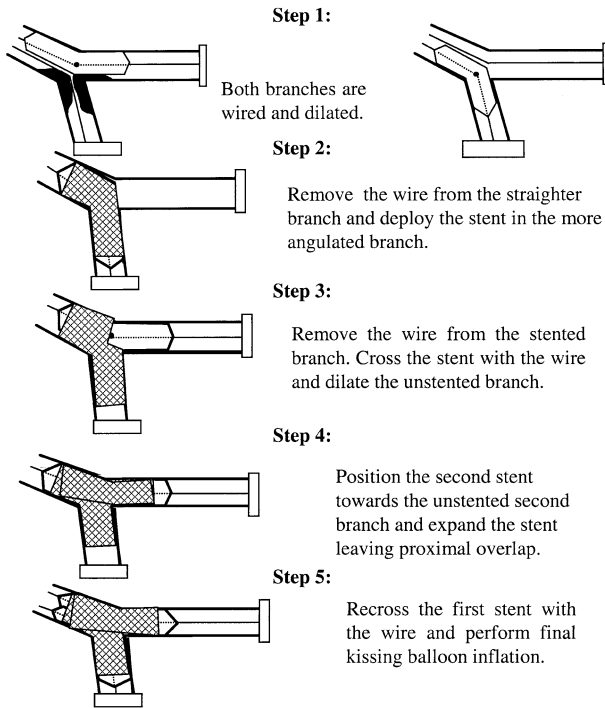


Figure 7. The culottes stenting technique.

**Advantages.** This technique is suitable for all angles of bifurcations and provides near-perfect coverage of the SB ostium.

**Disadvantages.** Like the crush technique, it leads to a high concentration of metal with a double-stent layer at the carina and in the proximal part of the bifurcation. The main disadvantage of the technique is that rewiring both branches through the stent struts can be difficult and time consuming.

### THE Y AND THE SKIRT TECHNIQUES

The Y technique has a particular historical value because it was one of the first bifurcation stenting techniques demonstrated in a live case course (34). This technique involves an initial pre-dilatation, followed by stent deployment in each branch (11) (Fig. 8). If the results are not adequate, a third stent may also be deployed in the MB. To effectively try to approximate the proximal stent to the already-deployed stents, it is necessary to modify the stent delivery device by placing one stent over two balloons (see description of the skirt technique in Fig. 9). With this technique, wire access to both branches is not lost.

**Advantages.** This technique is a last resort for treating very demanding bifurcations in which there is a need to maintain wire access to both branches.

**Disadvantages.** The major limitation of this approach is the need to modify the delivery system of the proximal stent and to manually crimp the stent on two balloons. When using a DES, this approach may lead to alteration of the polymer. In addition to this issue, it is not always feasible to closely approximate the proximal stent to the two more

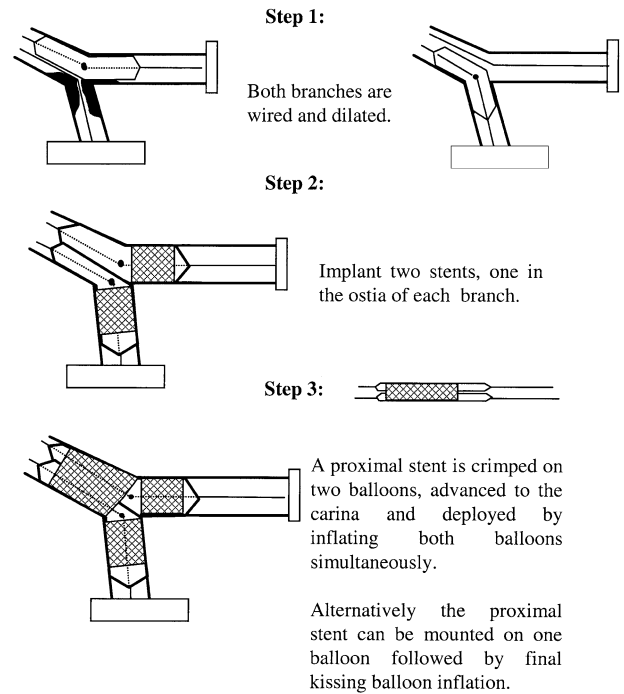


Figure 8. The Y stenting technique.

distal ones. For these reasons, when there is a need to perform the Y technique, a more practical approach is to remove the wire from the SB and advance and deploy a proximal stent in the MB, trying to approximate this stent as close as possible to the already-deployed stents at the newly formed carina.

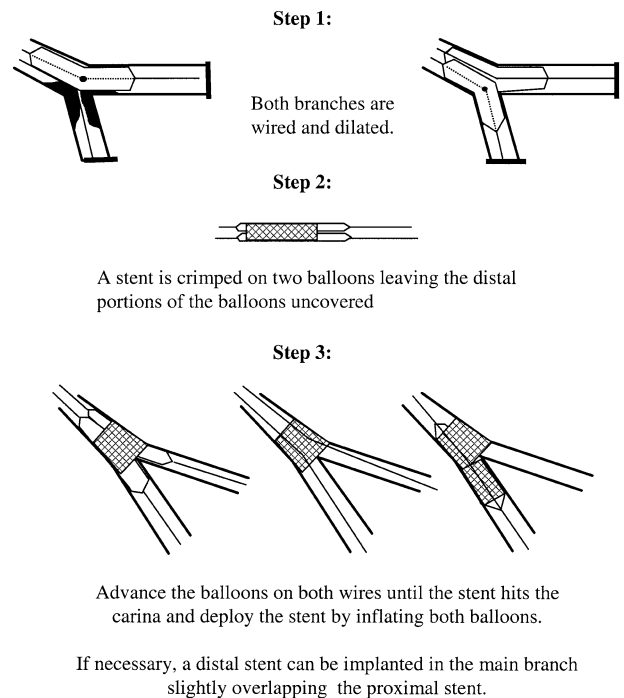


Figure 9. The skirt technique.

## LESION PREPARATION

Plaque removal before stent implantation, using directional atherectomy in noncalcified lesions and rotational atherectomy in calcified lesions, has been attractive. However, the encouraging results of many single-center experiences (35) have not been reproduced in the context of randomized studies (36,37).

**Role of atherectomy.** Analysis of the Coronary Angioplasty Versus Excisional Atherectomy Trial (CAVEAT)-I indicated the ability to achieve a larger post-procedure lumen in the main vessels in bifurcation lesions treated with directional atherectomy as opposed to angioplasty. This result was obtained with an increased risk of SB occlusion, with an increase in small non-Q-wave myocardial infarction, and with no difference in the six-month rate of restenosis (38). In the time of the Stenting after Optimal Lesion Debulking (SOLD) registry (39), bifurcational lesions were included with very encouraging results, leading to the launch of the Atherectomy and MULTILINK Stenting Improves Gain and Outcome trial (AMIGO) (40). However, this study failed to support the original findings and hypothesis, even in the subgroup of lesions involving a bifurcation. The main problem of directional atherectomy is that the technique is very operator-dependent and the amount of tissue removal varies depending on the commitment of the operator to performing extensive debulking. In addition, except for the very recent introduction of the Silverhawk device (Fox Hollow Technologies, Redwood City, California), no further developments in the devices available were made for a long time period.

In spite of these concerns and the lack of scientific evidence supporting the advantage of plaque debulking in bifurcation lesions, our experience in this setting has been favorable and we still occasionally combine atherectomy and DES when the anatomical setting is appropriate, such as a left main stenosis with a large plaque burden shown by intravascular ultrasound and plaque characteristics suitable for removal with current directional atherectomy devices.

**Role of rotational atherectomy.** As opposed to directional coronary atherectomy, which can be considered an optional procedure, the use of rotational atherectomy could be, in some lesions, the only procedure to permit lesion dilatation and hence stent delivery.

In most catheterization laboratories, the use of this procedure is <5% of all interventions. Early reports stated an advantage in facilitating stent delivery and expansion, with a suggestion for clinical benefit when used in lesions that demanded the use of this technology (41). The Stenting Post Rotational Atherectomy (SPORT) randomized study, using rotational atherectomy and stenting, failed to support any advantage of this technology over standard stenting (37). Our interpretation is that a niche technology cannot show its advantage when used outside the specific area of very calcified lesions, which were excluded from the SPORT trial. Most of the time, rotablation is performed

only on the MB, but occasionally (very rarely) also or only on the SB. We think that especially with the use of DES, lesion preparation with compliance change for a very calcified lesion can substantially facilitate stent delivery and symmetrical stent expansion with more homogeneous drug delivery.

**Role of cutting balloon.** A number of single-center studies (42–44) reported the beneficial combination of stenting preceded by cutting balloon dilatation. In bifurcation lesions, in which there is a large fibrotic plaque at the ostium of the SB, the use of the cutting balloon as a pre-dilatation strategy before stenting seems reasonable. The Restenosis reduction by Cutting balloon Evaluation trial (REDUCE III) evaluated the role of cutting balloon pre-dilatation before stenting versus standard balloon pre-dilatation in a variety of lesions. This trial reported a lower restenosis rate when lesions were pre-dilated with the cutting balloon.

Currently, we suggest the use of the cutting balloon in moderately calcific and fibrotic lesions, especially ones that involve the origin of the SB. In heavily calcified lesions, instead of using a larger burr, the cutting balloon could be used after small-burr rotablation with the goal of minimizing any distal embolization. Symmetric stent expansion, avoidance of SB recoil, and stent compression are all attractive hypotheses that need proper evaluation.

## ASSOCIATED PHARMACOLOGIC TREATMENT

When performing bifurcational stenting, we do not usually change our protocol of peri-procedural heparin administration (100 U/kg without and 70 U/kg with concomitant elective glycoprotein IIb/IIIa inhibitors). Use of glycoprotein IIb/IIIa inhibitors is reserved to thrombus-containing lesions, patients with unstable angina, acute myocardial infarction, and when long stents are implanted on both branches. These agents are sometimes administered when the final result at the SB seems suboptimal and for when various clinical or anatomical reasons the operator thinks it is not necessary to implant another stent.

We carefully consider peri-procedural preparation with thienopyridines, and when in doubt we administer a 600-mg loading dose of clopidogrel in the catheterization laboratory.

The duration of combined thienopyridine and aspirin treatment after stent implantation varies according to the length of the stent implanted, the type of stent used, and the clinical conditions of the patient (acute coronary syndrome at the time of stenting or diabetes mellitus).

## FUTURE DIRECTIONS AND CONCLUSIONS

When treating bifurcation lesions, we must pay attention to choosing the right guiding catheter size (should be large enough to accommodate two balloons or two stents when needed a priori or when likely to be used). A wire should be placed in the SB especially if there is disease at the ostium or with a problematic take-off. The general consensus is to



try to keep the procedure safe and simple. When the SB is not severely diseased, implantation of a stent in the MB and provisional stenting in the SB is the preferred strategy. Implantation of two stents as the initial approach is appropriate when both branches are significantly diseased (diameter stenosis >50%) and suitable for stenting. Final kissing balloon inflation should be performed in these cases.

The ongoing randomized trial Coronary bifurcations: Application of the Crushing Technique Using Sirolimus-eluting stents (CACTUS) comparing a provisional SB strategy with the crush technique using Cypher stents may help to better answer the approach of one versus two stents in true bifurcation lesions. Although dedicated stents are being developed, their clinical use in the format of DES is still very limited. However, these devices may have potentially important applications in proximal large bifurcations and in the left main trunk.

Despite all of the unanswered questions and some persisting problems, we cannot deny two major achievements in bifurcational stenting since the introduction of DES: 1) single-digit restenosis rates on the MB, and 2) focal restenosis at the SB, very frequently clinically silent. Considering how much has been done may help us to be more optimistic toward looking at what still needs to be done.

**Reprint requests and correspondence:** Dr. Antonio Colombo, EMO Centro Cuore Columbus, 48 Via M. Buonarroti, 20145 Milan, Italy. E-mail: info@emocolumbus.it.

## REFERENCES

- Colombo A, Iakovou I. Ten years of advancements in interventional cardiology. *J Endovasc Ther* 2004;11 Suppl 2:II10-8.
- Colombo A, Iakovou I. Drug-eluting stents: the new gold standard for percutaneous coronary revascularisation. *Eur Heart J* 2004;25:895-7.
- Iakovou I, Ge L, Michev I, et al. Clinical and angiographic outcome after sirolimus-eluting stent implantation in aorto-ostial lesions. *J Am Coll Cardiol* 2004;44:967-71.
- Iakovou I, Sangiorgi GM, Stankovic G, et al. Effectiveness of sirolimus-eluting stent implantation for treatment of in-stent restenosis after brachytherapy failure. *Am J Cardiol* 2004;94:351-4.
- Cohen DJ, Bakhai A, Shi C, et al. Cost-effectiveness of sirolimus-eluting stents for treatment of complex coronary stenoses: results from the Sirolimus-Eluting Balloon Expandable Stent in the Treatment of Patients with De Novo Native Coronary Artery Lesions (SIRIUS) trial. *Circulation* 2004;110:508-14.
- Al Suwaidi J, Berger PB, Rihal CS, et al. Immediate and long-term outcome of intracoronary stent implantation for true bifurcation lesions. *J Am Coll Cardiol* 2000;35:929-36.
- Chevalier B, Glatt B, Royer T, Guyon P. Placement of coronary stents in bifurcation lesions by the "culotte" technique. *Am J Cardiol* 1998;82:943-9.
- Yamashita T, Nishida T, Adamian MG, et al. Bifurcation lesions: two stents versus one stent—immediate and follow-up results. *J Am Coll Cardiol* 2000;35:1145-51.
- Pan M, Suarez de Lezo J, Medina A, et al. A stepwise strategy for the stent treatment of bifurcated coronary lesions. *Catheter Cardiovasc Interv* 2002;55:50-7.
- Ormiston JA, Webster MW, Ruygrok PN, Stewart JT, White HD, Scott DS. Stent deformation following simulated side-branch dilatation: a comparison of five stent designs. *Catheter Cardiovasc Interv* 1999;47:258-64.
- Fort S, Lazzam C, Schwartz L. Coronary "Y" stenting: a technique for angioplasty of bifurcation stenoses. *Can J Cardiol* 1996;12:678-82.
- Kobayashi Y, Colombo A, Akiyama T, Reimers B, Martini G, di Mario C. Modified "T" stenting: a technique for kissing stents in bifurcational coronary lesion. *Catheter Cardiovasc Diagn* 1998;43:323-6.
- Colombo A, Stankovic G, Orlic D, et al. Modified T-stenting technique with crushing for bifurcation lesions: immediate results and 30-day outcome. *Catheter Cardiovasc Interv* 2003;60:145-51.
- Colombo A. Bifurcational lesions and the "crush" technique: understanding why it works and why it doesn't—a kiss is not just a kiss. *Catheter Cardiovasc Interv* 2004;63:337-8.
- Carrie D, Karouny E, Chouairi S, Puel J. "T"-shaped stent placement: a technique for the treatment of dissected bifurcation lesions. *Catheter Cardiovasc Diagn* 1996;37:311-3.
- Colombo A, Moses JW, Morice MC, et al. Randomized study to evaluate sirolimus-eluting stents implanted at coronary bifurcation lesions. *Circulation* 2004;109:1244-9.
- Popma JJ, Leon MB, Topol EJ. *Atlas of Interventional Cardiology*. Philadelphia, PA: Saunders, 1994.
- Spokojny AM, Sanborn TM. The bifurcation lesion. In: Ellis SG, Holmes DR Jr., editors. *Strategic Approaches in Coronary Intervention*. Baltimore, MD: Williams and Wilkins, 1996:288.
- Safian RD. Bifurcation lesions. In: Safian RD, Freed MS, editors. *The Manual of Interventional Cardiology*. Royal Oak, MI: Physician's Press, 2001:222.
- Lefevre T, Louvard Y, Morice MC, et al. Stenting of bifurcation lesions: classification, treatments, and results. *Catheter Cardiovasc Interv* 2000;49:274-83.
- Ge L, Airoidi F, Iakovou I, et al. Clinical and angiographic outcome following implantation of drug-eluting stents in bifurcation lesions with the crush stent technique: importance of final kissing balloon post-dilatation. *J Am Coll Cardiol* 2005;46:613-20.
- Pan M, de Lezo JS, Medina A, et al. Rapamycin-eluting stents for the treatment of bifurcated coronary lesions: a randomized comparison of a simple versus complex strategy. *Am Heart J* 2004;148:857-64.
- Ge L, Tsalgalou E, Iakovou I, et al. In-hospital and nine-month outcome of treatment of coronary bifurcational lesions with sirolimus-eluting stent. *Am J Cardiol* 2005;95:757-60.
- Glagov S, Zarins C, Giddens DP, Ku DN. Hemodynamics and atherosclerosis. Insights and perspectives gained from studies of human arteries. *Arch Pathol Lab Med* 1988;112:1018-31.
- Honda Y, Fitzgerald PJ. Stent thrombosis: an issue revisited in a changing world. *Circulation* 2003;108:2-5.
- Farb A, Burke AP, Kolodgie FD, Virmani R. Pathological mechanisms of fatal late coronary stent thrombosis in humans. *Circulation* 2003;108:1701-6.
- Virmani R, Guagliumi G, Farb A, et al. Localized hypersensitivity and late coronary thrombosis secondary to a sirolimus-eluting stent: should we be cautious? *Circulation* 2004;109:701-5.
- Iakovou I, Schmidt T, Bonizzoni E, et al. Incidence, predictors, and outcome of thrombosis after successful implantation of drug-eluting stents. *JAMA* 2005;293:2126-30.
- Schampaert E, Fort S, Adelman AG, Schwartz L. The V-stent: a novel technique for coronary bifurcation stenting. *Catheter Cardiovasc Diagn* 1996;39:320-6.
- Colombo A, Gaglione A, Nakamura S, Finci L. "Kissing" stents for bifurcational coronary lesion. *Catheter Cardiovasc Diagn* 1993;30:327-30.
- Sharma SK, Choudhury A, Lee J, et al. Simultaneous kissing stents (SKS) technique for treating bifurcation lesions in medium-to-large size coronary arteries. *Am J Cardiol* 2004;94:913-7.
- Ormiston JA, Currie E, Webster MW, et al. Drug-eluting stents for coronary bifurcations: insights into the crush technique. *Catheter Cardiovasc Interv* 2004;63:332-6.
- Ge L, Tsalgalou E, Iakovou I, et al. In-hospital and 9-month outcome of treatment of coronary bifurcational lesions with sirolimus-eluting stents. *Am J Cardiol* 2005;95:757-60.
- Baim DS. Is bifurcation stenting the answer? *Catheter Cardiovasc Diagn* 1996;37:314-6.
- Karvouni E, Di Mario C, Nishida T, et al. Directional atherectomy prior to stenting in bifurcation lesions: a matched comparison study with stenting alone. *Catheter Cardiovasc Interv* 2001;53:12-20.

36. Bramucci E, Angoli L, Merlini PA, et al. Adjunctive stent implantation following directional coronary atherectomy in patients with coronary artery disease. *J Am Coll Cardiol* 1998;32:1855-60.
37. Moses JW, Carlier S, Moussa I. Lesion preparation prior to stenting. *Rev Cardiovasc Med* 2004;5 Suppl 2:S16-21.
38. Brener SJ, Leya FS, Apperson-Hansen C, Cowley MJ, Califf RM, Topol EJ. A comparison of debulking versus dilatation of bifurcation coronary arterial narrowings (from the CAVEAT I Trial). *Coronary Angioplasty Versus Excisional Atherectomy Trial-I*. *Am J Cardiol* 1996;78:1039-41.
39. Moussa I, Moses J, Di Mario C, et al. Stenting after optimal lesion debulking (SOLD) registry. Angiographic and clinical outcome. *Circulation* 1998;98:1604-9.
40. Stankovic G, Colombo A, Bersin R, et al. Comparison of directional coronary atherectomy and stenting versus stenting alone for the treatment of de novo and restenotic coronary artery narrowing. *Am J Cardiol* 2004;93:953-8.
41. Moussa I, Di Mario C, Moses J, et al. Coronary stenting after rotational atherectomy in calcified and complex lesions. Angiographic and clinical follow-up results. *Circulation* 1997;96:128-36.
42. Colombo A, Adamian M. Cutting balloon angioplasty of ostial coronary lesions: do we need the stent support? *J Invasive Cardiol* 1999;11:231-2.
43. Kurbaan AS, Kelly PA, Sigwart U. Cutting balloon angioplasty and stenting for aorto-ostial lesions. *Heart* 1997;77:350-2.
44. Muramatsu T, Tsukahara R, Ho M, et al. Efficacy of cutting balloon angioplasty for lesions at the ostium of the coronary arteries. *J Invasive Cardiol* 1999;11:201-6.