


Available online at www.sciencedirect.com

ScienceDirect

journal homepage: <http://www.pediatr-neonatol.com>

CASE REPORT

An Important Finding of Systemic Aspergillosis: Skin Involvement and Amphotericin B Resistance in an Adolescent



Aslinur Ozkaya-Parlakay^{a,*}, Buse Ozer-Bekmez^b, Ates Kara^a,
Baris Kuskonmaz^c, Zuhale Akcoren^d, Sevtap Arikan-Dagli^e,
Berna Oguz^f

^a Hacettepe University Medical Faculty, Pediatric Infectious Disease Department, Ankara, Turkey

^b Hacettepe University Medical Faculty, Pediatrics Department, Ankara, Turkey

^c Hacettepe University Medical Faculty, Pediatric Hematology Department, Ankara, Turkey

^d Hacettepe University Medical Faculty, Pediatric Pathology Department, Ankara, Turkey

^e Hacettepe University Medical Faculty, Mycology Department, Ankara, Turkey

^f Hacettepe University Medical Faculty, Radiology Department, Ankara, Turkey

Received May 18, 2013; received in revised form Aug 28, 2013; accepted Sep 14, 2013

Available online 8 December 2013

Key Words

Aspergillus fumigatus;
child;
primary
hemophagocytic
syndrome;
skin

Invasive aspergillosis is a life-threatening infectious complication in immunocompromised patients, especially with malignancy, and in some cases, it causes extensive tissue destruction and subsequent systemic illness, leading to multiorgan failure and death. Skin involvement and amphotericin B resistance are very rare findings of aspergillosis. Herein, we report the case of a primary hemophagocytic syndrome patient who developed subcutaneous nodules in the 3rd month of bone marrow transplantation from which *Aspergillus fumigatus* was cultivated despite the fact that she was under antifungal therapy. In immunocompromised patients with prolonged fever, atypical presentations of invasive mycosis should be kept in mind, and early appropriate therapy should be initiated promptly to decrease morbidity and mortality. Copyright © 2013, Taiwan Pediatric Association. Published by Elsevier Taiwan LLC. This is an open access article under the CC BY-NC-ND license (<http://creativecommons.org/licenses/by-nc-nd/4.0/>).

* Corresponding author. Hacettepe University Faculty of Medicine, Pediatric Infectious Diseases Department, 06100 Sıhhiye, Ankara, Turkey.

E-mail address: aslinur.o@gmail.com (A. Ozkaya-Parlakay).

1. Introduction

In patients affected by hematological diseases, fungal infections, especially those caused by *Aspergillus* spp. or by other filamentous fungi, are being increasingly diagnosed.

Data from the Centers for Disease Control and Prevention reveal that the mortality associated with invasive aspergillosis has increased by 357% since 1980.¹ The mortality of untreated invasive respiratory aspergillosis is nearly 100%; however, the survival among patients treated with amphotericin B is nearly 34%,^{2,3} and it was found to be 48.6% with voriconazole in a recent study.⁴ Incidence of invasive aspergillosis ranges from 0.5% to 30% according to series.^{2,5,6}

We report a case with primary hemophagocytic syndrome who had subcutaneous nodules during the 3rd month of bone marrow transplantation from which *Aspergillus fumigatus* was cultivated despite the fact that she was under antifungal therapy.

2. Case Report

A 16-year-old girl who had been diagnosed as primary hemophagocytic syndrome, treated with steroid, etoposide, and intravenous immunoglobulin in her two consecutive attacks (at 9 and 12 years) was hospitalized for bone marrow transplantation (BMT) from a fully matched donor (her sister). In the protocol of BMT preparation, busulfan, cyclophosphamide, etoposide, and steroid were initiated. As she had respiratory distress, hypoxia, cough, and bilateral pericardiac infiltration in chest X-ray (CXR), 1 day before BMT, imipenem, vancomycin, clarithromycin, and liposomal amphotericin B (3 mg/kg/day) were initiated. On the day of BMT, she had hemoptysis; thorax computed tomography (CT) yielded results consistent with pulmonary hemorrhage or infection. On the 2nd day of hospitalization, chest X-ray (CXR) showed right pleural effusion, thoracentesis results showed transudate criteria; additionally, she had acute renal impairment and needed hemodialysis, and also her respiratory distress increased; hence, she was intubated. Neutrophil engraftment occurred on Day 14 after BMT. After she had been mechanically ventilated for 23 days, she was extubated. After 2 days of extubation, she had extensive mucositis; paranasal CT showed maxillary, frontal, and sphenoidal sinusitis with soft tissue density, which was consistent with fungal infection. Thorax CT demonstrated multiple nodules surrounded by mild ground-glass opacities (halo sign) in the upper and lower lobes of bilateral lungs, which were not seen in previous CT (Figure 1A). Under therapy, new lesions were present; therefore, caspofungin was added to amphotericin B. When antifungal therapy was initiated, galactomannan (GM) antigen (GM levels were studied using the sandwich The enzyme-linked immunosorbent assay (ELISA) commercial kit [Platelia *Aspergillus*; Bio-Rad Laboratories, France] in accordance with the manufacturer's instruction), OD indices were 0.14 (0-1: negative, 1-1.5: board), but when caspofungin was started, the GM level has risen to 1.04. On Day 61 after BMT, CT results showed regression of soft tissue densities filling the sinus, but hemorrhagic and painful nodular cutaneous lesions of different sizes

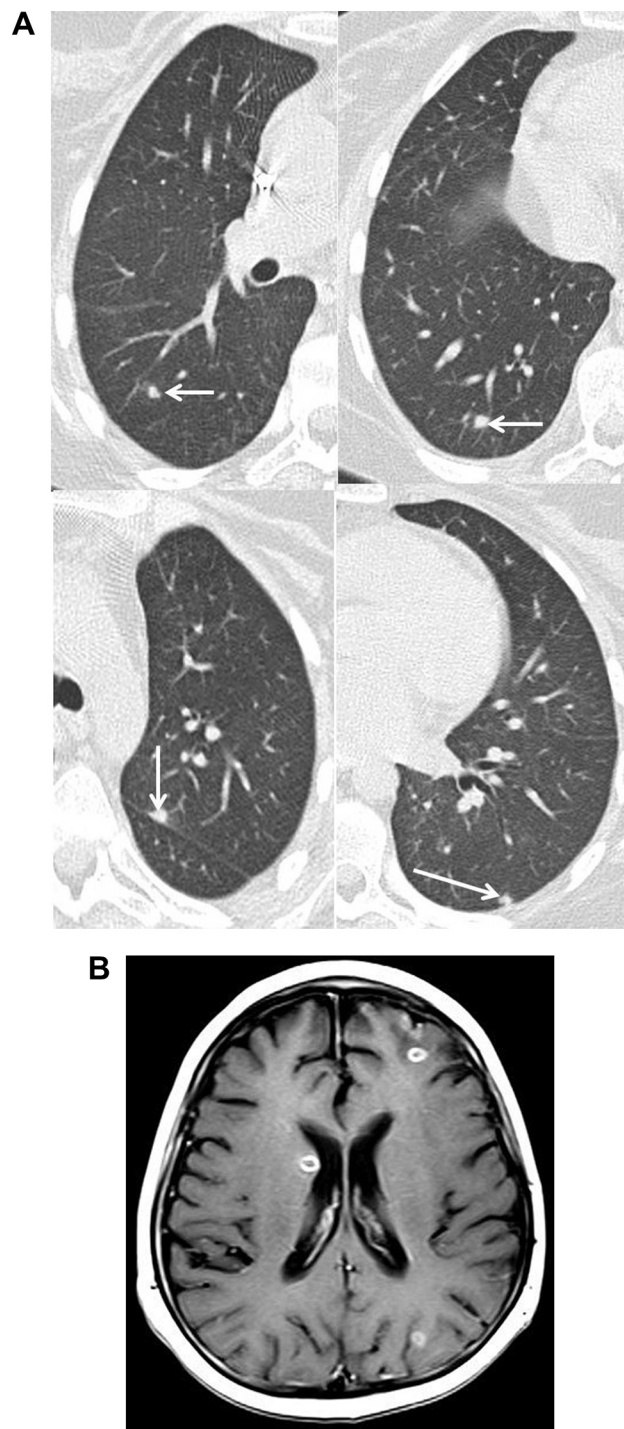


Figure 1 (A) Axial thorax CT image shows multiple subpleural and parenchymal millimetric nodules surrounded by mild ground-glass opacities (halo sign) in the upper and lower lobes of bilateral lungs (arrows). (B) Axial T1-weighted MR image of the brain obtained after the injection of contrast material shows multiple ring-enhancing lesions at the cortico-medullary junction in the hemisphere, consistent with the abscess. CT = computed tomography; MR = magnetic resonance.

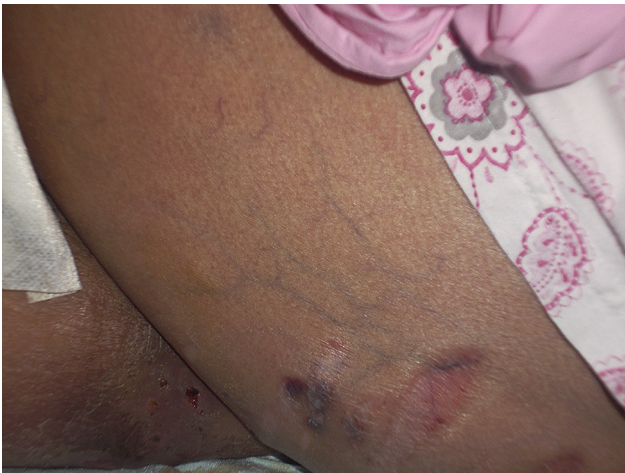

Figure 2 Subcutaneous nodule on the upper extremity.

appeared on bilateral extremities (Figure 2). Thorax CT showed the regression of lung nodules but revealed pleural effusion bilaterally and subcutaneous nodules on the chest wall.

As she experienced sudden vision loss for a short period, cranial magnetic resonance imaging (MRI) was studied, which yielded cerebral and cerebellar multiple cortico-medullary abscesses of which the largest had a diameter of 1.5 cm (Figure 1B). The biopsy of one of the nodular lesions of skin showed infiltration of dermis and subcutaneous fat by inflammatory cells, necrosis, and microabscess formation. Clusters of narrow-angle-branching and septate fungal hyphae consistent with *Aspergillus* were noticed in periodic acid–Schiff (PAS) and Gomori methenamine silver stains (Figure 3). Immunohistochemistry showed positive staining with the aspergillus antibody. Culture from biopsy yielded *Aspergillus fumigatus* [susceptibility testing and minimum inhibitory concentration (MIC) criteria for fluconazole, voriconazole, and caspofungin was performed according to

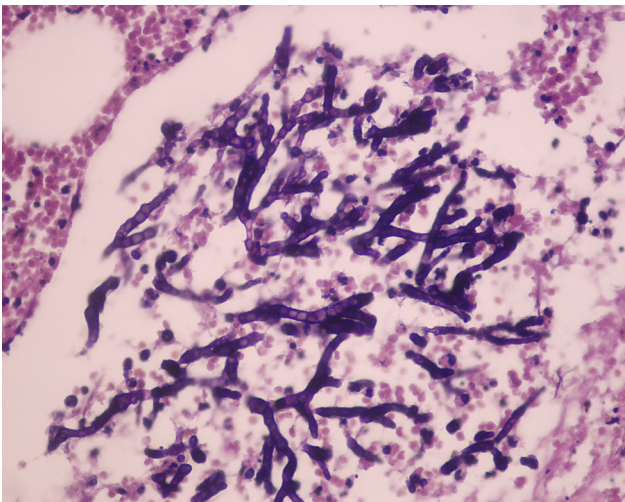


Figure 3 PAS staining showed clusters of septate and narrow-angle-branching fungal hyphae. PAS = periodic acid–Schiff.

the Clinical and Laboratory Standards Institute (CLSI) M38-A2guide]. Broth microdilution susceptibility testing was performed. MIC results were as follows: amphotericin B, 4 $\mu\text{g}/\text{mL}$; voriconazole, 0.06 $\mu\text{g}/\text{mL}$; and caspofungin, 0.03 $\mu\text{g}/\text{mL}$. After the addition of voriconazole, instead of caspofungin (6 mg/kg every 12 hours after loading dose) to liposomal amphotericin B, cutaneous lesions disappeared and thorax and paranasal CT confirmed there was regression of the lesions.

3. Discussion

Although extensive information about pulmonary aspergillosis in immunocompromised patients is available, cutaneous aspergillosis occurs relatively infrequently. Therefore, it remains poorly described, especially among bone marrow transplant recipients, mainly because literature reports have focused on the more frequent and severe clinical scenario of pulmonary or disseminated infection. In previous reports, cutaneous aspergillosis has been described as either a primary or secondary infection. Primary cutaneous aspergillosis usually involves sites of skin at or near intravenous access catheter sites, traumatic inoculation, and at sites associated with occlusive dressings, burns, or surgery. Secondary cutaneous lesions result either from contiguous extension to the skin from infected underlying structures or from widespread blood-borne seeding of the skin.⁷ Findlay et al⁸ attempted to distinguish five appearances of disseminated aspergillosis: solitary necrotizing dermal plaque, subcutaneous granuloma or abscess, persistent eruptive dermal maculopapules, transient erythema and generalized rash, and as an entity in immunocompetent hosts, progressive confluent granuloma. The morphology of the breakthrough skin lesion in our patient fits that of subcutaneous abscess in dermis.

The differential diagnosis includes candidemia, which is present with red pinpoint maculae in approximately 10% of patients⁹ and fusariosis metastatically involving the skin in the majority of cases. Fusarial lesions might present as subcutaneous nodules.¹⁰ Cryptococcal and nocardial disease were considered in the light of simultaneous pulmonary and skin lesions. We would like to underline the importance of an aggressive diagnostic approach whenever tender nodules of the skin occur in the immunocompromised host as in our patient. The prompt initiation of an appropriate therapy is also the second most important step to increase the patient survival rate.

Another important point of our case other than cutaneous involvement is amphotericin B resistance of *Aspergillus*, which was rarely reported in literature.^{11–13} Breakthrough fungal infection under amphotericin B therapy is uncommon. Therefore, our patient with a cutaneous lesion is an important example. Among 196 cases of *A. fumigatus* infections in Japan, isolates with MICs of $\geq 2 \mu\text{g}/\text{mL}$ were reported for 1.0% of the isolates (2/196).¹¹ In a study from Greece, amphotericin B resistance was reported as 10.8%,¹² and high levels of MIC for amphotericin B ($>1 \text{ mg}/\text{mL}$) were also reported by Mortensen et al¹³ as 2.7%. Resistance to amphotericin B in our patient might have caused the breakthrough infection.

Clinical findings of aspergillosis in immunocompromised patients with hematological malignancies may be more different than classical findings. Although skin involvement is estimated because of *Candida* or *Fusarium* infection, this case emphasizes that *Aspergillus* may also be encountered with dermal lesions and that urgent diagnostic approaches are necessary. As antifungal resistance of *A. fumigatus* (especially to azoles) is one of the concerns in the treatment of aspergillosis, the possibility of resistance to amphotericin B should be kept in mind in cases that are unresponsive to therapy, similar to our case.

References

1. Steinbach WJ. Pediatric aspergillosis disease and treatment differences in children. *Pediatr Infect Dis J* 2005;**24**:358–64.
2. Denning DW, Marinus A, Cohen J, Spence D, Herbrecht R, Pagano L, et al. An EORTC multicentre prospective survey of invasive aspergillosis in haematological patients: diagnosis and therapeutic outcome. *J Infect* 1998;**37**:173–80.
3. Lin SJ, Schranz J, Teutsch SM. Aspergillosis case-fatality rate: systematic review of the literature. *Clin Infect Dis* 2001;**32**:358–66.
4. Jacobs F, Selleslag D, Aoun M, Sonet A, Gadisseur A. An observational efficacy and safety analysis of the treatment of acute invasive aspergillosis using voriconazole. *Eur J Clin Microbiol Infect Dis* 2012;**31**:1173–9.
5. Wright JA, Bradfield SM, Park JR, Hawkins DS. Prolonged survival after invasive aspergillosis: a single-institution review of 11 cases. *J Pediatr Hematol Oncol* 2003;**25**:286–91.
6. Groll AH, Kurz M, Schneider W, Witt V, Schmidt H, Schneider M, et al. Five-year survey of invasive aspergillosis in a paediatric cancer centre. Epidemiology, management and long-term survival. *Mycoses* 1999;**42**:431–42.
7. van Burik JA, Colven R, Spach DH. Cutaneous aspergillosis. *J Clin Microbiol* 1998;**36**:3115–21.
8. Findlay GH, Roux HF, Simson IW. Skin manifestations in disseminated aspergillosis. *Br J Dermatol* 1971;**85**:94–7.
9. Viscoli C, Girmenia C, Marinus A, Collette L, Martino P, Vandercam B, et al. Candidemia in cancer patients: a prospective, multicenter surveillance study by the Invasive Fungal Infection Group (IFIG) of the European Organization for Research and Treatment of Cancer (EORTC). *Clin Infect Dis* 1999;**28**:1071–9.
10. Boutati EI, Anaissie EJ. *Fusarium*, a significant emerging pathogen in patients with hematologic malignancy: ten years' experience at a cancer center and implications for management. *Blood* 1997;**90**:999–1008.
11. Tashiro M, Izumikawa K, Minematsu A, Hirano K, Iwanaga N, Ide S, et al. Antifungal susceptibilities of *Aspergillus fumigatus* clinical isolates obtained in Nagasaki, Japan. *Antimicrob Agents Chemother* 2012;**56**:584–7.
12. Arabatzis M, Kambouris M, Kyprianou M, Chrysaki A, Foustoukou M, Kanellopoulou M, et al. Polyphasic identification and susceptibility to seven antifungals of 102 *Aspergillus* isolates recovered from immunocompromised hosts in Greece. *Antimicrob Agents Chemother* 2011;**55**:3025–30.
13. Mortensen KL, Johansen HK, Fursted K, Knudsen JD, Gahrn-Hansen B, Jensen RH, et al. A prospective survey of *Aspergillus* spp. in respiratory tract samples: Prevalence, clinical impact and antifungal susceptibility. *Eur J Clin Microbiol Infect Dis* 2011;**30**:1355–63.