

TECHNICAL NOTE / *Technique*

# Painful Pagetic vertebra palliated with percutaneous vertebral augmentation



A.N. Wallace<sup>a,\*</sup>, R.O. Chang<sup>b</sup>, A.C. Hsi<sup>c</sup>,  
J.W. Jennings<sup>a</sup>

<sup>a</sup> Mallinckrodt Institute of Radiology, Washington University School of Medicine, Saint Louis, MO, United States

<sup>b</sup> Washington University School of Medicine, Saint Louis, MO, United States

<sup>c</sup> Department of Pathology & Immunology, Division of Anatomic Pathology, Washington, University School of Medicine, Saint Louis, MO, United States

## KEYWORDS

Paget's disease;  
Percutaneous  
vertebral  
augmentation;  
Spine;  
Interventional  
radiology

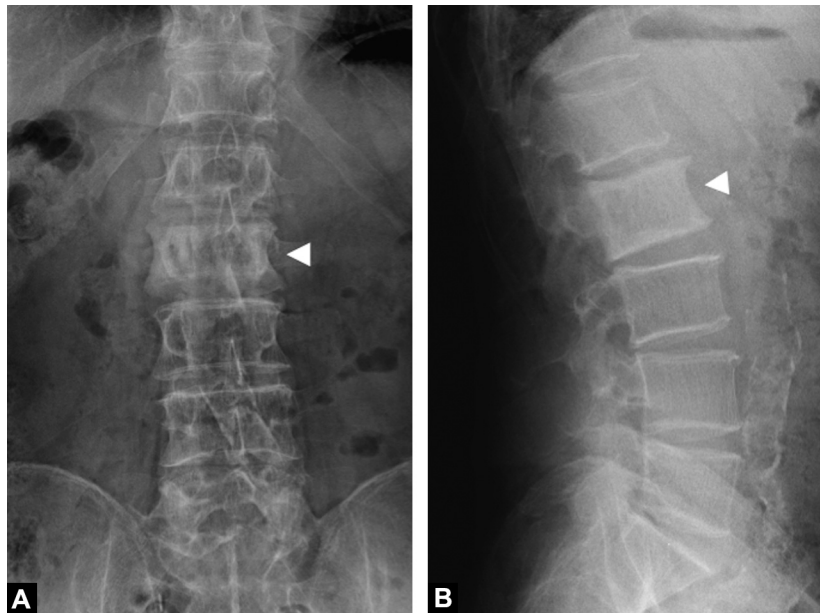Paget's disease is a benign bone disease of unclear etiology characterized by excessive bony remodeling that weakens, expands and distorts the shape of affected bones. Although the spine is the second most common site of Paget's disease, Pagetic vertebrae are typically asymptomatic [1]. Sources of pain secondary to spinal Paget's disease include pathologic fracture, spinal cord or nerve root compression, and rarely, sarcomatous transformation [2]. However, patients may also experience uncomplicated back pain that is most likely related to vertebral body microfractures and/or vascular congestion [3]. This mechanism is similar to that of painful vertebral body hemangiomas, which are effectively palliated with vertebral augmentation [4].

This led us to utilize percutaneous vertebral augmentation to treat a patient with painful, uncomplicated monostotic spinal Paget's disease with clinical success.

## Case presentation

A 71-year-old man presented with 14 months of severe lower back pain exacerbated by moving from sitting to standing. He denied incontinence and had no focal weakness on physical examination. Lumbar spine radiographs demonstrated an enlarged L2 vertebral body with trabecular thickening (Fig. 1), and lumbar spine MRI showed heterogenous signal on

\* Corresponding author at: Mallinckrodt Institute of Radiology, 510 South Kingshighway Boulevard, 63110 Saint Louis, MO, United States.  
E-mail address: [wallacea@mir.wustl.edu](mailto:wallacea@mir.wustl.edu) (A.N. Wallace).



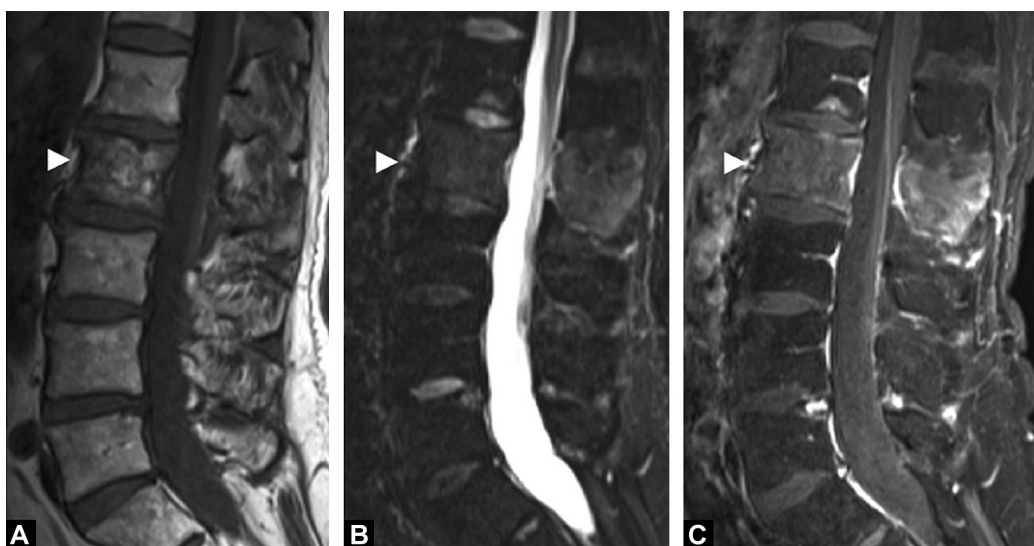
**Figure 1.** A, Anteroposterior and B, lateral radiographs of the lumbar spine show an enlarged, sclerotic L2 vertebra (white arrowheads) with thickened endplates consistent with Paget's disease.

T1- and T2-weighted images with mild enhancement after gadolinium chelate administration (Fig. 2). These imaging findings were compatible with Paget's disease. Fluoroscopy-guided percutaneous biopsy of the L2 vertebral body was performed with a coaxial, drill-assisted system (OnControl®, Vidacare Corporation, Shavano Park, TX, USA), which confirmed the diagnosis (Fig. 3). Over the next four months, his pain was partially relieved with acetaminophen and hydrocodone, but the resulting drowsiness, nausea, and constipation were detrimental to his quality of life. Consequently, vertebroplasty was attempted for pain palliation in lieu of more invasive surgical management.

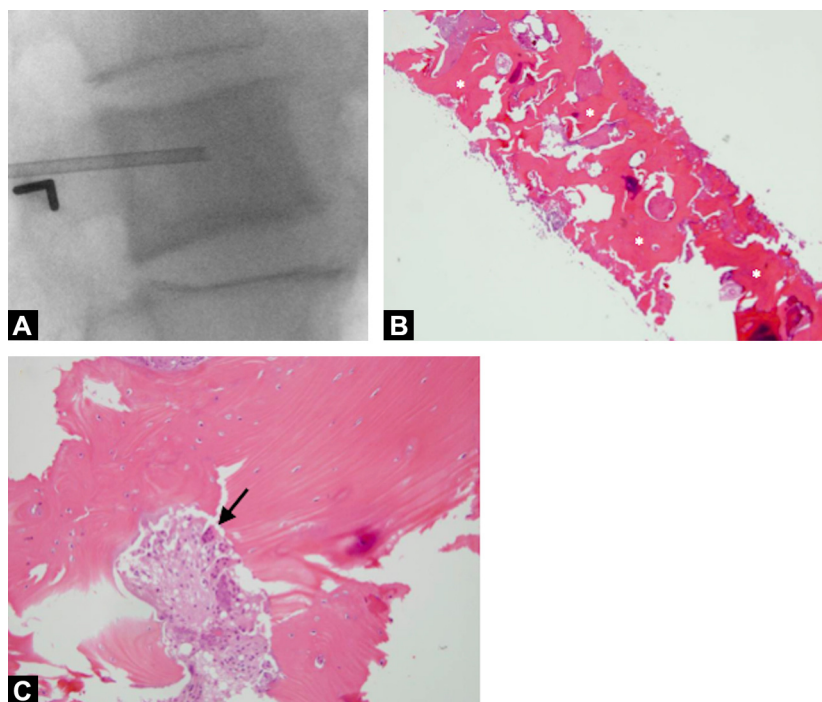
Written informed consent was obtained prior to the procedure. The vertebral body was accessed using a coaxial

10-G outer cannula and 12-G diamond-tipped inner needle attached to a hand-held drill (OnControl®). Intraosseous venography demonstrated brisk filling of epidural veins (Fig. 4). A total of 6 mL of ultrahigh-viscosity cement was injected into the L2 vertebral body using the StabiliT RF Targeted Vertebral Augmentation System (DFINE, San Jose, CA, USA) (Fig. 4).

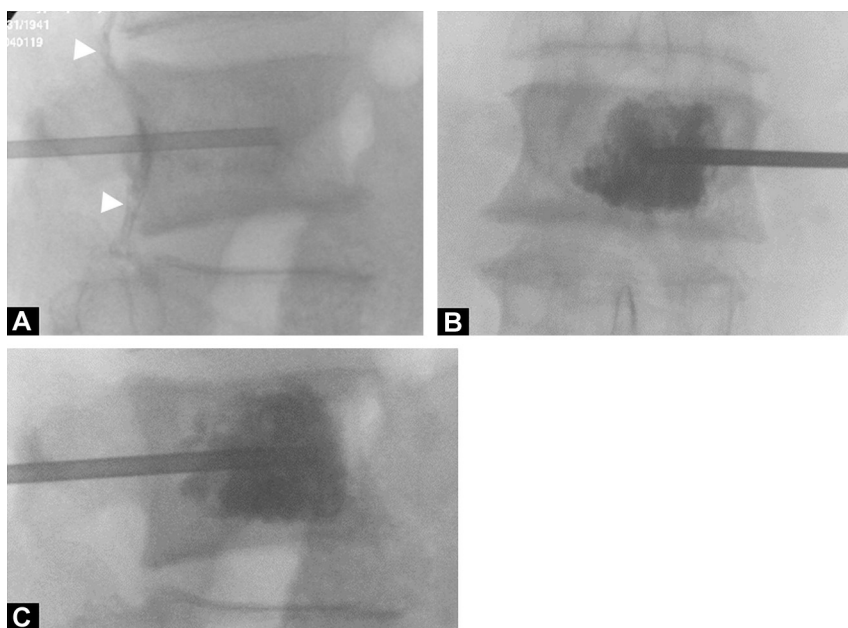
When the patient resumed walking after the procedure, his pain had completely resolved and physical examination revealed no new weakness or other evidence of complications. He has subsequently resumed an active lifestyle that includes golfing regularly, and his back pain has not recurred in 26 months of clinical follow-up.



**Figure 2.** A, T1-weighted, B, short tau inversion recovery, and C, T1-weighted, fat-suppressed, contrast-enhanced MR images show an enlarged L2 vertebra (white arrowheads) with heterogeneous signal on T1- and T2-weighted MR images and mild enhancement after intravenous administration of a gadolinium chelate. These findings are nonspecific but suggest Paget's disease complicated by microfractures and/or vascular congestion.



**Figure 3.** A. Lateral fluoroscopic image shows a 12-G hollow biopsy needle (OnControl®; Vidacare Corporation, Shavano Park, TX, USA) in the enlarged, sclerotic L2 vertebral body. One 3-cm bone core specimen was obtained. B. Low magnification (40 ×) hematoxylin and eosin staining shows thickened bony trabeculae (white asterisks) representing increased bone formation. C. Medium magnification (200 ×) shows reactive osteoclast activity (arrow) indicating increased bone resorption. These findings are consistent with a diagnosis of Paget’s disease.



**Figure 4.** A. Lateral fluoroscopic image during intraosseous venography shows rapid filling of epidural veins (white arrowheads). (B) Anteroposterior and (C) lateral fluoroscopic images show the L2 vertebral body accessed via a right transpedicular approach. Radiopaque cement fills the anterior two-thirds of the vertebral body, extending across the midline and to the superior and inferior endplates.

### Discussion

The increased radiographic density of Pagetic vertebrae belie a decreased mechanical strength due to replacement of normal bone with weaker, disorganized woven bone [5].

Pathologic fracture is the most common complication of spinal Paget’s disease, and it is hypothesized that pain in uncomplicated spinal Paget’s disease is caused by microfractures of vertical trabeculae, and the relative movements of the fragmented segments [3,6]. Vascular congestion caused

by replacement of vertebral body marrow with fibrovascular tissue may also be a contributing factor [3].

Percutaneous vertebroplasty is widely used to safely and effectively palliate back pain related to osteoporotic compression fracture, hemangioma, and metastatic disease [4,7–9]. This case report demonstrates that pain secondary to Pagetic vertebrae may be considered another indication. As with vertebral body hemangioma, in which mechanical strength is compromised by replacement of trabeculae by venous channels, pain relief is most likely related to cement stabilization of microfractures. Heat released from the exothermic polymerization of the cement may also cause coagulation that relieves vascular congestion.

We used ultrahigh-viscosity cement to minimize extravasation because the Pagetic vertebra was hypervascular with rapid flow into epidural veins. Retrospective studies have reported extravasation rates during vertebral augmentation with high-viscosity cement equal to or less than that during balloon kyphoplasty owing to the fixed, low rate of cement delivery [10].

In conclusion, percutaneous vertebroplasty may be considered for palliation of painful Pagetic vertebrae on an investigational basis. Use of ultrahigh-viscosity cement may reduce the risk of extravasation.

## Disclosure of interest

Jack W. Jennings is a speaker panelist and consultant for DFINE, Inc.

The other authors declare that they have no competing interest.

## References

- [1] Collins DH. Paget's disease of bone; incidence and subclinical forms. *Lancet* 1956;271:51–7.
- [2] Smith SE, Murphey MD, Motamedi K, Mulligan ME, Resnik CS, Gannon FH. From the archives of the AFIP: radiologic spectrum of Paget disease of bone and its complications with pathologic correlation. *Radiographics* 2002;22:1191–216.
- [3] Pedicelli A, Papacci F, Leone A, et al. Vertebroplasty for symptomatic monostotic Paget disease. *J Vasc Interv Radiol* 2011;22:400–3.
- [4] Anselmetti GC, Corrao G, Monica PD, et al. Pain relief following percutaneous vertebroplasty: results of a series of 283 consecutive patients treated in a single institution. *Cardiovasc Intervent Radiol* 2007;30:441–7.
- [5] Seitz S, Priemel M, Zustin J, et al. Paget's disease of bone: histologic analysis of 754 patients. *J Bone Miner Res* 2009;24:62–9.
- [6] Dell'Atti C, Cassar-Pullicino VN, Lalam RK, Tins BJ, Tyrrell PN. The spine in Paget's disease. *Skeletal Radiol* 2007;36:609–26.
- [7] Nas OF, Inecikli MF, Kacar E, Buyukkaya R, Ozkaya G, Aydın O, et al. Effectiveness of percutaneous vertebroplasty in cases of vertebral metastases. *Diagn Interv Imaging* 2015, <http://dx.doi.org/10.1016/j.diii.2015.05.001>.
- [8] Wallace AN, Greenwood TJ, Jennings JW. Use of imaging in the management of metastatic spine disease with percutaneous ablation and vertebral augmentation. *AJR Am J Roentgenol* 2015;205(2):434–41.
- [9] Wallace AN, Robinson CG, Meyer J, et al. The Metastatic Spine Disease Multidisciplinary Working Group Algorithms. *Oncologist* 2015;20(10):1205–15.
- [10] Georgy BA. Feasibility, safety and cement leakage in vertebroplasty of osteoporotic and malignant compression fractures using ultra-viscous cement and hydraulic delivery system. *Pain Physician* 2012;15:223–8.