

Available online at www.sciencedirect.com

ScienceDirect

journal homepage: <http://Elsevier.com/locate/radcr>

Case Report

Congenital nasal pyriform aperture stenosis in association with solitary median maxillary central incisor: unique radiologic features

Sara Yang BS, Pedro Orta II BS, Elizabeth M. Renk MD*, Jared C. Inman MD

Department of Otolaryngology—Head and Neck Surgery, Loma Linda University Health System, 11234 Anderson St, Suite 256A, Loma Linda, CA 92354, USA

ARTICLE INFO

Article history:

Received 16 May 2016

Received in revised form

9 June 2016

Accepted 15 June 2016

Available online 1 August 2016

Keywords:

Congenital nasal pyriform aperture stenosis

Solitary median maxillary central incisor

Hypothalamo-pituitary axis

Congenital nasal obstruction

ABSTRACT

Solitary median maxillary central incisor (SMMCI) coexists in 34%–65% of patients initially diagnosed with congenital nasal pyriform aperture stenosis. SMMCI, a genetic syndrome, warrants consideration for further screening because of its high prevalence of other diagnostic possibilities—specifically central defects, like nasal obstruction and hypothalamo-pituitary axis abnormalities. We report on a presentation of SMMCI with congenital nasal pyriform aperture stenosis which highlights the unique radiologic features and notes the relationship between these two central associated findings in the literature.

© 2016 the Authors. Published by Elsevier Inc. under copyright license from the University of Washington. This is an open access article under the CC BY-NC-ND license (<http://creativecommons.org/licenses/by-nc-nd/4.0/>).

Introduction

Respiratory distress in infants presents as nasal flaring, rapid and shallow breathing, cyanosis, and failure to thrive secondary to feeding difficulties. Infants are preferentially nasal breathers; therefore, nasal obstruction can result in respiratory distress [1]. The more common causes of nasal obstruction include rhinitis, adenoid hypertrophy, deviated nasal septum, and polyps [2]. However, anatomic causes must also be ruled out such as choanal atresia, midnasal stenosis, and congenital nasal pyriform aperture (PA) stenosis (CNPAS).

CNPAS is a rare cause of nasal obstruction that occurs around 1 in 25,000 births [3]. It is thought to arise from disrupted interaction between the nasal placode and the nasal processes that form the central maxilla and help establish the internal nasal aperture at the PA [4,5]. The excessive bone growth in the nasal processes of the maxillary bones results in stenosis of the PA [2]. The diagnosis is made with computerized tomography (CT) images. Belden et al. established diagnostic measurements on CT images of the PA taken parallel to the hard palate with 11 mm or less width being diagnostic of CNPAS. Furthermore, in looking at age cohorts with CNPAS,

Competing Interests: The authors have declared that no competing interests exist.

* Corresponding author.

E-mail address: erenk@llu.edu (E.M. Renk).

<http://dx.doi.org/10.1016/j.radcr.2016.06.004>

1930-0433/ © 2016 the Authors. Published by Elsevier Inc. under copyright license from the University of Washington. This is an open access article under the CC BY-NC-ND license (<http://creativecommons.org/licenses/by-nc-nd/4.0/>).

width between the medial aspect of the maxilla at the level of the inferior meatus were measured on axial CT images to be 4.8, 7.0, and 6.0 mm in patients with CNPAS in the age ranges of 0-3, 4-6, and 10-12 months, respectively. This compared with 13.4, 14.9, and 15.6 mm in control subjects in the same age ranges [3]. Wormald et al. [6] described in their literature and retrospective case review that a PA width of 5.7 mm or less required surgical intervention.

During the diagnostic workup for CNPAS patients, there can be associated findings—seen incidentally on CT scan or physical examination—that warrant further exploration for the possibility of a genetic syndrome. Particularly apparent when evaluating the PA on imaging are the unerupted maxillary incisors. When evaluating a child for nasal obstruction, the physical examination, CT, or dental x-ray, will clearly show the maxillary dentition presence of solitary median maxillary central incisor (SMMCI; Fig. 1). Of note, 90% of infants with SMMCI will have CNPAS, choanal atresia, or midnasal stenosis. CNPAS and SMMCI seemingly coexist in a higher percentage than previously reported historically in the literature. Cases seen in isolation should be given consideration for further screening, specifically when a SMMCI is noted.

Case report

A 9-month-old female child presented to the emergency department from the pediatric office for failure to thrive, repeated bouts of cyanosis, worsening difficulty feeding, and recurrent “sinus” infections. Otolaryngology consultations were obtained. On initial evaluation, anterior rhinoscopy with an otoscope showed bilateral yellow drainage and extremely swollen mucosa at the PA. A pediatric nasal fiberoptic endoscope (2.7-mm diameter) was not able to be passed through either nares. A lubricated 5-French plastic catheter was similarly not able to pass. The child was not in acute distress with stable vitals and saturation of 98% in room air. Afrin (oxymetazoline) sprays and nasal saline mist were recommended along with cool mist mask next to the child in the crib. Calorie count, strict ins and outs, and observed feeding was planned. The child was placed on a monitored unit and a noncontrast maxillofacial CT scan with 1-mm cut through the nose was obtained.

CT scan revealed a PA width <5-mm bilaterally and no apparent midnasal stenosis or choanal atresia (Figs. 2, right image and 3, right image). On review of the CT scan for surgical planning, a single maxillary central incisor was noted (Fig. 1 middle and right image). Endocrine and genetic consults were ordered, and the child was screened for other associated abnormalities and magnetic resonance imaging (MRI) of the brain was ordered. Once workup was completed, noting the child showed no central abnormalities, the family was counseled on PA surgical repair. The surgery was performed through a sublabial incision elevating the mucosa off the nasal floor and medial maxilla. The medial maxillary prominences were drilled down until size 5 endotracheal tubes were able to be passed with minimal resistance. These size 5 endotracheal tubes were then trimmed to size and left in place as stents. These stents were removed on post-operative day 2, and nasal hygiene rinses were started. After discharge, the patient's nasal obstruction was improved, and further surgery was not indicated.

Discussion

Diagnostic workup of a CNPAS patient may unearth an incidental finding of a median maxillary incisor on CT imaging. This characteristic finding is part of a syndrome called SMMCI, a genetic syndrome that occurs in 1:50,000 live births and represents a spectrum of midline facial defects and other possible congenital anomalies including intellectual disability in up to 50% of patients [4,7]. Phenotypic characteristics at birth include an arch-shaped appearance of the upper lip, prominent maxillary alveolus, absent labial frenulum, narrow nose, and “V”-shaped palate with a prominent narrow ridge along the midpalatal suture [4]. Case studies have also correlated the presence of SMMCI with conditions such as microcephaly, cardiac defects, holoprosencephaly (HPE), VACTERL, CHARGE, and velocardiofacial syndrome [4,7].

These phenotypic characteristics of SMMCI are thought to arise due to an interruption in development during gestational days 35-38 [4,8,9]. Interaction between the nasal placode and the nasal processes that form the central maxilla are disrupted leading to cranial facial, dentition, and nasal airway malformations. CNPAS may be an isolated anomaly. However,

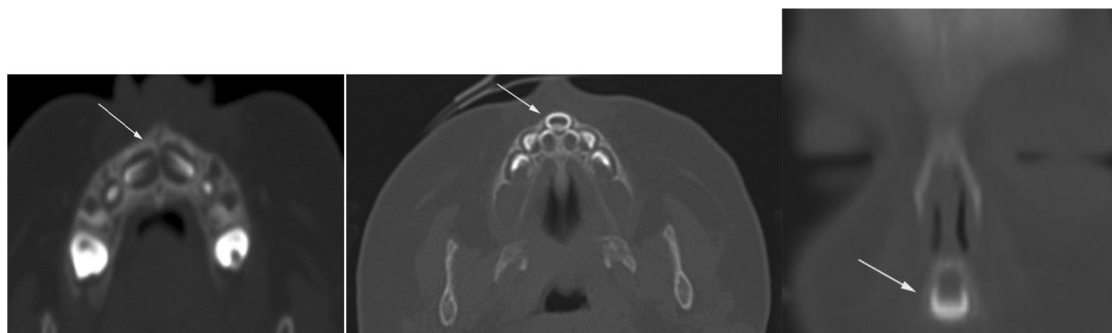

Fig. 1 – CT images through the hard palate in two 9-month-old females. An axial view of maxillary segment with normal tooth crowns is shown on the far left (arrow). In contrast with an axial view showing a solitary median maxillary central incisor (middle image, arrow). On the far right is a coronal view of a solitary median maxillary central incisor (arrow).

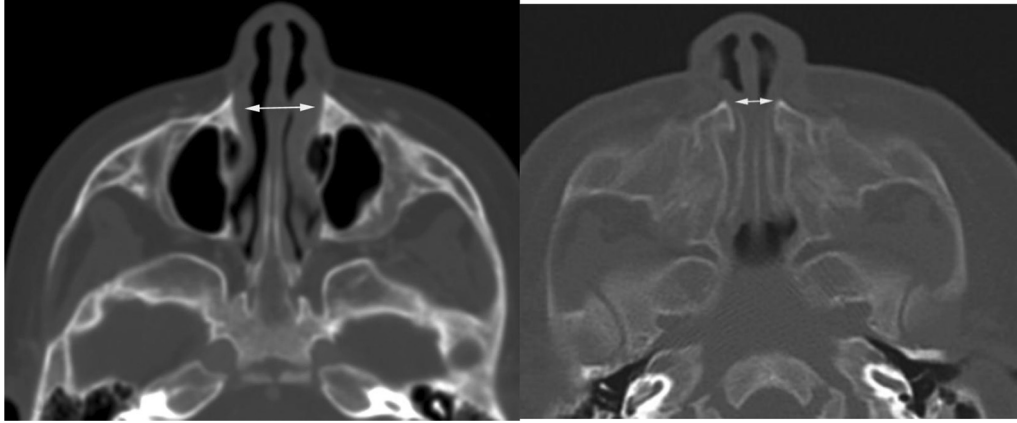


Fig. 2 – The width of the pyriform aperture is measured between the most medial segments of the frontal processes of the maxilla. On the left is an axial CT image of a normal 9-month-old female. On the right is a 9-month-old female with CNPAS. Note the arrows showing medial encroachment of the inferior portion of the maxillary frontal processes which seem to “pinch” the nasal aperture when compared with the normal infant on the left.

when SMMCI is specifically evaluated in patients with CNPAS, it has been found to be present in up to 65% of cases [9,10]. Conversely, in patients noted to have SMMCI, multiple studies show that CNPAS is the most common coexisting abnormality present in 55%-67% of patients [4,5,8,11]. Moreover, SMMCI patients have up to a 90% additive incidence of CNPAS, choanal atresia, or midnasal stenosis [4].

The exact etiology of SMMCI is unclear, but chromosomal abnormalities have been linked with cases of SMMCI. HPE genes have been proven to have genetic linkage to SMMCI with HPE genes reported in more than 10% of cases [7]. HPE includes a spectrum of malformations of the brain and face that involve cyclopia, midline cleft lip and palate, congenital heart disease, seizures, and mental retardation. Those affected by SMMCI with normal intelligence and normal brain imaging often have offspring with an increased incidence of a more severe manifestation of HPE [7,12]. Other associated findings with SMMCI include hypothalamo-pituitary axis (HPA) abnormalities like pituitary insufficiency and growth hormone deficiency which can be present in up to 33% of cases, resulting in short stature [4]. A study by Chen et al. pointed to a deficiency in the

literature in regard to recommendations for further screening of patients with CNPAS. They recommend baseline pituitary evaluation with brain MRI and baseline endocrine investigations along with growth monitoring for at least one year, as such abnormalities may have a delayed presentation [9]. Poelmans et al. [13] reported another genetic association with a point mutation in the sonic hedgehog gene along with point mutations in a variety of other genes involved in early odontogenesis. However, due to the rarity of this syndrome and variety in genotype-phenotype correlation, the percentage of incidence has yet to be researched.

MRI is highly predictive of pituitary dysfunction in children [14]. Over 50% of patients with an abnormal HPA on MRI have pituitary dysfunction [11]. However, there is no consensus in the literature for investigating the pituitary function of children with CNPAS. In an extensive literature review, Lo et al. [5] identified hypopituitarism or growth hormone deficiency in 43% of cases. Guilmin-Crepon et al. [11] investigated the HPA of 40 patients with CNPAS using pituitary stimulation tests and MRI of the brain and demonstrated pituitary hormone deficiencies in 25%. The most sensitive and early predictor of

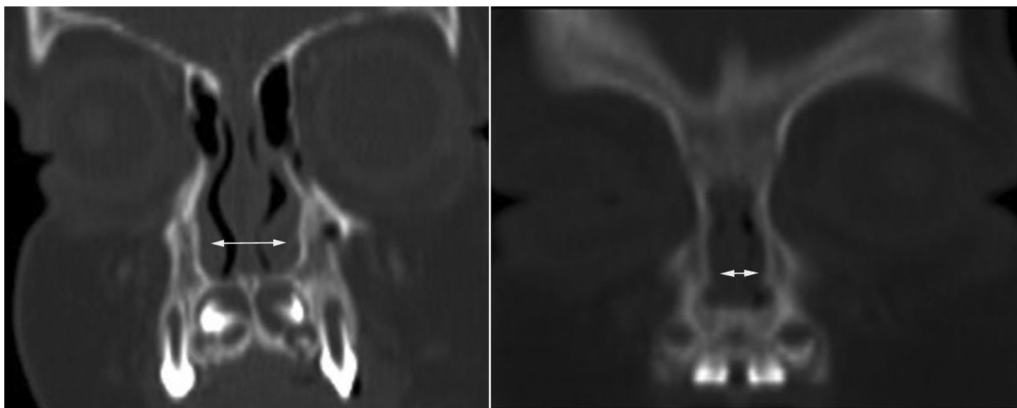


Fig. 3 – Coronal CT image showing normal width of the pyriform aperture in a 9-month-old female (left image). Compare to coronal CT image showing CNPAS in another 9-month-old female (right image).

pituitary dysfunction is the presence of clinical symptoms of hypoglycemia, hypotension, conjugated hyperbilirubinemia, or micropenis in the neonatal period [9].

Recommendations range from assessing basal levels of pituitary hormones, to various pituitary provocation tests. Early replacement of deficient pituitary hormones is important to recognize as they can significantly impact stature [15]. Endocrinology consultation should be taken in to consideration for screening recommendations for hypopituitarism: growth hormone deficiency (IGF-1), dopamine insufficiency (prolactin), adrenocorticotrophic hormone deficiency (blood glucose and cortisol), central hypothyroidism (free thyroxine and thyroid-stimulating hormone), and diabetes insipidus (electrolytes). Further investigations of pituitary function, including stimulation testing, are recommended if clinical symptoms such as hypoglycemia and jaundice are present, or if baseline endocrine tests are not normal [9].

CNPAS management benefits from multispecialty input involving the otolaryngologist, radiologist, endocrinologist, geneticist, and pediatrician. CNPAS with SMMCI patients should have an MRI of the brain and baseline endocrine investigations—or genetic and endocrine follow-up for risk stratification of other associated findings. Identifying other central defects with early recognition and treatment of pituitary insufficiency minimizes surgical risks and growth delay.

CNPAS is a rare cause of nasal obstruction that can be present as an isolated finding. However, more recent studies have shown up to 65% of patients with CNPAS can have coexisting SMMCI. SMMCI is diagnosed due to its characteristic single median maxillary incisor—these patients have a combined 90% incidence of midline congenital nasal obstruction. HPA-axis screening, endocrinology, and possibly genetic workup in a multidisciplinary approach should be considered in patients presenting with SMMCI. Patients with nasal obstruction secondary to CNPAS should be screened for a possible occult SMMCI during their surgical evaluation. CNPAS or SMMCI, regardless of which a patient presents with in presumed isolation, should lead one to suspect the other diagnosis as a likely possibility.

REFERENCES

[1] Harding R. Nasal obstruction in infancy. *Aust Paediatr J* 1985;22:59–61.

- [2] Prescott CA. Nasal obstruction in infancy. *Arch Dis Child* 1995;72:287–9.
- [3] Belden CJ, Mancuso AA, Schmalfluss IM. CT features of congenital nasal piriform aperture stenosis: initial experience 1. *Radiology* 1999;213:495–501.
- [4] Hall RK. Solitary median maxillary central incisor (SMMCI) syndrome. *Orphanet J Rare Dis* 2006;1:12.
- [5] Lo FS, Lee YJ, Lin SP, Shen EY, Huang JK, Lee KS. Solitary maxillary central incisor and congenital nasal pyriform aperture stenosis. *Eur J Pediatr* 1998;157:39–44.
- [6] Wormald R, Hinton-Bayre A, Bumbak P, Vijayasekaran S. Congenital nasal pyriform aperture stenosis 5.7 mm or less is associated with surgical intervention: a pooled case series. *Int J Pediatr Otorhinolaryngol* 2015;79:1802–5.
- [7] Nanni L, Ming JE, Du Y, Hall RK, Aldred M, Bankier A, et al. SHH mutation is associated with solitary median maxillary central incisor: a study of 13 patients and review of the literature. *Am J Med Genet* 2001;102:1–10.
- [8] Arlis H, Ward RF. Congenital nasal pyriform aperture stenosis. Isolated abnormality vs developmental field defect. *Arch Otolaryngol Head Neck Surg* 1992;118:989–91.
- [9] Chen SC, McDevitt H, Clement WA, Wynne DM, Mason A, Donaldson MD, et al. Early identification of pituitary dysfunction in congenital nasal pyriform aperture stenosis: recommendations based on experience in a single centre. *Horm Res Paediatr* 2015;83:302–10.
- [10] Gunther L, Sari-Rieger A, Jablonka K, Rustemeyer J. Clinical course and implications of pyriform stenosis and solitary median central incisor in a newborn: a case report. *J Med Case Rep* 2014;8:215.
- [11] Guilmin-Crepon S, Garel C, Baumann C, Bremond-Gignac D, Bailleul-Forestier I, Magnier S, et al. High proportion of pituitary abnormalities and other congenital defects in children with congenital nasal pyriform aperture stenosis. *Pediatr Res* 2006;60:478–84.
- [12] El-Jaick KB, Fonseca RF, Moreira MA, Ribeiro MG, Bolognese AM, Dias SO, et al. Single median maxillary central incisor: new data and mutation review. *Birth Defects Res Part A: Clin Mol Teratol* 2007;79:573–80.
- [13] Poelmans S, Kawamoto T, Cristofoli F, Politis C, Vermeesch J, Bailleul-Forestier I, et al. Genotypic and phenotypic variation in six patients with solitary median maxillary central incisor syndrome. *Am J Med Genet A* 2015;167:2451–8.
- [14] Mehta A, Hindmarsh PC, Mehta H, Turton JP, Russell-Eggitt I, Taylor D, et al. Congenital hypopituitarism: clinical, molecular and neuroradiological correlates. *Clin Endocrinol* 2009;71:376–82.
- [15] Beregszaszi M, Leger J, Garel C, Simon D, François M, Hassan M, et al. Nasal pyriform aperture stenosis and absence of the anterior pituitary gland: report of two cases. *J Pediatr* 1996;128:858–61.