



Contents lists available at ScienceDirect

## International Journal of Surgery Case Reports

journal homepage: [www.casereports.com](http://www.casereports.com)

## Type I locking of the metacarpophalangeal joint: A case report

Mohammad M. Al-Qattan<sup>a,\*</sup>, Atif Rafique<sup>b</sup><sup>a</sup> Division of Plastic Surgery at King Saud University, P.O. Box 18097, Riyadh 11415, Saudi Arabia<sup>b</sup> Division of Plastic Surgery at King Faisal Specialist Hospital and Research Center, Riyadh, Saudi Arabia

## ARTICLE INFO

## Article history:

Received 16 February 2016

Received in revised form 18 March 2016

Accepted 13 April 2016

Available online 19 April 2016

## Keywords:

Locked

Metacarpophalangeal

Joint

## ABSTRACT

**INTRODUCTION:** Type I locking of the metacarpophalangeal joint (MCPJ) is rare and is characterized by loss of extension at the MCPJ with full flexion of all joints of the digit. The condition is usually seen in the index and middle fingers when the normal osseous prominence or degenerative osteophytes of the radial condyle of the metacarpal head catches the accessory collateral ligaments of the MCPJ.

**PRESENTATION OF CASE:** We report on a case of Type I locking of the MCPJ affecting the index finger. The case was unusual because it might have been related to repeated stress while opening caps of specimen bottles in the laboratory. Furthermore, the impingement of the radial condyle of the metacarpal was to the sesamoid bone, and not to the collateral ligaments of the MCPJ. Finally, management was done by excision of the sesamoid bone rather than trimming of the prominence of the radial condyle of the metacarpals head.

**DISCUSSION:** Locking of the metacarpophalangeal joint (MCPJ) should be viewed as two different entities: The “locked MCPJ with further flexion possible” (Type I locking) and the “locked MCPJ with further flexion not possible” (Type II locking). Once the type of MCPJ locking is diagnosed clinically, radiological testing (X-rays, CT scan, MRI) may be done to direct further management to the cause of locking.

**CONCLUSION:** We present an unusual case of Type I locking of the MCPJ affecting the index finger.

© 2016 The Author(s). Published by Elsevier Ltd on behalf of IJS Publishing Group Ltd. This is an open access article under the CC BY-NC-ND license (<http://creativecommons.org/licenses/by-nc-nd/4.0/>).

## 1. Introduction

Locking of the metacarpophalangeal joint (MCPJ) should be viewed as two different entities. The “locked MCPJ with further flexion possible” (Type I locking) is rare and is characterized by loss of extension at the MCPJ with full flexion of all joints of the digit. The condition is usually seen in the index and middle fingers when the normal osseous prominence or degenerative osteophytes of the radial condyle of the metacarpal head catches the accessory collateral ligaments of the MCPJ [1,2]. The second entity (Type II locking) is the “locked MCPJ with further flexion not possible”. As the name implies, the patient is unable to actively flex the MCPJ. The condition is uncommon and is seen in all digits following an acute traumatic event resulting in an intra-articular entrapment of the palmar Plate [3], a sesamoid bone [4], or a loose body [5] within the MCPJ. MCPJ subluxation or dislocation will also result in this entity [6].

Once the type of MCPJ locking is diagnosed clinically, radiological testing (X-rays, CT scan, MRI) may be done to direct further management to the cause of locking. Management of the first entity (Type I locking) should start by a trial of closed reduction which may be facilitated by an intra-articular injection of xylocaine [7].

Yagi et al. [8] recommended gentle manual reduction by MCPJ flexion, radial deviation and external rotation of the proximal phalanx followed by gradual extension of the MCPJ. When this fails, surgical excision of the osseous prominence or osteophytes of the radial condyle of the metacarpal head is done either through a lateral or a palmar approach [2,9]. In contrast, management of the second entity (Type II locking) should be directed to removal of the intra-articular offending structure via a palmar approach [3–5]; or reduction of the subluxation/dislocation [6].

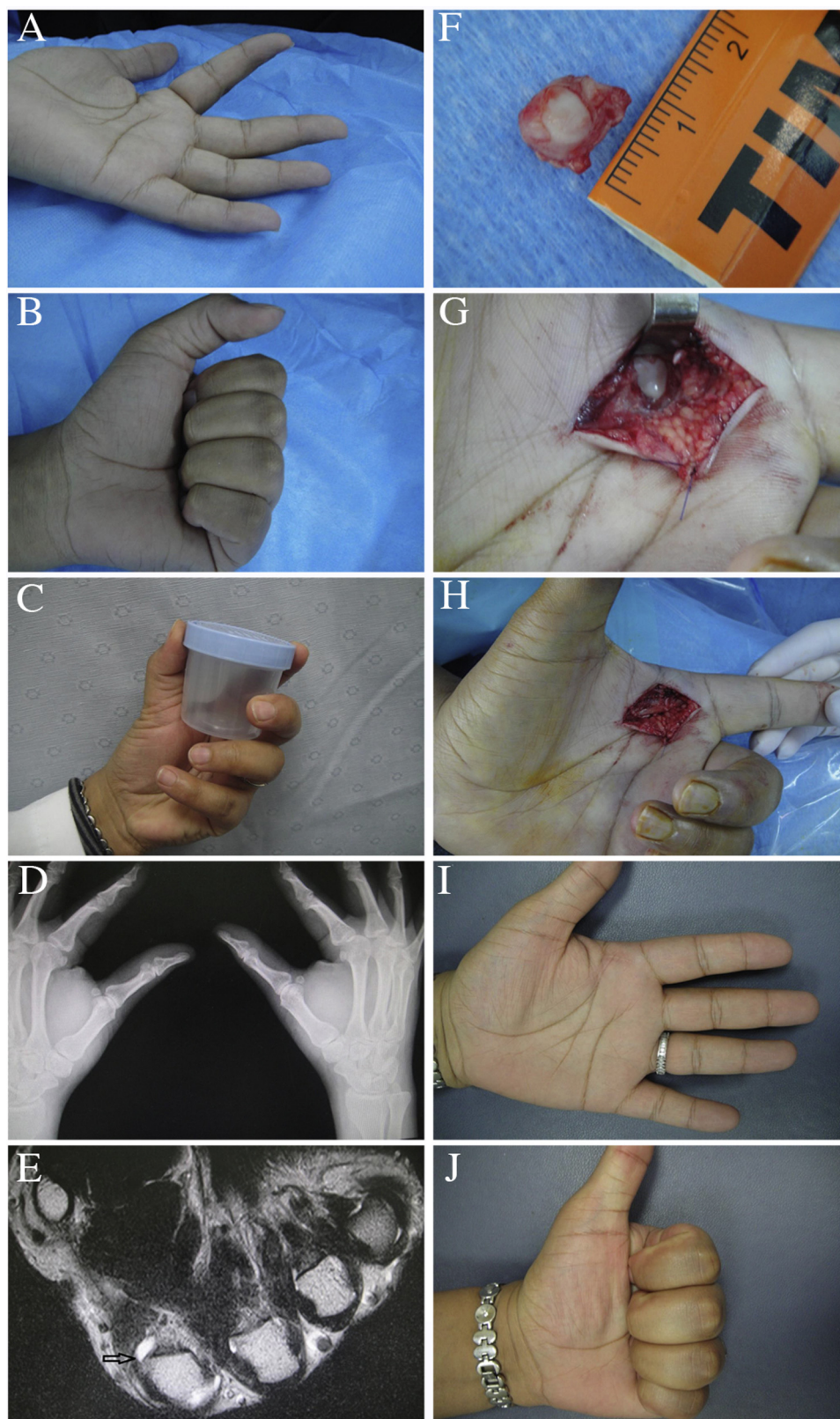
We report on a case of Type I locking of the MCPJ affecting the index finger. The case was unusual because it might have been related to repeated stress while opening caps of specimen bottles in the laboratory. Furthermore, the impingement of the radial condyle of the metacarpal was to the sesamoid bone, rather to the collateral ligaments of the MCPJ. Finally, management was done by excision of the sesamoid bone rather than trimming of the prominence of the radial condyle of the metacarpals head.

## 2. Presentation of case

A 32-year old female laboratory technician presented with a three-week history of locked MCPJ of the left index finger in 45° of flexion (Fig. 1A). No further extension at the MCPJ was possible, but she was able to flex the finger fully (Fig. 1B). Hence, the diagnosis of type I locked MCPJ was made. The patient worked in the laboratory for 6 years and has been opening the caps of spec-

\* Corresponding author.

E-mail address: [moqattan@hotmail.com](mailto:moqattan@hotmail.com) (M.M. Al-Qattan).



**Fig. 1.** (a) The locked MCPJ at the time of presentation with limitation of extension at MCPJ. (b) Full flexion is possible. (c) The way the patient opens the caps of specimen bottles in the laboratory. (d) Plain c-rays of both hands showing bilateral radial sesamoids of the index fingers with no displacement of the sesamoids. (e) MRI (T2 images) showing hyper-intensity around the radial sesamoids of the left index finger with impingement with bony prominence of the radial condyle of the metacarpal head (arrow). (f) The excised sesamoid and the surrounding palmar plate. (g) Excision exposed the metacarpal head. (h) Full extension of the finger immediately following sesamoid excision. (i and j) Full range of motion at 6 months.

**Table 1**  
Factors that predispose to the development of type I locking of the MCPJ.

Predisposing factors	Pathogenesis leading to type I locking of the MCPJ
Repeated thumb-to-index pinch (usually the index finger)	Impingement of the normal osseous prominence of the radial condyle of the metacarpal head of the index finger to the collateral ligaments or sesamoid bone.
Degenerative osteoarthritis (usually the middle finger)	Impingement of metacarpal head osteophytes to the collateral ligaments of the MCPJ.
Metacarpal head exostosis	Impingement of the exostosis to the collateral ligaments, palmar plate, interosseous tendon, or the sesamoid bone.
MCPJ palmar plate tumors	The tumor causes metacarpal neck resorption and secondary prominence of the metacarpal head
Acromegaly	Acromegaly predisposes to osteophytes of the metacarpal heads leading to impingement.
Gout	Gouty arthritis of the MCPJ may also lead to impingement.
Achondroplasia	Achondroplasia is associated to metacarpal head abnormalities predisposing to impingement.
Any metabolic or genetic disorder associated with secondary hyperparathyroidism (such as renal failure or PAX2 gene mutation which leads to renal failure)	Hyperparathyroidism increases the osteoclastic activity in the hand and predisposes to metacarpal neck resorption and prominence of the metacarpal heads.

imen bottles using the left hand repeatedly as shown in Fig. 1C. Over the last year prior to her presentation, she experienced several episodes of locking of the MCPJ when she stressed her hand at work. All episodes resolved spontaneously within 24–48 h; except for the last episode which persisted for 3 weeks. Examination confirmed type I locking of the MCPJ and there was tenderness over the radio-volar aspect of the MCPJ (over the area of the radial sesamoid). Plain x-rays of both hands showed bilateral symmetrical radial sesamoid bones of the index fingers with no displacements of the sesamoids (Fig. 1D). MRI showed synovitis around the radial sesamoid with impingement to the normal bony prominence of the radial condyle of the metacarpal head (Fig. 1E). Under general anesthesia, closed reduction was attempted but was not possible. The radial sesamoid and its surrounding palmar plate were then excised via a palmar incision (Fig. 1F and G). Immediately following sesamoid excision, full extension of the finger was obtained without any attempts of reducing the MCPJ (Fig. 1H). No splint was applied and the patient was instructed to use the hand freely. The patient returned to work two weeks later and was instructed not to open the caps of specimen bottles using one hand only as she used to do before surgery. She is now six months after surgery with no recurrence of the locking (Fig. 1I and J).

### 3. Discussion

Type I locking of the MCPJ is rare and is most commonly seen in the index finger. Kim et al. [2] stated that the reason for this preponderance is not clear, but proposed that the cause may be related to repeated thumb-to-index finger pinching which transmits repeated load to index radial metacarpal head. Our patient pinched and opened the caps of specimen bottles repeatedly using one hand and this supports the hypothesis of Kim et al. [2]. Our case was also unique because impingement of the radial condyle of the index finger metacarpal was to the sesamoid bone rather than to the accessory collateral ligament and locking resolved immediately once the sesamoid was excised. The case would be of interest to emergency physicians and hand surgeons.

Management of type I locking of the MCPJ should start with a trial of closed reduction. If that fails, open reduction with excision of offending cause of impingement (the metacarpal head prominence, the degenerative osteophytes, or the sesamoid) is performed. In our patient, excision of the sesamoid was curative.

We reviewed the literature on other factors that may predispose to the development of type I locking of the MCPJ, and we summarize our findings in Table 1. Degenerative osteophytes usually affect older patients and locking of the MCPJ usually involve the middle finger [1]. Metacarpal head abnormalities with type I locking of the MCPJ may also be caused by exostosis [10,11] MCPJ volar plate tumors [12], acromegaly [13], gouty arthritis [1], achon-

droplasia [14] and Hyperparathyroidism [15]. Although rare, the presentation and type of impingement in these metacarpal head abnormalities are different from cases related to repeated stress and degenerative osteophytes. Locking may be seen in any finger and initial presentation may be locking of multiple fingers [13]. Furthermore, the impingement of the abnormal metacarpal head may be to any structure around the MCPJ such as the collateral ligaments, the palmar plate, the interosseous tendon, or the sesamoid bone [10–15].

Finally, radiological assessment may be done for further assessment. Most authors recommended CT scans or MRI [1–15]. Wessely et al. [16] recommended dynamic ultrasound assessment. In our case, the MRI identified impingement to the sesamoid bone and excision of the sesamoid was curative.

### 4. Conclusion

We present an unusual case of Type I locking of the MCPJ affecting the index finger.

### Conflict of interest

None

### Funding

The work was supported by the College of Medicine Research Center, Deanship of Scientific Research, King Saud University, Riyadh, Saudi Arabia.

### Ethical approval

The study was approved by the research committee of the department of surgery at King Saud University

### Consent

Written informed consent was obtained from the patient for publication of this case report and accompanying images. A copy of the written consent is available for review by Editor-in-chief of this Journal on request.

### Authors contributions

Both authors have contributed significantly, and in agreement with the content of the manuscript. Both authors collected the data and wrote the paper. The senior author (M.M. Al-Qattan) performed the surgery.

**Guarantor**

M.M. Al-Qattan

**References**

- [1] M.A. Posner, V. Langa, S.M. Green, The locked metacarpophalangeal joint: diagnosis and treatment, *J. Hand Surg. Am.* 11 (2) (1986) 249–253.
- [2] B.S. Kim, K.H. Park, S.Y. Park, J.S. Yu, Y.H. Kim, Ligament preserving technique for a locked metacarpophalangeal joint of the index finger, *Clin. Orthop. Surg.* 7 (1) (2015) 104–109.
- [3] L. Thomsen, E. Roulot, B. Barbato, C. Dumontier, Locked metacarpophalangeal joint of long fingers: classification, definition and treatment based on 15 cases and literature review, *Chir. Main* 30 (4) (2011) 269–275.
- [4] S.S. Desai, W.J. Morgan, Locked thumb metacarpophalangeal joint caused by sesamoid entrapment, *J. Hand Surg. Am.* 16 (6) (1991) 1052–1055.
- [5] R. Honner, Locking of the metacarpo-phalangeal joint from a loose body. Report of a case, *J. Bone Joint Surg. Br.* 51 (3) (1969) 479–481.
- [6] K. Tajima, K. Sato, T. Sasaki, C.A. Peimer, Vertical locking of the metacarpophalangeal joint in young adults, *J. Hand Surg. Am.* 36 (9) (2011) 1482–1485.
- [7] G. Inoue, T. Miura, Locked metacarpophalangeal joint of the finger, *Orthop. Rev.* 20 (2) (1991) 149–153.
- [8] M. Yogi, K. Yamanak, K. Yoshida, N. Sato, Inoue Successful manual reduction of the locked metacarpophalangeal joints in fingers, *J. Bone Joint Surg. Am.* 82 (3) (2000) 366–371.
- [9] J.K. Kim, M.S. Chung, G.H. Baek, Locked metacarpophalangeal joint of the index finger: consideration about the surgical approach, *J. Hand Surg. Eur. Vol.* 34 (2) (2009) 278–280.
- [10] R.Q. Terrill, R.J. Groves, The locked metacarpophalangeal joint: report of four cases and review of the literature, *Contemp. Orthop.* 29 (2) (1994) 121–125.
- [11] M.D. Charendoff, Locking of the metacarpophalangeal joint: a case report, *J. Hand Surg. Am.* 4 (2) (1979) 173–175.
- [12] G.N. Fernandez, Locking of a metacarpo-phalangeal joint caused by a haemangioma of the volar plate, *J. Hand Surg. Br.* 13 (3) (1988) 323–324.
- [13] Y. Tani, N. Tanaka, E. Isoya, Locking of metacarpophalangeal joints in a patient with acromegaly, *Skeletal Radiol.* 28 (11) (1999) 655–657.
- [14] Y. Hamada, K. Sairyō, N. Yasui, Locking of the metacararpophalangeal joint as a result of the shape of the metacarpal head in achondroplasia, *J. Hand Surg. Eur. Vol.* 32 (5) (2007) 588–590.
- [15] F. Atlan, C. Oberlin, S. Durand, Locked metacarpophalangeal joint associated with PAX2 gene mutation: a case report, *J. Hand Surg. Eur. Vol.* 35 (6) (2010) 517–519.
- [16] K. Wessely, K. Owers, J. Healy, J. Lee, Ultrasound findings of the locked metacarpophalangeal joint, *Skeletal Radiol.* 38 (1) (2009) 85–89.

**Open Access**

This article is published Open Access at [scimedirect.com](http://scimedirect.com). It is distributed under the [IJSCR Supplemental terms and conditions](#), which permits unrestricted non commercial use, distribution, and reproduction in any medium, provided the original authors and source are credited.