

ORIGINAL
ARTICLE

Comparison of Extended Field of View and Dual Image Ultrasound Techniques for the Measurement of the Longitudinal Dimension of Enlarged Thyroid Glands

Ahmet Tuncay Turgut*, Zafer Ünsal Coşkun¹, Kemal Kısmet², Pınar Koşar,
Pınar Özdemir Geyik³, Uğur Koşar

Background: Extended field of view (EFOV) ultrasound (US) provides images with a large anatomic field of view and is a technical modification of conventional US. In this study, we aimed to assess the role of EFOV US in the accurate measurement of the longitudinal dimension of hyperplastic thyroid glands which were too big to be documented in a single image. In addition, the accuracy and reliability of EFOV US were compared with those of dual image US.

Patients and Methods: The actual longitudinal dimensions of 22 surgical specimens of thyroid glandular lobes excised by thyroidectomy were measured manually in the post-operative period. The longitudinal dimensions were also measured by two radiologists using EFOV US and dual image US after the surgical specimens were being placed in containers filled with gel.

Results: The accuracy and the reliability of EFOV US ($r=0.997-0.999$; reproducibility, 99.88%; repeatability, 99.88–99.92) were found to be higher than the dual imaging technique ($r=0.970-0.986$; reproducibility, 99.51%; repeatability, 99.56–99.59) in measuring the longitudinal dimension of enlarged thyroid glands. However, our results revealed that both US techniques can be considered in the evaluation of hyperplastic thyroid gland size. Dual image US should be regarded as the second choice for longitudinal dimension measurement of hyperplastic thyroid glands.

Conclusion: Based on our findings, we propose the use of EFOV US for accurate and reliable measurements in patients with an enlarged thyroid gland. EFOV US has a crucial role in the diagnosis and follow-up of patients undergoing medical therapy for diffuse or nodular goiter.

KEY WORDS — head, neck, ultrasound

■ *J Med Ultrasound* 2008;16(2):150–157 ■

The study was presented at the 2007 American Institute of Ultrasound in Medicine Annual Convention, March 15–18, 2007, New York, NY, USA.



Received: November 19, 2007 Accepted: January 4, 2008

Department of Radiology, Ankara Training and Research Hospital, ¹Department of Radiology, Turkish Armed Forces Rehabilitation and Care Center, ²Department of 4th General Surgery, Ankara Training and Research Hospital, and ³Department of Biostatistics, Hacettepe University, Faculty of Medicine, Ankara, Turkey.

*Address correspondence to: Dr. Ahmet Tuncay Turgut, 25 Cadde, 362 Sokak, Hüner Sitesi No. 18/30, TR-06530 Karakusunlar, Ankara, Turkey. E-mail: ahmettuncayturgut@yahoo.com

Introduction

The measurement of the dimensions of superficial anatomic structures or lesions using high-resolution ultrasound (US) is a routine procedure in clinical practice. The sonographic transducers, compared with other methods such as computed tomography or magnetic resonance imaging, enable the radiologist to scan in every position and every view owing to their small size and mobility. However, they have a major disadvantage in that they are inadequate for the documentation of relatively large superficial structures [1]. In this regard, anatomic structures with dimensions exceeding those of the sonographic transducer can be documented only with consecutive images. As the field of view (FOV) of the linear transducers, which is limited by the typical 4–6 cm probe width, is inadequate for depicting these structures in a single image, a wider US FOV is needed to display long anatomic segments, large lesions or entire abnormally enlarged organs. Extended field of view (EFOV) US is a technical modification of conventional US, which provides images with a large anatomic FOV while maintaining the traditional benefits of conventional US, such as high spatial resolution, low cost and the lack of ionizing radiation. Contrary to the static EFOV images produced by articulated arm scanners before the 1980s, the technique described by Weng and colleagues [2] allowed real-time EFOV imaging without the use of external sensors. On the other hand, dual display of US scans in the split screen mode is an alternative method, which allows dimension measurements of large lesions or anatomic structures [3].

Conventional US is limited in the depiction of entire glands, such as the hyperplastic thyroid gland, because the whole width and length of the thyroid cannot be included in a single image. In this study, we aimed to assess the role of EFOV US in the accurate measurement of hyperplastic thyroid glands, which were too big to be documented in a single image, and to compare the accuracy and reliability of EFOV US with that of dual image US. To the best of our knowledge, this is the first study in which the utility of these sonographic techniques

are compared in the assessment of thyroid gland size in humans.

Patients and Methods

Thirteen female patients with thyroid hyperplasia and a mean age of 40.9 ± 10 years (range, 24–65 years) undergoing bilateral subtotal or total thyroidectomy were included in this study. Out of 26 thyroid lobes removed during surgery, four single lobes from four patients could not be excised in one piece and were excluded because of resultant loss of anatomic integrity. Thus, measurement of the longitudinal dimension using US was carried out in the remaining 22 excised lobes. The actual longitudinal dimensions of these surgical specimens were measured manually in the postoperative period after being fixed in 10% formalin solution for 1 day (Fig. 1). The actual measurements of the longitudinal dimensions were calculated in millimeters and were performed by one of the authors. The surgical specimens were then embedded in containers filled with gel and were tightly covered with a thin layer of stretch film (Fig. 2). The study protocol was approved by the local institutional training board (ethical committee) of our hospital, and all patients included in the study gave their informed consent.

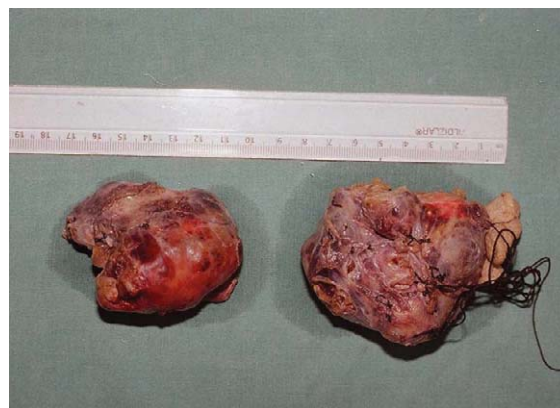

Fig. 1. The actual longitudinal dimension measurements of surgical specimens were performed manually in the postoperative period after being fixed in 10% formalin solution for 1 day.

Sonographic evaluation was performed using color Doppler ultrasonography (Sonoline Antares; Siemens AG, Erlangen, Germany) equipped with a 5–13 MHz VFX matrix linear array transducer with a scanning surface of 4 cm in length. All examinations were performed by two radiologists, radiologist 1 and radiologist 2, with 10 and 14 years' experience in conventional US imaging, respectively, and 6 months' and 2 years' experience in EFOV US imaging, respectively. The surgical specimens were scanned by each radiologist using both the dual image technique and EFOV imaging technology (Siescape; Siemens AG, Erlangen, Germany). Using the standard grayscale US examination, the gel within the containers appeared homogeneous

and hypoechoic, whereas the echogenicity of the surgical specimens was similar to that obtained during preoperative US examination of the thyroid gland. The tissue margins of the surgical specimens were discernible by US examination, which enabled accurate localization of the electronic calipers on the monitor of the US device for dimension measurements. The maximum longitudinal dimensions of the specimens were measured by two radiologists, who were blinded to the values obtained by two actual measurements carried out on the surgical specimens with an interval of 2 days between each measurement using each US technique (Fig. 3).

During the longitudinal scan using the dual image US technique, the scan was started at one end of the tissue specimen, and care was taken to include as much of the specimen in the first image as possible. The second image was obtained as the transducer was moved toward the other end of the specimen until the second image was aligned with the first image. The correct alignment of the images was determined by approximating the cut-off margin of the tissue specimen in the second image with that in the first image and by the correct alignment of the echogenic tissues of the surgical specimen in the two images monitored during the sweeping motion of the transducer, as described previously [4]. The standard distance of 3 mm for the gap between the two images on the monitor was subtracted from the calculated value of the longitudinal dimension of the specimen by dual image US



Fig. 2. The surgical specimens of hyperplastic thyroid glands were embedded in containers filled with gel, which were tightly covered with a thin layer of stretch film.

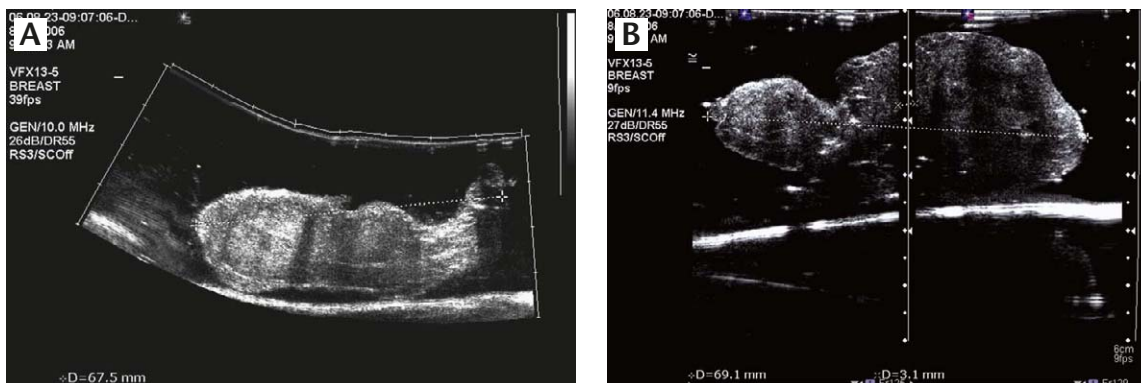


Fig. 3. The longitudinal dimension measurements of the specimens were performed by marking the tissue margins with electronic calipers (+) on (A) extended field of view ultrasound and (B) dual image ultrasound images. Note that the standard distance between the two images in dual image ultrasound was marked by the electronic calipers (x).

to ensure a more accurate measurement. In 13 cases where the longitudinal dimension of the surgical material was beyond the limits of the total FOV of the dual image in the split screen mode, a modification of the technique involving switching the first half of the screen for scanning the rest of the tissue specimen was used. The longitudinal scan using the EFOV technique was performed by moving the transducer from one end of the specimen to the other so that its entire length was included in the image. Reversal of scan direction which would destroy the image, or the transverse off-plane movement of the probe which would not be registered during image reconstruction resulting in image distortion and measurement inaccuracy, was being avoided. In addition, EFOV image scans containing artifacts, which would potentially limit the accuracy of the measurements, were excluded.

Statistical analyses were performed using the commercially available software, SPSS version 7.5 (SPSS Inc., Chicago, IL, USA) for Windows. The measured values using the two US techniques were compared with the actual longitudinal dimensions of the surgical specimens using Pearson's correlation coefficient (r). Intraclass correlation coefficient (ICC) was used for the evaluation of reproducibility (interobserver variability) and repeatability (intraobserver variability) of the measurements. A probability value of <0.05 was considered statistically significant.

Results

The mean actual longitudinal dimension of 22 surgical specimens was 62.3 mm (range, 41–90 mm). The sizes using the three types of measurements including mean standard deviation and ranges are shown in Table 1. Correlations of the measurements using EFOV and the dual image US techniques and the actual measurements of the surgical specimens in longitudinal axis are shown in Table 2. A high correlation was detected between the measurements using EFOV US ($r=0.997-0.999$; $p<0.001$) and those using dual image ($r=0.970-0.986$; $p<0.001$) and the actual dimension measurements

Table 1. Measurements of the maximum linear dimensions of the surgical specimens using extended field of view (EFOV) and dual image ultrasound (US) techniques by radiologist 1 and radiologist 2

Measurement	Mean (mm)	Standard deviation	Range (mm)
R1-EFOV ₁	62.6	13.7	42–91
R1-dual ₁	63.8	13.4	44–94
R1-EFOV ₂	62.5	13.9	42–92
R1-dual ₂	63.4	14.1	44–95
R2-EFOV ₁	61.9	14.0	43–92
R2-dual ₁	63.8	13.9	44–95
R2-EFOV ₂	62.6	13.7	41–91
R2-dual ₂	61.6	14.6	44–95

R1-EFOV₁ = first measurement of radiologist 1 using EFOV US; R1-dual₁ = first measurement of radiologist 1 using dual image US; R1-EFOV₂ = second measurement of radiologist 1 using EFOV US; R1-dual₂ = second measurement of radiologist 1 using dual image US; R2-EFOV₁ = first measurement of radiologist 2 using EFOV US; R2-dual₁ = first measurement of radiologist 2 using dual image US; R2-EFOV₂ = second measurement of radiologist 2 using EFOV US; R2-dual₂ = second measurement of radiologist 2 using dual image US.

Table 2. The correlation of the maximum linear dimension measurement using extended field of view (EFOV) and dual image ultrasound (US) techniques and the actual dimension measurement of the surgical specimen in longitudinal axis

Radiologists	US techniques	Pearson's correlation coefficient (r)	p
Radiologist 1	EFOV US	0.997	<0.001
	Dual image US	0.970	<0.001
Radiologist 2	EFOV US	0.999	<0.001
	Dual image US	0.986	<0.001

of the specimens by each radiologist. The interobserver variability (reproducibility) of EFOV and dual image US techniques in the measurement of the maximum longitudinal dimension of the surgical specimens are shown in Table 3. Importantly, a low interobserver variability was detected for both US techniques, although the ICC value for EFOV US (0.9986) was higher than that for dual image US (0.9951), revealing a reproducibility rate of 99.86% and 99.51%, respectively. The intraobserver variability (repeatability) of EFOV US and dual image

Table 3. Interobserver variability (reproducibility) of extended field of view (EFOV) and dual image ultrasound (US) techniques in the measurement of the longitudinal dimension of the surgical specimens

US techniques	ICC values	Lower 95% CI	Upper 95% CI	<i>p</i>
EFOV US	0.9986	0.9965	0.9994	<0.001
Dual image US	0.9951	0.9982	0.9980	<0.001

ICC = intraclass correlation coefficient; CI = confidence interval.

Table 4. Intraobserver variability (repeatability) of extended field of view (EFOV) and dual image ultrasound (US) techniques in the measurement of the longitudinal dimension of the surgical specimens

Radiologists	US techniques	ICC values	Lower 95% CI	Upper 95% CI	<i>p</i>
Radiologist 1	EFOV US	0.9988	0.9972	0.9995	<0.001
	Dual image US	0.9956	0.9895	0.9982	<0.001
Radiologist 2	EFOV US	0.9992	0.9981	0.9997	<0.001
	Dual image US	0.9959	0.9901	0.9983	<0.001

ICC = intraclass correlation coefficient; CI = confidence interval.

US in the actual measurement of the longitudinal dimension of the surgical specimens are shown in Table 4. Similarly, a low intraobserver variability was observed for both techniques, although the ICC for EFOV US (0.9988 and 0.9992 for radiologists 1 and 2, respectively) was higher than that for dual image US (0.9956 and 0.9959 for radiologists 1 and 2, respectively), revealing a repeatability rate of 99.88–99.92 for EFOV US and 99.56–99.59 for dual image US.

Discussion

The small size of high-resolution linear array transducers and the linear array of the US beam limit the use of standard linear US probes for displaying and calculating dimension measurements in medium-sized structures, such as the thyroid gland, as well as relatively large lesions or organs. Accordingly, there are several options available to overcome the limitations of standard US transducers to allow the measurement of structures larger than the dimensions of the transducer [3–5]. Among these, the use of lower frequency curved array transducers with a wider FOV in depth harbors the disadvantage of inadequate near-field resolution [3–5]. A wider

trapezoidal FOV provided by most recent linear-array transducers may be another choice. Alternatively, dual or side-by-side display of US scans in the split screen mode may be used for measurements during the evaluation of large lesions or anatomic structures [3]. However, the difficulty regarding the perfect juxtaposition of the two US scans for the two halves of a large lesion or structure, as well as inability to verify the absence of overlap of the two frames, limits the utility of the latter technique.

Technically, EFOV US imaging allows measurements without having to juxtapose two contiguous scans on the video monitor of the US unit. Real-time EFOV imaging involves the use of successive US images obtained when a standard transducer is scanned over a distance of up to 60 cm in any area of the body without any position sensors [2,6]. The technique involves the selection of the scan plane with the real-time probe and the initiation of the EFOV mode with a one-button function [7]. As the operator moves the probe over the skin surface in the direction of the scan plane, the real-time image is monitored on the screen, which allows the operator to visualize the structures in turn to be added to the EFOV file [7].

Importantly, the technique has been noted to be accurate and reliable in dimension measurements

[4,8]. Recently, Fornage et al [3] emphasized that dimension measurements up to 40 cm on technically optimal EFOV US scans are accurate. Moreover, it has been emphasized that EFOV imaging can be applied to the documentation of the area and volume, as well as the length of the structures [7,9]. It is noteworthy that sonographic evaluation using conventional US for change in lesion size is likely to be less accurate owing to the operator-dependent nature of the technique and the inadequacy of the transducer for lesions larger than the FOV of the transducer [10].

Clinically, an accurate measurement of thyroid volume is important in the diagnosis and follow-up of various thyroid disorders such as Graves disease and Hashimoto thyroiditis which cause enlargement of the thyroid gland [11,12]. Apart from the clinical examination involving palpation which is traditionally used to assess thyroid enlargement and has a subjective nature, sonographic measurement of thyroid volume using an ellipsoidal method which involves the measurement of mediolateral, anteroposterior and craniocaudal dimensions of the thyroid gland is the major way of estimating thyroid enlargement [13–15]. In a previous study, Özgen et al [16] reported that significant interobserver and intraobserver variations occurred in US measurement of thyroid volume in children. They also noted that the widest interobserver variation was encountered when determining the craniocaudal diameter of the thyroid gland [16]. It is also our experience during routine clinical practice that significant difficulty is encountered when using conventional US for measuring the craniocaudal diameter of the gland, particularly in cases of thyroid hyperplasia, owing to the inadequacy of the limited FOV of the typical 4–6 cm width of linear US probes. Moreover, we think that similar difficulties regarding the measurement of mediolateral and anteroposterior dimensions of the gland with significant hyperplasia frequently interferes with the ease and accuracy of relevant size assessment. However, we preferred to measure thyroid size in this study using the longitudinal axis of the thyroid specimens, as the difficulty experienced in the US evaluation of the size

of diffuse or nodular goiter is more prominent in the longitudinal axis.

EFOV allows visualization of a complete cross-sectional view of both thyroid lobes on a single image [17]. Importantly, the most significant benefit of this technique has been shown in diffuse disorders of the thyroid gland with an enhanced ability to demonstrate thyroid size, which can provide an accurate baseline for serial follow-up examinations [17]. In a recent study, Weissel [18] emphasized that EFOV US would avoid the frequent disadvantage of most diffuse or nodular goiters, in that their enormous size is incompatible with their documentation in one image. More recently, Ying and Sin [4] compared the accuracy of dual image and EFOV US techniques for distance measurements using acoustic phantoms. To our knowledge, there have been no previous studies comparing the performance of EFOV US and dual image US using human tissue. Interestingly, the mean value of 62.3 mm for the actual longitudinal dimensions of the thyroid specimens in the present study was similar to the mean distance value of 55.9 mm calculated by Ying and Sin [4] using phantoms. In the current study, we investigated the efficacy of EFOV US and dual image US in the accurate measurement of the longitudinal dimensions of hyperplastic thyroid glands.

Our findings clearly revealed that the linear measurements obtained using both US techniques were highly correlated with the actual dimensions of hyperplastic thyroid glands. However, the aforementioned correlation for EFOV US (0.997–0.999) was slightly higher than that for the dual image technique (0.970–0.986). In accordance with previous studies [2–4,7,9], these findings suggest that both EFOV US and dual image US are highly accurate in the measurement of enlarged thyroid glands. Furthermore, our findings demonstrated that dimension measurements performed using EFOV US and dual image US yielded high rates of reproducibility (99.86% and 99.51%, respectively) and repeatability (99.88%–99.92% and 99.56%–99.59%, respectively), although the aforementioned values were slightly higher for EFOV US. For dimension measurements using EFOV US, the calculated interobserver

and intraobserver variations were minimal in the present study, consistent with many previous studies [2–4].

In addition to high reproducibility and repeatability for EFOV US in this study, high reproducibility and repeatability were also obtained for dimension measurements using dual image US. We think that the reliability can be attributed to the technical suitability of high-resolution US in depicting the surgical specimen from its surrounding gel medium, which enabled easy merging of the two US images. Furthermore, we believe that no bias existed during measurement for both methods, as the radiologists were blinded to the values for the actual dimensions obtained earlier. Nevertheless, a major drawback in the use of dual image US was its inadequacy in cases where the longitudinal dimension of the specimen was beyond the limits of the total FOV of the dual image. Based on our findings and on those of previous studies, it is evident that EFOV US, as an alternative US technique, should be considered in cases with significant hyperplasia of the thyroid gland.

Note that the relatively sloping surface of the neck may be a limitation in the use of EFOV and dual image US in clinical practice, as it may limit the scanning procedure of both techniques resulting in possible inaccurate measurements. From a technical point of view, we suggest that the pressure applied by the probe may cause a slight curving appearance on the surface structure of the container covered with the thin stretch film, which could resemble the sloping neck surface in humans. Furthermore, the current surgical specimen model does not cover clinical situations involving retrosternal extension of the goiter and is inherently devoid of breathing or swallowing motion, which would impose a negative impact on the image construction using the EFOV technique in clinical practice. A minor limitation in the use of the EFOV technique may be the necessity for acquired skill to avoid the inherent artifacts that may interfere with the accuracy of dimension measurements, in spite of the relatively little degree of experience required to make accurate measurements [3].

In this study, the accuracy and reliability of EFOV US were found to be higher than those of the dual image technique in the measurement of the longitudinal dimension of enlarged thyroid glands. However, our results clearly revealed that both techniques could be considered in the evaluation of thyroid gland hyperplasia. Therefore, we suggest that the dual image technique should be regarded as the second choice for dimension measurements in patients with hyperplastic thyroid gland. Based on our observations, it may be concluded that the use of EFOV US allows for a more accurate and reliable size measurement in enlarged thyroid glands and has a crucial role in the diagnosis and follow-up of patients undergoing medical therapy for diffuse or nodular goiter.

References

1. Kröger K, Massalha K, Dobonici G, et al. SieScape: a new sonographic dimension with fictive images. *Ultrasound Med Biol* 1998;24:1125–9.
2. Weng L, Tirumalai AP, Lowery CM, et al. US extended-field-of-view imaging technology. *Radiology* 1997;203:877–80.
3. Fornage BD, Atkinson EN, Nock LF, et al. US with extended field of view: phantom-tested accuracy of distance measurements. *Radiology* 2000;214:579–84.
4. Ying M, Sin MH. Comparison of extended field of view and dual image ultrasound techniques: accuracy and reliability of distance measurements in phantom study. *Ultrasound Med Biol* 2005;31:79–83.
5. Peeters EY, Shabana WM, Verbeek PA, et al. Use of a curved-array transducer to reduce interobserver variation in sonographic measurement of thyroid volume in healthy adults. *J Clin Ultrasound* 2003;31:189–93.
6. Hara Y, Nakamura M, Tamaki N. A new sonographic technique for assessing carotid artery disease: extended-field-of-view imaging. *AJNR Am J Neuroradiol* 1999;20:267–70.
7. Sauerbrei EE. Extended field-of-view sonography: utility in clinical practice. *J Ultrasound Med* 1999;18:335–41.
8. Hangiandreou NJ. AAPM/RSNA physics tutorial for residents: topics in US. B-mode US: basic concepts and new technology. *Radiographics* 2003;23:1019–33.

9. Kim SH, Choi BI, Kim KW, et al. Extended field-of-view sonography: advantages in abdominal applications. *J Ultrasound Med* 2003;22:385-94.
10. Lin EC, Middleton WD, Teefey SA. Extended field of view sonography in musculoskeletal imaging. *J Ultrasound Med* 1999;18:147-52.
11. Clarke SEM, Rankin SC. The thyroid gland. *Imaging* 2002;14:103-14.
12. Shabana W, Peeters E, Verbeek P, et al. Reducing interobserver variation in thyroid volume calculation using a new formula and technique. *Eur J Ultrasound* 2003;16:207-10.
13. Ng E, Chen T, Lam R, et al. Three-dimensional ultrasound measurement of thyroid volume in asymptomatic male Chinese. *Ultrasound Med Biol* 2004;30:1427-33.
14. Riccabona M, Nelson TR, Pretorius DH, et al. Distance and volume measurement using three-dimensional ultrasonography. *J Ultrasound Med* 1995;14:881-6.
15. van Isselt JW, de Klerk JM, van Rijk PP, et al. Comparison of methods for thyroid volume estimation in patients with Graves' disease. *Eur J Nucl Med Mol Imaging* 2003;30:525-31.
16. Özgen A, Erol C, Kaya A, et al. Interobserver and intraobserver variations in sonographic measurement of thyroid volume in children. *Eur J Endocrinol* 1999;140:328-31.
17. Shapiro RS. Panoramic ultrasound of the thyroid. *Thyroid* 2003;13:177-81.
18. Weissel M. Panoramic ultrasound of the thyroid. *Thyroid* 2003;13:892.