


Contents lists available at ScienceDirect

Urology Case Reports

journal homepage: www.elsevier.com/locate/eucr

Oncology

Ductal Adenocarcinoma of the Prostate With a Rare Clinical Presentation; Late Gastric Metastasis

Hasan Huseyin Tavukcu^{a,*}, Omer Aytac^a, Fatma Aktepe^b, Fatih Atug^a, Levent Erdem^c, Coskun Tecimer^d^a Istanbul Bilim University Medical School, Department of Urology, Turkey^b Istanbul Bilim University Medical School, Department of Pathology, Turkey^c Istanbul Bilim University Medical School, Department of Gastroenterology, Turkey^d Istanbul Bilim University Medical School, Department of Medical Oncology, Turkey

ARTICLE INFO

Article history:

Received 22 March 2016

Accepted 30 March 2016

Keywords:

Ductal prostatic adenocarcinoma

Gastroscopy

Metastasis

Prostatectomy

ABSTRACT

A 67 year male had robotic prostatectomy whose pathology revealed mixed type prostate cancer composed of 55% ductal and 45% acinar components. The patient was then admitted to hospital with sudden health problems including ascites and serious vomiting attacks in the 46th month after prostatectomy and the PSA test was 4565 ng/mL. Gastroscopic biopsy was reported and proved immunohistochemically undifferentiated ductal prostate cancer metastasis. This is the first report of late gastric metastasis of ductal prostate cancer.

© 2016 The Authors. Published by Elsevier Inc. This is an open access article under the CC BY-NC-ND license (<http://creativecommons.org/licenses/by-nc-nd/4.0/>).

Introduction

Prostatic ductal adenocarcinoma (PDA) is a rare histological variant of prostate cancer (PC) that the prevalence of pure PDA diagnosed with biopsy is around 0.4%–1% and 5% for mixed ductal variants.¹ PDA mainly arises from periurethral prostatic ducts, and patients with this variant may present gross hematuria or urinary obstructive symptoms. PDA has a worse prognosis than acinar adenocarcinoma. In this case report, we aim to present a patient with mixed PDA that had late gastric metastasis.

Case report

We present a clinical case report of a 67 year-old patient with unremarkable digital rectal examination had third biopsy was performed because of rising prostate specific antigen (PSA) levels (6.3 ng/mL). The pathological investigation reported acinar PC with a Gleason score 6 (3+3), involving 30% of three cores. A pelvic MR imaging demonstrated no extraprostatic extension and no metastasis. Robotic radical prostatectomy was performed with an uneventful perioperative period. Pelvic lymphadenectomy was not

performed because the patient was in a low risk group. Final pathology revealed mixed type PC composed of 55% ductal and 45% acinar components. The total cancer volume was 30% with negative surgical margins (Fig. 1).

After regular follow-up with low PSA levels (0.05 ng/mL at the 6th month), at the 12th month a PSA value of 0.47 ng/mL was reported and adjuvant pelvic radiotherapy was administered. After this period PSA tests were in nadir till the 40th month. The patient was then admitted to hospital with ascites and serious vomiting attacks in the 46th month. The PSA test was 4565 ng/mL, the creatinine level was 1.4 mg/dL, and MR imaging reported bilateral high grade (2–3) hydronephrosis with enlarged pelvic lymph nodes and multiple bone metastases (Fig. 2a). Parasyntesis was performed due to massive ascites and at this period creatinine levels elevated to 6 mg/dL. The histopathology of gastroscopic reported undifferentiated prostate cancer metastasis (Fig. 2b). Immunohistochemically, the neoplastic cells showed positive stains for alpha methylacyl coenzyme A-reductase (AMACR) (Fig. 2c) and negative for cytokeratin 7 (CK 7) which are the typical immunohistochemical markers. AMACR is mainly expressed in PDA while CK 7, which is secreted from basal cells, is a negative marker for PDA.

Metastases of bone, pelvic lymph nodes, and peritoneum were also reported with MR imaging and regular parasyntesis performed for abdominal distention. Maximal androgen deprivation therapy was started immediately. After the injection of 11.25 mg of leuprolide acetate, creatinine levels dramatically decreased to

* Corresponding author.

E-mail addresses: hhtavukcu@gmail.com, hhtavukcu@yahoo.com (H.H. Tavukcu).

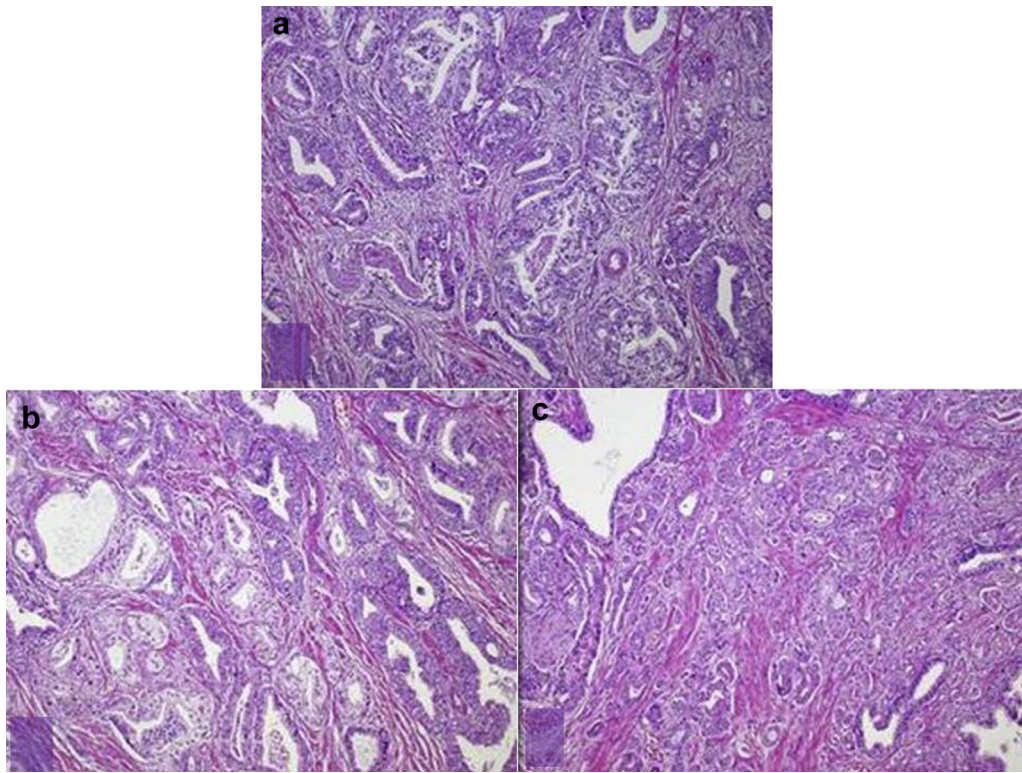


Figure 1. a. Stain of prostatic ductal adenocarcinoma; In the microscopic examination of the prostatectomy material, among the areas of classical prostatic acinar adenocarcinoma, there were adenocarcinoma cells composed of malignant neoplastic proliferation with papillary and cribriform architecture. Complex, branching architecture typical of prostatic ductal adenocarcinoma (H&E, $\times 40$). b. Acinar adenocarcinoma pattern; small atypical glands infiltrating in between larger glands (H&E, $\times 40$). c. Mixed pattern, ductal adenocarcinoma and acinar adenocarcinoma (H&E, $\times 40$).

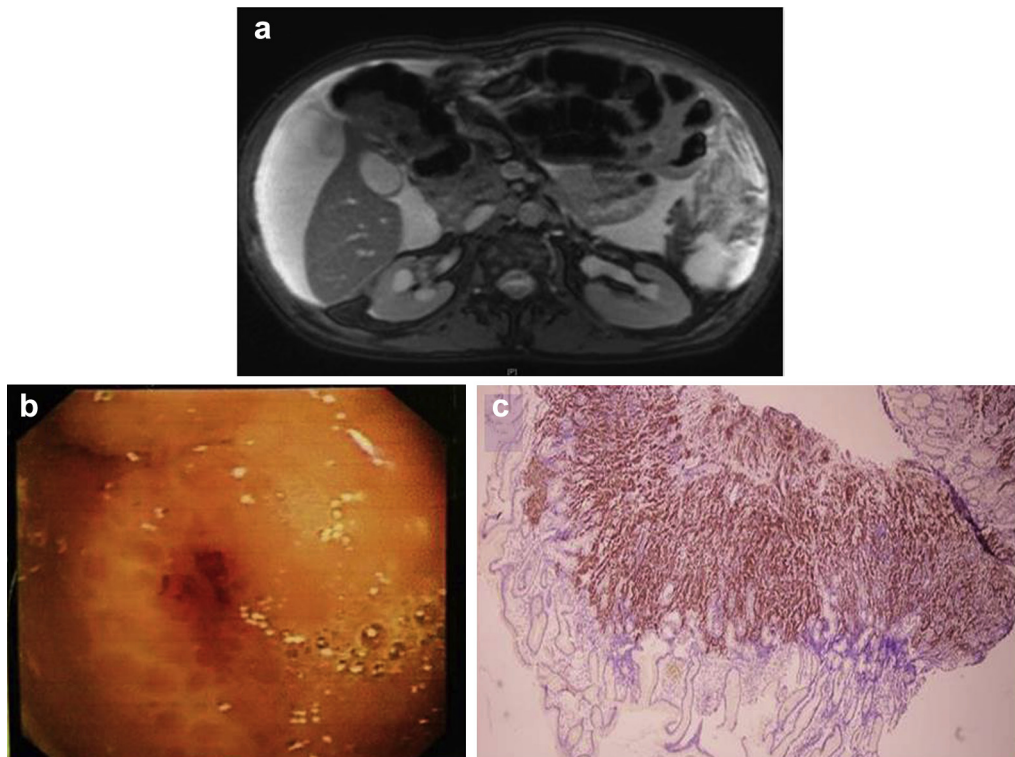


Figure 2. a. MR imaging revealing bilateral hydronephrosis of kidney. b. Endoscopic scene of suspicious area in gastric fundus. c. Diffuse AMACR positivity is seen in nearly all neoplastic cells that obtained from gastric biopsy (immunoperoxidase, $\times 40$).

1.28 mg/mL in the second week. Pelvic lymph nodes regressed in the MR imaging control. PSA levels decreased to 554 ng/mL in the second month of maximal androgen blockage however in the third month PSA levels were elevated to 839 ng/mL. After PSA elevation docetaxel chemotherapy was started. It was decided to convert to cabazitaxel regimen after the third cycle of docetaxel chemotherapy. Unfortunately in the second cycle of cabazitaxel treatment the patient developed ileus and soon the patient died as a result of the progression of symptoms.

Discussion

In comparison with classical acinar PC, PDA is a rare PC type with 5%–10% of all PC. As most PDA patients display urinary symptoms, our patient also had mild to moderate symptoms of urination that were controlled with oral medication. Patients with PDA are reported generally at the ages of 60–70 years as in our patient who was 67 year-old. PDA is identified mostly in the central region due to origin of prostatic ducts. In previous reports patients with PDA present symptoms including macroscopic hematuria or urinary retention.² Conversely, our patient had no hematuria and urinary retention at all.

Morgan et al³ reported patients with PDA that is independent of other clinicopathological variables have twice the possibility to have a lower PSA of 4.0 ng/mL. Our patient's previous PSA was not lower than 4.0 ng/mL at the beginning, and had no other high risk findings of MR imaging. PDA is more likely to present distant metastasis and in men with nondistant metastasis at diagnosis ductal histology was associated with 2.2 fold disease specific mortality.

After operation patient's pathology was reported with mixed type PDA; in current literature it was reported mostly after prostate needle biopsy and then transurethral resection of prostate, and very rarely after radical prostatectomy.¹

The pathological grade of PDA tends to be higher and PDA is usually identified with Gleason pattern 4 and 5. Most of the patients with PDA are in advanced disease, had poor prognosis and distant metastasis.³ While our patient had nadir PSA levels until the 12th month after the surgery, with a slightly elevated PSA of 0.47 ng/mL, adjuvant radiotherapy was performed with the current dose of 72 cGy for local disease control in the 12th month.

Prostatic ductal adenocarcinoma is known to have a tendency to metastases in distant sites and organs such as lung, rectum, testis, penis, retrovesical space and retroperitoneal region, and sometimes

with cystic components.³ Previous reports also recommend paying special attention to early bone or other visceral metastases. Although gastric metastasis of prostatic acinar adenocarcinoma was reported before to the best of our knowledge this is the first case of gastric metastasis with PDA that is reported in the literature.⁴

Hardie and colleagues reported a patient diagnosed with PDA to rectal wall invasion that underwent neoadjuvant external beam radiotherapy and concomitant hormonal therapy, MR imaging response was marked. Then definitive prostatectomy and pelvic exenteration was performed. In the pathology specimen there were no evidence of positive surgical margins and lymph node metastasis.⁵ In our case first cancer relapse in the first year when PSA was 0.47 ng/mL, pelvic salvage extended lymphadenectomy might have been performed before or after radiotherapy with concomitant hormonal therapy; these approaches may contribute to better survival.

Conclusion

As loco regional progression is more common in PDA, late distant metastasis of PDA unfortunately has really fulminant clinical progression as in our patient.

Conflict of interest

None.

Source of funding

None.

References

1. Epstein JI, Cubilla AL, Humphrey PA. *Tumors of the Prostate Gland, Seminal Vesicles, Penis, and Scrotum*. American Registry of Pathology; 2011.
2. Linden-Castro E, Pelayo-Nieto M, Alias-Melgar A, et al. Abiraterone acetate and castration resistant ductal adenocarcinoma of the prostate. *Case Rep Urol*. 2014;2014.
3. Morgan TM, Welty CJ, Vakar-Lopez F, et al. Ductal adenocarcinoma of the prostate: increased mortality risk and decreased serum prostate specific antigen. *J Urol*. 2010 Dec;184(6):2303–2307.
4. Gore RM, Sparberg M. Metastatic carcinoma of the prostate to the esophagus. *Am J Gastroenterol*. 1982 Jun;77(6):358–359.
5. Hardie AD, Naveed MA, Clarke HS. Ductal prostatic adenocarcinoma: magnetic resonance imaging documenting the effect of hormone-radiotherapy. *J Coll Physicians Surg Pak*. 2014;24:S55–S56.