

A new technique for hypogastric artery embolization

Jose Patricio Linares-Palomino, MD, PhD, Luis Miguel Salmerón, MD, PhD, and Eduardo Ros-Díe, MD, PhD *Granada, Spain*

We report a new procedure for embolization of hypogastric arteries simultaneously with aortoiliac stenting. Eight patients with aortoiliac ($n = 6$) and iliac ($n = 2$) aneurysms have been treated with this procedure. The technique involves the placement of a hook catheter near the hypogastric artery or in the sac, and the endoprosthesis insertion is done by using the same arteriotomy. The endoprosthesis is deployed and the coil is released. Saline is injected into the sac. The catheter is removed and the balloon at the distal end of the endoprosthesis is inflated. Computed tomography images showed periprosthesis or aneurysm thrombosis. No endoleaks or coils displacement in the sac were found. (*J Vasc Surg* 2006;43:1064-7.)

Aneurysmal involvement of the common iliac artery (CIA) complicates endoluminal treatment of abdominal aortic aneurysm (AAA) because it requires extension of the endoprosthesis to the external iliac artery (EIA). In such cases, exclusion of the hypogastric artery is indicated to prevent periprosthetic reflux, thus decreasing the risk of occurrence of a type II endoleak. There are two alternatives for excluding hypogastric artery: selective embolization and simple coverage with the limb of the endoprosthesis that is anchored at the EIA. Also in patients with isolated CIA or combined CIA-EIA aneurysms, selective embolization of the internal iliac artery is therefore required.¹⁻²

Most authors recommend embolization before the endovascular procedure.^{1,3,4} Few authors simultaneously perform embolization and implantation.⁵ Hypogastric artery embolization may be required to interrupt a potential route of type II endoleak through a common iliac aneurysm into an associated aortic aneurysm. In such cases, iliac tortuosity, stenosis, and mural thrombosis sometimes complicate selective catheterization of the hypogastric artery. We report our initial experience with a new technique for nonselective hypogastric artery embolization at the time of endoprosthesis placement surgery.

Circumstances in which we have applied nonselective hypogastric artery embolization include marked tortuosity in the iliac axes, anticipating that it will be difficult to catheterize the ostium of hypogastric artery; hypogastric artery aneurysms; in the presence of mural thrombosis in the CIA or EIA, and when we have already performed a selective embolization in the contralateral hypogastric artery and then have to simultaneously place the endoprosthesis to exclude the ipsilateral hypogastric artery.

METHODS

Endovascular technique for nonselective embolization. The common femoral artery is exposed on the same side as the hypogastric artery to be occluded (*Fig 1*), is punctured, and a 5F Easy Guide introducer (Medex Medical, Lancashire, United Kingdom) is placed.

A hooked catheter (1 hook, 2 hook, or multipurpose) is placed as close as possible to the hypogastric artery ostium or directly into the iliac aneurysm sac. The femoral artery is punctured again at the same level as the position of the first introducer, and an Easy Glide 7F introducer is placed that will be used as a maneuver port for endoprosthesis implantation. After placement of a rigid Amplatz-type 0.35-inch guidewire (Emerald Guidewire, Cordis, Miami, Fla), an arteriotomy is performed from one introducer to the other and is used to insert the endoprosthesis.

The proximal stent is deployed and the balloon is expanded in the proximal neck. An extension to the EIA in the same axis is assembled. The area joining the stents is balloon expanded, and then the coils are released. For biiliac stents, the coils are released before assembly of the contralateral extension, but for monoiliac stents, they are released before distal balloon expansion. We use 8- to 10-mm embolization coils of the M-Reye type (William Cook Europe, Bjæverskov, Denmark).

If the coils successfully navigate the hypogastric artery opening, they will have approximately the same size as the diameter of the main hypogastric artery trunk; for anatomically very hostile hypogastric arteries, multiple coils of various diameters are released into the periprosthetic space, and the catheter is moved to place them all around the sac.

Saline (100 to 200 mL) is injected into this sac, or in the space between the common iliac artery and the external wall of the endoprosthesis, to push the coils toward the hypogastric artery opening and fix them in a stable form.

Arteriography is done through this catheter, and then the catheter used for embolization is removed. Balloon expansion is performed in the distal end of the endoprosthesis and/or the assembly of the contralateral extension. All endoprostheses used in these nonselective embolization

From the Department of Vascular Surgery, San Cecilio University Hospital. Competition of interest: none.

Reprint requests: Dr Jose Patricio Linares-Palomino, Servicio de Cirugía Vascular, Hospital Universitario San Cecilio de Granada. Avda. de Madrid s/n 18014, Granada, España (e-mail: jlinaresp@seacv.org). 0741-5214/\$32.00

Copyright © 2006 by The Society for Vascular Surgery.

doi:10.1016/j.jvs.2005.12.061

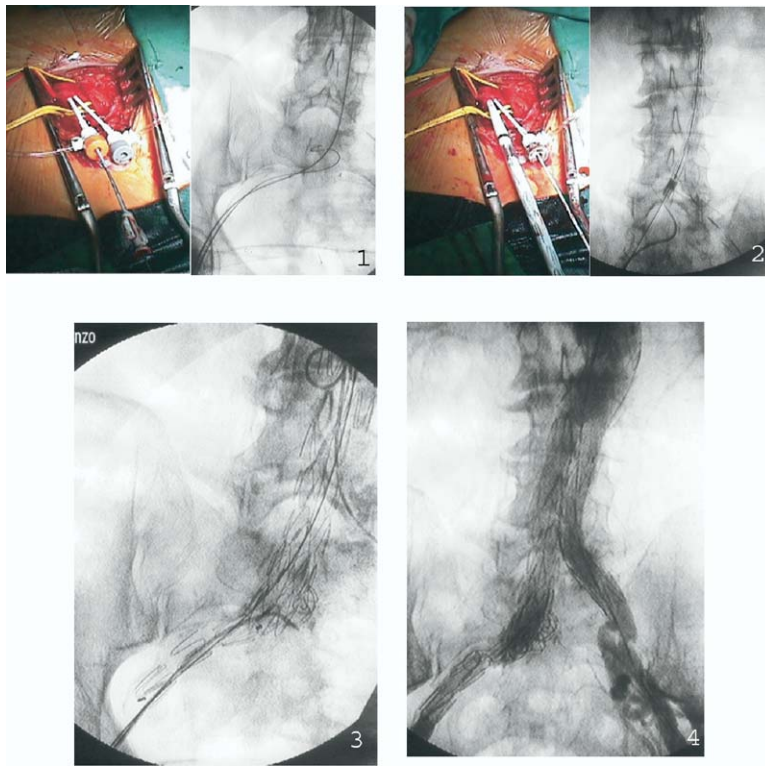


Fig 1. The general sequence of the nonselective hypogastric artery embolization technique is shown. **1,** Dual catheterization of the common femoral artery and passage of two independent navigation systems. **2,** Introduction and release of aortoiliac endoprosthesis in parallel to the coil-releasing catheter. **3,** Sequential release of coils. **4,** Final result. Arteriography with the endoprosthesis already implanted.

procedures were of Talent model (Medtronic AVE, Santa Rosa, Calif).

Patients. From January 2000 to April 2005, 100 patients with AAA were consecutively treated using endovascular surgery techniques at the Department of Vascular Surgery of Granada University Hospital, Spain.

The new procedure for nonselective hypogastric artery embolization was applied in eight patients (all of whom were men). Of these patients, two had iliac aneurysms, two had symmetric type E AAAs, and four had type D-E asymmetric AAAs of EUROSTAR⁶ classification.

The criteria for extending the distal anchorage area of the iliac extension of the endoprosthesis to the EIA were a CIA aneurysm >20 mm in diameter, a hypogastric artery aneurysm >20 mm in diameter, or the presence of a circumferential thrombus in CIA, even if the diameter was <20 mm.

In these nonselective hypogastric artery embolization cases, the standard follow-up protocol was modified by including a computed tomography (CT) scan before discharge, in the first week, and another at 1 month after surgery. CT scans were again conducted at 3 and 6 months, and very 6 months thereafter. Abdominal radiographs were simultaneously obtained in two positions.

RESULTS

Technical success occurred in eight of the nonselective hypogastric artery embolization intention to treat cases. The rate of type II endoleak due to re-entry through a patent hypogastric artery in our series was 0%. Gluteal claudication occurred in four of the eight patients undergoing nonselective hypogastric artery embolization. Claudication resolved in two of these patients within 6 months. No colic ischemia occurred with this new technique.

During the intraoperative procedure for nonselective embolization, two patients had complete sac thrombosis. Thrombosis was seen in the CT at 1 week in another four patients. The remaining two patients were discharged with contrast in the sac, but the CT scan at 1 month showed they had already occluded. A significant fact in nonselective hypogastric artery embolization is thrombosis involving the common iliac sac and hypogastric artery trunk only, while the secondary pelvic branches remain patent (n = 6) (Fig 2).

DISCUSSION

Over the years, the traditional principle of preserving pelvic flow in aortoiliac surgery was respected⁷ until endovascular surgery procedures were developed to treat AAAs.³

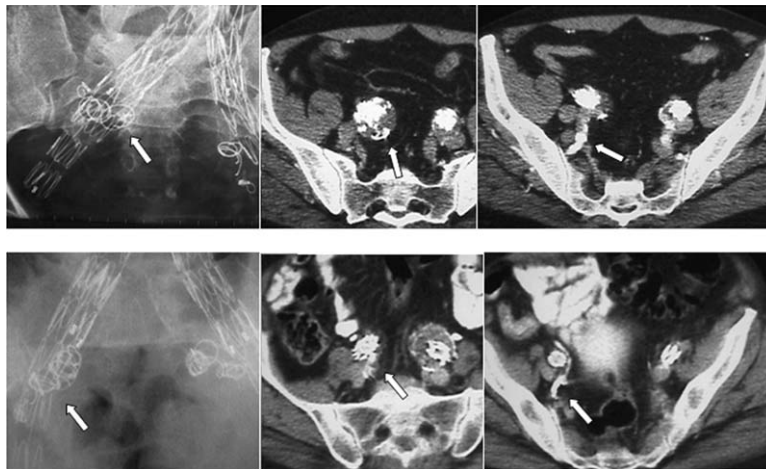


Fig 2. Radiographic and CT controls of two patients treated by selective embolization of the left hypogastric artery before surgery. In a second time, right nonselective hypogastric artery embolization was performed simultaneously with placement of an aortobiliac endoprosthesis. On the left and center images, *arrows* mark the position of the coils. Arrows in left images show occlusion of the hypogastric artery trunk and the patency of pelvic branches.

Many experts believe this classical principle is not applicable to the new, less-aggressive percutaneous treatment methods.^{1,2} The use of coils to occlude one or both hypogastric arteries has fewer consequences than surgical ligation because flow interruption occurs through gradual thrombosis of the hypogastric artery, leaving time for the establishment of collateral circulation.^{2,8}

Little mention has been made of the impossibility of hypogastric artery catheterization and embolization before endoprosthesis placement. In a series published by Criado et al,² a 7.5% failure rate was reported. The extreme anatomic difficulties in some of our patients led us to develop this nonselective hypogastric artery embolization procedure, which has been shown to be very simple to perform at the time of endoprosthesis placement surgery.

The minimum technical requirements for nonselective hypogastric artery embolization are similar to those required for placement of an aortobiliac endoprosthesis. Special reference should be made to the diameter of the common femoral artery, which must accommodate a 22F to 24F device and the 5F introducer for the embolization maneuver (8 mm plus 1.6 mm).

It should be noted that for some authors, endovascular manipulation of the hypogastric artery opening is one of the determinant factors for microembolization causing colic ischemia,^{3,9} particularly in cases of CIA aneurysm. This occurs less with the nonselective hypogastric artery embolization procedure presented here, because hypogastric artery catheterization is not attempted in any case.

Partly based on the accumulated experience, we attempted to thrombose only the main trunk of the hypogastric artery, avoiding embolization of distal branches.^{3,10} The nonselective embolization technique only occluded the hypogastric artery, and control tests have shown thrombosis of the main trunk and patency of distal branches in six cases, ensuring pelvic vascularization.

To prevent the final placement of small coils in hypogastric artery branches, we have only used 8- or 10-mm-diameter coils. The criteria to determine the size of the released coils is the diameter of hypogastric artery trunk. In hypogastric artery aneurysms, we have used 10-mm coils.

A matter to be considered is the type of endoprosthesis used. It seems appropriate to only use prostheses for this method that have a stent endoskeleton and prosthetic covering on the other wall. Theoretically, coils would not tangle up with the endoprosthesis stents and would navigate more easily toward the hypogastric artery opening. We have tried nonselective hypogastric artery embolization using an endoprosthesis that had an external nitinol skeleton, with no complications of coil fixation to the endoprosthesis wall or removal of the coil-releasing catheter.

CONCLUSION

The concept of selective embolization of the hypogastric artery trunk by catheterization of its ostium using catheter-based technology represents the extrapolation of a classic surgical technique (hypogastric artery ligation) to the field of endovascular surgery. Many groups with accumulated experience simply cover the ostium of hypogastric artery with the endoprosthesis, and they find few endoleaks. With our nonselective hypogastric artery embolization technique, we attempt to reduce them. The therapeutic approach in endovascular surgery should not be the one inherited from conventional surgery. Our nonselective embolization of a space located between the endoprosthesis and the CIA wall has been shown to be effective in thrombosing the hypogastric artery trunk.

Our accumulated experience and the follow-up period are still insufficient, and we are therefore cautious about recommending this procedure as a general technique for preventing type II endoleaks due to re-entry from the hypogastric artery in endovascular surgery for AAAs. Our

results suggest that this technique could be a good option to the endovascular exclusion of the hypogastric artery in some endovascular aneurysm repair cases.

REFERENCES

1. Yano OJ, Morrissey N, Eisen L, Faries PL, Soundararajan K, Wan S, et al. Intentional internal iliac artery occlusion to facilitate endovascular repair of aortoiliac aneurysms. *J Vasc Surg* 2001;34:204-11.
2. Criado FJ, Wilson EP, Velásquez OC, Carpenter JP, Barker C, Wellons E, et al. Safety of coil embolization of the internal iliac artery in endovascular grafting of abdominal aortic aneurysms. *J Vasc Surg* 2000;32:684-8.
3. Geraghty PJ, Sanchez LA, Rubin BG, Choi ET, Flye MW, Curci JA, et al. Overt ischemic colitis after endovascular repair of aortoiliac aneurysms. *J Vasc Surg* 2004;40:413-8.
4. Karch LA, Hodgson KJ, Mattos MA, Bohannon WT, Ramsey DE, McLafferty RB. Adverse consequences of iliac artery occlusion during endovascular repair of abdominal aortic aneurysms. *J Vasc Sur* 2000;32:676-83.
5. Cao P, Verzini F, Parlani G, Romano L, De Rango P, Pagliuca V, et al. Clinical effect of abdominal aortic aneurysms endografting: 7-year concurrent comparison with open repair. *J Vasc Surg* 2004;40:841-8.
6. Harris P and EUROSTAR Collaborators. Progress report, including the data of the overall patients cohort, EUROSTAR Data Registry Centre. January 2001. www.csvs.org/docs/Eurostar_jan_2001.pdf (accessed Feb 16, 2006).
7. Andriole GL, Sugarbaker PH. Perineal and bladder necrosis following bilateral internal iliac ligation. Report of a case. *Dis Colon Rectum* 1985;28:183-4.
8. Criado FJ. Iliac bifurcation relocation: more complex and controversial. *J Endovasc Surg* 1999;16:548-9.
9. Cohnert TU, Oelert F, Wahlers T, Gohrbandt B, Chavan A, Farber A, et al. Matched-pair analysis of conventional versus endoluminal AAA treatment outcomes during the initial phase of an aortic endografting program. *J Endovasc Ther* 2000;7:94-100.
10. Kritpracha B, Pigott JP, Price CI, Russell TE, Corbey MJ, Beebe HG. Distal internal iliac artery embolization: a procedure to avoid. *J Vasc Surg* 2003;37:943-8.

Submitted Oct 9, 2005; accepted Dec 10, 2005.