

## Pneumoscrotum, pneumomediastinum, pneumothorax, and pneumorrhachis following colon surgery

Anass Anaye, M.D., Constantin Moschopoulos, M.D., Emmanuel Agneessens, M.D., and Bernard Hainaux, M.D.

We report the case of an 80-year-old man who developed a colocutaneous fistula as a complication of anastomotic leakage following segmental colonic resection. The patient presented with an abscess of the abdominal wall, subcutaneous emphysema, pneumomediastinum, pneumothorax, pneumorrhachis, and pneumoscrotum. We discuss the possible mechanisms for these unusual clinical presentations of extraperitoneal air following anastomotic leak.

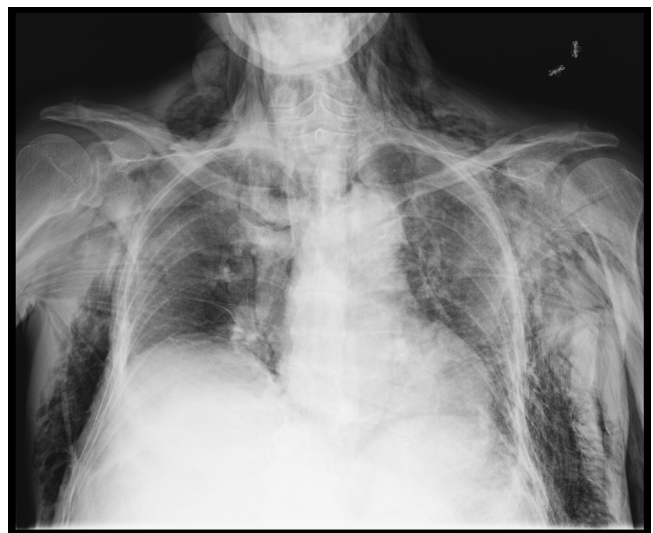Anastomotic leaks increase morbidity and mortality after colorectal surgery. Usually the leakage occurs into the peritoneum, causing peritoneal irritation. Few cases of retroperitoneal leakage have been described. We report a rare case of a colonic postoperative leakage leading to colocutaneous fistula and, as a consequence, spread of gas into multiple extraperitoneal areas.

### Case report

An 80-year-old man presented to the Emergency Department with massive subcutaneous emphysema and pneumoscrotum. The patient had undergone a segmental colon resection for a polyp of the splenic angle 15 days before. Postoperatively, his course was uneventful. On examination, the patient had marked swelling of the neck, upper chest, and scrotum. He had mild tenderness and

crepitation of the left flank. There was no abdominal defense or rebound. The main laboratory findings on admission were leukocytosis with WBCs of 25900/mm<sup>3</sup> and remarkable increased C-reactive protein of 27, 9 mg/dl.

Chest radiograph and abdominal radiograph showed extensive subcutaneous emphysema over the neck, anterior chest wall (Fig. 1), and abdominal wall (Fig. 2). Body com-



**Figure 1.** 80-year-old man with massive subcutaneous emphysema. Chest radiograph shows subcutaneous emphysema over anterior chest wall and neck.

**Citation:** Anaye A, Moschopoulos C, Agneessens E, Hainaux B. Pneumoscrotum, pneumomediastinum, pneumothorax and pneumorrhachis following colon surgery. *Radiology Case Reports*. [Online] 2008;3:216.

**Copyright:** © 2008 The Authors. This is an open-access article distributed under the terms of the Creative Commons Attribution-NonCommercial-NoDerivs 2.5 License, which permits reproduction and distribution, provided the original work is properly cited. Commercial use and derivative works are not permitted.

Anass Anaye, M.D. (Email: [aanaye@ulb.ac.be](mailto:aanaye@ulb.ac.be)), Constantin Moschopoulos, M.D., and Bernard Hainaux, M.D., are in the Department of Radiology, CHU Saint-Pierre, Université Libre de Bruxelles, 322 rue Haute, Brussels 1000, Belgium.

Emmanuel Agneessens, M.D., and Bernard Hainaux, M.D., are in the Department of Radiology, HIS Etterbeek-Ixelles, 63 rue Jean Paquot, Brussels 1050, Belgium.

**Competing Interests:** The authors have declared that no competing interests exist.

DOI: 10.2484/rcr.v3i4.216

## Pneumoscrotum, pneumomediastinum, pneumothorax, and pneumorrhachis following colon surgery

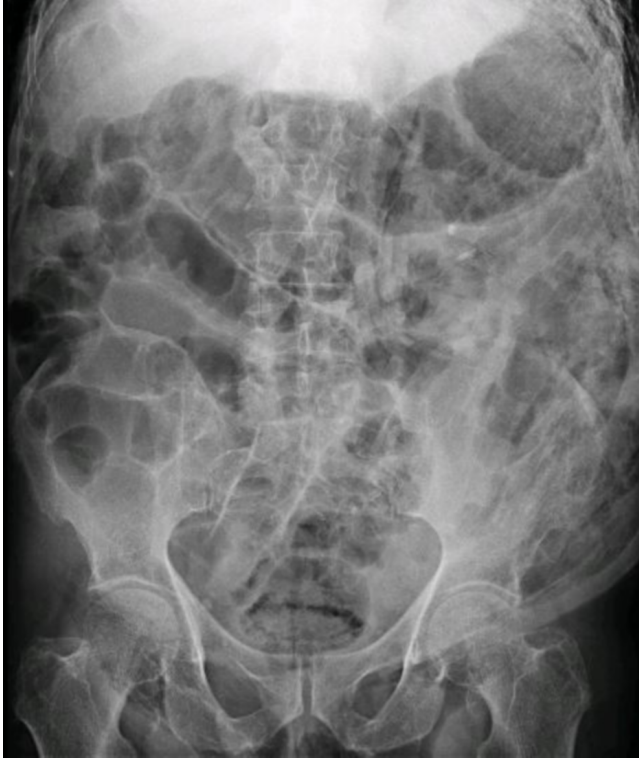

Figure 2. 80-year-old man with massive subcutaneous emphysema. Abdominal radiograph shows extensive subcutaneous emphysema of the abdominal wall.

puted tomography (CT) without oral or intravenous contrast confirmed the radiographic findings and demonstrated pneumorrhachis (Fig. 3), as well as pneumomediastinum, pneumothorax, and pneumoscrotum. CT also revealed a fistula between the colic anastomosis and the left abdominal wall leading to the formation of an abscess in the abdominal wall. A few bubbles of extraluminal air were seen in the proximity of the anastomotic leak. Once his condition was stable, the patient was transferred to the operating room. Surgical exploration revealed a fecaloïd abscess of the abdominal wall, and it confirmed the anastomotic leakage and the colocutaneous fistula.

### Discussion

Anastomotic leaks are one of the major complications of colorectal surgery, leading to serious consequences with impacts on morbidity and mortality. Reported rates for experienced surgeons range from 3.4% to 6% [1, 2]. Usually, diagnosis of an anastomotic leak is based on clinical and radiological findings. Frequently, signs of anastomotic leak in the early postoperative period are fever, ileus, renal failure, leukocytosis, and also presence of pus or fecal material in the abdominal drain [3]. However, because of the nonspecificity of the clinical signs, radiological investigation is often required. Currently, CT scan appears to be the best imaging method for the detection of anastomotic leaks [3,

4]. Common findings on CT are pneumoperitoneum, contrast medium leak, or intraperitoneal abscess formation.

The majority of anastomotic leaks that occur are intraperitoneal. Few cases of anastomotic leaks into the retroperitoneum have been described [5, 6]. Our case presented

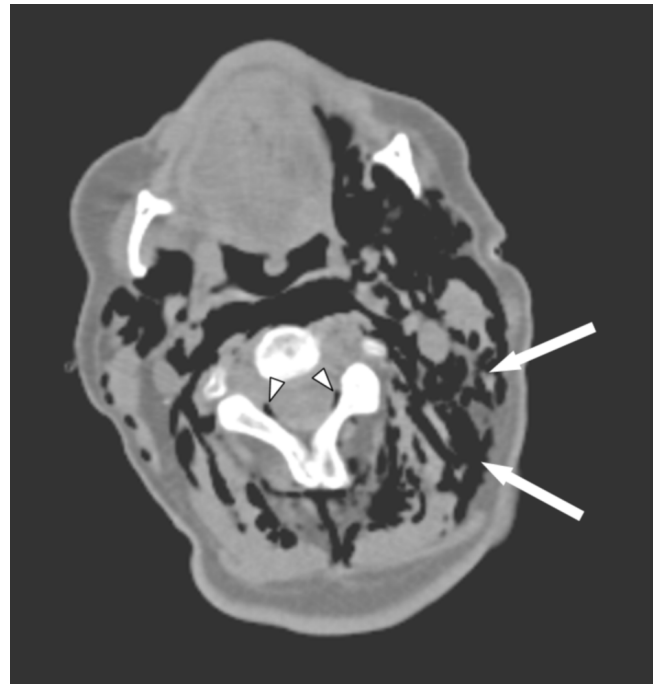


Figure 3A. 80-year-old man with massive subcutaneous emphysema. Axial CT at the level of the neck shows extensive subcutaneous emphysema (arrows) and pneumorrhachis (arrowheads).

with subcutaneous emphysema, pneumoscrotum, pneumomediastinum, pneumothorax, and pneumorrhachis due to colocutaneous fistula after colon surgery, which is to our knowledge the first case reported in the English literature. Subcutaneous emphysema and pneumoscrotum of gastrointestinal origin are unusual signs of intestinal perforation. The presentation of the emphysema is determined by the anatomic location of the primary perforation [7]. In our case, it can be explained by two phenomena. First, gas can spread into the abdominal wall by direct communication through the colocutaneous fistula. Second, the abscess of the abdominal wall with gas-producing organisms may have contributed to the subcutaneous emphysema.

Pneumoscrotum occasionally can be associated with retroperitoneal or intraperitoneal perforation [8]. In our case, the source of air in the scrotum was the subcutaneous emphysema due to the colocutaneous fistula. Once the air reached the subcutaneous tissues, it may have dissected into the dartos lining of the scrotal wall, causing pneumoscrotum [8]. The anatomical continuity of those soft tissues

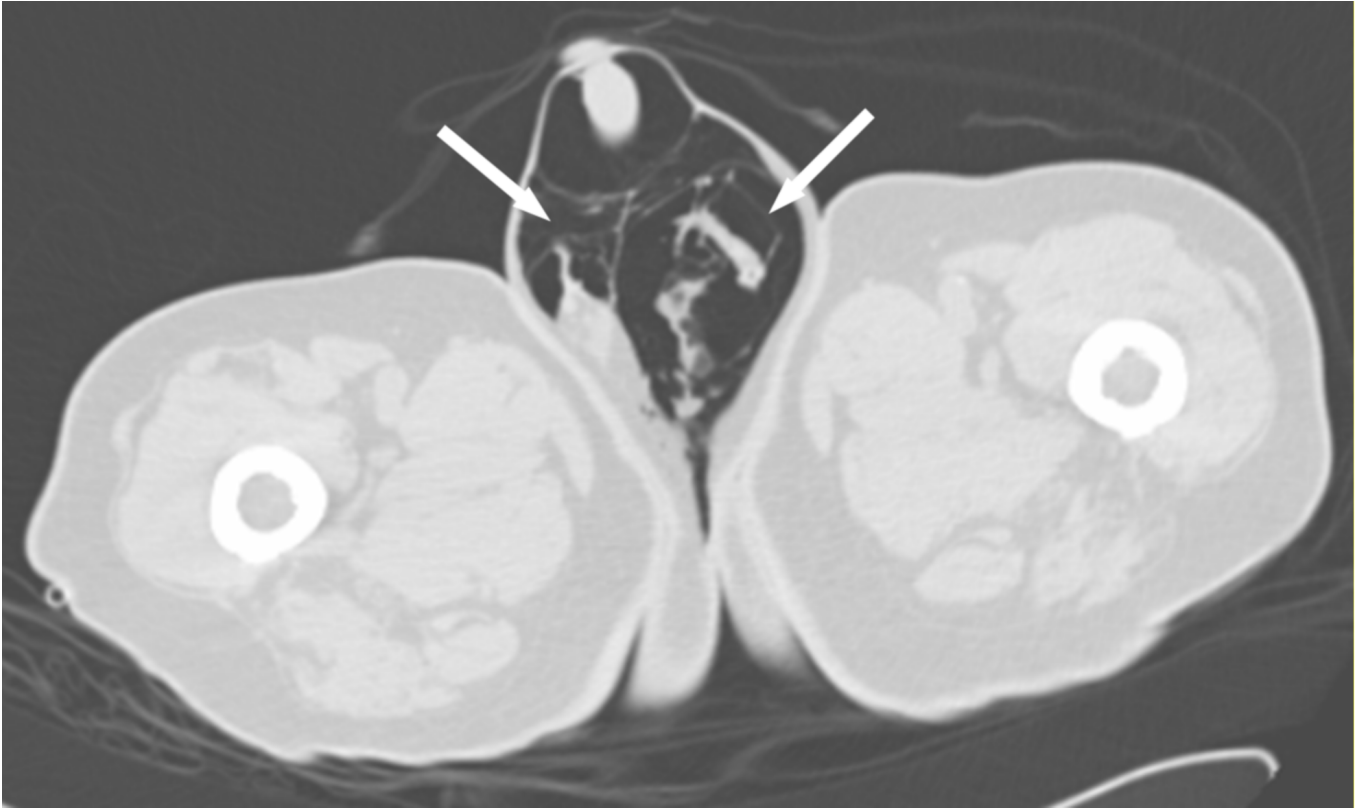

Figure 3B. 80-year-old man with massive subcutaneous emphysema. CT of perineum shows bilateral intrascrotal air (arrows).

explains spread of gas into the other extraperitoneal areas in our patient. It is well established that an anatomical route along the fascial planes exists between the neck, the chest, and the abdomen [9, 10]. And because fascial planes in the neck communicate through the retropharyngeal space with the mediastinum, air can track into the thorax and even into the epidural space [11]. This explained the pneumomediastinum, pneumothorax, and pneumorrhachis in this patient.

In conclusion, our case describes an unusual complication of colorectal surgery. Examiners should consider, in the postoperative period, the possibility of an anastomotic leak into an extraperitoneal space in a patient presenting with extraperitoneal air without signs of peritoneal irritation.

**Acknowledgment**

The authors would like to acknowledge gratefully Dr. Vera Hoylman and Dr. Mark Ayoubi for helpful suggestions.

**References**

1. Golub R, Golub RW, Cantu R, Stein HD. A multivariate analysis of factors contributing to leakage of intestinal

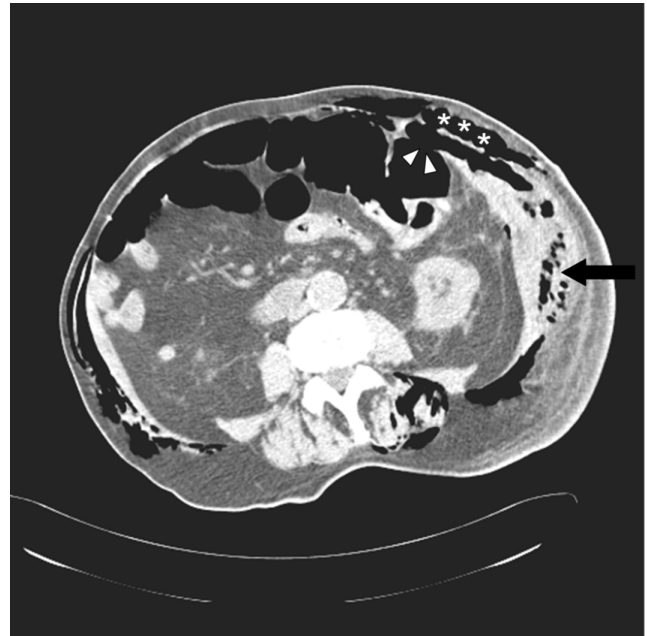


Figure 3C. 80-year-old man with massive subcutaneous emphysema. Abdominal CT at the level of the left kidney shows the colocolic fistula (arrowheads) and abscess of the abdominal wall (arrow). Subcutaneous emphysema is also present at this level (asterisks).

## Pneumoscrotum, pneumomediastinum, pneumothorax, and pneumorrhachis following colon surgery

- anastomoses. *J Am Coll Surg* 1997; 184: 364-372. [PubMed]
2. Alves A, Panis Y, Trancart D. Factors associated with clinically significant anastomotic leakage after large bowel resection: multivariate analysis of 707 patients. *World J Surg* 2002; 26: 499-502. [PubMed]
  3. Alves A, Panis Y, Pocard M. Management of anastomotic leakage after nondiverted large bowel resection. *J Am Coll Surg* 1999; 189: 554-559. [PubMed]
  4. Hyman N, Manchester TL, Osler T, Burns B, Cataldo P. Anastomotic leaks after intestinal anastomosis: it's later than you think. *Ann Surg* 2007; 245:254-258. [PubMed]
  5. Holton LH, Migaly J, Rolandelli RH. Pneumorrhachis, subcutaneous emphysema, pneumomediastinum, pneumopericardium, and pneumoretroperitoneum after proctocolectomy for ulcerative colitis. *Dis Colon Rectum* 2002; 45: 567-570. [PubMed]
  6. Mohammad SK, Sorensen SL. Pneumomediastinum as a sign of anastomotic leakage. *Ugerskr Laeger* 2007; 169: 1692-1693. [PubMed]
  7. Oetting HK, Kramer NE, Branch WE. Subcutaneous emphysema of gastrointestinal origin. *Am J Med* 1955; 19: 872-886. [PubMed]
  8. Watson S, Klugo R, Coffield S. Pneumoscrotum: report of two cases and review of mechanisms of its development. *Urology* 1992; 40: 517-521. [PubMed]
  9. Maunder RJ, Pierson DJ, Hudson LD. Subcutaneous and mediastinal emphysema. *Arch Int Med* 1984; 144: 1447-1453. [PubMed]
  10. Meyers MA. Radiological feature of the spread and localization of extraperitoneal gas and their relationship to its source. *Radiology* 1974; 111: 17-26. [PubMed]
  11. Burn JM, Guyer PB, Langdon L. The spread of solutions injected into the epidural space; a study using epidurograms in patients with lumbosciatic syndrome. *Br J Anaesth* 1973; 45: 334-338. [PubMed]