

Available online at [www.sciencedirect.com](http://www.sciencedirect.com)

ScienceDirect

journal homepage: [www.elsevier.com/locate/ajur](http://www.elsevier.com/locate/ajur)

## CASE REPORT

# Superselective embolisation of bilateral superior vesical arteries for management of intractable hematuria in context of metastatic bladder cancer

Ahmed Saadi <sup>a,\*</sup>, Abderrazak Bouzouita <sup>a</sup>,  
 Mohamed Hedi Rebai <sup>a</sup>, Mohamed Cherif <sup>a</sup>, Walid Kerkeni <sup>a</sup>,  
 Haroun Ayed <sup>a</sup>, Amine Derouiche <sup>a</sup>, Hatem Rajhi <sup>b</sup>,  
 Riadh Ben Slama <sup>a</sup>, Najla Mnif <sup>b</sup>, Mohamed Chebil <sup>a</sup>

<sup>a</sup> Department of Urology, Charles Nicolle University Hospital, Tunis, Tunisia

<sup>b</sup> Department of Radiology, Charles Nicolle University Hospital, Tunis, Tunisia

Received 14 August 2015; received in revised form 15 December 2015; accepted 22 March 2016

## KEYWORDS

Urinary bladder neoplasms;  
 Hematuria;  
 Therapeutic embolisation

**Abstract** Hematuria due to locally advanced or metastatic bladder cancer is a common condition and is often a management problem. Percutaneous embolisation is a mini-invasive option to handle this situation. We report a case of a patient with a metastatic bladder cancer and who presented with an abundant hematuria and severe anemia. After failure of endoscopic resections and “flush” of radiotherapy haemostatic and refusal of cystectomy by the patient, he was treated by superselective embolisation of bilateral superior vesical arteries with excellent immediate results. The technique is safe and effective in the short term. The long-term effectiveness requires further investigation.

© 2016 Editorial Office of Asian Journal of Urology. Production and hosting by Elsevier B.V. Ltd. This is an open access article under the CC BY-NC-ND license (<http://creativecommons.org/licenses/by-nc-nd/4.0/>).

## 1. Introduction

In a patient with bladder urothelial cancer that is not suitable for or does not choose curative treatment, intractable hematuria is a disastrous condition. Several means are available to handle this situation as trans-

\* Corresponding author.

E-mail address: [dr.saadi.ahmed@gmail.com](mailto:dr.saadi.ahmed@gmail.com) (A. Saadi).

Peer review under responsibility of Second Military Medical University.

<http://dx.doi.org/10.1016/j.ajur.2016.03.003>

2214-3882/© 2016 Editorial Office of Asian Journal of Urology. Production and hosting by Elsevier B.V. Ltd. This is an open access article under the CC BY-NC-ND license (<http://creativecommons.org/licenses/by-nc-nd/4.0/>).

Please cite this article in press as: Saadi A, et al., Superselective embolisation of bilateral superior vesical arteries for management of intractable hematuria in context of metastatic bladder cancer, Asian Journal of Urology (2016), <http://dx.doi.org/10.1016/j.ajur.2016.03.003>

urethral resection of bladder and “flushes” of radiotherapy haemostatic, urinary diversions and palliative cystectomy [1]. The introduction of percutaneous arterial embolisation has provided a minimally invasive and less morbid option to patients suffering from intractable hematuria in context of advanced or metastatic bladder cancer. Refinement of both techniques and instruments has enabled the development of selective embolisation of the anterior division of the internal iliac artery and superselective embolisation of the vesical artery [2,3].

We report our initial experience with managing a patient who had a metastatic bladder tumor and intractable hematuria with superselective embolisation of bilateral superior vesical arteries.

## 2. Case report

A 50-year-old man, smoker, which presented a tumor infiltrating the bladder muscle with lung and liver metastases presented with an abundant hematuria with severe anemia. The patient was treated with palliative chemotherapy based on gemcitabine. To control hematuria resection transurethral bladder and the “flush” of radiotherapy haemostatic had been made but without result. We tried to make a cystectomy but refused by the patient. So we decided to perform a selective embolisation of bladder arteries.

Retrograde catheterization of the right common femoral artery was performed under local anesthesia. Angiography revealed a vascular blush at the branches of the upper bladder arteries most important on the right side (Fig. 1).

Bilaterally and through the same puncture site right femoral was catheterized the common iliac artery, the hypogastric artery and the anterior trunk of the internal iliac artery to reach the bladder artery where we realized an injection of embospheres (BioSphere Medical Embosphere 900-1200  $\mu\text{m}$ ) realizing a bilateral superselective

embolisation superior vesical arteries. The result was satisfactory with no immediate incidents.

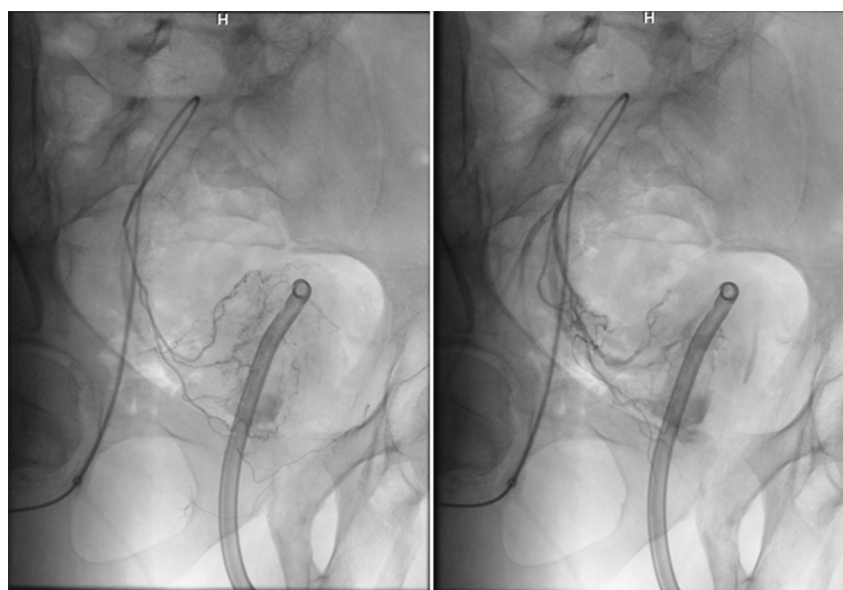
Angiography post-embolisation (Fig. 2) showed occlusion of the vesical artery and disappearance of vascular blush with the preservation of other major branches of the internal iliac artery. Hematuria stopped immediately after the procedure and the patient did not develop acute complications.

## 3. Discussion

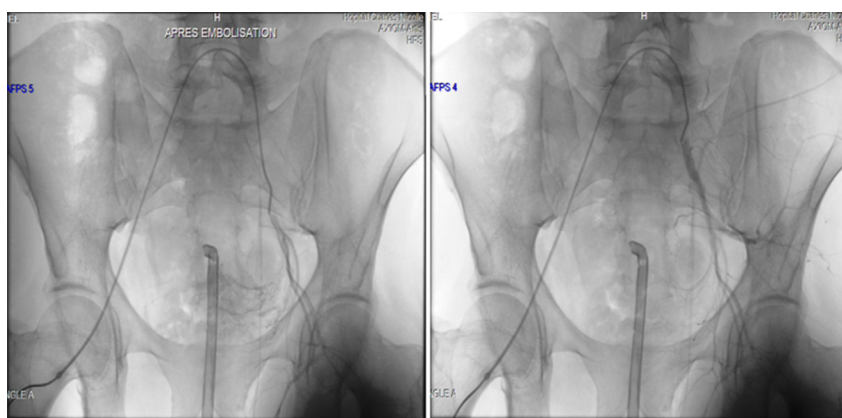
Abundant hematuria in the context of bladder cancer may have many etiologies such as tumoral mass, radiation cystitis, cyclophosphamide-induced hemorrhagic cystitis (CIHC), and also other sources of bleeding such as prostate or a tumor of the upper urinary tract associated [1]. Hematuria in our patient was rather related to the scaling of the tumor mass with the side effects of treatment.

The most widely used methods for the treatment of hematuria due to bladder cancer are arterial embolisation, the intravesical instillation of formalin, aluminum or Carboprost (prostaglandin F2 alpha) [1], the hyperbaric oxygenation [1], hypo-fractionated radiotherapy [2], and finally urinary diversions and palliative cystectomy [1]. In our experiment we tried resection and radiotherapy goal haemostatic before proposing a palliative cystectomy refused by the patient. So we had recourse to the arterial embolisation.

The embolisation is a medical technique which is to inject selectively in a vessel an occlusive agent with the aim to stop a blood flow, to slow down this stream and/or for the devascularizing of the tissue irrigated by these vessels. It is a procedure known as mini-invasive, by opposition to the surgical techniques, because it is in general less aggressive, carried out under simple local anesthesia and requires a shorter hospital stay. The embolus produces a closure of vessels in the afferents of the tumor,



**Figure 1** Pre-embolisation pelvic angiogram showing a vascular blush at the branches of the upper bladder arteries most important on the right side (the left one is at the beginning and the right one at the end of opacification).



**Figure 2** Post-embolisation pelvic angiogram showing occlusion of the vesical artery and disappearance of vascular blush with the preservation of other major branches of the internal iliac artery (the left one is immediately after embolisation and the right one 3 min after).

peritumoral plexus or intratumoral blood vessels [1]. It can be used for ischemia and tumor necrosis or preoperative devascularization to facilitate resection or in some cases to stop an uncontrollable hemorrhage [1].

The procedure endovascular percutaneous was first reported in 1974 by Hald and Mygind [3]. The embolisations bilateral and proximal of the iliac arteries internal (hypogastriques) have been in a prime time described but they did not allow stopping the hemorrhage of the fact of multiple collateralites and networks of alternates pelvic vascular [4]. That is why, to be effective, the arterial embolisation must be the most selective possible, bilateral and complete. Moreover, this type of embolisation may cause temporary lameness of gluteal muscles by obstruction gluteal arteries or even to the extreme a bladder necrosis [5].

Technical and instrumental progress helped the development of selective embolisation of the anterior division of the internal iliac artery and superselective embolisation of the vesical artery [6]. Kobayashi et al. [7] were the first to describe the superselective embolisation of the vesical artery in 1980. The technique is now an accepted therapeutic approach with proven efficacy for haemorrhagic cystitis [6], the radiation-induced cystitis [4], and bladder tumors [8]. The technique of superselective embolisation of bladder arteries next to its superior efficiency reduces the incidence of post-embolic ischemic events, but the possibility of this major complication should not be overlooked [6].

Contrary to embolisation of proximal arteries, the superselective approach prevents the risk of reflux of the thrombotic material and therefore extends the spectrum of materials which can be used [6].

Various materials were used: autologous clot isobutyl-2-cyanoacrylate, ethanol or occlusive elements (coils) [9–11]. The currently used materials are polyvinyl alcohol particles (PVA) or the microspheres of gelatin-tris-acryl [12]. The use of microspheres of different sizes adaptable provides a better plasticity and a better occlusion of arteries [6]. We chose the embospheres ranging from 900 to 1200  $\mu\text{m}$  size as the agent of embolisation. This size allows penetration into the target capillary bed and prevents the redevelopment of a circulation of substitution.

There are seven publications on arterial embolisation for the treatment of hematuria secondary to bladder tumor: two case studies and five case series [1]. In all studies, endovascular techniques have been used, with the exception of one in which the endovascular technique was compared to the ligation by open surgery [13]. In a case study, superselective endovascular technique was used [14].

The results of the first embolisation superselectives of vesical arteries seems to be promising and the immediate results seem to be good in these cases of potentially fatal uncontrollable bleeding [14]. The procedure is relatively safe, minimally invasive and can be repeated if necessary [15]. There is no important series on medium and long-term results [4,6].

#### 4. Conclusion

Superselective embolisation of the vesical arteries is a technique used to control a refractory hematuria with few complications. It can be considered in case of uncontrollable hematuria in patients with vesical tumor locally advanced or metastatic or inoperable patients. The long-term effectiveness of the procedure requires further investigation.

#### Conflicts of interest

The authors declare no conflict of interest.

#### References

- [1] Ghahestani SM, Shakhssalim N. Palliative treatment of intractable hematuria in context of advanced bladder cancer: a systematic review. *Urol J* 2009;6:149–56.
- [2] Gallocher O, Bachaud JM. Place de la radiothérapie dans la prise en charge palliative des patients cancéreux. *Med Pal* 2003;2:307–19 [Article in French].
- [3] Hald T, Mygind T. Control of life-threatening vesical hemorrhage by unilateral hypogastric artery muscle embolization. *J Urol* 1974;112:60–3.

- [4] Rigaud J, Hetet JF, Bouchot O. Management of radiation cystitis. *Prog Urol* 2004;14:568–72.
- [5] deVries CR, Freiha FS. Hemorrhagic cystitis: a review. *J Urol* 1990;143:1–9.
- [6] Cho CL, Lai MH, So HS, Kwok KK, Chan JC, Velayudhan V. Superselective embolisation of bilateral superior vesical arteries for management of haemorrhagic cystitis. *Hong Kong Med J* 2008;14:485–8.
- [7] Kobayashi T, Kusano S, Matsubayashi T, Uchida T. Selective embolization of the vesical artery in the management of massive bladder hemorrhage. *Radiology* 1980;136:345–8.
- [8] Hayes MC, Wilson NM, Page A, Harrison GS. Selective embolization of bladder tumours. *Br J Urol* 1996;78:311–2.
- [9] Appleton DS, Sibley GN, Doyle PT. Internal iliac artery embolisation for the control of severe bladder and prostate haemorrhage. *Br J Urol* 1988;61:45–7.
- [10] Giuliani L, Carmignani G, Belgrano E, Puppo P. Gelatin foam and isobutyl-2-cyanoacrylate in the treatment of life-threatening bladder haemorrhage by selective transcatheter embolisation of the internal iliac arteries. *Br J Urol* 1979;51:125–8.
- [11] Traxer O, Desgrandchamps F, Sebe P, Haab F, Le Duc A, Gattegno B, et al. [Hemorrhagic cystitis: etiology and treatment]. *Prog Urol* 2001;11:591–601 [Article in French].
- [12] Prasad V, Sacks BA, Kraus S, Clouse ME. Embolotherapy for lower urinary tract hemorrhage. *J Vasc Interv Radiol* 2009;20:965–70.
- [13] Granov AM, Anisimov VN, Grinval'd VA, Ryzhkov VK, Borisova NA. [Roentgenological-endovascular occlusion and ligation of internal iliac arteries in bleeding tumors of the bladder]. *Vestn Khir Im I I Grek* 1985;135:51–5 [Article in Russian].
- [14] De Berardinis E, Vicini P, Salvatori F, Sciarra A, Gentile V, Di Silverio F. Superselective embolization of bladder arteries in the treatment of intractable bladder haemorrhage. *Int J Urol* 2005;12:503–5.
- [15] Palandri F, Bonifazi F, Rossi C, Falcioni S, Arpinati M, Giannini MB, et al. Successful treatment of severe hemorrhagic cystitis with selective vesical artery embolization. *Bone Marrow Transplant*. 2005;35:529–30.