




Contents lists available at ScienceDirect

Asian Pacific Journal of Tropical Medicine

journal homepage: www.elsevier.com/locate/apjtm

Document heading

Melioidosis: a rare cause of anterior chest wall abscess

Rashidi Ahmad^{1*}, Azhar Amir Hamzah², Ahmad Kasfi Abdul Rahman³, Phee Kheng Cheah¹¹ Department of Emergency Medicine, School of Medical Sciences, USM Health Campus, Kelantan, Malaysia² Department of Surgery, School of Medical Sciences, USM Health Campus, Kelantan, Malaysia³ Infectious Unit, Department of Medicine, Hospital Kuala Terengganu, Malaysia

ARTICLE INFO

Article history:

Received 3 September 2009

Received in revised form 7 December 2009

Accepted 10 January 2010

Available online 20 March 2010

Keywords:

Melioidosis

Chest wall abscess

Diagnostic challenge

ABSTRACT

Melioidosis is an unusual tropical infectious disease caused by the gram-negative bacterium *Burkholderia pseudomallei*, which was formerly known as *Pseudomonas pseudomallei*. Melioidosis is characterized by abscess formation and it may manifest in any part of the human body, however, musculoskeletal melioidosis is uncommon and chest wall melioidosis is very rare. To determine the exact organism based solely on clinical presentation poses a great challenge to the physician. Yet, delay administration of antibiotic may be harmful. We describe a diabetic patient who had anterior chest wall melioidosis that mimics *Staphylococcus aureus* infection. A description of his presentation and management, along with a review of literature is presented.

Case report

A 53-year-old Malay male presented to the Emergency Department (ED) with a complain of enlarging right upper chest wall swelling for 4 days. Two days ago, he developed persistent high grade fever, chills and rigors. The fever partially subsided with paracetamol. No cough, shortness of breath, abdominal pain, muscular pain or urinary symptoms were presented. The patient suffered from diabetes mellitus for the past 15 years, and it was well controlled with medication. During the illness he also had frequency in micturition, polyuria and nocturia.

On general physical examination, he appeared lethargic, uncomfortable and dehydrated. His oral temperature, pulse rate, respiratory rate and blood pressure was 38.5 °C, 110 beats per minute, 20 per minute and 125/80 mmHg respectively.

Precordial examination revealed a huge immobile and fluctuant mass over the right upper chest wall measuring 8 cm × 10 cm. The mass was firm, tender and warm with ill defined margin (Figure 1), the overlying skin was erythematous. Supraclavicular, infraclavicular and axillary

lymph nodes were not palpable. Lung and abdominal examinations were normal. The patient was in sepsis secondary to anterior chest wall abscess. Stat dose of 2 g cloxacillin was given intravenously because in our opinion the most likely organism at that time was *Staphylococcus aureus*. Intravenous normal saline and insulin infusion was also commenced.

Laboratory results revealed elevated total white count (19.3×10^6 /L), hemoglobin and platelet counts were normal. Blood urea and serum electrolytes were normal. Erythrocyte sedimentation rate and random blood sugar was raised to 119 mm/hour and 25.2 mmol/L respectively. Chest radiograph showed soft tissue swelling, normal cardiac borders and clear lung fields. Samples for blood culture and sensitivity test was sent. Ultrasonography of abdomen revealed normal liver and spleen.

Incision and drainage was done under general anesthesia on the next day of admission. A large amount of pus was drained and the collected pus was sent for gram stain and culture and sensitivity tests. After necrotic tissue removal and wound dressing, the wound was packed with povidone soaked gauze. His insulin infusion and antibiotic was continued. Gram stain result was not traced till all the microbiology results were sent back 3 days later. Gram stain of pus showed gram-negative, intracellular, safety pin-like bacilli and later blood and pus culture revealed growth of *Burkholderia pseudomallei*. The organism was

*Corresponding author: Dr. Rashidi Ahmad, MD, USM, MMed (Emergency), USM, AM Mal, Department of Emergency Medicine, School of Medical Sciences, Health Campus, USM Kubang Kerian, Kelantan, Malaysia
E-mail: shidee_ahmad@yahoo.com

sensitive to ceftazidime, chloramphenicol, ciprofloxacin, cefepime, amoxicillin–clavulanate, co–trimoxazole; and resistant to amikacin, gentamicin and netilmicin.

Two gram of intravenous ceftazidime was administered immediately and followed by 2 g every 8 hours. He was on intravenous ceftazidime and had daily wound dressing with normal saline for 6 weeks. He was then continued with 100 mg oral doxycycline every 12 hour and 480 mg oral co–trimoxazole every 12 hour for 20 weeks. His condition progressed very well and later secondary suturing was done. He was counselled regarding the risk of relapse and the eradication therapy, and the importance of the life long follow up. During his one year follow up recently, he was found to be well with no relapse.

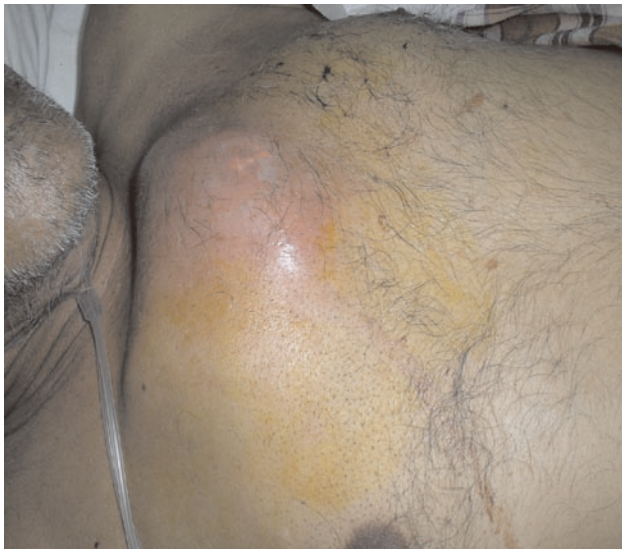

Figure 1. The above picture showing “hot abscess” over the right upper chest.

Discussion

Most of the pyogenic infections are due to aerobic bacteria such as *Staphylococcus aureus*, *Streptococcus pyogenes*, *Streptococcus pneumoniae*, *Neisseria gonorrhoeae*, *N. meningitidis*, *Bacillus coli communis*, *Bacillus typhosus* and others^[1]. *Staphylococcus aureus* is the most common organism cultured in soft tissue infections^[2] hence, starting intravenous cloxacillin empirically for this patient is justified.

To determine the exact organism based solely on clinical presentation poses a great challenge to the physician. Empirical antibiotic therapy is not an ideal solution. We may miss the responsible organism, killing normal flora and it may develop antibiotic resistance. In addition, the organism may not be sensitive to the particular antibiotic. The patient had a “hot abscess” over his anterior chest wall that mimics *Staphylococcus aureus* infection and sepsis. Presence of *Burkholderia pseudomallei* on blood and pus cultures is consistent with septic melioidosis. Delayed identification of this organism may result in fatal outcome.

Burkholderia pseudomallei is a soil saprophyte readily

recovered from wet soils in rice fields in endemic areas^[3]. It is a motile, aerobic, oxidase positive and gram–negative bacillus. Gram stain shows the characteristic bipolar staining gram–negative rods or “safety pin appearance”^[4,5]. The organism is introduced to the human body by contact of skin lesions with soil or water containing the organism or by inhalation and ingestion of infected dust or water particles. Uncommon routes of transmission include hematogenous spread, nosocomial or laboratory transmission, vertical transmission at childbirth and sexual transmission^[4–11].

Melioidosis is endemic in tropical countries in Southeast Asia (Malaysia, Thailand, and Singapore) and Northern Australia. The average annual incidence of melioidosis in Malaysia (State of Pahang), Singapore, Northeastern Thailand and Northern Territory of Australia was 6.0, 1.7, 4.4 and 16.5 per 100,000 populations respectively^[12–15].

The clinical manifestations of melioidosis range from the totally asymptomatic patient to the patient presenting to the ED in septic shock^[16–18]. Other presentations include pneumonia, lung abscess, lung masses and empyema chronic otitis media, mycotic aneurysms, brain–stem encephalitis and flaccid paraparesis ^[12,19–21]. Localized melioidosis usually occurs in the form of acute suppurative lesions or superficial and deep–seated abscess^[16].

Chest wall melioidosis is a rare presentation, though the disease can manifest over any part of the human body. It is important for the physician to consider this disease as one of the differential diagnosis of anterior chest wall abscess, especially in those who live in an endemic area of melioidosis, in Asian migrants, or in those with a history of travel to the endemic regions^[17]. Presence of risk factors such as diabetes mellitus, renal failure, cirrhosis, thalassemia, chronic lung disease, hematological malignancies, collagen vascular disease and immunodeficient by drugs (steroids) makes the diagnosis more likely ^[3]. Patient with poorly controlled diabetes mellitus has higher risk to suffer from melioidosis^[18].

Melioidosis is a significant cause of morbidity and mortality. The morbidity and mortality are related to community acquired septicemia and community acquired pneumonia. Epidemiology study on melioidosis in northeast Thailand revealed the incidence of community acquired septicemia and pneumonia to be 27% and 36% respectively^[15]. In Malaysia the reported mortality rate is up to 53.5%. Majority of them succumbed to the illness due to severe pneumonia and multi–organ failure and they died within 72 hours of hospital admission^[13,19]. The reported mortality rate in Northern Australia, Thailand and Singapore is 19%, 44% and 46% respectively^[12,15,20]. In endemic areas of melioidosis like Northern Thailand, whereby majorities are seropositive, the mortality rate was noted higher in the septicemic group (36.3%) than the non–septicemic group (16.5%)^[15].

Early diagnosis of melioidosis leads to early appropriate and sensitive antibiotic administration. Isolation and identification of the organism from various clinical specimens along with its sensitivity to various types of antibiotics is vital to confirm the presence of bacterium and to eradicate them completely. Since the culture and

sensitivity results may only be available after 3 to 7 days, immunologic (Indirect hemagglutination and enzyme linked immunosorbent assay) and molecular (Polymerase chain reaction) tests are now available to diagnose and exclude melioidosis rapidly. Unfortunately, its low specificity makes the tests unsuitable in endemic areas where most of the population is seropositive^[15,21].

The main objective of melioidosis treatment is to reduce mortality and morbidity and to prevent relapse. Therefore, the mainstay of treatment for this patient is operative drainage and intravenous antibiotics, i.e. intensive and eradication therapy. Even if the proper antibiotics are given, the clinical improvement is usually slow. The median time for the resolution of fever is nine days but patients with large abscess may have fluctuating fevers for more than 1 month. Enlargement of abscesses or appearance of new abscesses is not uncommon in the first week of treatment and is not necessarily a sign of treatment failure^[3].

Relapse can occur in melioidosis. A long course of oral eradication therapy is required to prevent relapse^[12,22]. The treatment may be continued over 12–20 weeks or longer if clinically indicated. In our case, the patient received only a single intravenous antibiotic (ceftazidime) for 6 weeks because we believed an addition of co-trimoxazole during the intensive course of antibiotic therapy does not confer any additional benefit in mortality^[23]. Combination of oral doxycycline and co-trimoxazole is a common eradication antibiotic in our practice.

In conclusion, though chest wall melioidosis is very rare, a high index of suspicion is needed particularly in patients who live in the endemic areas, or patients with predisposing factors, as diagnosis can only be established by bacteriological and immunological studies. Melioidosis has been known to be 'the great mimicker' and posed great challenge to the physician to identify the correct organism clinically.

Conflict of interest statement

We declare that we have no conflict of interest.

References

- [1]Set R, Sequeira L, Angadi SA, Koppikar GV. Prevalence of anaerobic bacteria in pyogenic infections. *Indian Journal of Medical Microbiology* 1997; **15**(3): 121–2.
- [2]Paydar KZ, Hansen SL, Charlebois ED, Harris HW, Young DM. Inappropriate antibiotic use in soft tissue infections. *Arch Surg* 2006; **141**: 850–6.
- [3]White NJ. Melioidosis. *Lancet* 2003; **361**: 1715–22.
- [4]Dance DA. Melioidosis: the tip of the iceberg? *Clin Microbiol Rev* 1991; **4**: 52–60.
- [5]Raja NS, Ahmed MZ, Singh NN. Melioidosis: an emerging infectious disease. *J Postgrad Med* 2005; **51**: 140–5.
- [6]Whitmore A, Krishnaswami CS. An account of a hitherto undescribed infective disease occurring among the population of Rangoon. *Indian Med Gaz* 1912; **47**: 262–7.
- [7]Whitmore A. An account of a glandres-like-disease occurring in Rangoon. *J Hyg* 1913; **13**: 1–34.
- [8]Green RN. Laboratory acquired melioidosis. *Am J Med* 1968; **44**: 599–605.
- [9]Lumbiganon P, Pengsaa K, Puapermpoonsiri S, Puapairoj A. Neonatal melioidosis: a report of 5 cases. *Pediatr Infect Dis J* 1988; **7**: 634–6.
- [10]Halder D, Abdullah WA, Johari MR, Choo KE. Neonatal melioidosis. *Singapore Med J* 1993; **34**: 85–6.
- [11]Abbink FC, Orendi JM, de Beaufort AJ. Mother-to-child transmission of *Burkholderia pseudomallei*. *N Engl J Med* 2001; **344**: 1171–2.
- [12]Currie BJ, Fisher DA, Anstey NM. Melioidosis: acute and chronic disease, relapse and reactivation. *Trans R Soc Trop Med Hyg* 2000; **94**: 301–4.
- [13]How SH, Ng KH, Jamalludin AR, Shah A, Rathor Y. Melioidosis in Pahang, Malaysia. *Med J Malaysia* 2005; **60**: 606–13.
- [14]Chan KW, Jayaratna FY. Acute septicemia melioidosis: A report of three fatal cases. *Singapore Medical Journal* 1985; **26**: 382–5.
- [15]Suputtamongkol Y, Hall AJ, Dance Da, Chaowagul W, Rajchanuvong A, Smith MD, et al. The epidemiology of melioidosis in Ubon Ratchatani northeast Thailand. *Int J Epidemiol* 1994; **23**: 1082–90.
- [16]Zulkiflee AB, Prepageram N, Philip R. Melioidosis: an uncommon cause of neck abscess. *American Journal of Otolaryngology* 2008; **29**: 72–4.
- [17]Currie BJ, Fisher DA, Howard DM, Burrow JN, Selvanayagam S, Snelling PL, et al. Endemic melioidosis in tropical northern Australia: a 10-year prospective study and review of the literature. *Clin Infect Dis* 2000; **31**: 981–6.
- [18]Puthucheary SD. Septicemic melioidosis: A review of 50 cases from Malaysia. *Trans R Soc Trop Med Hyg* 1992; **86**: 683–5.
- [19]Pagavalan L. Melioidosis: The Johor Bharu experience. *Med J Malaysia* 2005; **60**: 606–13
- [20]Singapore Committee on Epidemic Disease. Melioidosis in Singapore. *Epidemiological News Bulletin*. 1995; **21**: 69–72.
- [21]Inglis TJJ, Rolim DB, Rodriguez JLN. Clinical guideline for diagnosis and management of melioidosis. *Rev Inst Med Trop* 2006; **48**(1): 1–4.
- [22]Rajchanuvong A, Chaowagul W. A prospective comparison of co-amoxiclav and the combination of the chloramphenicol, doxycycline and cotrimoxazole for the oral maintenance treatment of melioidosis. *Trans R Soc Trop Med Hyg* 1995; **89**: 546–9.
- [23]Chierakul W, Anunnatsiri S, Short JM, Maharjan B, Mootsikapun P, Simpson AJ, et al. Two randomized controlled trials of ceftazidime alone versus ceftazidime in combination with trimethoprim-sulfamethoxazole for the treatment of severe melioidosis. *Clin Infect Dis* 2005; **41**: 1105–13.