

## CASE REPORT

# Prenatal Diagnosis of Dextrotransposition of the Great Arteries

Jeng-Hsiu Hung<sup>1,5\*</sup>, Pi-Tao Huang<sup>2,5</sup>, Zen-Chung Weng<sup>3,5</sup>, Chih-Yao Chen<sup>4,5</sup>,  
Kuan-Chong Chao<sup>4,5</sup>, Ming-Jie Yang<sup>4,5</sup>, Jamie Hung<sup>4,5</sup>

<sup>1</sup>Department of Obstetrics and Gynecology, Buddhist Tzu Chi General Hospital, Taipei Branch, Departments of  
<sup>2</sup>Pediatrics, <sup>3</sup>Surgery, and <sup>4</sup>Obstetrics and Gynecology, Taipei Veterans General Hospital, and  
<sup>5</sup>National Yang-Ming University School of Medicine, Taipei, Taiwan, R.O.C.

Dextrotransposition of the great arteries (DTGA) is a common cardiac cause of cyanosis in newborn infants that can cause acidosis and death within a short period of time unless there is a large atrial-level shunt or a patent ductus arteriosus. Here, we report a case of prenatal diagnosis of DTGA at 24<sup>+1</sup> gestational weeks. In a tilted 4-chamber view, the pulmonary trunk branched to the left and the right pulmonary, with its root connected to the left ventricle outflow tract. In the short-axis view, the pulmonary trunk was shown to be parallel with the ascending aortic root. Cesarean section was performed due to the nonreassuring fetal status at 38<sup>+5</sup> gestational weeks. The male neonate appeared to have mild cyanotic symptoms and weighed 3,108 g. Apgar scores were 8 and 9 at 1 and 5 minutes, respectively. Neonatal echocardiography was performed immediately after birth and the findings confirmed DTGA associated with atrial septal defect secundum. Postnatally, angiography confirmed the echocardiographic diagnosis of DTGA with a large atrial septal defect secundum and a large patent ductus arteriosus. Jatene arterial switch operation and atrial septal defect closure with Gore-Tex patch were performed. The neonate withstood the operation well and was discharged 27 days after birth weighing 2,950 g and in a stable condition. Prenatal diagnosis of DTGA can greatly aid to prepare the patient's family and the surgeon and significantly improve the outcome of complex heart disease in the neonatal period. [*J Chin Med Assoc* 2008;71(10):541–545]

**Key Words:** arterial switch operation, dextrotransposition of the great arteries, prenatal diagnosis

## Introduction

Dextrotransposition of the great arteries (DTGA) is defined as a ventriculoarterial discordance and results from spiraling failure of the primitive truncus arteriosus.<sup>1</sup> The aorta arises from the morphologic right ventricle and the pulmonary artery arises from the morphologic left ventricle in the setting of d-loop ventricles.<sup>2,3</sup> Thus, the pulmonary and systemic circulatory systems function in parallel. Systemic venous blood flows to the aorta while pulmonary venous blood flows to the pulmonary artery. In children, this anomaly accounts for 10% of all cyanotic congenital cardiac defects, with a predominance in boys over girls at ratios between 2:1 and 3:1.<sup>4,5</sup> Here, we report a case of prenatal diagnosis of DTGA. Echocardiography of the fetus included comprehensive segmental analysis of the great arteries,

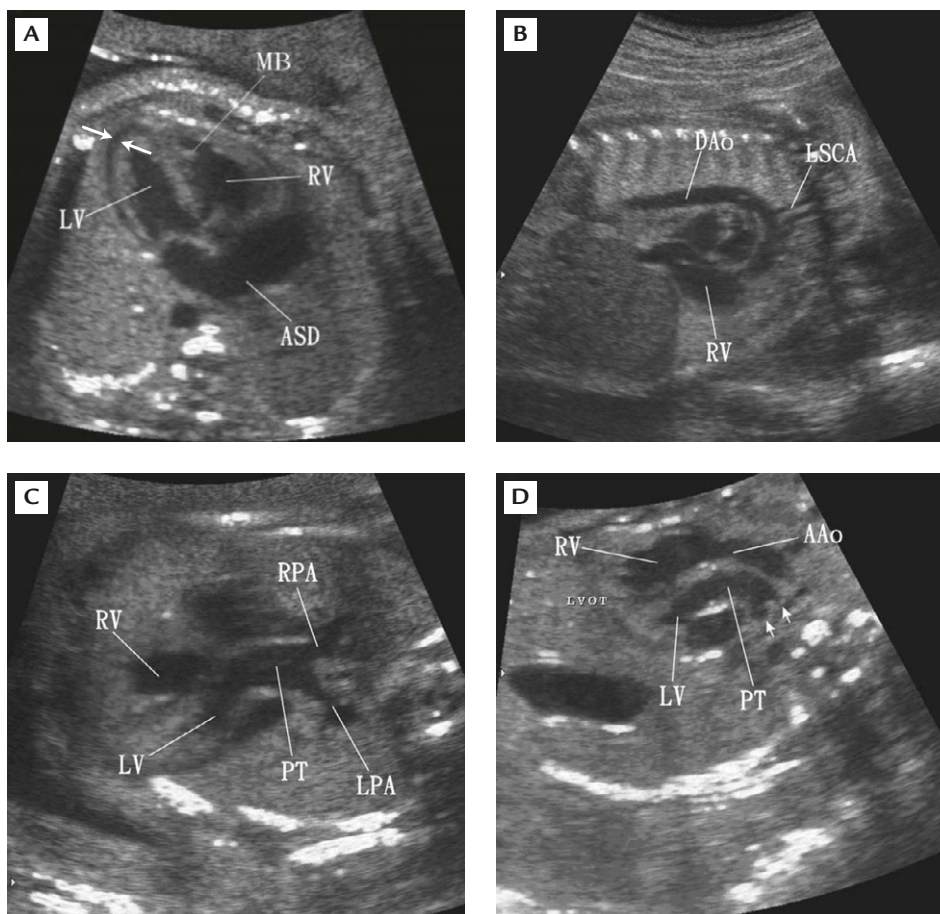
conal anatomy and assessment of the ventricular septum. Other potential sources of mixing of the circulations, including atrial septal defect and patent ductus arteriosus, were also evaluated to determine the feasibility of surgical repair.

## Case Report

A 31-year-old gravida, G2P0A1, was referred to our fetal diagnosis unit at 24<sup>+1</sup> gestational weeks because of suspected fetal cardiac anomalies. She had no known systemic disease. Initial findings included symmetrically dilated fetal heart with pericardial effusion, which was 3.0 mm in width at the left cardiac apex. Fetal echocardiograms including standard 4-chamber view, 2-chamber view, right ventricular outflow tract, left



\*Correspondence to: Dr Jeng-Hsiu Hung, Department of Obstetrics and Gynecology, Buddhist Tzu Chi General Hospital, Taipei Branch, 289, Jianguo Road, Xindian City, Taipei 231, Taiwan, R.O.C.  
E-mail: jhung@tzuchi.com.tw • Received: September 10, 2007 • Accepted: May 26, 2008



**Figure 1.** (A) Two-dimensional echocardiography of the fetal heart shows a large atrial septal defect secundum on 4-chamber view. Pericardial effusion (arrows) measuring 3 mm was seen at the left apex. (B) Sagittal view of the fetal heart demonstrates an aortic arch connecting to the right ventricular outflow tract, and the left subclavian artery arising from the aortic arch connecting to the right ventricular flow tract. (C) Tilted 4-chamber view shows the pulmonary trunk branched to the left and the right pulmonary, with its root connected to the left ventricle outflow tract. (D) Short axis view shows the pulmonary trunk to be parallel with the ascending aortic root (arrows represent both pulmonary arteries). LV = left ventricle; RV = right ventricle; MB = moderator band; ASD = atrial septal defect; DAo = descending aorta; LSCA = left subclavian artery; PT = pulmonary trunk; RPA = right pulmonary artery; LPA = left pulmonary artery; AAo = ascending aorta.

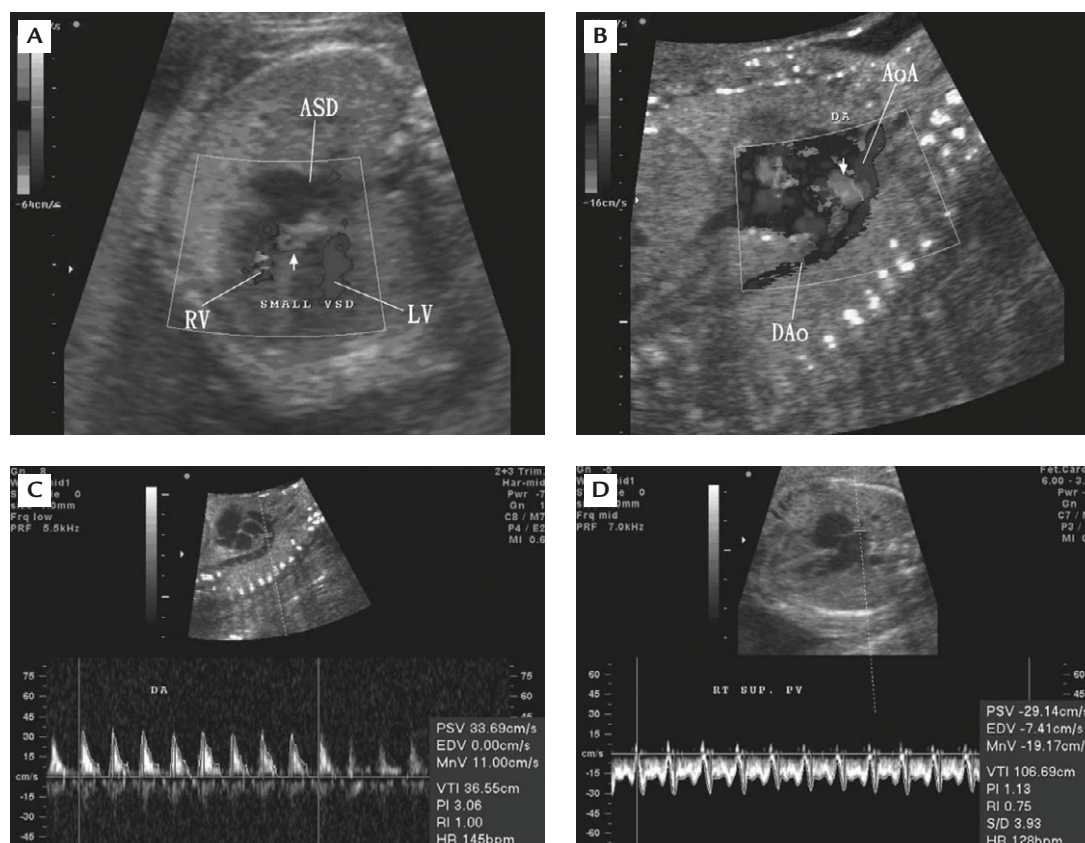
ventricular outflow tract, and short-axis and aortic arch views; their respective pulse-wave Doppler flow recordings were performed with a 2.0- to 5.0-MHz convex probe. A Voluson 730 (Kretztechnik AG, Tiefenbach, Austria) ultrasound apparatus was used for the Doppler studies.

Two-dimensional echocardiography showed a large atrial septal defect in the 4-chamber view (Figure 1A). The sagittal view of the fetal heart demonstrated an aortic arch connected to the right ventricular outflow tract (Figure 1B), showing the left subclavian artery arising from the aortic arch connecting to the right ventricular flow tract. In a tilted 4-chamber view, the pulmonary trunk branched to the left and the right pulmonary, with its root connecting to the left ventricle outflow tract (Figure 1C). In the short-axis view, the pulmonary trunk was shown to be parallel with the

ascending aortic root (Figure 1D). Moderate pericardial effusion over ventricular regions was also noted.

On Doppler color flow mapping, the 4-chamber view of the fetal heart suggested a small ventricular septal defect measuring 2 mm in size (Figure 2A) that had not been observed 1 week before. In aortic arch view, the ductus arteriosus was seen to be connected to the descending aorta (Figure 2B). The flow direction of the ductus arteriosus was reversed (Figure 2C). The Doppler flow of the right superior pulmonary vein was recorded in the left atrium in the 4-chamber view (Figure 2D).

Other than the fetal cardiac anomalies described, fetal karyotype was 46,XY. Prenatal monitoring revealed preterm labor with cervical length of 25 mm, which was treated with magnesium sulfate via intravenous continuous drip. Fetal cardiac failure was demonstrated

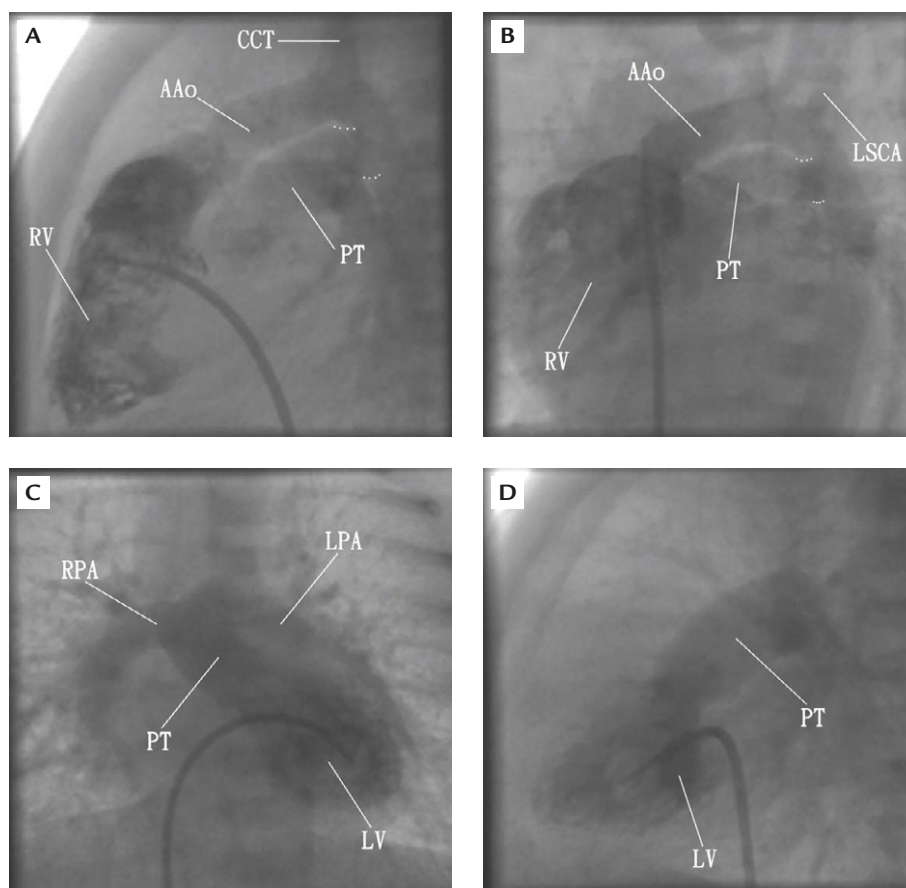


**Figure 2.** Color and Doppler flow mapping of the fetus with dextrotransposition of the great arteries at 24<sup>+1</sup> gestational weeks. (A) On color flow mapping, the 4-chamber view of the fetal heart shows a small ventricular septal defect (arrow). (B) On aortic arch view, the ductus arteriosus (arrow) with reversed flow direction was connected to the descending aorta. (C) The flow direction of the ductus arteriosus was reversed, with a peak velocity of 33.69 cm/sec. (D) The Doppler flow velocity of the right superior pulmonary vein, with a reversed “a” wave velocity of 7.41 cm/sec, was recorded in the left atrium. RV = right ventricle; LV = left ventricle; ASD = atrial septal defect; Dao = descending aorta; AoA = aortic arch.

with pericardial effusion, increased cardiac size, and marked tricuspid regurgitation which was recorded when the sampling site was placed in the tricuspid valve during color Doppler interrogation. The “a” wave of ductus venosus was reversed in the direction of the blood flow in this fetus. A reversed “a” wave of the ductus venosus flow velocity represented the marked increase of preload in the fetal heart.<sup>6</sup> The fetal heart failure had been treated with 0.25 mg/day of oral digoxin to the mother since 24<sup>+2</sup> gestational weeks. The sign of pericardial effusion gradually disappeared 2 weeks later. Labor pain began spontaneously at 38<sup>+5</sup> gestational weeks and fetal bradycardia with fetal heart rate of 110–130 beats/min variability was recorded. The nonreassuring fetal status (NRFS) was documented by fetal bradycardia and loss of beat-to-beat variability to 2 beats/min on fetal heart monitoring. The biophysical profile score was 6, and the amniotic fluid index was 130 mm. Cesarean section was performed due to NRFS. The male neonate appeared to have mild cyanotic symptoms and weighed 3,108 g. Apgar scores

were 8 and 9 at 1 and 5 minutes, respectively. Neonatal echocardiography was performed immediately after birth, and the findings confirmed DTGA associated with atrial septal defect secundum. The patient had oxygen desaturation of 73% and was admitted to the neonatal intensive care unit for further evaluation and management. He received prostaglandin E1 to maintain the dilated ductus arteriosus. On the 3<sup>rd</sup> postnatal day, cardiac catheterization was done for presurgical evaluation.

Lateral view of the right ventriculogram showed the right infundibulum portion of the right ventricle connecting to the aortic arch (Figure 3A), while a lateral view of the aortogram showed the tip of the catheter placed at the aortic root and the dilated ductal arteriosus connected to the pulmonary trunk (Figure 3B). The aortic arch was also noted to be running parallel to the pulmonary trunk. Anterior-posterior and lateral views of the left ventriculogram showed the catheter placed in the left ventricle and the bilateral pulmonary arteries connecting to the pulmonary trunk, which was



**Figure 3.** Angiography of the neonate. (A) Lateral view of the right ventriculogram shows the right infundibulum of the right ventricle connected to the aortic arch. The dotted lines represent the dilated ductus arteriosus. (B) Lateral view of the aortogram shows the tip of the catheter placed at the aortic root and the dilated ductal arteriosus (dotted lines) connected to the pulmonary trunk. (C) Anteroposterior view and (D) lateral view of the left ventriculogram show the catheter placed in the left ventricle and the bilateral pulmonary arteries connecting to the pulmonary trunk, which was arising from the left ventricular outflow tract. CCT = common cephalic trunk; AAo = ascending aorta; RV = right ventricle; PT = pulmonary trunk; LSCA = left subclavian artery; RPA = right pulmonary artery; LPA = left pulmonary artery; LV = left ventricle.

arising from the left ventricular outflow tract (Figures 3C and D).

Angiography confirmed the echocardiographic diagnosis of DTGA atrial septal defect secundum and patent ductus arteriosus. Neonatal arterial switch operation (ASO) and atrial septal defect repair with Gore-Tex patch were performed on the 4<sup>th</sup> postnatal day. The neonate tolerated the operation well and was discharged 27 days after birth in a stable condition, weighing 2,950 g, with daily milk intake of 50–55 mL q3h.

## Discussion

DTGA is a common cardiac cause of cyanosis in newborn infants that can cause acidosis and death within a short period of time unless there is a large atrial-level shunt or a patent ductus arteriosus. Even with

a large ventricular septal defect, there is not enough mixing to keep the infant well oxygenated. Thus, a large atrial septal defect is an absolute necessity for these infants. Without any intervention, most of them will die within the first year of life. Currently, the most common intervention involves the use of prostaglandin E1 infusion, which inhibits the natural closure of the ductus arteriosus and may actually cause its dilatation. Thus, the prenatal diagnosis of DTGA represents early preparation for stabilization and improving the neonatal outcome of this complex congenital heart disease.

There are 2 types of TGA: DTGA and LTGA. DTGA is known as “complete” TGA; the “D” stands for dextroposition. The “L” in LTGA stands for levotransposition. In DTGA, the aorta and the pulmonary artery have switched places, leaving the child very cyanotic. In LTGA, the aorta and pulmonary artery are in the right place but the ventricles have switched

places. The differential diagnoses of LTGA include ventricular septal defects, valvular or subvalvular pulmonary stenosis, and tricuspid valve incompetence. With a ventricular defect, the pulmonary artery often overrides the ventricular septal defect and may arise from the ventricle with right ventricular morphologic features. This results in a double-outlet right ventricle.

In the past, the most common form of palliation for dextrotransposition was an intra-atrial baffle (also known as a Mustard, Senning, or atrial switch) procedure. A baffle connects the vena cavae to the mitral valve (and hence the pulmonary circuit) by diverting blood flow across the atrial septum while simultaneously allowing pulmonary venous blood to be routed over the baffle to the tricuspid valve (and on to the systemic circuit). Reoperation is performed in approximately 20% of patients for baffle-related complications, progressive left ventricular outflow tract stenosis, or tricuspid insufficiency.<sup>7</sup> The incidence of sudden cardiac death varies from 2–3% to as high as 16%.<sup>8</sup> The etiology of sudden death is poorly understood but it is likely to be multifactorial and related to poor right-ventricular hemodynamics in combination with bradyarrhythmias and supraventricular tachyarrhythmias.<sup>7</sup>

The other procedure is the ASO, which involves surgically transposing the aorta and pulmonary artery trunks and reimplantation of the coronary arteries.<sup>8</sup> The ASO is now accepted as the treatment of choice for surgical correction of hearts with DTGA.<sup>9</sup> The overall mortality is now low, but the branching patterns of the coronary arteries are known to be variable and to influence outcome. Some patterns have been associated with mortality of up to 30%.<sup>9</sup> Because of variations in coronary anatomy associated with DTGA and the need to transfer the coronary arteries during ASO, much attention has been paid to the relationship between the coronary anatomy pattern and outcome.<sup>9</sup> Patients with unusual coronary anatomy, particularly single and intramural coronaries, have a significantly higher mortality than those with a more normal pattern.<sup>10</sup> Therefore, it is important for the cardiac surgeon to have an excellent knowledge of the variations, patterns of the variations, and patterns of coronary artery anatomy in DTGA before ASO.<sup>11</sup>

Fortunately, in our case, the coronary artery pattern was 1 L 2 RCx (i.e. left anterior descending coronary artery from sinus 1 and right coronary artery and left circumflex coronary artery from sinus 2, according to

the Leiden classification), and there was no technical difficulty in coronary reimplantation during ASO. Therefore, the patient was discharged uneventfully 2 weeks after undergoing ASO.

## Acknowledgments

This study was supported by research grants (NSC 94-2314-B-075-014 and V96C1-159) from the National Science Council and Taipei Veterans General Hospital, Taiwan, R.O.C.

## References

1. Van Praagh R, Perez-Trevino C, Lopez-Cuellar M, Baker FW, Zuberbuhler JR, Quero M, Perez VM, et al. Transposition of the great arteries with posterior aorta, anterior pulmonary artery, subpulmonary conus and fibrous continuity between aortic and atrioventricular valves. *Am J Cardiol* 1971;28:621–31.
2. Van Praagh R. Transposition of the great arteries: history, pathologic anatomy, embryology, etiology, and surgical considerations. *Cardiac Surg: State Art Rev* 1991;5:7–82.
3. Hwang B, Ng HT, Yang ZL, Hsieh KS, Meng CC. Prenatal diagnosis of congenital heart disease and arrhythmias. *J Chin Med Assoc* 1988;41:7–12.
4. Fisher E, Paul MH. Transposition of the great arteries: recognition and management. *Cardiovasc Clin* 1970;2:211–30.
5. Yuan SM, Zhang LS, Xu QZ, Guo JQ. Echocardiography of the right ventricle-to-pulmonary artery homograft conduit of patients with transposition of the great arteries or double outlet right ventricle undergoing the Rastelli procedure. *J Chin Med Assoc* 1997;59:359–66.
6. Hung JH, Fu CY, Lu JH, Hung CYS. Ductus venosus blood flow resistance and congenital heart defects in the second trimester of pregnancy. *J Clin Ultrasound* 2008;36:72–8.
7. Marelli AJ, Moodie DS. Adult congenital heart disease. In: Topol EJ. *Comprehensive Cardiovascular Medicine*. Philadelphia: Lippincott-Raven, 1998:879–906.
8. Martin RP, Qureshi SA, Ettetdgui JA, Baker EJ, O'rien BJ, Deverall PB, Yates AK, et al. An evaluation of right and left ventricular function after anatomical correction and intra-atrial repair operations for complete transposition of the great arteries. *Circulation* 1990;82:808.
9. Scheule AM, Zurakowski D, Blume ED, Stamm C, del Nido PJ, Mayer JE Jr, Jonas RA. Arterial switch operation with a single coronary artery. *J Thorac Cardiovasc Surg* 2002;123:1164–72.
10. Pasquali SK, Hasselblad V, Li JS, Kong DF, Sanders SP. Coronary artery pattern and outcome of arterial switch operation for transposition of the great arteries: a meta-analysis. *Circulation* 2002;106:2575–80.
11. Baslaim GM. Is preoperative delineation of coronary artery pattern a prerequisite for arterial switch operation? *J Cardiol Surg* 2006;21:465–70.