



Available online at

ScienceDirect
www.sciencedirect.com

Elsevier Masson France

EM|consulte
www.em-consulte.com/en

Orthopaedics
& Traumatology
Surgery & Research

ORIGINAL ARTICLE

Influence of glenoid component design and humeral component retroversion on internal and external rotation in reverse shoulder arthroplasty: A cadaver study



J. Berhouet*, P. Garaud, L. Favard

Université François-Rabelais de Tours, Faculté de Médecine de Tours, CHRU Trousseau, Service d'orthopédie traumatologie 2A, 1C, avenue de la République, 37170 Chambray-les-Tours, France

Accepted: 21 August 2013

KEYWORDS

Reverse shoulder prosthesis;
Glenoid component combinations;
Humeral component retroversion;
Rotations

Summary

Background: A common disadvantage of reverse shoulder arthroplasty is limitation of the range of arm rotation. Several changes to the prosthesis design and implantation technique have been suggested to improve rotation range of motion (ROM).

Hypothesis: Glenoid component design and degree of humeral component retroversion influence rotation ROM after reverse shoulder arthroplasty.

Material and methods: The Aequalis Reversed™ shoulder prosthesis (Tornier Inc., Edina, MN, USA) was implanted into 40 cadaver shoulders. Eight glenoid component combinations were tested, five with the 36-mm sphere (centred seating, eccentric seating, inferior tilt, centred with a 5-mm thick lateralised spacer, and centred with a 7-mm thick lateralised spacer) and three with the 42-mm sphere (centred with no spacer or with a 7-mm or 10-mm spacer). Humeral component position was evaluated with 0°, 10°, 20°, 30°, and 40° of retroversion. External and internal rotation ROMs to posterior and anterior impingement on the scapular neck were measured with the arm in 20° of abduction.

Results: The large glenosphere (42 mm) was associated with significantly ($P < 0.05$) greater rotation ROMs, particularly when combined with a lateralised spacer (46° internal and 66° external rotation). Rotation ROMs were smallest with the 36-mm sphere. Greater humeral component retroversion was associated with a decrease in internal rotation and a significant increase ($P < 0.05$) in external rotation. The best balance between rotation ROMs was obtained with the native retroversion, which was estimated at 17.5° on average in this study.

* Corresponding author. Tel.: +33 02 47 47 47 47; fax: +33 02 47 47 59 12.
E-mail address: julien.berhouet@gmail.com (J. Berhouet).

Discussion: Our anatomic study in a large number of cadavers involved a detailed and reproducible experimental protocol. However, we did not evaluate the variability in scapular anatomy. Earlier studies of the influence of technical parameters did not take humeral component retroversion into account. In addition, no previous studies assessed rotation ROMs.

Conclusion: Rotation ROM should be improved by the use of a large-diameter glenosphere with a spacer to lateralise the centre of rotation of the gleno-humeral joint, as well as by positioning the humeral component at the patient's native retroversion value.

Level of evidence: Basic Science Study III.

© 2013 Elsevier Masson SAS. All rights reserved.

Introduction

Reverse shoulder arthroplasty (RSA) is now a firmly established treatment method for older patients with eccentric gleno-humeral osteoarthritis [1,2]. The effectiveness of RSA is ascribable to two major changes in shoulder morphology: a large-diameter metallic hemisphere with no neck is implanted into the glenoid cavity, and a polyethylene socket covering less than half of the glenosphere and having a non-anatomic neck-shaft angle is used to replace the humeral head [3,4]. The biomechanical effect of this unique design consists of medialisation and distalisation of the humerus, which improves deltoid performance. The functional effects include improved joint stability and decreased shear forces on the glenoid component. Potential disadvantages of these morphological changes are a decrease in rotation range of motion (ROM) with the elbow by the side [4–6] and scapular notching [7].

Loss of arm rotation with the elbow by the side was evaluated by Boileau et al. [2]. After a mean follow-up of 53 months, internal rotation improved by only two vertebral levels and external rotation by only 4°. Factors responsible for loss of rotation may include the small lateral glenosphere offset and the medialisation of the humerus [4], which result in impingement of the humerus on the anterior or posterior part of the glenoid cavity, with the development of scapular notching. Thus, the changes suggested to prevent scapular notching also improve the range of rotation with the elbow by the side. Decreased medialisation of the centre of rotation was associated with a 36° increase in external rotation with the elbow by the side after 33 months [8]. In two studies, lateralisation of the centre of rotation by 8.5 mm improved external rotation by 15° after a mean follow-up of 36 months [9,10]. Lateralisation achieved by bone graft implantation between the glenoid surface and baseplate (Bony Increased Offset-Reverse Shoulder Arthroplasty, BIO-RSA) [4,11] improved external rotation by 10° and internal rotation by 1.4 points on the Constant score [12] after a follow-up of 28 months. Grammont in his seminal work then Walch et al. [2] reported that less humeral component retroversion was associated with better outcomes. However, to the best of our knowledge no other studies of the impact of humeral retroversion on rotation ROM have been reported.

Given these persistent uncertainties, we assessed the influence of various glenoid component combinations and degrees of humeral retroversion on rotation ROM after RSA.

Materials and methods: shoulders and implants

We conducted a study in 40 cadaver shoulders, 20 from left and 20 from right upper limbs. Mean age at death was 79.1 years (range, 61–95 years). There were 21 men and 19 women. Each specimen included the shoulder girdle with the clavicle and the entire upper limb including the forearm and hand.

We used the Aequalis Reversed™ prosthesis (Tornier Inc., Edina, MN, USA). The specific instruments were used as recommended by the manufacturer. For all 40 shoulders, we used the same humeral component design, with a 36-mm metaphysis screwed into a diaphyseal stem measuring 6.5 mm in diameter and 150 mm in length and screwed into an intra-medullary nail measuring 3.5 mm in diameter and 250 mm in length. The distal end of the nail exited through the distal humeral metaphysis and olecranon and secured the humerus to the measurement device. We implanted a removable humeral insert measuring 36 mm in diameter and having 6 mm of lateral offset. Insert concavity (36 mm or 42 mm) was selected according to the diameter of the glenosphere.

A 29-mm glenoid baseplate was implanted, with the following glenospheres and lateralised spacers:

- 36-mm centred glenosphere;
- 36-mm glenosphere positioned off centre by 2 mm;
- 36-mm glenosphere with 10° tilt;
- 42-mm centred glenosphere;
- 36-mm centred glenosphere with 5 mm lateralisation;
- 36-mm centred glenosphere with 7 mm lateralisation;
- 42-mm centred glenosphere with 7 mm lateralisation;
- 42-mm centred glenosphere with 10 mm lateralisation.

Measurement device

A modular metallic holder was devised (Sawbones, Malmö, Sweden). A vise was clamped onto the scapula and an articulated arm held the remainder of the upper limb, to which it was secured by the intra-medullary nail screwed onto the humeral prosthetic component. The device allowed the reproduction of shoulder movements in all planes and was equipped with protractors to record motion ranges. The goal of the assembly was to allow variations in humeral elevation while enabling the measurement of rotation ROMs.

Experimental method

The anatomic specimen was removed from the cadaver and the scapula was clamped into the vise of the measurement device. The deltoid muscle was detached from the clavicle and acromion down to the deltoid 'V' to expose the plane of the rotator cuff. The supra-spinatus and infra-spinatus muscles were removed. To enable a reliable assessment of anterior impingements, the sub-scapularis was detached from the lesser tuberosity. The teres minor was preserved. A vertical incision of the gleno-humeral joint was performed and the capsule was resected together with the long head of the biceps tendon. The glenoid cavity rim and upper portion of the scapular pillar were carefully exposed, if needed by detaching the long head of the triceps. Full exposure of the anterior, inferior, and posterior rim of the glenoid cavity was achieved to allow an assessment of impingements during the measurements.

For implantation of the glenoid baseplate, the glenoid cavity was prepared by successively removing the glenoid labrum; inserting a threaded drill guide perpendicular to the glenoid surface to ensure centring, in compliance with the 12-mm rule [13]; powered reaming of the glenoid to 29 mm in diameter; and manual reaming to 36 or 42 mm in diameter. The 29-mm glenoid baseplate was then impacted into the glenoid. An additional screw was inserted if needed to achieve firm baseplate fixation.

Preparation of the humerus started with resection of the humeral head using a cutting guide, after identification of the reamer entry site along the extended diaphyseal axis. The cutting guide allowed humeral head resection according to the native retroversion measured with reference to the forearm axis. Reaming of the diaphysis followed by preparation of the metaphysis with a 36-mm burr and finally by reaming of the metaphysis and epiphysis were then

performed manually. A drill bit was inserted into the medullary cavity and made to exit the olecranon with the elbow in 90° of flexion. This last step prepared the implantation of the humeral component secured to a threaded intra-medullary nail, whose tip was screwed onto a protractor to enable measurement of rotation ROMs. The humeral component implanted with the native retroversion was then secured to the articulated arm of the metallic holder. At the level of the metaphysis, a small anti-rotation pin served to block the retroversion of the humeral component. A lateralised 36-mm humeral insert was implanted (Fig. 1).

Baseplate adjustment

Baseplate adjustment was required before the measurements could be started. A guide system comprising a spirit level and a pointer was centred on the implanted baseplate. This system served to adjust the position of the baseplate relative to the metallic holder equipped with the measurement instruments. Adjustments were made in all three planes to ensure co-axiality of the centres of rotation of the gleno-humeral joint and articulated holder. The glenosphere was screwed into the baseplate when the glenoid was properly aligned (Fig. 2). This adjustment step was repeated at each change in baseplate or glenosphere. Humeral prosthesis retroversion was determined by adjusting a retroversion pin relative to the axis of the forearm.

Measurements

On each of the 40 cadaver shoulders, we tested the eight above-described glenoid component combinations, each with five different degrees of humeral component retroversion (0°, 10°, 20°, 30°, and 40°). All the measurements

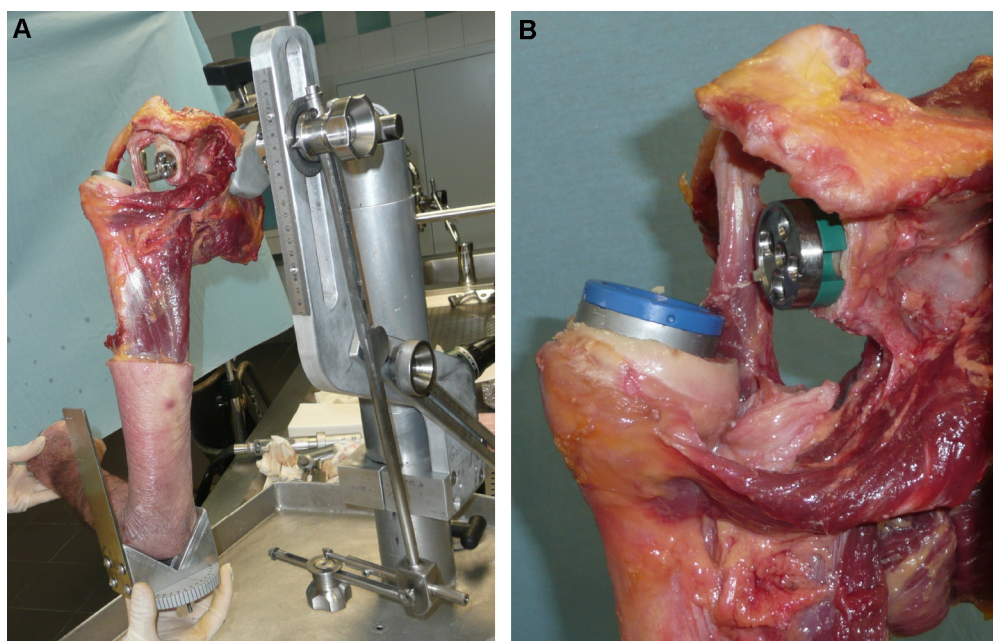


Figure 1 Anatomical specimens. A. The rotation measurement device was screwed to the humeral intra-medullary threaded nail before being secured to the metallic holder arm. B. 36-mm humeral insert opposite a 29-mm baseplate with a 7-mm-thick lateralised spacer.

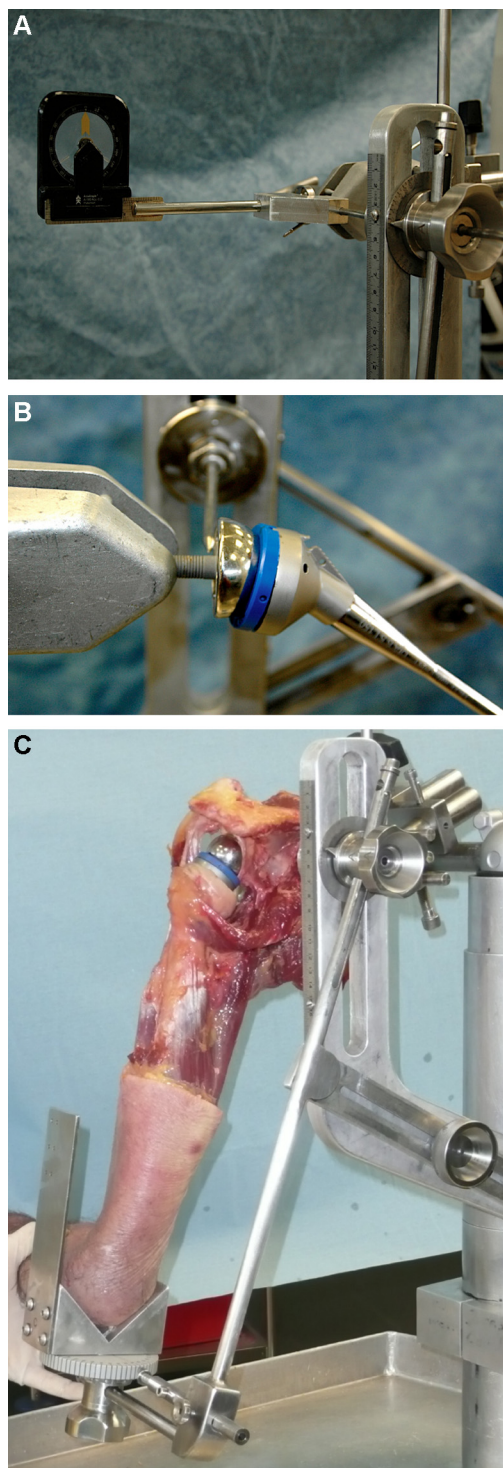


Figure 2 Sequential adjustments to glenoid component positioning (from left to right). A and B. Insertion of a drill guide through the adjustment V towards the target of the centring guide inserted into the glenoid baseplate. Position was adjusted using the various screws. The objective was 0° on the spirit level. C. Anatomic view of a coated shoulder implant ready for measurement of rotation motion ranges.

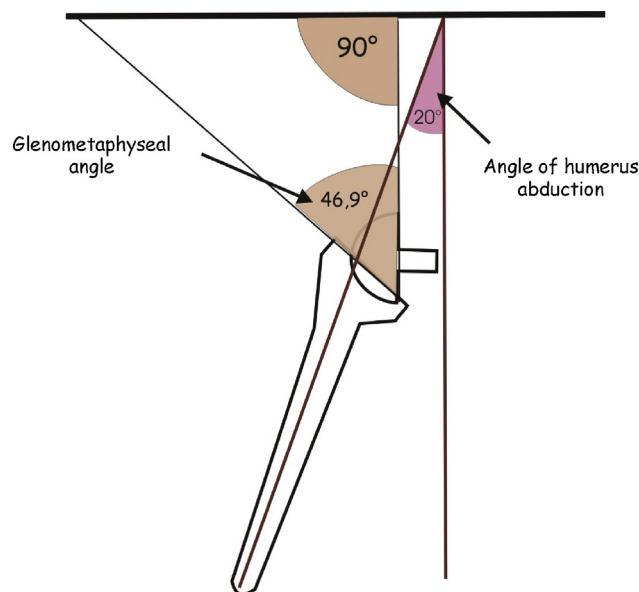


Figure 3 Method used to evaluate the degree of humerus abduction based on the gleno-metaphyseal angle.

were made using the plane of the scapula as the reference. Neutral rotation was defined as the forearm being perpendicular to the plane of the scapula when the elbow was in 90° of flexion. The maximum internal and external rotation ROMs were measured with the humerus in 20° of abduction. The abduction angle was defined based on the gleno-metaphyseal angle, which reflects the position of the glenosphere relative to the humeral implant. In a study comparing patients with and without scapular notching after RSA, the mean gleno-metaphyseal angle was 46.9° in patients with notching, indicating 20° of humerus abduction, and 37.5° in patients without notching, indicating 52° of humerus abduction with a strictly vertical orientation of the glenoid [13] (Fig. 3). We intentionally chose the lower abduction value to enable detection of impingements during arm rotation. The maximum rotation ROMs were defined as the ranges to posterior or anterior impingement. When no impingement occurred with the greatest motion ranges allowed by the measurement device, we arbitrarily assigned a value of 200° to internal or external rotation, as appropriate.

To assess the influence of the glenoid combinations on rotation ROM, we placed the humeral component in native retroversion. We assessed the influence of humeral retroversion on rotation ROM by obtaining measurements with the five degrees of retroversion for each of the eight glenoid combinations.

Statistical analysis

The data were described as the mean values with the 95% confidence intervals (95% CIs).

To compare rotation ROMs across glenoid implants and retroversions, we used the Wilcoxon rank sum test. Values of P lower than 0.05 were considered significant. All statistical analyses were performed using StatView 4.1 (Abacus Concepts Inc., Berkeley, CA, USA).

Results

Influence of glenoid modularity on internal and external rotation motion range

The internal and external rotation ROMs were smallest with the centred 36-mm glenosphere ($31.1 \pm 10.2^\circ$ and $33.8 \pm 11.1^\circ$, respectively, $P < 0.0001$ versus all other glenosphere sizes). Both rotation ROMs were greater with the 42-mm glenospheres, and the best ranges were obtained when a 7-mm or 10-mm lateralised spacer was added ($78.8 \pm 8.6^\circ$ and $99.3 \pm 6.3^\circ$, respectively; $P < 0.001$ versus all other glenosphere sizes). Thus, the increases were about 46° for internal rotation and 66° for external rotation ($P < 0.0001$). With a given amount of lateralisation (7-mm spacer), the factor that had the largest influence was the diameter of the glenosphere ($P < 0.0001$). The increases in internal and external rotation with the 42-mm glenosphere were about 20° and 24° compared to the ranges obtained using the 36-mm glenosphere (Table 1).

Influence of humeral retroversion on internal and external rotation motion ranges

Mean native humerus retroversion was 17.25° (range, $0-40^\circ$). Maximal internal rotation with each of the glenoid component combinations decreased significantly as humeral component retroversion increased ($P < 0.0001$). In contrast, maximal external rotation increased significantly with humeral component retroversion ($P < 0.0001$). With native retroversion, both internal and external rotation ROMs were closely similar to those obtained at 20° of retroversion. The changes in both internal and external rotation induced by varying the degree of humeral component retroversion were similar with each of the glenoid component combinations. Classification of the implants based on rotation ROM produced the same order as during the part of the study involving changes in the glenoid component (Fig. 4).

Discussion

Influence of glenoid modularity on internal and external rotation motion range

Loss of rotation with the elbow by the side is the main source of functional impairment after RSA [2]. The main technical method that has been suggested to improve rotation ROMs is glenosphere lateralisation via either bone graft interposition [11] or a change in implant design [8]. Other methods consist in eccentric glenosphere positioning or tilting of the glenosphere. We evaluated the impact of these variants on rotation ROM and risk of impingement.

Our results indicate that the larger 42-mm glenosphere produces considerably greater ranges of internal and external rotation. The increases were largest when we used a lateralised spacer replicating the effects of the BIO-RAD procedure. The combination of a 10-mm lateralised spacer (adding to the 3 mm supplied by the 42-mm glenosphere compared to the 36-mm glenosphere) and a 9-mm inferior

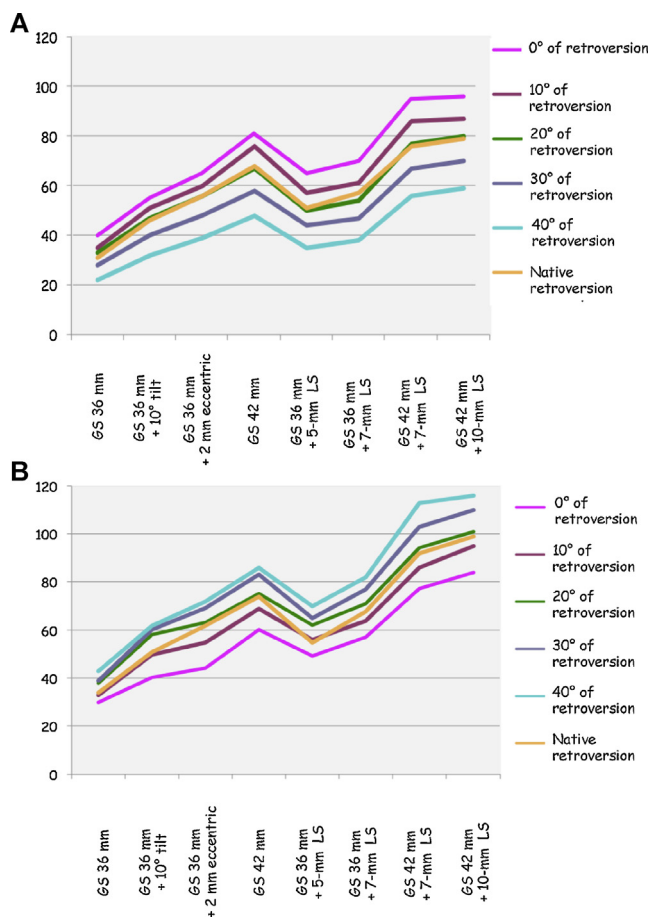


Figure 4 Mean motion ranges in degrees with the arm abducted at 20° , with the five humeral component retroversion values tested for each of the glenoid combinations. Panel A: internal rotation. Panel B: external rotation. Although the data are independent, they are shown as continuous curves to improve readability and comparability. However, the trends are preserved.

overhang significantly improved both internal and external rotation.

No previous biomechanical studies assessed the influence of glenoid component modularity on internal and external rotation ROMs and on the occurrence of anterior and posterior impingement, respectively. The available data come from retrospective case-series studies of patients managed with RSA. With 8.5-mm lateralisation, external rotation increased by 15° and internal rotation with the elbow by the side by 1 point on the Constant score after a mean follow-up of 36 months [9,10]. When an autologous bone graft 7 or 10 mm in thickness was implanted (BIO-RSA), external rotation improved by 10° and internal rotation by 1.4 point on the Constant score after 28 months [11]. Use of a 42-mm glenosphere was associated with a 13° improvement in external rotation with the elbow by the side after a mean follow-up of 12 months, whereas rotation ROM decreased when a 38-mm glenosphere was implanted [14]. Internal rotation decreased by four vertebral levels with the 42-mm glenosphere and increased to the same extent with the 38-mm glenosphere. However, the subgroup sizes in this study were

Table 1 Maximal ranges of internal and external rotation with the arm abducted at 20°, with eight different glenoid component combinations and with native retroversion. The data are means with their 95% confidence intervals.

	GS 36 mm	GS 36 mm + 10° tilt	GS 36 mm + 2 mm eccentric	GS 42 mm	GS 36 mm + 5-mm LS	GS 36 mm + 7-mm LS	GS 42 mm + 7-mm LS	GS 42 mm + 10-mm LS
MaxER	31.1 (10.2)	46.3 (10.3)	56.3 (11.5)	68.3 (10.9)	51 (10.6)	56.5 (9)	76.5 (9.1)	78.8 (8.6)
MaxIR	33.8 (11.1)	51.3 (11.2)	62.3 (11.3)	74 (10)	55.6 (11)	68.5 (9.3)	92.6 (7.4)	99.3 (6.3)

GS: glenosphere; Max: maximal; LS: lateralised spacer; ER: external rotation; IR: internal rotation.

small and unequal, and the thickness of the humeral inserts was variable.

Variations in patient selection criteria for RSA, surgical approaches, implantation technique, and prosthesis design are obstacles to comparisons of case-series studies. The study reports sometimes fail to provide important information such as the condition of the rotator cuff muscles, particularly the teres minor, and the degree of humeral implant retroversion. The main limitations of our study are the variability in cadaver shoulder anatomy and the absence of a morphological analysis of each scapula. In addition, possible variations in prosthesis implantation and the extensive soft tissue resection during preparation of the cadaver specimens may have influenced the measured ROMs and the reliability of our impingement assessments. In particular, when the shoulder has been detached from the torso, internal rotation cannot be evaluated based on the hand-to-spine manoeuvre, which also requires repulsion. Thus, it can be difficult to determine whether ROM differences are ascribable solely to differences in implant geometry. Nevertheless, a detailed standardised protocol was used for implantation of all 40 prostheses in our study. The degree of detail and standardisation of this protocol is a major strength of our work.

We found better rotation ROMs with the 42-mm glenosphere, particularly when a lateralised spacer was used. However, this combination raises a number of problems in everyday practice. Obtaining sufficient exposure to allow its implantation can prove challenging. The considerable bulk of this prosthesis in the joint cavity puts the surrounding soft tissues under tension. Excessive tension of the sub-scapularis or teres minor muscles may cause functional alterations responsible for loss of internal or external rotation [4]. This factor is among the explanations put forward by De Wilde [15] to explain the loss of rotation seen with a 42-mm glenosphere. Nevertheless, greater glenosphere diameter clearly exerts a major influence on rotation ROM. As use of the 42-mm glenosphere is not always feasible, availability of an intermediate glenosphere diameter might be useful. Thus, a 39-mm glenosphere might constitute an acceptable compromise when implantation of a 42-mm glenosphere raises insurmountable technical problems.

Influence of humeral retroversion on internal and external rotation motion range

In our study, increasing the degree of humeral component retroversion improved external rotation while decreasing internal rotation in similar measure. As expected, the opposite occurred when the degree of retroversion was decreased. At each of the tested retroversion values, the influence of the glenosphere was the same as at the native retroversion value: rotation ROM was greatest with the 42-mm glenosphere, particularly when a lateralised spacer was used. This combination decreased the risk of anterior and posterior impingement.

As with data reported for inferior impingement, our results regarding rotation ROM can be explained by the anatomy of the scapular pillar [16–18]. With high retroversion values, posterior impingement occurs late and the range

of external rotation is high. In this situation, the humerus is displaced anteriorly, away from the scapular pillar, which is in a more posterior location. Anterior impingement, in contrast, occurs earlier. With the 42-mm glenosphere, we even found in a few cases that anterior impingement on the coracoid process occurred before impingement on the scapular pillar could develop. The loss of internal rotation probably explains the early inferior impingement seen with 30° or 40° of humeral retroversion. This is the worst situation in terms of function and subsequent clinical course, as the patient has both ROM limitation and a high risk of early scapular notching.

In previous studies, the value of humeral component retroversion is rarely reported and, when it is known, it varies across authors. In the seminal description of RSA by Grammont et al. [3], the humeral component was positioned in 30° of retroversion. Valenti et al. [10] used 20° of retroversion to optimise the function of the glenoid and humeral components by aligning them along the same axis. Humeral component retroversion seems to have little impact on implant alignment, however. In a computed tomography study of normal shoulders, De Wilde et al. [19] found 8° of divergence between the glenoid and humeral axes. Karelse et al. [20] conducted a radio-clinical study of 30 RSAs and observed that gleno-humeral divergence values of up to 34° had no effect on internal rotation. Thus, no sound basis exists for recommending a specific fixed position appropriate for all situations. At the end of the 2006 SOFCOT symposium, Walch [3] argued in favour of using little or no humeral component retroversion, as this situation was associated with benefits on activities of daily living, strength, the absolute and weighted Constant's scores, and passive anterior elevation. However, no effect was found on the rate of notching after a mean follow-up of 52 months. More recently, Stephenson et al. [21] reported that 20° to 40° of retroversion produced the greatest maximal rotation ROMs without scapular impingement. The measurements were performed with the arm abducted to 60° in the plane of the scapula.

Thus, the recommendations vary and the optimal degree of retroversion of the humeral component remains unclear. The main functional limitation that affects everyday activities after RSA is loss of internal rotation, which induces major impairments, particularly for dressing and perineal care. In theory, the hand can be placed on the spine if internal rotation is at least 100°, provided repulsion of the shoulder can be achieved simultaneously [22]. Everyday activities rarely require more than 90° of external rotation with the elbow by the side. In our study, the best balance between internal and external rotation was obtained with 0° to 20° of humeral retroversion. The mean native retroversion value of 17.5° seemed to produce the best result. As mentioned above, this retroversion value was also associated with the greatest range to inferior impingement. Thus, with the 42-mm glenosphere and the native retroversion, there was a good balance between the maximal ROMs in internal and external rotation, which were 69° and 74°, respectively. Inferior impingement occurred at 6° of elevation. With 40° of retroversion, internal rotation was only 48° whereas external rotation increased to 86°, and inferior impingement occurred earlier, at 7° of elevation. This was the least favourable situation. With 0° of retroversion,

inferior impingement also occurred at 6° of elevation but the rotation ROMs were not well balanced, as internal rotation increased to 81° but external rotation decreased to 60°. Finally, the only drawback of using the native retroversion value is limitation of arm elevation in the plane of the scapula. The range of this movement is greater when retroversion tends towards 0°. However, caution is in order regarding this point, as the scapula-thoracic joint was blocked in our study. This joint plays a key role in arm elevation after RSA [23]. Patients receiving follow-up after RSA rarely complain about loss of arm elevation.

A final argument in favour of using the native retroversion value for positioning the humeral component is that it produces an optimal match between the prosthetic and native epiphyses. With the extreme retroversion values of 0° or 40°, we found a mismatch between the prosthetic epiphysis and proximal humerus, indicating a risk of fracture of the lesser and greater tuberosity, respectively.

Conclusion

A 42-mm glenosphere with a 7-mm or 10-mm lateralised spacer produced the best internal and external rotation ROMs with the arm in 20° of abduction. An intermediate-size glenosphere measuring 39 mm in diameter might constitute a good compromise when implantation of a 42-mm glenosphere raises major technical challenges.

Replicating the native humeral retroversion value, usually between 10° and 20°, seems the best option for obtaining a good balance between internal and external rotation motion ranges.

Disclosure of interest

Berhouet Julien: none.

Garaud Pascal: none.

Favard Luc: consultant for Tornier Inc.

References

- [1] Guery J, Favard L, Sirveaux F, Oudet D, Mole D, Walch G. Reverse total shoulder arthroplasty. Survivorship analysis of eighty replacements followed for five to ten years. *J Bone Joint Surg Am* 2006;88:1742–7.
- [2] Molé D, Favard L. Excentered scapulohumeral osteoarthritis. *Orthop Traumatol Surg Res* 2007;93(6 Suppl.):37–94 [In French].
- [3] Grammont PM, Trouilloud P, Laffay JP, Deries X. Étude et réalisation d'une nouvelle prothèse d'épaule. *Rhumatologie* 1987;39:17–22 [In French].
- [4] Boileau P, Watkinson DJ, Hatzidakis AM, Balg F. Grammont reverse prosthesis: design, rationale, and biomechanics. *J Shoulder Elbow Surg* 2005;14(1 Suppl. S), 147S–161S.
- [5] Boulahia A, Edwards TB, Walch G, Baratta RV. Early results of a reverse design prosthesis in the treatment of arthritis of the shoulder in elderly patients with a large rotator cuff tear. *Orthopedics* 2002;25:129–33.
- [6] Sirveaux F, Favard L, Oudet D, Huquet D, Walch G, Molé D. Grammont inverted total shoulder arthroplasty in the treatment of glenohumeral osteoarthritis with massive rupture of the cuff. Results of a multicentre study of 80 shoulders. *J Bone Joint Surg Br* 2004;86:388–95.
- [7] Sirveaux F. La prothèse de Grammont dans le traitement des arthropathies de l'épaule à coiffe détruite. À propos d'une série multicentrique de 42 cas, 245 p. Thèse: Médecine. Nancy I; 1997 [In French].
- [8] Frankle M, Siegal S, Pupello D, Saleem A, Mighell M, Vasey M. The reverse shoulder prosthesis for glenohumeral arthritis associated with severe rotator cuff deficiency. A minimum two-year follow-up study of sixty patients. *J Bone Joint Surg Am* 2005;87:1697–705.
- [9] Kalouche I, Sevivas N, Waheganonker A, Sauzieres P, Katz D, Valenti P. Reverse shoulder arthroplasty: does reduced medialisation improve radiological and clinical results? *Acta Orthop Belg* 2009;75:158–66.
- [10] Valenti P, Sauzières P, Katz D, Kalouche I, Kilinc A. Does less medialized reverse shoulder prostheses increase motion and reduce notching? *Clin Orthop Relat Res* 2011;469(9):2550–60.
- [11] Boileau P, Moineau G, Roussanne Y, O'Shea K. Bony increased-offset reversed shoulder arthroplasty (BIO-RSA): minimizing scapular impingement while maximizing glenoid fixation. *Clin Orthop Relat Res* 2011;469(9):2558–67.
- [12] Constant CR, Murley AH. A clinical method of functional assessment of the shoulder. *Clin Orthop Relat Res* 1987;214:160–4.
- [13] Kelly 2nd JD, Humphrey CS, Norris TR. Optimizing glenosphere position and fixation in reverse shoulder arthroplasty. Part One: The twelve-mm rule. *J Shoulder Elbow Surg* 2008;17:589–94.
- [14] Falaise V, Lévine C, Favard L. Scapular notching in reverse shoulder arthroplasties: the influence of glenometaphyseal angle. *Orthop Traumatol Surg Res* 2011;97:S131–7.
- [15] De Wilde L. Influence of the sphere diameter on radiographic and clinical results of RSA. In: Walch G, Boileau P, Molé D, Favard L, Lévine C, Sirveaux F, editors. *The glenoid*. Montpellier, France: Sauramps Médical; 2010. p. 393–402.
- [16] Middernacht B, De Roo P-J, Van Maele G, De Wilde LF. Consequences of scapular anatomy for reversed total shoulder arthroplasty. *Clin Orthop Relat Res* 2008;466:1410–8.
- [17] Karelse A, Kegels L, De Wilde LF. The pillars of the scapula. *Clin Anat* 2007;20:392–9.
- [18] Von Schroeder, Herbert P, Scott D, Botte, Michael J. Osseous anatomy of the scapula. *Clin Orthop Relat Res* 2001;383:131–9.
- [19] De Wilde LF, Berghe BM, VandeVyver F, Schepens A, Verdonk RC. Glenohumeral relationship in the transverse plane of the body. *J Shoulder Elbow Surg* 2003;12:260–7.
- [20] Karelse AT, Bhatia DN, De Wilde LF. Prosthetic component relationship of the reverse Delta III total shoulder prosthesis in the transverse plane of the body. *J Shoulder Elbow Surg* 2008;17:602–7.
- [21] Stephenson DR, Oh JH, McGarry MH, Rick Hatch 3rd GF, Lee TQ. Effect of humeral component version on impingement in reverse total shoulder arthroplasty. *J Shoulder Elbow Surg* 2011;20:652–8.
- [22] Kapandji IA. L'épaule. In: Kapandji IA, editor. *Physiologie articulaire, Tome 1: membre supérieur*. France: Maloine; 1994. p. 10–79 [In French].
- [23] Favard L, Fournier J, Berhouet J. Cinématique de l'élévation de l'épaule normale et prothésée. In: Walch G, Boileau P, editors. *Prothèse d'épaule. États actuels*. France: Elsevier Masson; 2008. p. 21–8 [In French].