

IMAGE OF THE ISSUE

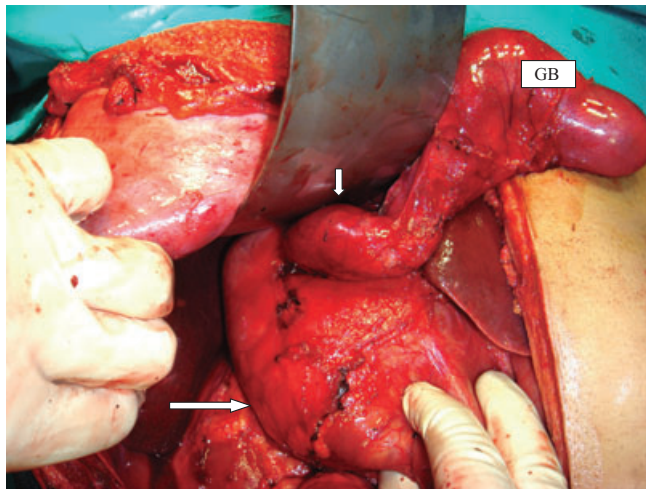
Type IV A choledochal cyst with cystic duct cyst

Supriyo Ghatak

Division of Surgical Gastroenterology, School of Digestive and Liver Diseases, Institute of Postgraduate Medical Education and Research, Kolkata, India

Correspondence

Supriyo Ghatak, Division of Surgical Gastroenterology, School of Digestive and Liver Diseases, Institute of Postgraduate Medical Education and Research, Kolkata, India, Email: drsupriyo@yahoo.co.in



Long arrow; common bile duct cyst, short arrow; cystic duct cyst, GB; gall bladder

Operative view of a saccular cystic duct cyst joining the gall bladder to a fusiform dilatation of a common bile duct cyst. The complex cysts were excised and a Roux-en-Y hepaticojejunostomy was fashioned. Very rarely has a cystic duct cyst been reported.¹ It can present either as a cystic duct cyst or in association with a cyst in another part of the choledochus.^{2,3}

References

1. Serena Serradel AF, Santamaria Linares E, Herrera Goepfert R. (1991) Cystic dilatation of the cystic duct: A new type of biliary cyst. *Surgery* 109:320–322.
2. Crozier F, Hardwisgen J, Jaoua S, Charrier A, Aillaud S, Bourlière B *et al.* (2003) Choledochal cyst associated with congenital cystic duct dilatation: Report of two cases. *Ann Chir* 128:459–461.
3. Elabsi M, Amraoui M, Elouannani M, Echarrab M, Elalami Faricha A, Errou-gani A, Chkof Moulay R. (2006) Choledochal cyst associated with dilatation of the cystic duct. *J Chir (Paris)* 143:308–309.