



Case Report

Finger snapping during seizures

M.J. Overdijk^a, M. Zijlmans^{b,c,*}, P.H. Gosselaar^b, A. Olivier^d, F.S.S. Leijten^c, F. Dubeau^d^a Department of Neurology, Medical Center The Hague, The Hague, The Netherlands^b Department of Neurology and Neurosurgery, Rudolf Magnus Institute of Neuroscience, University Medical Center Utrecht, Utrecht, The Netherlands^c SEIN, Epilepsy Institute in the Netherlands Foundation, Heemstede, The Netherlands^d Department of Neurology and Neurosurgery, Montreal Neurological Hospital and Institute, Montréal, Canada

ARTICLE INFO

Article history:

Received 25 March 2014

Received in revised form 28 March 2014

Accepted 29 March 2014

Available online 4 May 2014

Keywords:

Complex partial seizure

Intracranial EEG

Finger snapping

Automatism

Semiology

Epilepsy

ABSTRACT

We describe two patients who showed snapping of the right hand fingers during invasive intracranial EEG evaluation for epilepsy surgery. We correlated the EEG changes with the finger-snapping movements in both patients to determine the underlying pathophysiology of this phenomenon. At the time of finger snapping, EEG spread from the supplementary motor area towards the temporal region was seen, suggesting involvement of these sites.

© 2014 The Authors. Published by Elsevier Inc. This is an open access article under the CC BY-NC-ND license (<http://creativecommons.org/licenses/by-nc-nd/3.0/>).

1. Introduction

Surgical intervention in epilepsy is a widely accepted, effective therapy in patients with pharmacoresistant partial epilepsy. Seizure semiology correlates with the seizure origin, spread, and release phenomenon and can help in the estimation of the anatomical brain localization [1]. Recognition of seizure semiology is important for correct diagnosis and surgical treatment of epilepsy.

Finger snapping has been noted as a common act for centuries and is employed in securing someone else's attention. The sound of the snap is created by forcing air out between the fingers with an audible crack. Automatisms involving the distal segments of the upper or lower limbs are frequent during seizures [1] and, when unilateral, often indicate ipsilateral seizure onset, mostly in the temporal lobe or in the orbitofrontal region [1,2]. Finger snapping could be interpreted as a temporal lobe automatism, but the fierceness of the finger-snapping movement associated with tonic abduction of the upper limb could indicate a focus in the supplementary motor area (SMA) [3,4]. We describe two patients in whom invasive intracranial EEG evaluation was performed to localize the seizure onset for surgical intervention. Both patients showed ictal snapping of the right hand fingers, which has not previously been described in literature.

* Corresponding author at: University Medical Center Utrecht, Rudolf Magnus Institute of Neuroscience, Department of Neurology (HP G03.228), PO Box 855000, 3508 GA Utrecht, The Netherlands. Tel.: +31 88 7555555; fax: +31 30 2542100.

E-mail address: g.j.m.zijlmans@umcutrecht.nl (M. Zijlmans).

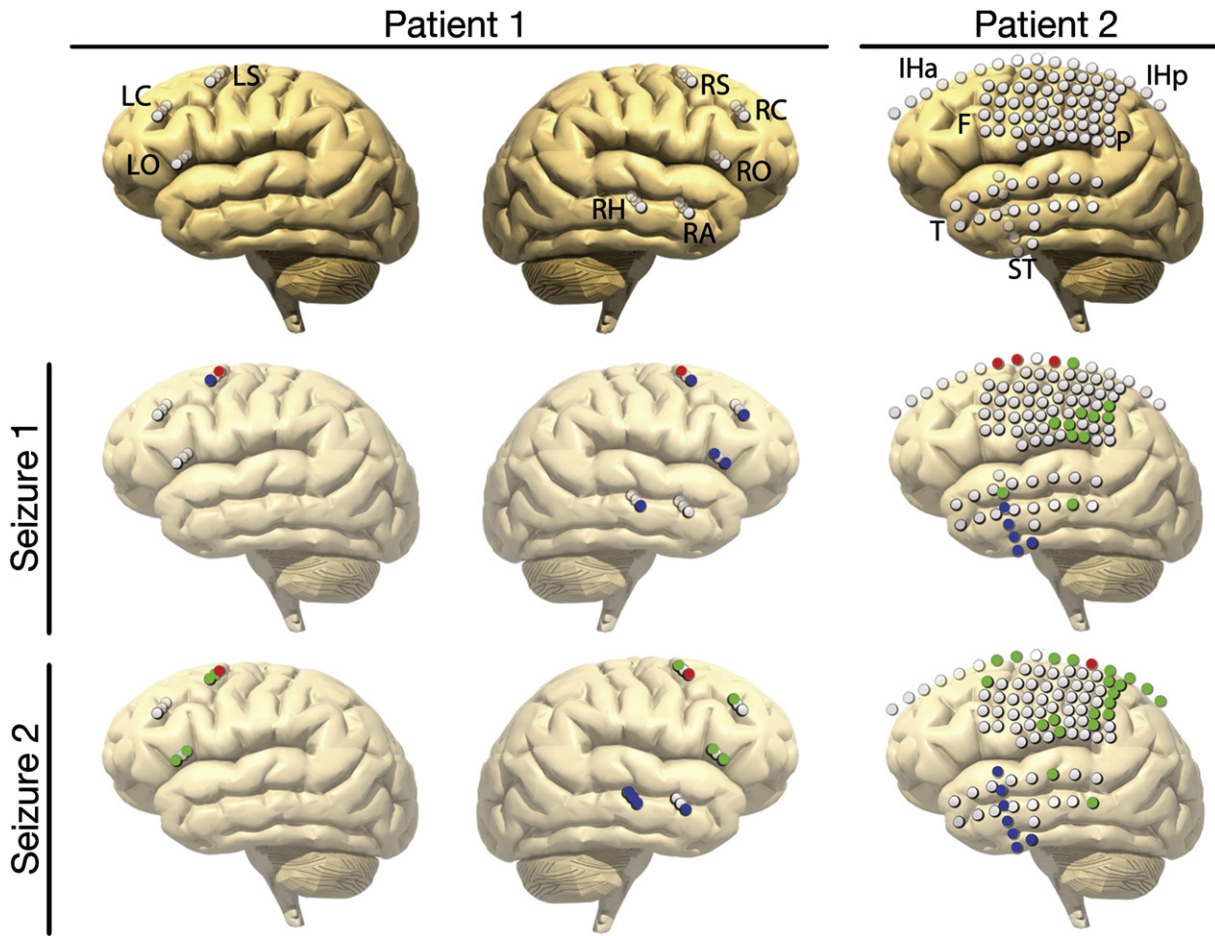
2. Case reports

2.1. Patient 1

A 34-year-old right-handed man was seen at the Montreal Neurological Hospital for investigation of refractory seizures. His seizures began at the age of seven, two years after a right-sided head trauma. A maternal great uncle had unspecified epilepsy. Early EEGs revealed an active epileptiform anomaly over the right midfrontal region. Over the years, he showed fluctuation in frequency and severity of seizures, which eventually remained refractory. 1.5-Tesla MRI showed no structural abnormalities.

During admission for video-EEG, typical clinical seizures occurred predominantly during sleep, without aura, and were defined as tonic posturing with fencing, extension of the right arm, snapping of the right hand fingers, and some pedaling movement. Electroencephalography telemetry showed several seizures not only with bilateral background activity changes, such as generalized epileptiform anomalies, but also with focal attenuation over the right frontal or temporal regions.

For nine days, intracranial stereo-EEG exploration with 11-contact depth electrodes was performed, exploring both frontal lobes and the right temporal lobe (Fig. 1). Active interictal epileptiform discharges were seen in the right hippocampal formation, and an independent, less active interictal epileptiform anomaly was found in the mesial aspect of the right orbitofrontal lobe. Twenty-five seizures were recorded, mostly nocturnal, with a semiology typical for this patient's seizure



Patient I (SEEG - depth electrodes)	Patient II (subdural grids)
LS = Left SMA LC = Left cingulate gyrus LO = Left orbito-frontal RS = Right SMA RC = Right cingulate gyrus RO = Right orbito-frontal RA = Right amygdala RH = Right hippocampus	IHa = Interhemispheric anterior IHp = Interhemispheric posterior F = Frontal P = Parietal T = Temporal ST = Subtemporal
● = Gamma onset ● = First spread ● = Activity during typical Finger Snapping	

Fig. 1. Schematic figures representing the seizure onset and spread.

pattern: they were usually brief, lasting 22 to 40 s, consisting of tonic posturing with fencing, extension of the right arm and elevation and flexion of the left arm, deviation of the head to the right, and discreet pedaling with both legs. Right hand finger snapping was observed in 10/25 (40%) seizures during the second half of the ictal phase. Electrographical onsets were bilateral and frontal with often right-sided predominance and maximum involvement of the SMA. The finger snapping coincided with the discharge spreading to the right temporal lobe to both mesial hippocampal and more superficial temporal channels. A typical seizure was electrically evoked when the right mesial orbitofrontal area was stimulated (biphasic square wave stimulus, 60 Hz, 4 mA, 3 s), with finger snapping occurring 12 s after onset and while a rhythmic discharge was seen in the right temporal lobe (Supplementary Video 1). The patient first underwent a restricted resection of the right anterior orbitofrontal region and, one year later, a more extensive anterior frontal resection with no changes in seizure frequency or in semiology. Histological analysis of the first surgical specimen showed moderate to marked gliosis.

2.2. Patient 2

A 15-year-old right-handed girl was seen at the University Medical Center Utrecht for investigation of pharmacoresistant seizures. Her typical seizures began at the age of eight and had deteriorated ever since. Perinatal complications involved cyanosis caused by vacuum extraction. There was no history of febrile seizures, CNS infection, or trauma. Family history was uneventful. Seizures occurred six to eight times a month. Magnetic resonance imaging showed a left mesial parietal focal cortical dysplasia.

During admission for video-EEG, typical clinical seizures consisted of gazing and grunting, twitching of the upper body, head, right arm, and hand with occasional snapping of the right hand fingers, and followed by dysphasia. Ictal EEG showed irregular slow wave activity over the left laterofrontal and frontotemporal regions and diffuse spread in the left hemisphere.

Intracranial subdural grids were placed over the mesial aspect of both the frontoparietal region and the convexity of the left centroparietotemporal neocortex (Fig. 1) and recordings were obtained for seven days. Active interictal multifocal epileptiform discharges occurred near the mesial parietal lesion, more laterally over the parietotemporal transition area and the inferotemporal surface. Twenty-two typical seizures were recorded, and 3/22 (13%) were with typical finger snapping which started a few seconds after seizure onset. These three attacks consisted of gazing and grunting, twitching of the head, and right hand finger snapping. The other seizures showed subtle clinical manifestations like dysphasia. No seizures were induced with stimulation. Ictal corticography showed gamma activity over the mesial aspect of the parietal lobe and caudal to the lesion prior to clinical symptoms. The discharge then spread to the parietotemporal transition area and the inferotemporal surface (Supplementary Video 1). This patient eventually underwent resection, and the lesion turned out to be focal cortical dysplasia type 2b. Resection was constrained by eloquent functions of the brain tissue; postoperative MRI showed remains of the cortical dysplasia, and postsurgical seizures remained unchanged.

3. Discussion

We describe two cases of ictal finger snapping. During these seizures, patients extended the right arm and snapped the right hand fingers. In one patient, there was clear tonic posturing and loud snapping suggesting high muscle tension. When this patient was requested to snap his fingers on purpose, he could not snap as loudly. In both patients, the SMA was involved early in the seizure, with spread to the orbitofrontal and parietal areas. The EEG activity at the start of the finger snapping during these seizures coincided with the spread of discharge into the temporal lobe, which suggests that finger snapping represents

another upper limb automatism generated or modulated by the temporal lobe. The localizing precision is, however, limited as snapping occurred only during seizure spread. In the first patient, the predominant activity was ipsilateral to the finger snapping, but the contralateral temporal lobe was not implanted. Video-EEG showed predominantly ipsilateral activity. In the second patient, the temporal seizure activity seemed contralateral, but, in this case, the ipsilateral side was not explored. However, video-EEG showed only contralateral activity. Within the temporal lobe, the spread of activity seemed to differ between patients which could result from different recording methods, depth versus corticography. The sampling of the implantations imposes a limitation to our hypothesis. In both patients, epilepsy surgery of the mesiofrontal and parietal cortex could not control the seizures. The semiology was unchanged, which fits with our hypothesis of the involvement of the SMA and temporal lobes.

Investigation of ictal behavior through video-EEG monitoring has led to the recognition of a number of typical clinical signs, including oral and limb automatisms such as lip smacking, swallowing, chewing, and exploratory movements in temporal lobe epilepsy [2,5]. Finger snapping has not been described as a typical ictal sign or following electrocortical stimulation. It might be a type of rhythmic ictal nonclonic hand motions which are associated with contralateral temporal lobe seizures [6].

A number of studies specifically compared semiologic features of frontal lobe seizures with those of temporal lobe seizures [7–10]. Leg movements such as pedaling and kicking, tonic posturing, and tonic-clonic movements seem to occur more frequently in frontal lobe seizures, while oral, exploratory, and hand automatisms are seen more frequently in temporal lobe seizures [8,10]. Automatisms have been quantitatively analyzed by Yang et al. [11], and they suggest limb movements during temporal lobe epilepsy to be predominantly distal, while, in frontal lobe epilepsy, proximal movements are predominant.

Ictal finger snapping might be interpreted as a combination of two common features of epileptic seizures. The start of snapping in fact follows a tonic abduction of the distal part of the right arm with high muscle tension in the fingers, which is seen in supplementary motor seizures [3,4]. Tonic posturing is associated with contralateral seizure onset in 80% of frontal lobe seizures [12]. The subsequent repetitive snapping of fingers can be interpreted as an automatism of the right hand, originating from the involvement of the temporal lobe [1,2]. This is supported by the evolution of the movement in patient 2 in whom the finger-snapping movement seems to start as a slow rhythmic pill-rolling movement, gets stronger, and eventually becomes finger snapping. This could emphasize that finger snapping could be atypical unilateral motor automatisms but, in a way, similar to classical temporal automatisms.

4. Conclusion

In two cases of ictal finger snapping, the ictal onset zone was near the supplementary motor area, with spread to the temporal lobe. We hypothesize that this semiology is a combination of muscle tension of the hand from supplementary motor area activation followed by an automatism of snapping originating from temporal lobe involvement.

Supplementary data to this article can be found online at <http://dx.doi.org/10.1016/j.ebcr.2014.03.010>.

Acknowledgments

We acknowledge assistance with the video editing done by Stefan Koudstaal, MD, University Medical Center Utrecht and Nico Theunissen, Employee, Clinical Neurophysiology Department, University Medical Center Utrecht. The second author was supported by the Netherlands Organization for Scientific Research (NWO) grant no. 92003481, the University Medical Center Utrecht (internationalization grant) and the “Stichting De Drie Lichten”.

References

- [1] Rossetti AO, Kaplan PW. Seizure semiology: an overview of the 'inverse problem'. *Eur Neurol* 2010;63:3–10.
- [2] Chee MW, Kotagal P, Van Ness PC, Gragg L, Murphy D, Luders HO. Lateralizing signs in intractable partial epilepsy: blinded multiple-observer analysis. *Neurology* 1993;43:2519–25.
- [3] Van Ness PC. Invasive electroencephalography in the evaluation of supplementary motor area seizures. *Adv Neurol* 1996;70:319–40.
- [4] Luders HO. The supplementary sensorimotor area. An overview. *Adv Neurol* 1996;70:1–16.
- [5] Ebner A, Dinner DS, Noachtar S, Luders H. Automatismes with preserved responsiveness: a lateralizing sign in psychomotor seizures. *Neurology* 1995;45:61–4.
- [6] Lee GR, Arain A, Lim N, Lagrange A, Singh P, Abou-Khalil B. *Epilepsia* 2006;47: 2189–92.
- [7] O'Brien TJ, Mosewich RK, Britton JW, Cascino GD, So EL. History and seizure semiology in distinguishing frontal lobe seizures and temporal lobe seizures. *Epilepsy Res* 2008;82:177–82.
- [8] Kramer U, Riviello Jr JJ, Carmant L, Black PM, Madsen J, Holmes GL. Clinical characteristics of complex partial seizures: a temporal versus a frontal lobe onset. *Seizure* 1997;6:57–61.
- [9] Manford M, Fish DR, Shorvon SD. An analysis of clinical seizure patterns and their localizing value in frontal and temporal lobe epilepsies. *Brain* 1996;119(Pt 1):17–40.
- [10] Salanova V, Morris HH, Van Ness P, Kotagal P, Wyllie E, Luders H. Frontal lobe seizures: electroclinical syndromes. *Epilepsia* 1995;36:16–24.
- [11] Yang X, Chen L, Liu Y, Zeng D, Tang Y, Yan B, et al. Motor trajectories in automatismes and their quantitative analysis. *Epilepsy Res* 2009;83:97–102.
- [12] Bonelli SB, Lurger S, Zimprich F, Stogmann E, Assem-Hilger E, Baumgartner C. Clinical seizure lateralization in frontal lobe epilepsy. *Epilepsia* 2007;48:517–23.