

ORIGINAL ARTICLE / *Senology*

Evaluation of lumpectomy surgical specimen radiographs in subclinical, in situ and invasive breast cancer, and factors predicting positive margins

C. Rua^{a,*}, P. Lebas^b, P. Michenet^c, L. Ouldamer^a^a Gynaecology Department, Centre Hospitalier Universitaire de Tours, Hôpital Bretonneau, 2, boulevard Tonnelé, 37044 Tours cedex, France^b Breast centre, CHR d'Orléans, 45022 Orléans cedex, France^c Department of Anatomy and Pathological Cytology, CHR d'Orléans, 45022 Orléans cedex, France**KEYWORDS**

Ductal carcinoma;
Radiograph;
Conservative breast
surgery;
Surgical margins;
Predictive factors

Abstract

Purpose: To determine the diagnostic performance of radiological evaluation of the margins of surgical specimens from lumpectomies for subclinical malignant breast lesions.

Materials and methods: Retrospective study in two French hospitals including all patients who had a non-palpable in situ (ISDC) or invasive (IDC) ductal carcinoma treated by lumpectomy after radiological localisation. For the analysis, the lesions were divided into two groups depending on the majority component in the definitive histological examination: ISDC or IDC. The radiological margin considered was 10 mm.

Results: For the 178 lumpectomies studied, the sensitivity of the radiographs of the surgical specimen was 33.3% for ISDC and 50% for IDC. The surgical revision rate was 27.41% for ISDC and 12.64% for IDC. The significant predictive factors for positive margins were the radiological size of the lesions (> 10 mm) for ISDC ($P=0.02$) and radiologically positive margins for IDC ($P=0.01$). Correlation was found between the histological and radiological sizes of the lesion for IDC, but not for ISDC.

Conclusion: Radiological examination of surgical specimens does not provide a satisfactory evaluation of the histological margins, in particular for ISDC, even with a radiological threshold of 10 mm.

© 2012 Éditions françaises de radiologie. Published by Elsevier Masson SAS. All rights reserved.

The generalisation of systematic screening for breast cancer by mammography and the progress of mammary imaging have increased the discovery of subclinical breast cancers [1]. When malignancy is diagnosed before surgery, conservative treatment of these non-palpable lesions is acceptable [2,3]. This treatment, known as lumpectomy, requires prior

* Corresponding author.

E-mail address: carina_rua@hotmail.fr (C. Rua).

marking of the area of the breast containing the tumour, usually by inserting a metal marker guided by mammography and/or ultrasound, and a radiograph of the tissue, once removed, to check complete ablation of the target lesion.

Since the status of the margins is a major prognostic factor [4,5], intraoperative evaluation of the resection margins is essential in order to limit the number of revision procedures.

The aim of our study was to evaluate the relationship between the radiological and histological assessment of the margins of the surgical specimens, in the treatment of sub-clinical malignant lesions of the breast (in situ and invasive ductal carcinoma) in two French hospitals in 2010.

Materials and methods

Study population

By using the surgical databases, we identified all patients with a diagnosis of malignancy on definitive histological examination, who had had a lumpectomy for subclinical mammary lesions between 1st January and 31st December 2010.

The inclusion criterion was any non-palpable lesion (T0) treated during the study period. In order to have a homogeneous population and to limit confusing factors, we chose to exclude lobular carcinomas, so called "borderline" lesions, and benign lesions, retaining only lesions of in situ and invasive ductal carcinoma. The patients were divided into two groups depending on the majority histological type found in the definitive examination: either invasive ductal carcinoma (IDC) or in situ ductal carcinoma (ISDC).

Procedure

For all the patients, pre-operative histological diagnosis was obtained by stereotactic macrobiopsy or ultrasound-guided microbiopsy. When the macrobiopsy was performed in the Orléans hospitals, a MammoMark® collagen clip (Artemis Medical, Hayward, CA) was inserted which could be detected using ultrasound for up to 6 weeks after implantation.

The lesions were located using ultrasound whenever possible, or stereotactically, with the help of one or more Cook® DXRLB -19.5-9.0-S metal markers (X-Reidy Breast Lesion Localization Needle, William Cook Europe), or by a skin localisation marker.

Ultrasound imaging was performed and a cranio-caudal (CC) or lateral mammogram taken for the ultrasound guided localisation. Two mammograms (CC and lateral) were taken for stereotactic localisation. After lumpectomy, the specimen was oriented by fixing it onto a polystyrene support using pins, and the outer surfaces stained with India ink. It was then sent to the radiology unit.

The intraoperative radiological interpretation (ablation of the lesion and status of the margins) was provided orally by a specialist mammary radiologist to the surgeon, who also received the mammogram. The images of the surgical specimen were made using a digital Sectra MicroDose® mammography system, and were not enlarged.

Re-excision was performed intraoperatively either at the request of the radiologist because of positive margins or

systematically by the surgeon, irrespective of radiological evaluation of the margins. The radiological margin status was evaluated qualitatively as positive or clear. A value of 10 mm was routinely used to define a clear margin.

After radiological examination, the surgical specimen was sent to the histopathology laboratory where it underwent histological examination by a histopathologist specialising in breast pathology.

Data collected

We recorded age, personal or family history of cancers, menopausal status and whether or not hormone replacement therapy had been taken, for all the patients studied.

The following data were collected concerning the lesions:

- radiographic data: the ACR's BI-RADS classification (American College of Radiology's Breast Imaging Reporting and Data System), modified by ANAES (French National Agency for Health Accreditation and Evaluation) was used to classify the radiological lesions [6–8]. We recorded the number of lesions, the radiological size, the side, quadrant, type of anomaly (mass, microcalcifications, architectural distortion), type of localisation used and number of metal markers inserted, and the intraoperative quality of the margins (positive or clear) as well as whether or not re-excision was performed;
- histopathological data: the histology of the biopsy samples, the definitive histology of the lesion from the surgical specimen as well as the size of the invasive and in situ components, the minimum distance separating the lesion from the edges in millimetres before and after re-excision, the weight and size of the surgical specimen and finally, lymph node status.

If a second or third surgical procedure was necessary, the type of procedure, the size and margins of the lesion were also recorded.

Statistical analysis

The radiological and histological sizes were compared using the correlation coefficient r which was determined by linear regression. The diagnostic performance of the radiographs of the surgical specimens was evaluated by calculating the sensitivity (Se), specificity (Sp) and positive (PPV) and negative (NPV) predictive values. The radiological margin was considered as being positive when the value was less than 10 mm. The histopathological margin was considered as positive for a value lower than or equal to 1 mm. The factors predicting positive histopathological margins underwent uni- and multivariate analysis using logistic regression. Tests were considered to be significant for a P value below 0.05.

Results

Of the 178 lumpectomies performed in 2010, 149 met the inclusion criteria. Three patients had two lesions and one had three lesions, i.e. there were 144 patients.

The majority component of 62 of the lesions analysed was in situ ductal carcinoma, and of 87 it was invasive ductal

carcinoma. Of the lesions classified in the majority IDC group, 47 (54%) had no in situ component. When present, the mean size of the in situ component was 3.89 ± 5.65 mm [0–20]. Of the lesions classified in the majority ISDC group, 40 (64.5%) had no invasive component, but when it was present, it measured a mean of 3.01 ± 4.34 mm [2–40].

The clinical and radiological characteristics of the two groups are given in Table 1.

The lesions were all marked in the IDC group with a metal marker, including six patients with two metal markers for a single lesion. In the ISDC group, three lesions were located cutaneously without inserting metal markers and four lesions were marked by two metal markers. The collagen clip provided a purely ultrasound localisation rate of 69.4% in the ISDC group.

The histopathological characteristics of the surgical specimens – size of the lesion and margins – are given in Table 2.

In the ISDC group, the radiological margins were positive in 14 cases (22.6%) and the lesion not found in two

cases (3.2%), i.e. re-excision was necessary in the light of the radiographs of the surgical specimens in 25.8% of the lumpectomies. Twenty-four patients (38.7%) underwent re-excision including eight that were systematically performed regardless of the radiograph of the surgical specimen. Four of the re-excisions produced clear margins, i.e. the previously histologically positive margins became clear; these results only occurred among the excisions performed systematically.

The surgical revision rate for positive margins, not including revision for a positive sentinel lymph node, was 27.41%: 11 revisions of the tumour bed and six mastectomies. In the six ablated mastectomy tissues, two ISDCs and two IDCs were found. Two were negative. The tumour bed revisions produced eight cases of histologically clear margins while three had positive margins, i.e. 3.44% of patients needed surgery for a third time (3 mastectomies).

In the IDC group, the radiological margins were positive in 24 cases (27.6%) and the lesion not found in one case (1.1%),

Table 1 Clinical and radiological characteristics.

	ISDC group <i>n</i> = 62 (%)	IDC group <i>n</i> = 87 (%)
<i>Mean age</i>	57.98 ± 11.86 [24–83]	60.1 ± 11.9 [26–84]
<i>Menopausal status</i>		
Post-menopausal	44 (71)	69 (79.3)
Not post-menopausal	18 (29)	18 (20.7)
<i>History of breast cancer</i>		
Personal	5 (8.1)	9 (10.3)
Family	11 (17.7)	23 (26.4)
<i>ACR BI-RADS</i>		
3	4 (6.5)	2 (2.3)
4	37 (59.7)	34 (39.1)
5	21 (33.9)	51 (58.6)
<i>Type of lesions</i>		
Mass	23 (37.1)	71 (81.6)
Microcalcifications	33 (53.2)	5 (5.7)
Mass and microcalcifications	4 (6.4)	7 (8)
Architectural distortion	2 (3.2)	4 (4.5)
Weight of the surgical specimen (grams)	54.79 [5–453]	47.18 [5–106]

Table 2 Characteristics of the lesions.

	ISDC group <i>n</i> = 62 (%)	IDC group <i>n</i> = 87 (%)
<i>Radiological size of the lesions</i>	14.65 ± 12.81 [2–81]	13.72 ± 8.04 [4.4–40]
≤ 10 mm	31	37
11–40 mm	29	48
> 40 mm	2	2
<i>Histological size</i>	14.65 ± 11.81 [0.5–70]	13.91 ± 6.84 [0–20]
≤ 10 mm	27	24
11 mm	31	60
> 40 mm	4	3
<i>Histological margins before re-excision</i>		
≤ 1 mm	22 (35.5)	17 (19.5)
2 mm	32 (51.6)	47 (54.0)
≥ 10 mm	8 (12.9)	23 (26.5)

Table 3 Evaluation of the diagnostic performance of surgical specimen radiographs.

	Se (%)	Sp (%)	PPV (%)	NPV (%)
ISDC	33.3	80	52.25	60.87
IDC	50	76.81	36	85.48

i.e. re-excision was necessary in the light of the radiographs of the surgical specimens in 29.9% of the lumpectomies. Forty patients (46%) underwent re-excision, including 15 systematically performed irrespective of the radiograph of the surgical specimen. Sixteen of the re-excisions were clear, including five performed systematically.

The rate of surgical revision in this group was 12.64%: eight revisions of the tumour bed and three mastectomies. In the three mastectomy specimens, two further IDC foci were found. In the tumour bed revisions, four patients had histologically positive and four had clear margins, including one patient whose surgical specimen with a clear margin contained another IDC focus. While one patient refused mastectomy, 4.83% of patients underwent surgery for a third time (3 mastectomies).

As far as the diagnostic performance of the radiographs of the surgical specimens is concerned, the sensitivity was 33% for ISDC and 50% for IDC (Table 3).

Good correlation between the radiological and histological size was found for the IDC group ($P=0.008$) but this was not so for the ISDC group ($P=0.42$) (Fig. 1).

Univariate statistical analysis showed a significant link, in the IDC group, between the histological margin and radiological status of the margins: if the margins were positive, the mean histological margin was 3.54 ± 3.27 mm, and if the margins were clear, it was 6.52 ± 4.83 mm. There was also a significant link in univariate analysis between the histological margins and the indication for re-excision given by the radiologist: where the latter was necessary, the mean margin was 3.34 ± 3.22 mm, where it was not necessary the margin was 6.59 ± 4.83 mm (Table 4).

Multivariate statistical analysis showed a significant link, in the ISDC group, between the histological margin and the radiological size (≤ 10 mm or > 10 mm) (Table 5).

Discussion

Conservative breast treatment by lumpectomy has become an acceptable alternative for treating subclinical breast

cancers, since randomised studies have shown that conservative treatment followed by radiotherapy produces overall survival equivalent to that of mastectomy [2,3].

It has been demonstrated that positive initial margins were correlated with the rate of local recurrence; hence the need to obtain clear margins [4,5]. One or more surgical revisions are sometimes necessary to obtain margins that are histologically adequate. However, that may alter the final cosmetic result and lead to the patient being subjected to further surgery [9].

A radiograph of the specimen is the current reference tool allowing the surgeon to ensure that the lesion has been excised. However, there is no consensus concerning the radiological margin to take into account to obtain a histologically clear margin.

In order to evaluate the diagnostic performance of surgical specimen radiographs, several authors have calculated their sensitivity, specificity, positive predictive value and negative predictive value [10–16]. Sensitivity varies between 27% and 76% depending on the value chosen for the radiological margin. Only two authors have studied a value of 10 mm for radiological margins: Mazouni et al. [10] and Britton et al. [14]. The latter, grouping together ISDC and IDC lesions, correlated the definitive histological margins with the radiological margins and calculated the sensitivity and the corresponding specificity. For a radiological margin of 10 mm they found sensitivity of 64% associated with a mean histological margin of 4 mm. The choice of a radiological margin of 10 mm may seem high but Britton et al. found that for a histological margin of 1 mm, a radiological margin was necessary of 9.5 mm, and for a histological margin greater than 5 mm a radiological margin was needed of 11 mm.

Although in our study the sensitivity of the surgical specimen radiographs was below the levels reported in the literature, our rate of surgical revision is still equivalent. Indeed, in conservative breast treatment, excluding surgical biopsies, the revision rate varies from 5% to 34% [12,13,17–19]. Such heterogeneity can be attributed to the methodology employed, varying from study to study. The radiographs of the surgical specimen and the margin chosen are not the only factors which can influence revision rates [13,20,21]. Some authors take a radiograph at two orthogonal incidences or combine it with extemporaneous examination of the surgical specimen [19]. Several methods for pinpointing the lesion are also possible [22]: locating it using ultrasound, mammography or MRI, using one or more metal markers, ^{99}Tc colloids (ROLL technique: radioisotope for occult lesion location), intraoperative ultrasonography

Table 4 Predictive factor for positive margins in the IDC group.

Factors	Histological margins (mm)		Univariate analysis <i>P</i>	Multivariate analysis <i>P</i>
	≤ 1	> 1		
<i>Radiological size of the lesions</i>				
≤ 10 mm	7	29	0.49	0.13
> 10 mm	10	41		
<i>Radiological margins before re-excision</i>				
Clear	9	53	0.01	0.25
Positive	8	17		

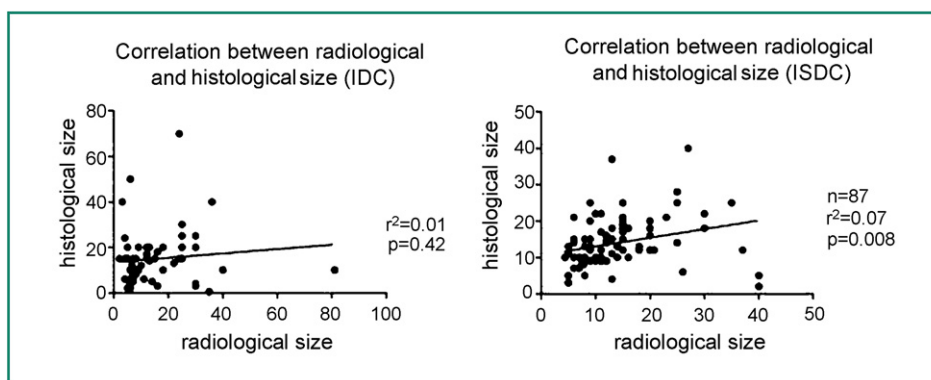


Figure 1. Correlation between radiological and histological size.

Factors	Histological margins (mm)		Univariate analysis	Multivariate analysis
	≤ 1	> 1	P	P
<i>Radiological size of the lesions</i>				
≤ 10 mm	13	18	0.15	0.02
> 10 mm	9	22		
<i>Radiological margins</i>				
Clear	5	29	0.42	0.89
Positive	17	11		

or using a stain (carbon black, blue stain) [12]. In our hospital, we prefer ultrasound-guided marking using a metal marker to aid the surgical approach whenever possible: insertion of an ultrasound-guided metal marker can follow a shorter, more direct path than when stereotactic guidance is used. Our high rate of ultrasound localisation, particularly among the ISDC group, is possible by inserting a collagen clip during the macrobiopsy, allowing ultrasound localisation up to 6 weeks after implantation.

Another point likely to improve the rate of revision is the surgeon’s ability to accurately pinpoint the lesion. In their systematic review, Lovrics et al. [20] found better results with the ROLL technique than with localisation using a metal marker. They suggested that this was related to the use of the gamma probe by the surgeon who can thus detect the lesion more easily. Producing a diagram, in addition to radiological images, explaining the metal marker’s pathway, its distance and position relative to the superficial surface, for example by cutaneous localisation, may improve pinpointing the lesion.

In our study, the revision rate is higher for ISDCs (27.41%) than for IDCs (12.64%), due to extensive ISDC lesions not being detected on the surgical specimen radiograph. We note in fact that no re-excision performed at the request of the radiologist produced clear margins in the ISDC group because the re-excision was still within the lesion. We know that the intraductal component, in particular an extensive ISDC, is a predictive factor for positive margins [17,18,23–26]. The radiological size of the ISDC is sometimes under-estimated [27,28] which can explain the poor diagnostic performances of the surgical specimen radiograph for some lesions. In their study involving 2564

patients who had had conservative breast treatment for ISDC, Thomas et al. [27] estimated that the size of the ISDC lesion had been under-estimated in 30% of cases. This under-estimation of size is not found in the literature for IDC, and may be related to the nature of the X-ray lesions (masses vs. microcalcifications), since in 75% of cases ISDC presents as microcalcifications [29]. Another element, which the retrospective character of this study prevented us from evaluating, is the type of mass (contours, regularity) and microcalcifications (shape, distribution). Graham et al. [16] indeed suggest that the type of lesion can modify the performance of the surgical specimen radiograph.

By separating the lesions into two different groups we were able to evaluate the factors predicting positive margins specific to each histology. Of all the points analysed, the significant predictive factors for positive margins in the histopathological examination are radiological size greater than 10 mm for ISDC and positive radiological margins for IDC. When our data are compared with those in the literature [10,11,17,18,23–26,30–32], as for the revision rate, there is heterogeneity concerning both the methodologies used and the lesions studied: some studies only concern ISDC, non-palpable lesions or all lesions treated conservatively, without giving details of their histological nature. Unlike the data in the literature, the histological size of the tumour did not prove to be significant in our study. The studies in the literature are indeed on conservative treatments not limited to non-palpable tumours, and study lesions of histological size differing from sizes in our study. To our knowledge, only Mazouni et al. [10] and Saarela et al. [11] have studied these predictive factors in a population of non-palpable lesions. Study of the radiological size of the lesions [10,11]

was significant for Saarela et al. This data from our study may have clinical implications for ISDC since it is known pre-operatively, unlike the histological size.

Conclusion

Excision of the target lesion was able to be well verified by using surgical specimen radiographs. However, despite a 10 mm threshold, radiography did not permit satisfactory evaluation of the status of the histological margins, in particular for ISDC, for which the surgical revision rate remains higher than for IDC. Elements other than the radiological margin need to be taken into account to improve management. Specific predictive factors of positive involvement of the histological margins, such as the radiological size of the lesion, must be confirmed in a prospective study, to guide the surgeon in management of this type of lesion. This would also overcome the bias of a retrospective study.

Disclosure of interest

The authors declare that they have no conflicts of interest concerning this article.

References

- [1] Lastier D, Salines E, Danzon A. Programme de dépistage du cancer du sein en France : résultats 2007–2008, évolutions depuis 2004. Saint-Maurice: Institut de veille sanitaire; 2011.
- [2] Fisher B, Anderson S, Bryant J, Margolese RG, Deutsch M, Fisher ER, et al. Twenty-year follow-up of a randomized trial comparing total mastectomy, lumpectomy, and lumpectomy plus irradiation for the treatment of invasive breast cancer. *N Engl J Med* 2002;347:1233–41.
- [3] Veronesi U, Cascinelli N, Mariani L, Greco M, Saccozzi R, Luini A, et al. Twenty-year follow-up of a randomized study comparing breast-conserving surgery with radical mastectomy for early breast cancer. *N Engl J Med* 2002;347:1227–32.
- [4] Leong C, Boyages J, Jayasinghe UW, Bilous M, Ung O, Chua B, et al. Effect of margins on ipsilateral breast tumor recurrence after breast conservation therapy for lymph node-negative breast carcinoma. *Cancer* 2004;100:1823–32.
- [5] Dunne C, Burke JP, Morrow M, Kell MR. Effect of margin status on local recurrence after breast conservation and radiation therapy for ductal carcinoma in situ. *J Clin Oncol* 2009;27:1615–20.
- [6] American College of Radiology (ACR). Illustrated Breast Imaging Reporting and Data System Atlas (BI-RADS atlas). 4th ed Reston (VA): American College of Radiology; 2003.
- [7] Agence nationale d'accréditation et d'évaluation de santé (ANAES). Recommandations pour la pratique clinique. Conduite à tenir devant une image mammographique infra-clinique anormale. Paris; 1999.
- [8] BI-RADS™ Première édition française. Éditions de la Société française de radiologie. 2001.
- [9] Al-Ghazal SK, Blamey RW, Stewart J, Morgan AA. The cosmetic outcome in early breast cancer treated with breast conservation. *Eur J Surg Oncol* 1999;25:566–70.
- [10] Mazouni C, Rouzier R, Balleyguier C, Sideris L, Rochard F, Delaloge S, et al. Specimen radiography as predictor of resection margin status in non-palpable breast lesions. *Clin Radiol* 2006;61:789–96.
- [11] Saarela AO, Rissanen TJ, ähteenäki KM, Soini Y, Haukipuro K, Kaarela O, et al. Wire-guided excision of non-palpable breast cancer: determinants and correlations between radiologic and histologic margins and residual disease in re-excisions. *Breast* 2001;10:28–34.
- [12] Ciccarelli G, Di Virgilio MR, Menna S, Garretti L, Ala A, Giani R, et al. Radiography of the surgical specimen in early stage breast lesions: diagnostic reliability in the analysis of the resection margins. *Radiol Med* 2007;112:366–76.
- [13] McCormick JT, Keleher AJ, Tikhomirov VB, Budway RJ, Caushaj PF. Analysis of the use of specimen mammography in breast conservation therapy. *Am J Surg* 2004;188:433–6.
- [14] Britton PD, Sonoda LI, Yamamoto AK, Koo B, Soh E, Goud A. Breast surgical specimen radiographs: how reliable are they? *Eur J Radiol* 2011;79:245–9.
- [15] Foucé CJ, Tabareau F, Michenet P, Lebas P, Simon EG. Specimen radiography assessment of surgical margins status in subclinical breast carcinoma: a diagnostic study. *J Gynecol Obstet Biol Reprod (Paris)* 2011;40:314–22.
- [16] Graham RA, Homer MJ, Sigler CJ, Safaii H, Schmid CH, Marchant DJ, et al. The efficacy of specimen radiography in evaluating the surgical margins of impalpable breast carcinoma. *AJR Am J Roentgenol* 1994;162:33–6.
- [17] Kurniawan ED, Wong MH, Windle I, Rose A, Mou A, Buchanan M, et al. Predictors of surgical margin status in breast-conserving surgery within a breast screening program. *Ann Surg Oncol* 2008;15:2542–9.
- [18] Smitt MC, Horst K. Association of clinical and pathologic variables with lumpectomy surgical margin status after preoperative diagnosis or excisional biopsy of invasive breast cancer. *Ann Surg Oncol* 2007;14:1040–4.
- [19] Chagpar A, Yen T, Sahin A, Hunt KK, Whitman GJ, Ames FC, et al. Intraoperative margin assessment reduces reexcision rates in patients with ductal carcinoma in situ treated with breast-conserving surgery. *Am J Surg* 2003;186:371–7.
- [20] Lovrics PJ, Cornacchi SD, Vora R, Goldsmith CH, Kahn moui K. Systematic review of radioguided surgery for non-palpable breast cancer. *Eur J Surg Oncol* 2011;37:388–97.
- [21] Köhler J, Krause B, Grunwald S, Thomas A, Köhler G, Schwesinger G, et al. Ultrasound and mammography guided wire marking of non-palpable breast lesions: analysis of 741 cases. *Ultraschall Med* 2007;28:283–90.
- [22] Pleijhuis RG, Graafland M, de Vries J, Bart J, de Jong JS, van Dam GM. Obtaining adequate surgical margins in breast-conserving therapy for patients with early-stage breast cancer: current modalities and future directions. *Ann Surg Oncol* 2009;16:2717–30.
- [23] Aziz D, Rawlinson E, Narod SA, Sun P, Lickley HLA, McCready DR, et al. The role of reexcision for positive margins in optimizing local disease control after breast-conserving surgery for cancer. *Breast J* 2006;12:331–7.
- [24] Dillon MF, Hill ADK, Quinn CM, McDermott EW, O'Higgins N. A pathologic assessment of adequate margin status in breast-conserving therapy. *Ann Surg Oncol* 2006;13:333–9.
- [25] Lovrics PJ, Cornacchi SD, Farrokhyar F, Garnett A, Chen V, Franic S, et al. The relationship between surgical factors and margin status after breast-conservation surgery for early stage breast cancer. *Am J Surg* 2009;197:740–6.
- [26] Miller AR, Brandao G, Prihoda TJ, Hill C, Cruz Jr AB, Yeh IT. Positive margins following surgical resection of breast carcinoma: analysis of pathologic correlates. *J Surg Oncol* 2004;86:134–40.
- [27] Thomas J, Evans A, Macartney J, Pinder SE, Hanby A, Ellis I, et al. Radiological and pathological size estimations of pure ductal carcinoma in situ of the breast, specimen handling and the influence on the success of breast conservation surgery: a review of 2564 cases from the Sloane Project. *Br J Cancer* 2010;102:285–93.

- [28] Holland R, Hendriks JH, Vebeek AL, Mravunac M, Schuurmans Stekhoven JH. Extent, distribution, and mammographic/histological correlations of breast ductal carcinoma in situ. *Lancet* 1990;335:519–22.
- [29] Gajdos C, Tartter PI, Bleiweiss IJ, Hermann G, de Csepe J, Estabrook A, et al. Mammographic appearance of nonpalpable breast cancer reflects pathologic characteristics. *Ann Surg* 2002;235:246–51.
- [30] Cabioglu N, Hunt KK, Sahin AA, Kuerer HM, Babiera GV, Singletary SE, et al. Role for intraoperative margin assessment in patients undergoing breast-conserving surgery. *Ann Surg Oncol* 2007;14:1458–71.
- [31] Chagpar AB, Martin 2nd RCG, Hagendoorn LJ, Chao C, McMasters KM. Lumpectomy margins are affected by tumor size and histologic subtype but not by biopsy technique. *Am J Surg* 2004;188:399–402.
- [32] Schiller DE, Le LW, Cho BCJ, Youngson BJ, McCready DR. Factors associated with negative margins of lumpectomy specimen: potential use in selecting patients for intraoperative radiotherapy. *Ann Surg Oncol* 2008;15:833–42.