

Relative Amounts of Keratin 17 Are Higher Than Those of Keratin 16 in Hair-Follicle-Derived Tumors in Comparison with Nonfollicular Epithelial Skin Tumors

Ken-ichi Yoshikawa, Yohtaro Katagata, and Shigeo Kondo

Department of Dermatology, Yamagata University School of Medicine, Yamagata, Japan

Specimens of trichilemmal cyst, malignant trichilemmoma, keratoacanthoma, and epidermal cyst were examined to characterize keratin peptides in hair-follicle-derived tumors. Keratins were extracted from the specimens and analyzed by two-dimensional gel electrophoresis and densitometry; the results were then compared with those for normal epidermis, the outer root sheath of hair follicles, psoriatic epidermis, and various nonfollicular cutaneous epithelial tumors. The specific nonfollicular tumors examined were squamous cell carcinoma, Bowen disease, actinic keratosis, eccrine porocarcinoma, and sebaceous carcinoma. Immunohistochemistry also was performed with a few anti-keratin monoclonal antibodies. As a general rule, K6 and K16

were expressed in hyperproliferative conditions, such as epidermal tumors, and K17 was coexpressed in the same lesions. The ratio of K16 to K17 in many epithelial skin tumors has been unclear until now. K17 content exceeded K16 content in most follicular tumors, whereas in almost all the nonfollicular tumors and the psoriatic epidermis, K17 levels were less than or about equal to K16 levels. There was a significant difference in the ratio of K16 to K17 between follicular and nonfollicular skin tumors. These results indicate that alterations in the content of these keratins may be associated with follicular differentiation. Key words: follicular tumors/two-dimensional gel electrophoresis/quantitative analysis. *J Invest Dermatol* 104:396-400, 1995

Keratins, a type of intermediate filament, are the major structural proteins of various epithelial cells [1]. Thus far, at least 20 different keratin peptides (K1-K20) are known to be expressed in diverse human epithelia [1,2]. The expression of each keratin is regulated by various factors, such as cell type, stage of differentiation, neoplastic change, etc. [3].

Several studies of the keratin peptide composition of epithelial skin tumors have been reported [4-10]. There have also been a few biologic studies of keratin in adnexal skin tumors derived from sweat glands [5] and hair follicles [10]. Recently, as the first in a series of experiments, we reported an analysis of keratin composition in sebaceous carcinomas, performed by two-dimensional gel electrophoresis (2-DE) [11]. Despite numerous investigations, no tumor-specific keratin peptides have yet been found in epithelial skin tumors because of the biologic heterogeneity of such tumors. We have discovered, however, that in terms of the ratio of K16 to K17, keratin expression in follicular tumors is different from that in nonfollicular tumors derived from other skin epithelia. In this study, we systematically compared the keratins of diverse epithelial skin tumors of different origins by performing 2-DE, densitometry, and immunohistochemistry. Interesting results were obtained,

showing larger amounts of K17 than of K16 in follicular tumors specifically.

MATERIALS AND METHODS

Tissues Lesion-tissue samples from various epithelial skin tumors and psoriatic epidermis were obtained from patients admitted to our hospital. Controls consisted of normal epidermis from eight different body sites (excluding palm and sole epidermis) and outer root sheaths (ORS) of 15 scalp hair follicles taken from the edge of surgical specimens. Small samples of unfixed material from each tumor were used for keratin extraction. A part of each tumor was frozen for immunohistochemistry. The remaining tumor material was fixed in formalin and embedded in paraffin for histologic diagnosis. Hematoxylin-and-eosin-stained sections were prepared from all tumors, and the tumors were classified using a standard histology textbook [12]. The follicular and nonfollicular skin tumors used in this study are listed in **Table I**.

The individual tumors, the lesional tissues of psoriatic epidermis, and the normal epidermis were prepared from tissue sections by trimming under a stereomicroscope to avoid contamination by surrounding connective tissue and/or overlying epidermis. For trichilemmal cysts and epidermal cysts, cyst wall epithelium was used for keratin extraction. The ORS were prepared from plucked anagen scalp hair follicles and separated from the hair shaft and bulb, in phosphate-buffered saline, under a stereomicroscope.

Extraction of Keratins Keratin extraction was performed by the method of Achtstaetter *et al* [13]. Minced tissues were washed with a high-salt buffer containing 1.5 M KCl, 140 mM NaCl, 0.5% Triton X-100, 5 mM ethylenediamine tetraacetic acid, and 10 mM Tris-HCl (pH 7.6); they were then sonicated and centrifuged at 4°C for 20 min (10,000 × *g*, three times). The final residues were sonicated and incubated with 100 μl of 10 M urea (ultrapure), 5% Nonidet P-40, 5% 2-mercaptoethanol, and 2% Am-

Manuscript received May 5, 1994; revised November 18, 1994; accepted for publication November 28, 1994.

Reprint requests to: Dr. Ken-ichi Yoshikawa, Department of Dermatology, Yamagata University School of Medicine, 2-2-2, Iida-Nishi, Yamagata City, Yamagata 990-23 Japan.

Abbreviation: 2-DE, two-dimensional gel electrophoresis.

Table I. Quantitative Comparison of the Ratio of K16 to K17 by Densitometry in Follicular Tumors, Nonfollicular Epithelial Skin Tumors, and Psoriatic Epidermis

Skin Tumors and Psoriatic Epidermis	Group by Ratios of K16 to K17 ^a		Ratio of K14:K16:K17 in Representative Cases
	K16 < K17 ^b	K16 ≥ K17 ^c	
Follicular tumors			
Trichilemmal cyst (n = 2)	2		1:0.1:1.1
Malignant trichilemmoma (n = 2)	2		1:0.16:0.53
Keratoacanthoma (n = 8)	4	4	1:0.21:0.56, 1:0.26:0.22
Epidermal cyst (n = 2)	2		1:1.1:36
Total (n = 14) ^d	10	4	
Nonfollicular epithelial skin tumors			
Squamous cell carcinoma (n = 3)	1	2	1:0.16:0.78, 1:0.21:0.03
Bowen disease (n = 6)		6	1:3.5:0.35
Actinic keratosis (n = 5)		5	1:0.37:0.29
Ecrrine porocarcinoma (n = 3)	1	2	1:1.4:6.9, 1:1.23:1.32
Sebaceous carcinoma ^e (n = 2)		2	1:4.1:0.78
Total (n = 19) ^f	2	17	
Nontumorous hyperproliferative epidermal disease			
Psoriatic epidermis (n = 10) ^g		10	1:0.28:0.13

^a Numbers of cases classified into groups according to the ratio of K16 to K17.

^b K17 exceeded K16 in quantity.

^c K16 was higher than or almost equal to K17.

^d versus ^f: $p < 0.001$ (χ^2 test for independence). ^d versus ^g: $p < 0.001$ (Fisher exact probability test).

^e The same samples were reported recently [11].

pholine (pH 3.5–10) for 12 h at 37°C. After centrifugation for 20 min (10,000 × g, 30°C), the soluble supernatant was subjected to 2-DE.

2-DE The extracted keratin was analyzed by 2-DE, using nonequilibrium pH gradient gel electrophoresis in the first dimension [14] and sodium dodecylsulfate-polyacrylamide gel electrophoresis with 12% acrylamide in the second dimension [15]. Gels were stained with Coomassie brilliant blue R-250. To identify the expressed keratin peptides, 3-phosphoglycerokinase, bovine serum albumin, and rabbit α -actin were employed at the same time as standard proteins.

Quantitative Analysis of the Ratio of K16 to K17 The relative amounts of K16 and K17 to K14 in the individual tumors, psoriatic epidermis, and ORS were analyzed by LHB 222, Ultra Scan XL, enhanced laser densitometry (LKB, Bromma, Sweden). The amounts of K16 and K17 were estimated relative to those of K14 because K14 was usually discrete and was present in all samples. The relative amounts of these keratins were given by the density multiplied by the total area of each keratin spot stained with Coomassie brilliant blue. Each sample was then classified into two groups according to the ratio of these keratins: 1) the amounts of K17 were larger than those of K16 (over 1.1 times as much as K16) (K16 < K17), and 2) the amounts of K16 were greater than or about equal to those of K17 (less than 1.1 times as much as K16) (K16 ≥ K17). Statistical analysis was performed by the χ^2 test for independence and Fisher exact probability test.

Immunohistochemistry From some representative samples of the tumors, frozen sections were cut, air dried, and fixed in acetone at 4°C. After washing in phosphate-buffered saline, endogenous peroxidase was blocked by 0.001% phenylhydrazine hydrochloride at 37°C. Sections were incubated overnight at 4°C with the following primary antibodies: K₁₇E3, specific for K17 (Progen Biotechnik GmbH, Heidelberg, Germany) [16]; and K8.12, specific for K13, K15, and K16 (Sigma, St. Louis, MO) [4]. Sections were rinsed in phosphate-buffered saline, incubated with peroxidase-conjugated anti-mouse immunoglobulin rabbit serum (Dako Corp.) for 15 min at room temperature, and washed again in phosphate-buffered saline. The reactions were visualized using 3,3'-diaminobenzidine and H₂O₂. Sections were then washed in water, counterstained with 1% methyl green, dehydrated, cleaned, and mounted.

RESULTS

Table I compares the ratios of K16 to K17 in the various skin tumors and psoriatic epidermis.

ORS Contain Similar Amounts of K16 and K17, and Normal Epidermis Does Not Contain These Keratins In normal epidermis from various body sites (i.e., the thigh, lower leg, back, abdomen, and forearm), K1, K5, K10, K11, and K14 were usually present, and K2 and K15 were sometimes found in small amounts (**Fig 1a**). K16 and K17 were not detected in normal epidermis. In

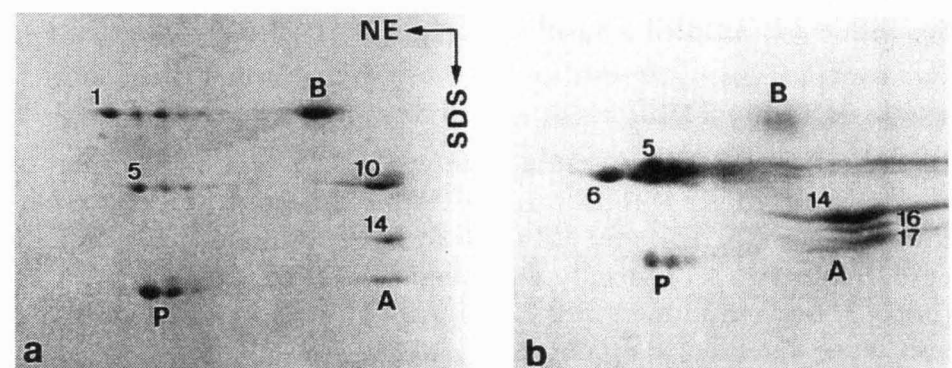


Figure 1. ORS contain similar amounts of K16 and K17, and normal epidermis does not contain these keratins. 2-DE of keratin proteins in normal epidermis (46-year-old woman, thigh) (a) and ORS of anagen scalp hair follicles (66-year-old woman) (b). Standard proteins used: P, 3-phosphoglycerokinase (pI 7.4, Mr 43 kDa); B, bovine serum albumin (pI 6.35, Mr 68 kDa); A, rabbit α -actin (pI 5.4, Mr 42 kDa). Separation in the first dimension, nonequilibrium pH gradient gel electrophoresis (NE) (right to left); in the second dimension, sodium dodecylsulfate-polyacrylamide gel electrophoresis (SDS). The ratio of K14:K16:K17 in the ORS was 1:0.16:0.22 (6.25:1:1.38).

the ORS of scalp hair follicles, K5, K6, K14, K16, and K17 were present (**Fig 1b**), and the ratio of K16 to K17 was 1:1.38 (**Fig 1b**).

Relative Amounts of K17 Are Higher Than Those of K16 in Hair-Follicle-Derived Tumors Trichilemmal cyst and malignant trichilemmoma, both of which are widely assumed to be derived from hair follicle ORS [17,18], showed similar keratin patterns. Trichilemmal cyst exhibited intense expression (large amounts) of K17 and also expressed K1, K10, and K16 (all in trace amounts) and K5, K6, and K14 (all in large amounts) (**Fig 2a**). Malignant trichilemmoma contained large amounts of K17 and small amounts of K16 (**Fig 2b**). K1, K10, and K11 (all in small amounts) and K5, K6, and K14 (all in large amounts) were also present in malignant trichilemmoma (**Fig 2b**).

Keratoacanthoma and epidermal cyst, both of which are regarded as derived from follicular infundibulum [19,20], had keratin patterns resembling those of trichilemmal cyst and malignant trichilemmoma. The keratin pattern of keratoacanthoma was characterized by a low level (six of eight cases) or lack (two of eight) of the K1 and K10 components. With respect to the ratio of K16 to K17, K17 exceeded K16 in four of the eight keratoacanthomas (**Fig 2c**).

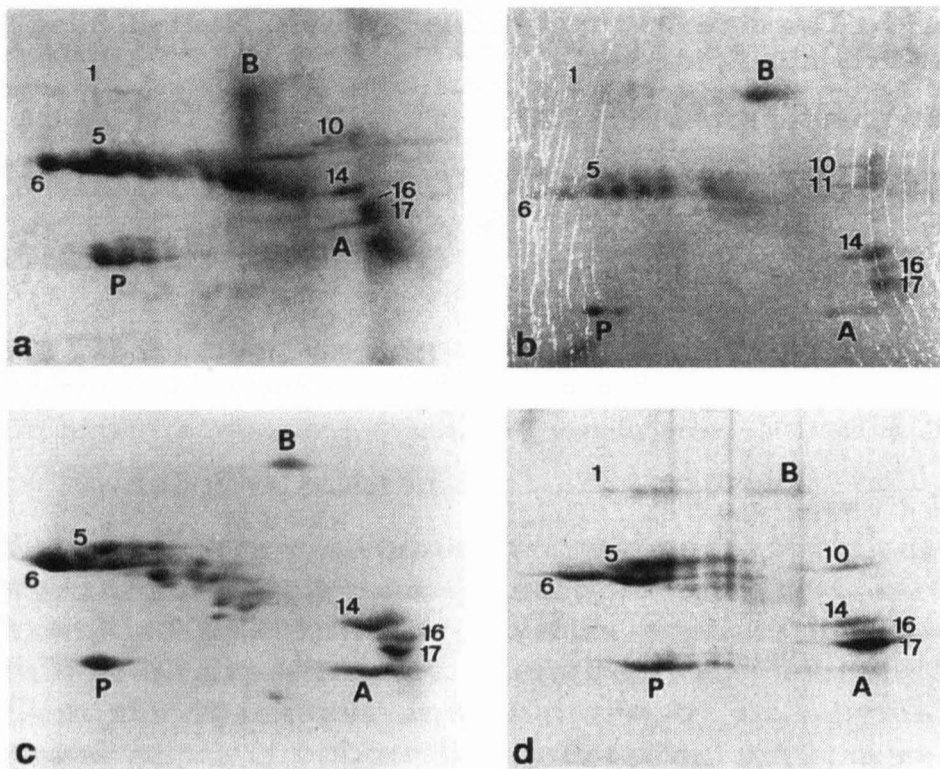


Figure 2. Relative amounts of K17 are higher than those of K16 in follicular tumors. 2-DE of keratins in trichilemmal cyst (66-year-old woman, scalp) (a), malignant trichilemmoma (79-year-old woman, forehead) (b), keratoacanthoma (71-year-old man, nose) (c), and epidermal cyst (28-year-old man, right ankle) (d). The ratios of K14:K16:K17 in these cases were 1:0.1:1.1 (a), 1:0.16:0.53 (b), 1:0.21:0.56 (c), and 1:1.1:36 (d). Separation and standard proteins as in Fig 1.

In the remaining four keratoacanthomas, K16 was higher than or about equal to K17. The other keratins detected in keratoacanthoma were K5, K6, and K14 (all in large amounts) (Fig 2d). In epidermal cyst, K17 largely exceeded K16 (Fig 2d). K1 and K10 (both in trace amounts) and K5 and K14 (both in large amounts) also were detected in epidermal cyst (Fig 2d).

Relative Amounts of K16 Are Higher Than or About Equal to Those of K17 in Nonfollicular Epithelial Skin Tumors and Psoriatic Epidermis

The keratin patterns in nonfollicular skin tumors (squamous cell carcinoma, Bowen disease, actinic keratosis, eccrine porocarcinoma, and sebaceous carcinoma) and psoriatic epidermis were different from those in the follicular tumors with respect to the proportions of K16 and K17.

Squamous cell carcinoma contained K1, K10, K16, and K17 (in variable amounts) and K5, K6, and K14 (all in large amounts); K16 was greater than K17 in one of the three cases (Fig 3a). In one of the remaining two well-differentiated squamous cell carcinomas, K16 was higher than K17; in the third case, K17 was greater than K16.

In all cases of Bowen disease and actinic keratosis, K16 was higher than or about equal to K17 (Fig 3b,c). These tumors also displayed K1, K10, and K11 (all in variable amounts) and K5, K6, and K14 (all in large amounts).

The ratio of K16 to K17 in eccrine porocarcinoma also differed from that in follicular tumors. In one case of eccrine porocarcinoma, both K16 and K17 were present in almost equally large amounts (Fig 3d). The other keratins found in these lesions were K5, K6, and K14, whereas components K1 and K10 were reduced (or lacking) (Fig 3d). In one of the remaining two eccrine porocarcinomas, both K16 and K17 were present in large amounts; in the third case, amounts of K17 were higher than those of K16.

One of two sebaceous carcinomas contained both K16 and K17 in considerable amounts, together with K5, K6, and K14, and low levels of K1 and K10. The other lesion contained higher amounts of K16 than of K17, in addition to containing K1, K5, K6, K8, K10, K14, K15, and K19 (for details, see [11]).

Psoriatic epidermis, which was marked by hyperproliferative keratinocytes, had large amounts of K16 and K17, and K17 was always present in amounts less than or about equal to those of K16

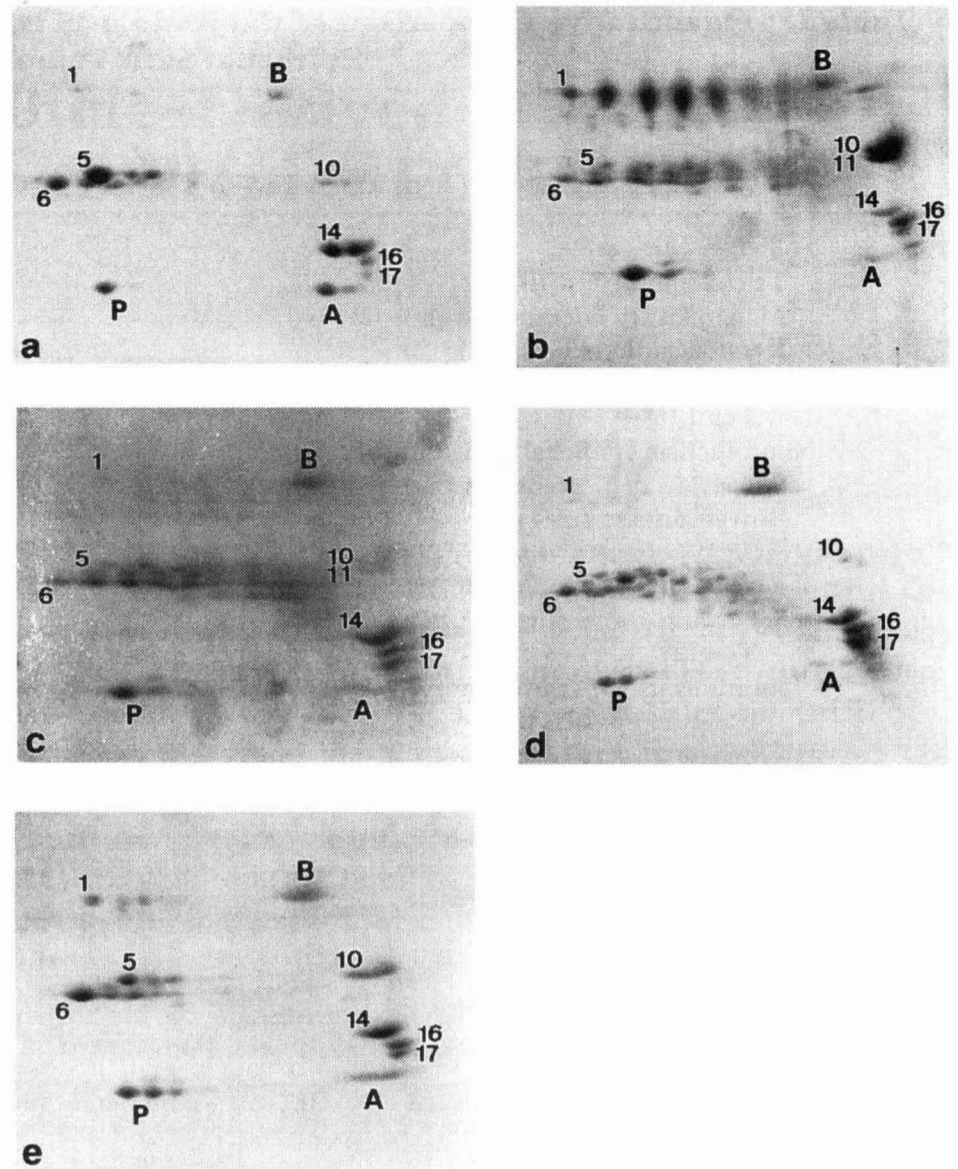


Figure 3. Relative amounts of K16 are higher than or about equal to those of K17 in nonfollicular epithelial skin tumors and psoriatic epidermis. 2-DE of keratins in squamous cell carcinoma (74-year-old woman, right preauricle; moderately differentiated type) (a), Bowen disease (76-year-old man, left thigh) (b), actinic keratosis (76-year-old man, right hand, dorsal; hypertrophic type) (c), eccrine porocarcinoma (75-year-old woman, left cheek) (d), and lesional psoriatic epidermis (74-year-old man, back) (e). The ratios of K14:K16:K17 in these cases were 1:0.21:0.03 (a), 1:3.5:0.35 (b), 1:0.37:0.29 (c), 1:1.23:1.32 (d), and 1:0.28:0.13 (e). Separation and standard proteins as in Fig 1.

(Fig 3e). K1, K5, K6, K10, K11, and K14 also were present in psoriatic epidermis.

Nonfollicular tumors and psoriatic epidermis were significantly different from follicular tumors in the ratio of K16 to K17 ($p < 0.001$) (Table I).

Immunohistochemistry The inner several layers of the cyst wall of trichilemmal cyst (the same case as shown in Fig 2a) were positive for K_s17.E3 (Fig 4), whereas K8.12 showed positive reactions only in a part of the inner two or three layers of the cyst



Figure 4. K_s17.E3 (specific for K17) shows positive reactions in the large areas of the tumor cells of trichilemmal cyst. Inner several layers of the cyst wall reacted strongly to K_s17.E3. This tumor was the same case as shown in Fig 2a. Bar, 50 μ m.

wall. The tumor cells of keratoacanthoma (one case) and squamous cell carcinoma (one case), both of which showed similar amounts of K16 and K17, were stained diffusely by K_s17.E3 and K8.12.

DISCUSSION

It is generally agreed that K16, a partner of K6, is expressed in hyperproliferative epithelial cells [21]. Moreover, K17 is known to be induced in such conditions [22]. As shown in this study, K6, K16, and K17 were detected in almost all epithelial skin tumors examined and were also found in psoriatic epidermis, which is marked by nontumorous hyperproliferative keratinocytes.

However, the main point of this investigation was the difference in the ratios of K16 to K17 between follicular and nonfollicular tumors. Our experimental results revealed the following interesting difference between the tumor groups. In follicular tumors, such as trichilemmal cyst, malignant trichilemmoma, and epidermal cyst, K17 was always much greater than K16. On the other hand, such keratin patterns were virtually absent in most nonfollicular tumors and in psoriatic epidermis. It follows from these results that relatively larger amounts of K17 than those of K16 were specific to follicular tumors, and the results thus indicate that alterations in these keratins are associated with follicular differentiation.

No biochemical analyses of keratins by 2-DE have been reported in trichilemmal cyst or malignant trichilemmoma. An immunohistochemical study of keratins in trichilemmal cyst has been reported [23], but the amounts of K16 and K17 were not examined. Assessment of the ratio of K16 to K17 by immunohistochemistry is to some extent useful if proper combinations of anti-keratin monoclonal antibodies are used. For example, K_s17.E3 (specific for K17) showed positive reactions in larger areas of the tumor cells of trichilemmal cyst than did K8.12 (specific for K13, K15, and K16) (Fig 4), which was consistent with the results of 2-DE and densitometry. However, this method alone would not provide quantitative information for various types of tumors. Moreover, it is difficult to estimate the ratio of K16 to K17 by sodium dodecylsulfate-polyacrylamide gel electrophoresis alone because of the similar molecular weights (Mr) and isoelectric points (pI) of K16 (Mr 48,000; pI 5.1) and K17 (Mr 46,000; pI 5.1) and because of the possible presence of proteins of similar molecular weight other than K16 and K17. 2-DE systems are thus more suitable for identifying these keratins and provide quantitative data by densitometry.

Trichilemmal cyst and malignant trichilemmoma are regarded as skin tumors derived from the ORS of hair follicles [17,18]. Heid *et al* [24] reported in an immunohistochemical study of hair follicles that K17 was distributed distinctively in ORS. Another study [22] has revealed that ORS epithelium contains both K16 and K17 in large amounts. Our keratin analysis of ORS showed similar amounts of K16 and K17 (the ratio of K16 to K17 was 1:1.38). It is unclear why the ratio of K16 to K17 is different in normal ORS and in tumors differentiated toward ORS, i.e., trichilemmal cyst and malignant trichilemmoma. Such differences may be due to tumorous transformation, and the level of differentiation is thought to be different in these two epithelia. Therefore, the expression of K17 does not always reflect direct differentiation toward ORS.

Keratoacanthoma and epidermal cyst are assumed to be derived from the infundibulum of hair follicles [19,20]. To our knowledge, there have been no analyses of the keratin composition in epidermal cyst by 2-DE. Here, we performed a keratin analysis in epidermal cyst and found a large increase in K17 in comparison with K16, consistent with the findings in trichilemmal cyst and malignant trichilemmoma. Moll *et al* [8] reported a keratin study of keratoacanthomas by 2-DE. In their one case, K16 was found to be slightly higher than K17. In our present study of keratoacanthoma, however, we found that K17 greatly exceeded K16 in four of eight cases, and K16 was higher than or almost equal to K17 in the other four. These inconsistent results may reflect the similarity in histologic structure of keratoacanthoma and squamous cell carcinoma, or they may be due to differences in the growth stage of the keratoacanthoma. We conclude from such results that keratoacanthoma has characteristics of both follicular differentiation and a

differentiated stage that resembles squamous cell carcinoma. We therefore believe that follicular tumors differentiated toward ORS and the infundibulum of hair follicles are widely characterized by a predominant expression of K17.

K16 and K17 are expressed not only in tumor lesions but also in various nontumorous skin conditions, such as during wound healing [21], in verruca vulgaris [8], in condyloma acuminatum [8], and in psoriatic epidermis (as shown in Fig 3e). However, the level of K17 is usually lower than that of K16 in such conditions; i.e., the keratin patterns in these conditions are quite different from those in follicular tumors. We therefore conclude that a higher level of K17 than of K16 is a useful marker for follicular tumors.

With respect to the expression of K1 and K10, we found that these keratins were absent in ORS and that they had decreased (or disappeared) in all follicular tumors. Indeed, these observations reveal one of the characteristics of follicular tumors. However, such changes also occurred in squamous cell carcinoma (Fig 3a), actinic keratosis (Fig 3c), eccrine porocarcinoma (Fig 3d), active lesional psoriatic epidermis (Fig 3e), and poorly differentiated squamous cell carcinoma [8,25]. Thus, the reduction or absence of K1 and K10 is not specific to follicular tumors.

It is also of great interest that K6, a partner of K16, was always present in large amounts with considerable amounts of K17, despite the trace amounts of K16 in trichilemmal cyst (Fig 2a) and epidermal cyst (Fig 2e). Therefore, pair keratins were not expressed in the same amounts. These findings suggest that the expression of abnormal amounts of individual members of keratin pairs is due to tumorous changes.

Some keratin analyses have suggested that the origin of basal cell carcinoma is closely related to hair follicles [6,26], although views on the derivation of basal cell carcinoma are divergent [27-29]. The keratin analyses [6,26] were based on observations of specific K17 expression. These facts are also the same to a considerable extent for the follicular tumors examined in this study. The prominent expression of K17 in human haarscheiben keratinocytes has been shown recently by Moll *et al* [30], indicating that haarscheiben are related to hair follicles. Thus, K17 may play an important role in differentiation toward hair follicles. The high ratio of K17 to K16 also may be a suitable biologic marker for distinguishing follicular tumors from other epithelial skin tumors. However, future studies will be required to confirm this.

There have been no general comparative studies on characterization of K17 in follicular and nonfollicular tumors. Here, we demonstrated by 2-DE, densitometry, and immunohistochemistry that predominant expression of K17, in comparison with K16, was found specifically in follicular skin tumors and not in various nonfollicular epithelial skin tumors.

We thank Dr. Yutaka Hozumi for his help with the photographic work.

REFERENCES

1. Moll R, Franke WW, Schiller DL, Geiger B, Krepler R: The catalog of human cytokeratins: patterns of expression in normal epithelia, tumors and cultured cells. *Cell* 31:11-24, 1982
2. Moll R, Schiller DL, Franke WW: Identification of protein IT of the intestinal cytoskeleton as a novel type I cytokeratin with unusual properties and expression patterns. *J Cell Biol* 111:567-580, 1990
3. Cooper D, Schermer A, Sun T-T: Classification of human epithelia and their neoplasms using monoclonal antibodies to keratins: strategies, applications, and limitations. *Lab Invest* 52:243-256, 1985
4. Huszar M, Gigi-Leitner O, Moll R, Franke WW, Geiger B: Monoclonal antibodies to various acidic (type I) cytokeratins of stratified epithelia. Selective markers for stratification and squamous cell carcinomas. *Differentiation* 31:141-153, 1986
5. Moll I, Moll R: Comparative cytokeratin analysis of sweat gland ducts and eccrine poromas. *Arch Dermatol Res* 283:300-309, 1991
6. Moll R, Franke WW, Volc-Platzer R: Different keratin polypeptides in epidermis and other epithelia of human skin: a specific cytokeratin of molecular weight 46,000 in epithelia of the pilosebaceous tract and basal cell carcinomas. *J Cell Biol* 95:285-295, 1982

7. Moll R, Krepler R, Franke WW: Complex cytokeratin polypeptide patterns observed in certain human carcinomas. *Differentiation* 23:256-269, 1983
8. Moll R, Moll I, Franke WW: Difference of expression of cytokeratin polypeptides in various epithelial skin tumors. *Arch Dermatol Res* 276:349-363, 1984
9. Moll I, Moll R: Cells of extramammary Paget's disease express cytokeratins different from those of epidermal cells. *J Invest Dermatol* 84:3-8, 1985
10. Moll I, Heid H, Moll R: Cytokeratin analysis of pilomatrixoma: changes in cytokeratin-type expression during differentiation. *J Invest Dermatol* 91:251-257, 1988
11. Yoshikawa K, Katagata Y, Kondo S: Characterization of keratin peptide in sebaceous carcinomas. *Arch Dermatol Res* 285:241-244, 1993
12. Lever WF, Schaumburg-Lever G: *Histopathology of the Skin. 7th Ed.* Lippincott, Philadelphia, 1990
13. Achtstaetter T, Hatzfeld M, Quinlan RA, Parmelee DC, Franke WW: Separation of cytokeratin polypeptides by gel electrophoretic and chromatographic technique and their identification by immunoblotting. *Methods Enzymol* 134:355-371, 1986
14. O'Farrell PZ, Goodman HM, O'Farrell PH: High resolution two-dimensional electrophoresis of basic as well as acidic proteins. *Cell* 12:1133-1142, 1977
15. Thomas JO, Kornberg RD: An octamer of histones in chromatin and free in solution. *Proc Natl Acad Sci USA* 72:2626-2630, 1975
16. Troyanovsky SM, Guelstein VI, Tchipsheva TA, Krutovskikh VA, Bannikov GA: Patterns of expression of keratin 17 in human epithelia: dependency on cell position. *J Cell Sci* 93:419-426, 1989
17. Pinkus H: "Sebaceous cysts" are trichilemmal cysts. *Arch Dermatol* 99:544-555, 1969
18. Headington JT: Tumors of the hair follicle: a review. *Am J Pathol* 85:480-514, 1976
19. Ghadially FN: The role of the hair follicle in the origin and evolution of some cutaneous neoplasms of man and experimental animals. *Cancer* 14:801-816, 1961
20. Brownstein MH: Hybrid cyst: a combined epidermoid and trichilemmal cyst. *J Am Acad Dermatol* 9:872-875, 1983
21. Weiss RA, Eichner R, Sun T-T: Monoclonal antibody analysis of keratin expression in epidermal diseases: a 48- and 56-kdalton keratin as molecular markers for hyperproliferative keratinocytes. *J Cell Biol* 98:1397-1406, 1984
22. Stark HJ, Breitskreutz D, Limat A, Bowden P, Fusening NE: Keratin of the human hair follicle: "hyperproliferative" keratins consistently expressed in outer root sheath cells in vivo and in vitro. *Differentiation* 35:236-248, 1987
23. Broekaert D, Goeman L, Ramaekers FCS, Van Muijen GNP, Eto H, Lane EB, Leigh IM, De Bersaques J, Coucke P: An investigation of cytokeratin expression in skin epithelial cysts and some uncommon types of cystic tumours using chain-specific antibodies. *Arch Dermatol Res* 282:383-391, 1990
24. Heid HW, Moll I, Franke WW: Patterns of expression of trichocytic and epithelial cytokeratins in mammalian tissues. I. Human and bovine hair follicles. *Differentiation* 37:137-157, 1988
25. Markey AC, Lane EB, Churchill LJ, MacDonald DM, Leigh IM: Expression of simple epithelial keratins 8 and 18 in epidermal neoplasia. *J Invest Dermatol* 97:763-770, 1991
26. Markey AC, Lane EB, MacDonald DM, Leigh IM: Keratin expression in basal cell carcinomas. *Br J Dermatol* 126:154-160, 1992
27. Pinkus H: Premalignant fibroepithelial tumors of the skin. *Arch Dermatol Syph* 67:598-615, 1953
28. Lever WF, Schaumburg-Lever G: *Histopathology of the Skin. 7th Ed.* Lippincott, Philadelphia, 1990, pp 622-634
29. Kariniemi AL, Holthofer H, Vartio T, Virtanen I: Cellular differentiation of basal cell carcinoma studied with fluorescent lectins and cytokeratin antibodies. *J Cutan Pathol* 11:541-548, 1984
30. Moll I, Troyanovsky SM, Moll R: Special program of differentiation expressed in keratinocytes of human haarscheiben: an analysis of individual cytokeratin polypeptides. *J Invest Dermatol* 100:69-76, 1993