



# Bilateral avascular necrosis of the femoral head due to the use of heroin: A case report



Okan Ozkunt\*, Kerim Sariyılmaz, Mustafa Sungur, Ferhat Ilen, Fatih Dikici

Department of Orthopedics and Traumatology, Acibadem Atakent University Hospital, Istanbul, Turkey

## ARTICLE INFO

### Article history:

Received 19 August 2015

Received in revised form 7 October 2015

Accepted 31 October 2015

Available online 11 November 2015

### Keywords:

Heroin

Avascular necrosis

Arthroplasty

## ABSTRACT

**INTRODUCTION:** Femoral head avascular necrosis is caused by disruption of the blood supply of the femoral head, which finally results in hip dysfunction. Non traumatic osteonecrosis may related with corticosteroid use, alcohol abuse, SLE, hemoglobinopathies or exposure to cytotoxic agents. But avascular necrosis of the femoral head (ANFH) due to heroin use is a rare condition. We report a patient with bilateral ANFH due to heroin use treated by simultaneous bilateral hip arthroplasty.

**PRESENTATION OF CASE:** 37 year-old male patient presented with bilateral hip pain that had been occurring for four years. The patient had no history of smoking, excessive drinking, using corticosteroid and the other drugs or trauma but used heroin for 10 years. In clinic and radiologic examination indicated advanced degenerative changes on both hip due to femoral head avascular necrosis. The patient was treated with simultaneous bilateral total hip arthroplasty. After 6 months postoperatively the active hip range of motion was painless.

**DISCUSSION:** Avascular femoral head necrosis caused by the using of heroin is rare. Ultimately, osteonecrosis of the femoral head occurs through one final common pathway, which is decreased blood flow to the femoral head that leads bone ischemia and death. But it is still unknown that heroin's systemic effects. Intravenous drug use more as a serious problem for today. There is a need for comprehensive studies to demonstrate effects of heroin on bone and vascularity metabolism.

**CONCLUSION:** Heroin use will be important problem for population. That's why is crucial to understand the effect of heroin.

© 2015 The Authors. Published by Elsevier Ltd. on behalf of IJS Publishing Group Ltd. This is an open access article under the CC BY-NC-ND license (<http://creativecommons.org/licenses/by-nc-nd/4.0/>).

## 1. Introduction

Femoral head avascular necrosis is caused by disruption of the blood supply of the femoral head, which finally results in hip dysfunction [1,2]. Osteonecrosis progresses traumatically or non-traumatically. Nontraumatic osteonecrosis is usually associated with corticosteroid use, alcohol abuse, systemic lupus erythematosus, hemoglobinopathies including sickle cell anemia, Legg-Calve Perthes disease and exposure to radiation or cytotoxic agents [3–5]. Less common associations include Gaucher's disease, dysbarisms, HIV, hyperlipidemia, pancreatitis and gout [2]. The treatment is challenging and based on the stage of the necrosis. Advanced stage avascular necrosis needs total hip arthroplasty [6].

Avascular necrosis of the femoral head (ANFH) due to heroin use is a rare condition. There are few reports of heroin injection to the femoral veins resulted with thrombophlebitis and subsequently ANFH [7]. However, osteonecrosis of femoral head caused by heroin

without injection to the femoral veins is not reported. In this case, we report a patient with bilateral ANFH due to heroin use treated by simultaneous bilateral total hip arthroplasty.

## 2. Case report

A 37 year-old male patient presented with bilateral hip pain that had been occurring for four years. When we deepen the patient's history learned that, he is a history teacher and using IV heroin for 10 years. The patient had no history of smoking, excessive drinking, using corticosteroid and the other drugs or trauma but use heroin for 10 years. 2 years ago he applied psychiatrist for treatment and had seen pharmacotherapy 2 months, psychotherapy 6 months. Buprenorphine/naloxone (suboxone 8 mg) treatment was applied for 2 months. He completely stopped heroin use during six months, but then he left follow-up and started using drug again. There is no family history for ANFH. Patient redirected by psychiatrist when hip pain increased dramatically. There is no other predispose factors can related with osteonecrosis. Routine blood test results of liver and kidney electrolytes, hemoglobinopathies and coagulopathies were normal. Clinic examination of both hip revealed generalized tenderness in the groin with limited range of motion. Hip flexion

\* Corresponding author at: Department of Orthopedics and Traumatology, Acibadem Atakent University Hospital, Halkali, Istanbul, Turkey. Fax: +90 212 404 4445. E-mail address: [drdeto@gmail.com](mailto:drdeto@gmail.com) (O. Ozkunt).

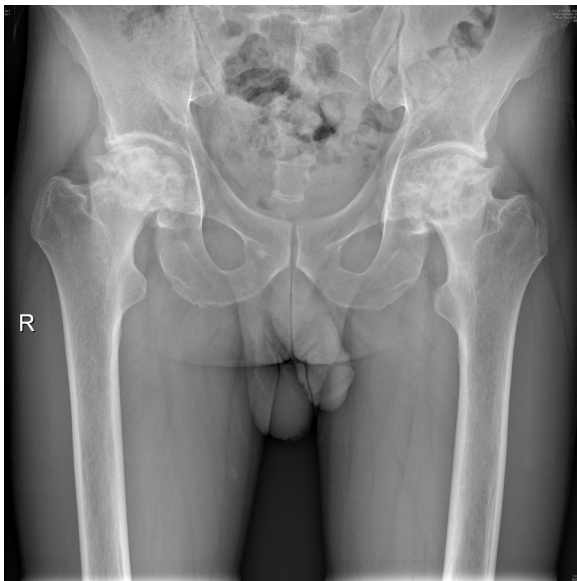

Fig. 1. Preoperative X-ray imaging.

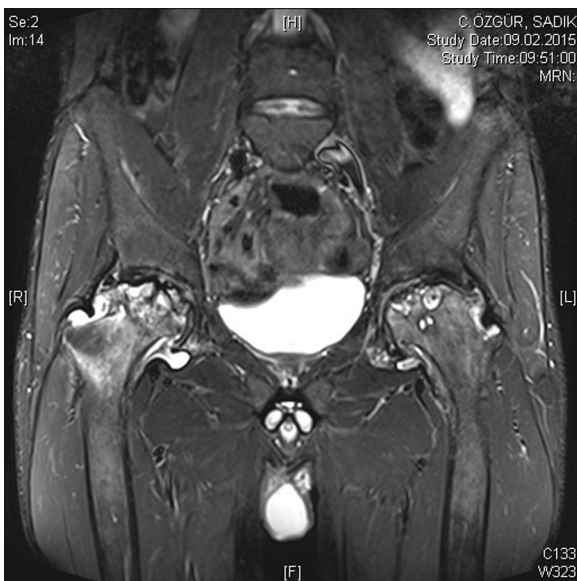

Fig. 2. Preoperative MRI imaging.

was restricted to 90°, hip extension to 10° with minimal abduction and fixed in external rotation. Initial radiographs showed severe ischemic necrosis which lead to arthrosis and collapse in bilateral hip joints (Fig. 1). Magnetic resonance imaging of the bilateral hip joints indicated advanced degenerative changes on both sides (Fig. 2).

The patient was treated with simultaneous bilateral total hip arthroplasty. After 6 months postoperatively the active hip range of motion was painless. There was no flexion or abduction contracture at both hip joints. Harris hip score raised from 52 to 89. Being treated to leave the drug last year. Blood and urine tests for heroin is clean out for the last 6 months. The control radiographs there is no evidence for loosening and infection for arthroplasty (Fig. 3).

### 3. Discussion

Avascular femoral head necrosis caused by the using of heroin is rare. Ultimately, osteonecrosis of the femoral head occurs through

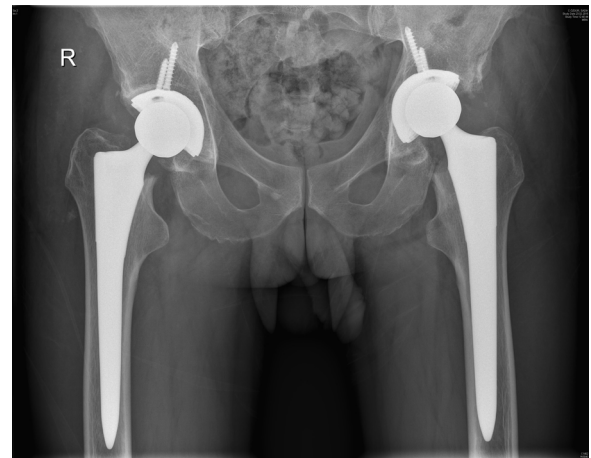


Fig. 3. Postoperative X-ray imaging.

one final common pathway, which is decreased blood flow to the femoral head that leads to bone ischemia and death. Vascular occlusion can be caused by local thrombi, fat emboli, nitrogen bubbles, or abnormally shaped red cells [8]. The blood vessels in the femoral head may be directly damaged by vasculitis, irradiation, or chemical toxicity [9,10]. Most common factors like alcohol and corticosteroids cause osteonecrosis with abnormality of lipid metabolism and fat emboli [2]. Also hypercoagulopathy and genetic alterations like factor V Leiden mutation can cause avascular necrosis [11]. In this case our patient has no risk factor for osteonecrosis other than using heroin. It is complicated that how heroin causes osteonecrosis of the femoral head [12–14]. Wu et al. show osteonecrosis of the femoral head in the patient who injected heroin into the femoral vein [7]. They explain the process with thrombophlebitis resulting from the intravenous injection. But it is still unknown that heroin's systemic effects. There are some studies about microvascular damage and apoptosis caused by intravenous opioid use [15,16]. Intravenous drug use is more of a serious problem for today. There is a need for comprehensive studies to demonstrate the effects of heroin on bone and vascular metabolism. We fixed the late stage of necrosis in this patient and had to do arthroplasty for treatment. In the future it is crucial that we reveal the etiology for more cost-effective and more functional therapies.

### Conflicts of interest

None.

### Funding

None.

### Ethical approval

None.

### Consent

This is a statement that the patient had given informed consent for the case report to be published.

### Author contribution

OO, corresponding author of the case, did the literature search, manuscript writing, worked in data collection (follow-up data).

FD had attended the surgery and also worked in data collecting (follow-up data). KS did the literature search and helped the manuscript writing.

FI performed the surgery, made study design and helped in manuscript editing.

MS made the initial study design, joined the surgery and made the general supervision of the case report.

All authors read and approved the final manuscript.

### Research studies

None.

### Guarantor

Okan Ozkunt.

### References

- [1] T.J. Claffey, Avascular necrosis of the femoral head. An anatomical study, *J. Bone Joint Surg. Br.* 42-B (1960) 802–809.
- [2] J. Seamon, et al., The pathogenesis of nontraumatic osteonecrosis, *Arthritis* 2012 (2012), 601763.
- [3] S.S. Hasan, A.A. Romeo, Nontraumatic osteonecrosis of the humeral head, *J. Shoulder Elbow Surg.* 11 (3) (2002) 281–298.
- [4] M. Abu-Shakra, D. Buskila, Y. Shoenfeld, Osteonecrosis in patients with SLE, *Clin. Rev. Allergy Immunol.* 25 (1) (2003) 13–24.
- [5] A.L. Akinyoola, et al., Risk factors for osteonecrosis of the femoral head in patients with sickle cell disease, *Int. Orthop.* 33 (4) (2009) 923–926.
- [6] J. Arlet, Nontraumatic avascular necrosis of the femoral head. Past, present, and future, *Clin. Orthop. Relat. Res.* 277 (1992) 12–21.
- [7] D. Wu, et al., Avascular necrosis of the femoral head due to the bilateral injection of heroin into the femoral vein: a case report, *Exp. Ther. Med.* 6 (4) (2013) 1041–1043.
- [8] M.M. Mukisi, K. Bashoun, F. Burny, Sickle-cell hip necrosis and intraosseous pressure, *Orthop. Traumatol. Surg. Res.* 95 (2) (2009) 134–138.
- [9] B.W. Hancock, P. Huck, B. Ross, Avascular necrosis of the femoral head in patients receiving intermittent cytotoxic and corticosteroid therapy for Hodgkin's disease, *Postgrad. Med. J.* 54 (634) (1978) 545–546.
- [10] I.H. Abdulkareem, Radiation-induced femoral head necrosis, *Niger. J. Clin. Pract.* 16 (1) (2013) 123–126.
- [11] G. Etienne, M.A. Mont, P.S. Ragland, The diagnosis and treatment of nontraumatic osteonecrosis of the femoral head, *Instr. Course Lect.* 53 (2004) 67–85.
- [12] B. Pieper, T. Templin, Chronic venous insufficiency in persons with a history of injection drug use, *Res. Nurs. Health* 24 (5) (2001) 423–432.
- [13] S. Manekeller, et al., Analysis of vascular complications in intra-venous drug addicts after puncture of femoral vessels, *Zentralbl. Chir.* 129 (1) (2004) 21–28.
- [14] A.M. Raso, et al., Vascular pathology of surgical interest in drug addicts, *Minerva. Cardioangiol.* 48 (10) (2000) 287–296.
- [15] F.R. Ghosheh, S.S. Kathuria, Intraorbital heroin injection resulting in orbital cellulitis and superior ophthalmic vein thrombosis, *Ophthal. Plast Reconstr. Surg.* 22 (6) (2006) 473–475.
- [16] W.J. Somers, F.C. Lowe, Localized gangrene of the scrotum and penis: a complication of heroin injection into the femoral vessels, *J. Urol.* 136 (1) (1986) 111–113.

### Open Access

This article is published Open Access at [sciedirect.com](http://sciedirect.com). It is distributed under the [IJSCR Supplemental terms and conditions](#), which permits unrestricted non commercial use, distribution, and reproduction in any medium, provided the original authors and source are credited.