

## ORIGINAL ARTICLE

# Comparison of Plain MRI and MR Arthrography in the Evaluation of Lateral Ligamentous Injury of the Ankle Joint

Mei-Chun Chou<sup>1,4</sup>, Lee-Ren Yeh<sup>1,3</sup>, Clement Kuen-Huang Chen<sup>1,3\*</sup>, Huay-Ban Pan<sup>1,3</sup>,  
Yi-Jiun Chou<sup>2</sup>, Huei-Lung Liang<sup>1,3</sup>

<sup>1</sup>Department of Radiology and <sup>2</sup>Department of Orthopedics, Kaohsiung Veterans General Hospital, Kaohsiung, <sup>3</sup>National Yang-Ming University School of Medicine, Taipei and <sup>4</sup>Department of Radiology, Chi-Mei Medical Center, Yung Kang Campus, Taiwan, R.O.C.

**Background:** The purpose of this study was to determine the efficacy of plain magnetic resonance imaging (MRI) and magnetic resonance (MR) arthrography for detecting collateral ligamentous injury of the ankle joint.

**Methods:** Fifty patients (October 2001 to November 2003) suffering from ankle disability who underwent plain MRI and MR arthrographic studies were enrolled in this study. The diagnostic criteria for ligament disruption on plain MRI included nonvisualization, disruption, waviness of the ligament, or coexistent avulsion fracture. The MR arthrographic findings of ligament disruption were based on leakage of gadolinium contrast medium anterior to the anterior talofibular (ATaF) ligament following ATaF ligament disruption, and the contrast medium filling into the common peroneal tendon sheath after calcaneofibular (CF) ligament disruption. The 2 modalities were interpreted respectively and blindly.

**Results:** Seventeen patients received surgical intervention. There were 14 patients who had a torn ATaF ligament and 6 patients who suffered from CF ligament disruption proved by surgery. Limited detection of preoperative plain MRI survey, which showed 12 patients had torn ATaF and 2 patients had torn CF ligament, was noted. However, most patients with ligamentous injury were correctly diagnosed by MR arthrography preoperatively (only 1 case of CF injury was missed). The plain MRI alone had a higher incidence of false negative and false positive detection. MR arthrography was also valuable for evaluating the coexisting intra-articular pathologies of the ankle joint.

**Conclusion:** For evaluating ankle disability, using plain MRI alone is not adequate for correctly detecting lateral collateral ligamentous injury of the ankle joint. MR arthrography improves the sensitivity and the accuracy for ATaF and CF ligament injuries. It also helps in assessing coexisting pathologic lesions of ankle joints, especially impingement syndromes and osteochondral lesions, and provides more information for therapeutic decision making. [*J Chin Med Assoc* 2006;69(1):26–31]

**Key Words:** ankle joint, arthrography, collateral ligament, MRI

## Introduction

Lateral ankle sprain is commonly seen in sports-related trauma of the ankle joints; it represents 16–21% of all sports injuries.<sup>1</sup> There are 3 major lateral collateral ligaments: anterior talofibular (ATaF), calcaneofibular (CF), and posterior talofibular (PTaF) ligaments. The ATaF ligament is the weakest and the most

frequently torn. A predictable pattern of injury involving the ATaF ligament followed by the CF then the PTaF ligament may be seen in severe traumatic events.<sup>1</sup> Based on the anatomy and number of affected ligaments, ankle sprains may be classified as: (1) first-degree sprain, characterized by a partial or complete tear of the ATaF ligament; (2) second-degree sprain, in which both the ATaF and CF ligaments are either

\*Correspondence to: Dr. Clement Kuen-Huang Chen, Department of Radiology, Kaohsiung Veterans General Hospital, 386, Ta-Chung 1<sup>st</sup> Road, Kaohsiung 813, Taiwan, R.O.C.

E-mail: ckhc@isca.vghks.gov.tw • Received: February 25, 2005 • Accepted: November 3, 2005

partially or completely torn; and (3) third-degree sprain, with injuries to the ATaF, CF, and PTaF ligaments.<sup>1</sup> Surgical intervention for ligamentous repair may be needed in acute, second-degree or more severe ankle sprain, and in patients suffering from chronic ankle instability.<sup>2</sup> Although the role of plain magnetic resonance imaging (MRI) in assessing pathologic conditions of the ankle and foot has been recognized for years, its limited ability to detect lateral collateral ligament injury, especially to the CF ligament, also has been noted.<sup>3-5</sup> The diagnostic benefit of direct magnetic resonance (MR) arthrography for soft-tissue structures around the ankle, such as ligaments, has been reported.<sup>2,6</sup> In this study, we aimed to compare the diagnostic efficacy of plain MRI and MR arthrography for lateral collateral ligament injury of the ankle joint.

## Methods

Between October 2001 and November 2003, 50 patients who underwent plain MRI and MR arthrographic studies were enrolled in this study. All patients were referred for MR evaluation because of clinical complaint of chronic ankle instability, repetitive ankle sprain, or suffering from severe acute ankle trauma. The patients included 29 men and 21 women, whose ages ranged from 14 to 77 years. MR images were obtained with a 1.5-T imager (Signa; GE Medical Systems, Milwaukee, WI, USA).

Our routine plain MRI protocol for ankle joints consisted of axial, coronal, and sagittal planes of fat-suppressed fast spin echo (FSE) proton density-weighted (repetition time/echo time = 2800/34) sequence; axial spin echo (SE) T1-weighted (500/19) sequence; and oblique coronal (angled 50°) fat-suppressed FSE proton density-weighted (2800/34) sequence. The diagnostic criteria for ligament disruption on plain MRI included discontinuity, disruption, nonvisualization, waviness of the ligament, or coexistent avulsion fracture.

Arthrography of the ankle joints immediately following plain MRI was performed by the direct anterior approach, using intra-articular injection of contrast medium under lateral fluoroscopy. The volume

of injected contrast medium (1:400 saline-diluted gadolinium) was dependent on the capacity of the joint space, and ranged from 5 to 15 mL. The following MR arthrography protocol consisted of axial, coronal, and sagittal planes of SE T1-weighted (516/11) sequence with fat suppression. The MR arthrographic signs of ligament disruption were leakage of gadolinium contrast anteriorly to the ATaF if the ATaF ligament was torn, and the contrast medium filling into the common peroneal tendon sheath when the CF ligament was disrupted.

The 2 modalities were interpreted respectively and blindly by 2 senior osteoradiologists in musculoskeletal radiology. The image results were correlated with the operative findings and final diagnosis.

## Results

Seventeen patients received surgical intervention. Fourteen patients had torn ATaF ligaments and 6 patients suffered from CF ligament disruption according to the operative findings. Only 12 cases of ATaF ligament injury and 2 cases of CF ligament tear had been diagnosed preoperatively by plain MRI. All cases proved to have ATaF ligament injury, and most cases of CF ligament tear (except 1 missed case) were correctly identified by the MR arthrographic study preoperatively (Table 1). The sensitivity, specificity, positive predictive value, and negative predictive value for ATaF and CF ligament tear by plain MRI and MR arthrography are summarized in Table 2.

Reviewing all of the 50 patients disclosed disagreements in diagnosis between plain MRI and MR arthrography (Figure 1), with kappa values of 0.80 and 0.20 measured for ATaF and CF ligaments, respectively. Five cases considered to be negative based on the plain MRI had torn ATaF ligament diagnosed by MR arthrography, and 2 of them were proved by operative findings (Table 3). The discrepancy of diagnosis between the 2 modalities was more apparent in CF ligament injury. There were 9 cases with disagreement in diagnosis of CF ligament injury: 5 of them received surgery and all were correctly diagnosed by MR arthrography (Table 4). However,

**Table 1.** Summary of ligament injury by preoperative plain MRI, MR arthrography, and operative findings

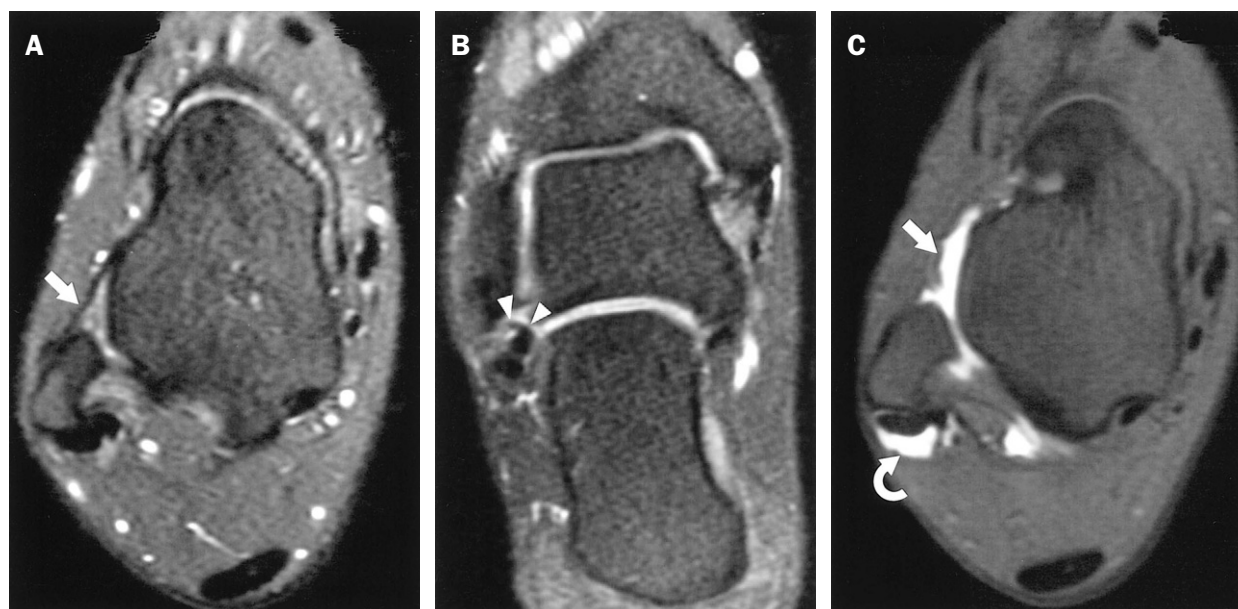
Ligamentous injury	Plain MRI (preoperative)	MR arthrography (preoperative)	Operative findings
ATaF ligament	12	14	14
CF ligament	2	5	6

ATaF = anterior talofibular; CF = calcaneofibular; MR = magnetic resonance; MRI = magnetic resonance imaging.

**Table 2.** Sensitivity, specificity, positive predictive value, and negative predictive value for ATaF and CF tear by plain MRI and MR arthrography

	Sensitivity	Specificity	Positive predictive value	Negative predictive value
ATaF				
Plain MRI, %	85.7	100.0	100.0	60.0
MR arthrography, %	100.0	100.0	100.0	100.0
CF				
Plain MRI, %	33.3	81.8	50.0	69.2
MR arthrography, %	83.3	100.0	100.0	91.7

ATaF = anterior talofibular; CF = calcaneofibular; MR = magnetic resonance; MRI = magnetic resonance imaging.



**Figure 1.** Twenty-six-year-old female with chronic ankle disability. Axial fast spin echo (FSE) proton density-weighted (TR/TE = 2800/34) with fat-suppressed image of plain MRI (A) showed the ATaF ligament (arrow) as a thin, straight, low-signal-intensity band extending from the talus to the fibular malleolus. Oblique coronal (angled 50°) fat-suppressed FSE proton density-weighted (2800/34) image (B) showed the CF ligament as a round, hypointense structure (arrowheads) extending from the lateral malleolar tip to the lateral wall of the calcaneus. No apparent evidence of ligament tear could be identified according to the diagnostic criteria of plain MRI. In MR arthrography of the same patient, the axial SE T1-weighted (516/11) image (C) showed nonvisualization of the ATaF ligament with leakage of gadolinium contrast anteriorly (arrow); there was also contrast medium filling into the common peroneal tendon sheath (curved arrow), indicating that the CF ligament was disrupted. The patient underwent surgery and both torn ligaments were surgically repaired.

**Table 3.** Summary of diagnoses regarding ATaF ligament injury by the 2 imaging modalities\*

ATaF		MR arthrography	
		Intact	Tear
Plain MRI	Intact	19 (3) <sup>†</sup>	5 (2) <sup>†</sup>
	Tear	0	26 (12) <sup>‡</sup>

\*Figures in parentheses indicate the number of patients receiving surgical intervention.

<sup>†</sup>The ATaF ligament was surgically proved intact in all of these patients.

<sup>‡</sup>The ATaF ligament was surgically proved torn in all of these patients.

ATaF = anterior talofibular; CF = calcaneofibular; MR = magnetic resonance; MRI = magnetic resonance imaging.

**Table 4.** Summary of diagnoses regarding CF ligament injury by the 2 imaging modalities\*

CF		MR arthrography	
		Intact	Tear
Plain MRI	Intact	39 (10) <sup>†</sup>	4 (3) <sup>§</sup>
	Tear	5 (2) <sup>†</sup>	2 (2) <sup>§</sup>

\*Figures in parentheses indicate the number of patients receiving surgical intervention.

<sup>†</sup>Surgical finding revealed that the CF ligament was intact in 9 patients and torn in 1.

<sup>‡</sup>The CF ligament was surgically proved intact in both patients.

<sup>§</sup>The CF ligament was surgically proved torn in all of these patients.

ATaF = anterior talofibular; CF = calcaneofibular; MR = magnetic resonance; MRI = magnetic resonance imaging.

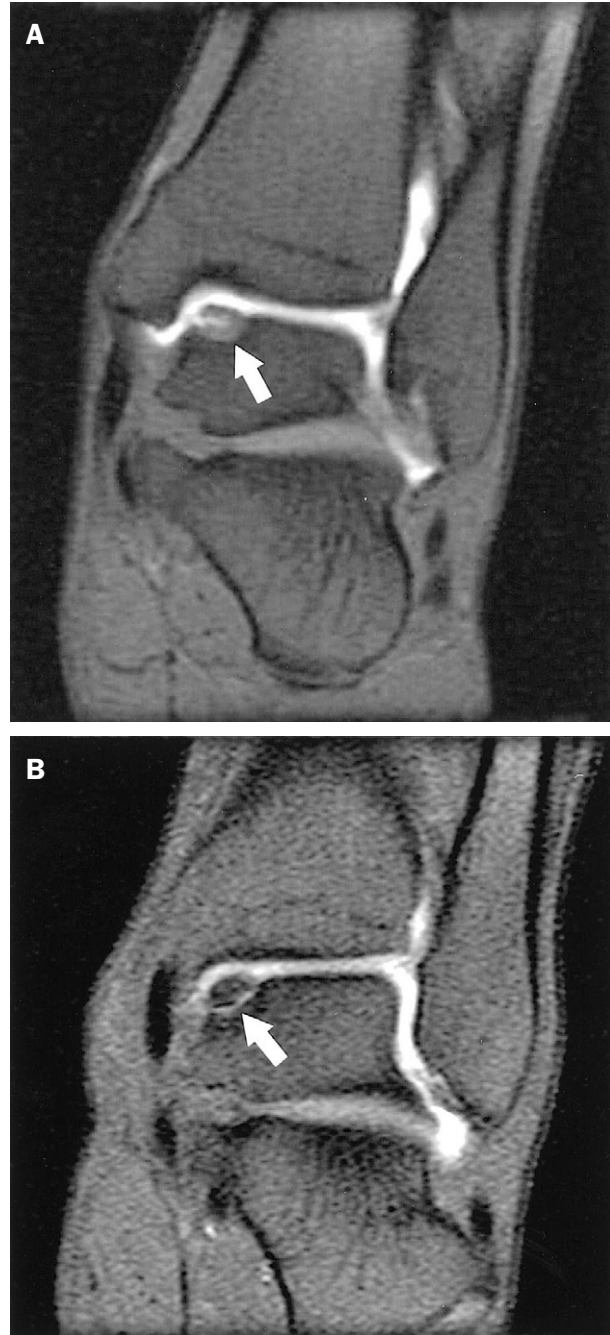
1 case with torn CF ligament was still missed preoperatively, even though the patient underwent both imaging modalities (Table 4).

There were additional findings in MR arthrography. One patient who had concurrent intra-articular fibrous tissue proliferation was found by MR arthrography and proved by arthroscopic debridement. Two of our cases had coexisting osteochondritis dissecans (OCD), and both were well demonstrated by MR arthrography (Figure 2).

## Discussion

In plain MRI, the definitive diagnostic clues of ligamentous disruption are image findings as follows: total absence of the ligaments, ligamentous discontinuity, ligamentous elongation and laxity, or total ligamentous detachment from the normal bony insertion site.<sup>1</sup> However, there are often equivocal image findings in clinical practice. If intact but altered intra-ligamentous signal intensity is found in plain MRI study, or if only focal contour irregularity without obvious ligamentous disruption is noted in plain MRI, the severity of ligamentous injury is difficult to determine. In some cases that may present as posttraumatic reattachment of the ligaments after initial injury, although the coexisting soft tissue and bone abnormalities may give some hints for interpretation,<sup>7</sup> sometimes they may be overemphasized and result in diagnostic confusion (Figure 3).

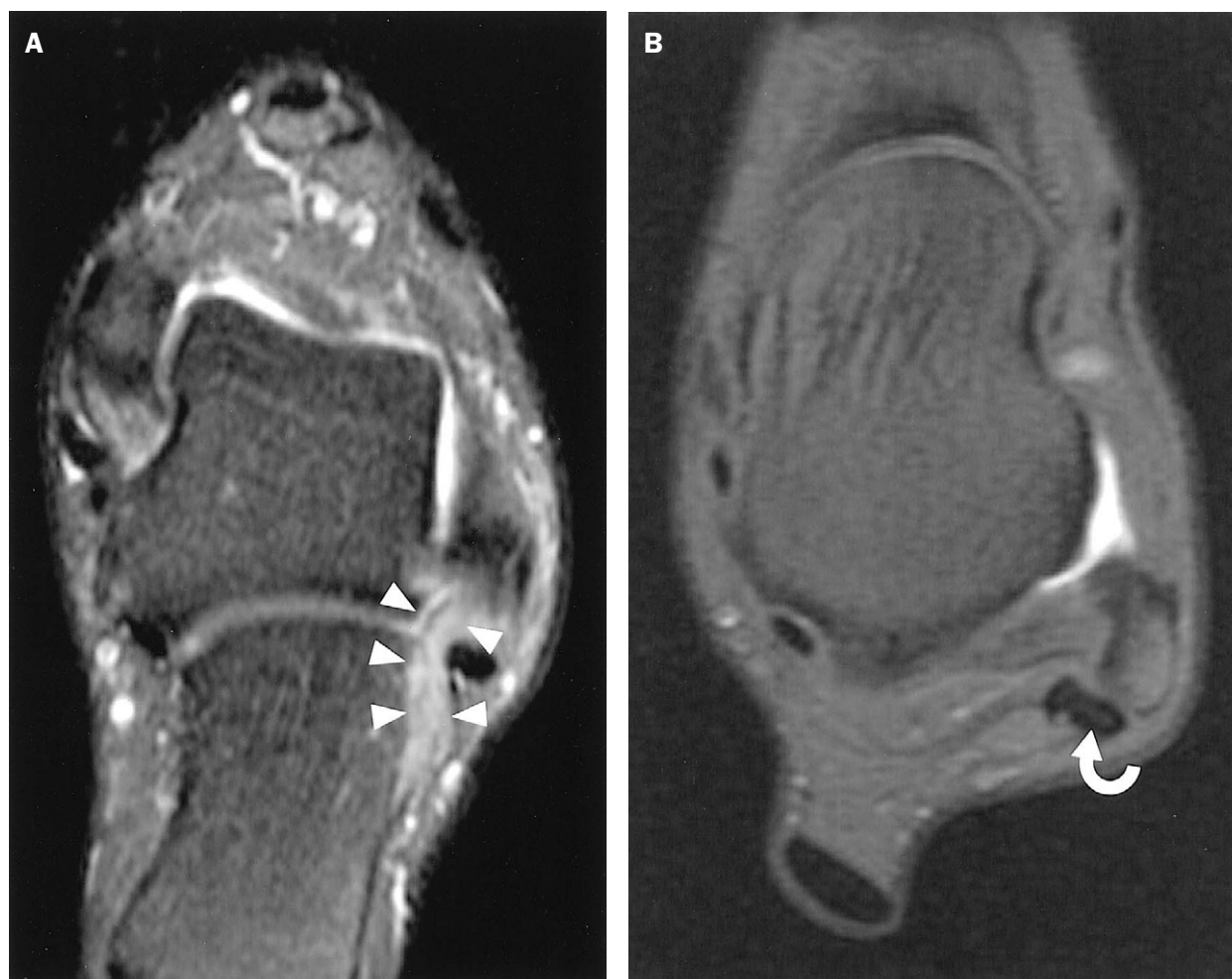
In this study, the ligamentous injuries were classified as “complete tear” or “not complete tear”, since they play an important role in determining the method of treatment. Partial tear and nontear edematous ligaments, together with normal cases, were classified to the same group because surgical intervention was not necessary for these cases. For the plain MR imaging, difficulty in interpretation of ligamentous integrity mainly arises from its signal intensity. In the acute stage, the edematous ligament and adjacent tissue manifest high signal intensity on T2-weighted images that can be similar in partial and complete tears, and, therefore, can be a cause of misinterpretation. In contrast, MR arthrography determines the ligamentous integrity by the leakage of contrast medium rather than by the signal intensity of the ligament, thus reducing the possibility of inaccuracy. In the chronic stage, the fibrosis around the torn ligament and the subsidence of edema may be a cause of false negative interpretation by plain MR imaging. Unfortunately, the chronic adhesion around the torn ligament may also seal the leakage of contrast medium, producing a false negative result by MR arthrography.



**Figure 2.** The coronal SE T1-weighted (TR/TE = 516/11) images of MR arthrography revealed concurrent osteochondritis dissecans in 2 patients with ATaF injuries (not shown). In patient 1 (A), they showed partially detached osteochondral fragment of the talus dome (arrow), compatible with Anderson classification of stage II lesion. Patient 2 (B) had detached but nondisplaced osteochondral fragment of the talus (arrow), indicating Anderson classification of stage III lesion.

MR arthrography combines the advantages of arthrography and the superior spatial resolution of MRI; it improves the delineation of the intra-articular structures such as ligamentous contour and the integrity





**Figure 3.** Forty-three-year-old female suffering from ankle strain. The oblique coronal (angled 50°) fat-suppressed proton density-weighted (TR/TE = 2800/34) images (A) showed nonvisualization of the hypointense structure between the calcaneus and the fibular malleolus. There were apparent edematous changes of the surrounding soft tissue (arrowheads). The initial interpretation based on plain MRI findings was CF ligament disruption. In MR arthrography of the same patient, the axial SE T1-weighted (516/11) image (B) revealed no evidence of gadolinium contrast medium filling into the common peroneal tendon sheath (curved arrow). The surgical findings of this patient proved that the CF ligament was intact.

of its osseous insertion, increasing the diagnostic confidence in detecting lateral collateral ligament injury.<sup>1,6,8</sup> According to our results, MR arthrography could improve the sensitivity in detecting ATaF ligament injury and both the sensitivity and specificity in detection of CF ligament injury.

However, there was 1 case of CF ligament disruption missed in our study, although both plain MRI and MR arthrography were undertaken preoperatively. We presumed 2 possibilities for the diminished contrast medium leakage of MR arthrography in this case. It might have been because of regional fibrotic tissue obliterating the ligamentous disruption, or because of the inadequate exercise of the ankle joint during MR arthrography.

Additional advantages of MR arthrography for evaluating the intra-articular pathologies are also noted.<sup>9,10</sup> In 1 of our patients, there was concurrent intra-articular fibrous tissue and synovial proliferation consistent with the diagnosis of anterolateral impingement syndrome of the ankle joint. The patient underwent arthroscopic debridement, which confirmed the MR arthrographic findings. MR arthrography is useful for establishing diagnosis of ankle impingement syndrome, for better distension and evaluation of the capsular recesses of the ankle joints, and demonstration of intra-articular fibrous mass.<sup>11,12</sup>

Some patients with chronic ankle instability suffer from simultaneous lateral collateral ligament injury and osteochondral lesions such as OCD. MR

arthrography is better for demonstrating the severity of osteochondral injury and loose bodies in the joints. It was reported that MR arthrography had higher sensitivity in assessing osteochondral lesions of joints than plain MRI (85% for MR arthrography vs 69% for plain MRI), and better accuracy in evaluating the instability of the osteochondral fragment as compared to the plain MRI (93% for MR arthrography vs 39% for plain MRI).<sup>8</sup> The treatment is based on the instability of osteochondral lesions. MR arthrography has benefits for OCD staging and helps in therapeutic decision making.

In conclusion, using plain MRI alone for evaluating ankle disability may be inadequate for detecting lateral collateral ligament injury. MR arthrography improves the sensitivity and the accuracy for ATaF and CF ligament injuries of the ankle joint. It provides more advantages for evaluating ankle impingement and coexisting osteochondral lesions and helps in therapeutic decision making.

## References

- Rosenberg ZS, Beltran J, Bencardino JT. From the RSNA Refresher Courses. Radiological Society of North America. MR imaging of the ankle and foot. *Radiographics* 2000;20 (Suppl):153-79.
- Peters JW, Trevino SG, Renstrom PA. Chronic lateral ankle instability. *Foot Ankle* 1991;12:182-91.
- Muhle C, Frank LR, Rand T, Yeh L, Wong EC, Skaf A, Dantas RW, et al. Collateral ligaments of the ankle: high-resolution MR imaging with a local gradient coil and anatomic correlation in cadavers. *Radiographics* 1999;19:673-83.
- Mesgarzadeh M, Schneck CD, Tehranzadeh J, Chandnani VP, Bonakdarpour A. Magnetic resonance imaging of the ankle ligaments: emphasis on anatomy and injuries to lateral collateral ligaments. *Magn Reson Imaging Clin N Am* 1994;2:39-58.
- Chandnani VP, Harper MT, Ficke JR, Gagliardi JA, Rolling L, Christensen KP, Hansen MF. Chronic ankle instability: evaluation with MR arthrography, MR imaging, and stress radiography. *Radiology* 1994;192:189-94.
- Schulte-Altendorneburg G, Gebhard M, Wohlgemuth WA, Fischer W, Zentner J, Wegener R, Balzer T, et al. MR arthrography: pharmacology, efficacy and safety in clinical trials. *Skeletal Radiol* 2003;32:1-12.
- Pinar H, Akseki D, Kovanlikaya I, Arac S, Bozkurt M. Bone bruises detected by magnetic resonance imaging following lateral ankle sprains. *Knee Surg Sports Traumatol Arthrosc* 1997;5:113-7.
- Steinbach LS, Palmer WE, Schweitzer ME. Special focus session. MR arthrography. *Radiographics* 2002;22:1223-46.
- Kramer J, Stiglbauer R, Engel A, Prayer L, Imhof H. MR contrast arthrography (MRA) in osteochondrosis dissecans. *J Comput Assist Tomogr* 1992;16:254-60.
- Brossmann J, Preidler KW, Daenen B, Pedowitz RA, Andresen R, Clopton P, Trudell D, et al. Imaging of osseous and cartilaginous intraarticular bodies in the knee: comparison of MR imaging and MR arthrography with CT and CT arthrography in cadavers. *Radiology* 1996;200:509-17.
- Robinson P, White LM, Salonen DC, Daniels TR, Ogilvie-Harris D. Anterolateral ankle impingement: MR arthrographic assessment of the anterolateral recess. *Radiology* 2001;221:186-90.
- Robinson P, White LM, Salonen D, Ogilvie-Harris D. Anteromedial impingement of the ankle: using MR arthrography to assess the anteromedial recess. *AJR Am J Roentgenol* 2002;178:601-4.