

Case Report

Manifestation of ST-Segment Elevation in Right Precordial Leads during Ischemia at a Right Ventricular Outflow Tract Area in a Patient with Brugada Syndrome

Naohiko Takahashi MD*¹, Tetsuji Shinohara MD*¹, Takeshi Tsuchiya MD*², Yasuko Torigoe MD*¹, Mikiko Nakagawa MD*¹, Masahide Hara MD*¹, Tetsunori Saikawa MD*¹, Hironobu Yoshimatsu MD*¹

*¹Department of Internal Medicine 1 and Department of Cardiovascular Science, Faculty of Medicine, Oita University

*²Department of Cardiology, Hakuai Hospital

A 35-year-old man experienced chest pain and a subsequent syncope attack at during the night. Ventricular fibrillation (VF) was documented, which was successfully defibrillated. The ST-segment of his 12-lead electrocardiogram (ECG) showed day-by-day variation, sometimes showing spontaneous coved-type elevation in V1 and V2. He was diagnosed as having Brugada syndrome, and an implantable cardioverter defibrillator was implanted. A coronary angiography was performed. During the procedure, the catheter was selectively inserted to the right ventricular (RV) branch of the right coronary artery (RCA) whereupon the ST-segment in V1 and V2 elevated rapidly, manifesting a coved-type Brugada ECG. The main RCA angiogram revealed the conus branch running to the RV outflow tract area, indicating that the ST-segment elevation was due to ischemia of the RV outflow tract area by transient occlusion of conus branch. The findings indicate that some patients with Brugada syndrome are specifically sensitive to ischemia in the RV outflow tract area, leading to manifestation of the ST-segment elevation in precordial ECG leads.

(J Arrhythmia 2007; 23: 236–240)

Key words: Brugada syndrome, ST-segment elevation, Ischemia, Right ventricular outflow tract

Introduction

In patients with Brugada syndrome, the relationship between ischemia and coronary vasospasm and ST-segment elevation in the precordial leads have been debated.^{1–5)} In the special report endorsed by the Heart Rhythm Society and the European Heart

Rhythm Association, it was suggested that the patients with Brugada syndrome may be at higher risk for ischemia-related sudden cardiac death.⁶⁾ We present here a patient with Brugada syndrome, in whom ischemia of the right ventricular (RV) outflow tract might have caused ST-segment elevation in the right precordial leads.

Received 10, May, 2007; accepted in final form 23, July, 2007.

Address for correspondence: Naohiko Takahashi MD PhD, Department of Internal Medicine 1, Faculty of Medicine, Oita University, 1-1 Idaigaoka, Hasama, Oita 879-5593, Japan. Phone: +81-97-586-5793 Fax: +81-97-549-4480 E-mail: takanao@med.oita-u.ac.jp

Case Report

A 35-year-old man who habitually smoked had undergone diagnostic catheterization when he was 32 years old, due to chest pain and transient syncope during the night. His coronary angiogram revealed no organic stenosis, and a vasospasm provocation test using ergonovine infusion into the coronary artery was negative. He again experienced chest pain and a subsequent syncope attack at 1 am on 29 May 2005. Five minutes later, an ambulance arrived and paramedics confirmed his ventricular fibrillation (VF) using a monitor electrocardiogram (ECG). The VF was defibrillated by direct current shock. The ST-segment of his 12-lead ECG showed day-by-day variation, sometimes showing coved-type elevation in V1 and V2 (**Figure 1**). Therefore, he was diagnosed as having Brugada syndrome. He had no family history of sudden cardiac death. After written informed consent was obtained, an implantable cardioverter defibrillator (ICD) was implanted. One month after discharge he suffered from ICD shock three times due to VF at during the night. He still continued to smoke against our advice. An electrophysiological study was performed in the fasting and unседated state. VF was not induced by programmed ventricular stimulation from the RV apex or the RV

outflow tract with three extrastimuli. Due to a recent report that demonstrated an induction of coronary vasospasm by intravenous injection of a sodium channel blocker in a patient with Brugada-type ECG,¹⁾ coronary angiography was performed before and after the intravenous administration of procainamide (400 mg). The procainamide augmented coved ST-segment elevation in V1 and V2 (**Figure 2**), without inducing coronary vasospasm. After the procainamide administration, the catheter was selectively inserted into the RV branch of the RCA (**Figure 3A**). During the procedure his 12-lead ECG showed distinct ST-segment elevation (**Figure 4**). Immediately after insertion into the RV branch, the ST-segment in V1 and V2 rapidly elevated, manifesting coved-type Brugada ECG. The ST-segment elevation was remarkable, mimicking the ECG observed during acute myocardial infarction. The ST-segment elevation was also observed in II, III, and aVF. The elevation was ameliorated gradually after prompt pulling back of the catheter. When the catheter was inserted into the main RCA, such ST-segment elevation was not observed (**Figure 3B**). The characteristic ECG changes reappeared by selective insertion in the same manner. The main RCA angiogram revealed the conus branch running of to the RV outflow tract area (**Figure 2B**, arrows). The

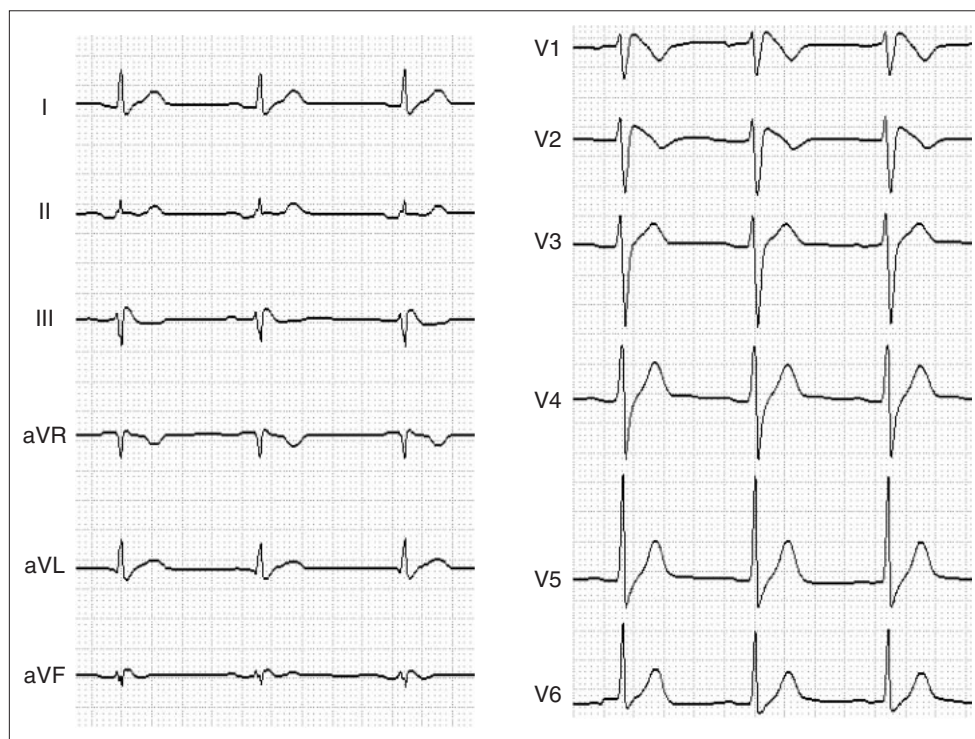


Figure 1 Twelve-lead electrocardiogram showing spontaneous coved-type ST-segment elevation in V1 and V2.

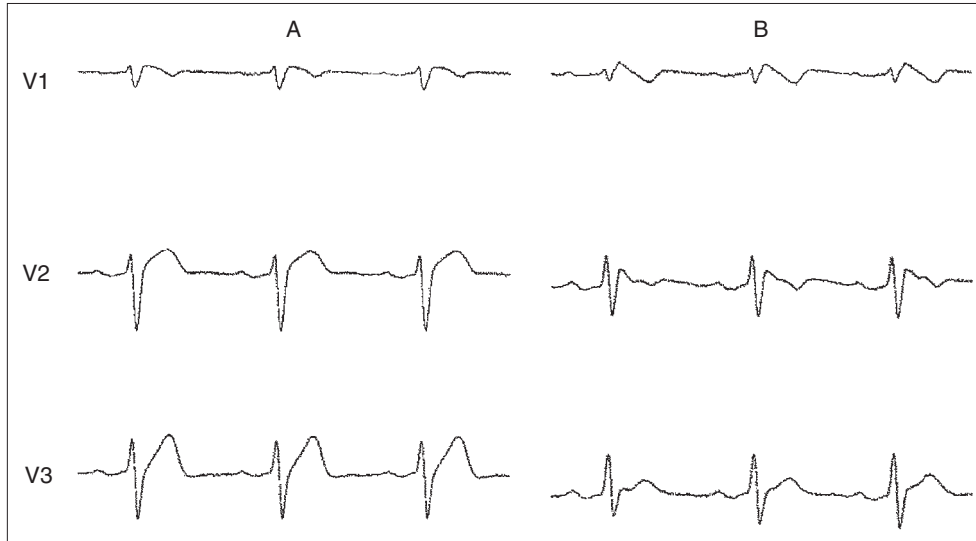


Figure 2 Electrocardiographic (ECG) changes by intravenous injection of 400 mg procainamide. A. ECG (leads V1–V3) before procainamide. B. ECG (leads V1–V3) after procainamide. Procainamide augmented covered ST-segment elevation in V1 and V2.

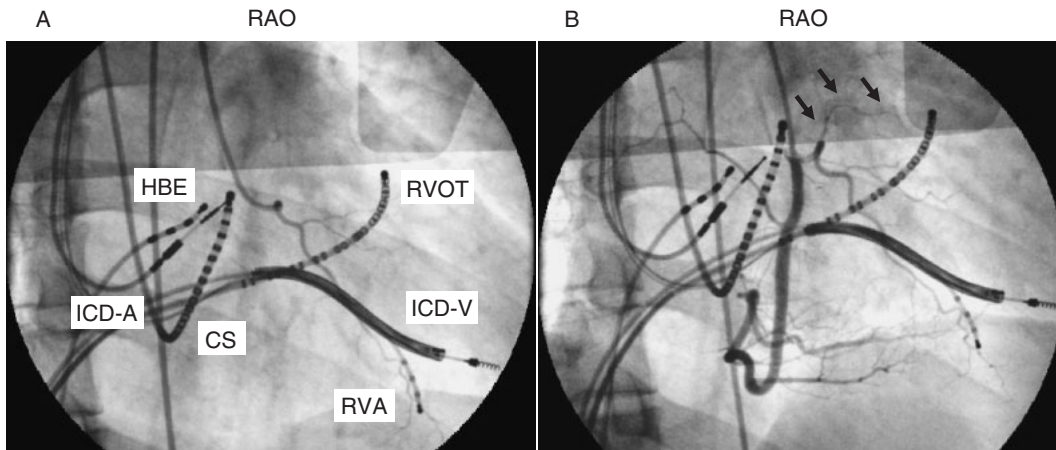


Figure 3 Coronary angiograms. A. Catheter insertion into right ventricular (RV) branch of right coronary artery (RCA). B. Catheter insertion into main RCA. Arrows indicate perfusion of RV outflow tract area by conus branch of RCA. RAO = right anterior oblique. CS = coronary sinus. HBE = His bundle electrogram. RVA = RV apex. ICD-A = Atrial lead of implantable cardioverter defibrillator (ICD). ICD-V = Ventricular lead of ICD.

patient has completely stopped his smoking and has been treated with a calcium channel antagonist. Since then, he has been free from chest pain and VF.

Discussion

In our patient, characteristic ST-segment elevation was induced in precordial leads in response to the selective insertion of a catheter into the RV branch, suggesting that ischemia of the RV outflow tract area was due to the transient occlusion of the conus

branch of RCA and that this might underlie the ST-segment elevation. Although the coronary vasospasm provocation test was negative, the thin conus branch was likely to have accidentally spasmed, yielding insufficient blood flow to the RV outflow tract area. Indirect evidence suggesting that cessation of smoking and administration of a calcium channel antagonist was effective in preventing VF may support our interpretation. We tried to induce coronary vasospasm by intravenous injection of 400 mg of procainamide, which possesses inhibitory

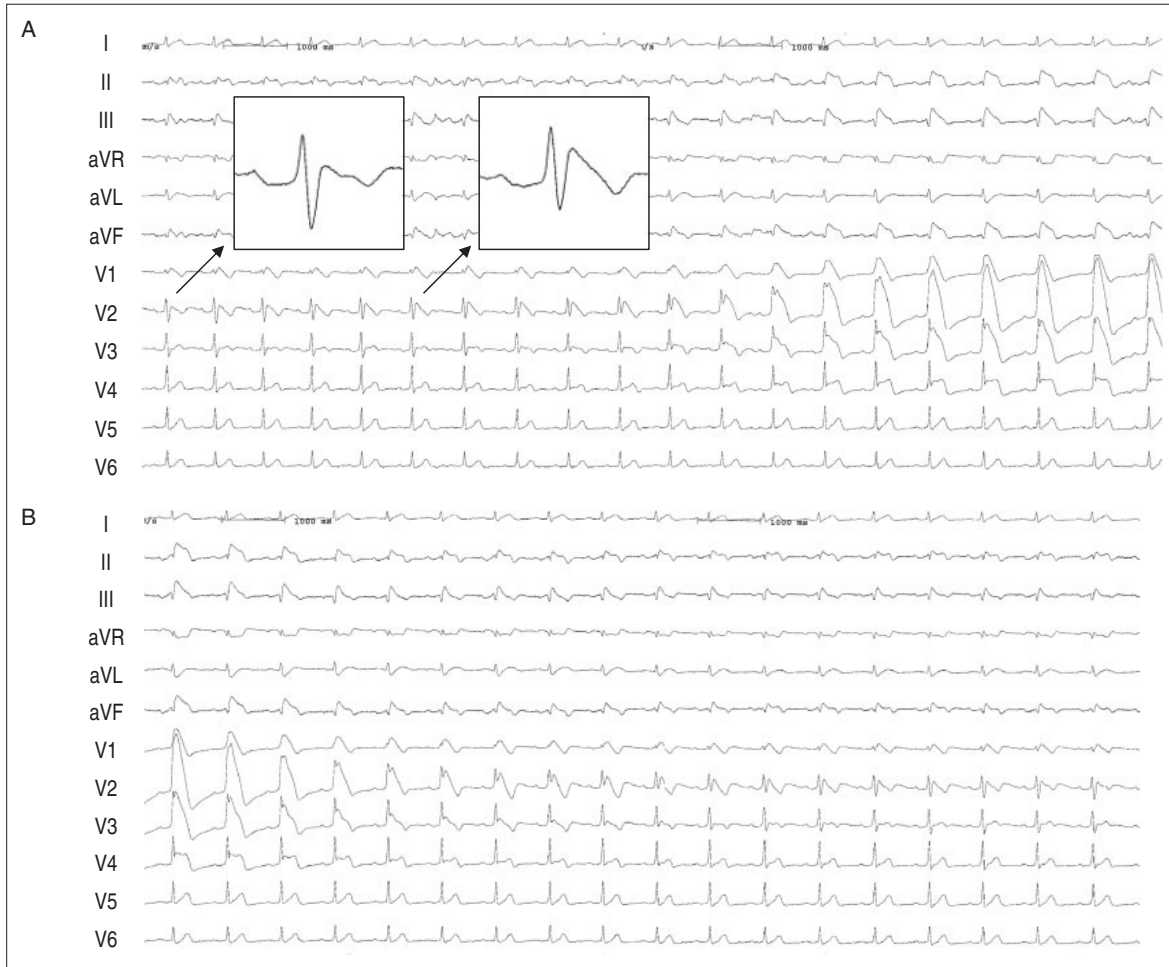


Figure 4 The serial changes in the 12-lead electrocardiogram (ECG).

A and B are continuous recordings. See text for details.

effects on potassium currents as well as sodium currents. However, employment of procainamide at a dose of 400 mg might not be sufficient to induce coronary vasospasm. The effects of pure sodium channel blockers like pilsicainide should have been considered.¹⁾

We diagnosed our patient as having Brugada syndrome because a spontaneous coved ST-segment elevation and VF had been documented.⁷⁾ However, the coved ST-segment elevation and VF observed in the present case was possibly due to ischemia at the RVOT area, suggesting the difficulty of obtaining a definitive diagnosis of Brugada syndrome for this patient. The relationship between Brugada syndrome and ischemia/coronary vasospasm has been discussed previously.¹⁻⁶⁾ Using arterially perfused wedges of canine RV, Yan and Antzelevitch⁷⁾ reported that depression or loss of the action potential dome in RV epicardium by terfenadine

(Brugada syndrome model) creates a transmural voltage gradient, resulting in an ST-segment elevation, as observed in patients with Brugada syndrome. Using the same wedges, Yan and Antzelevitch⁷⁾ also showed that brief ischemia can cause loss of the dome at some epicardial sites leading to ST-segment elevation. However, such an ischemic change was observed rarely and only in RV wedge preparations displaying prominent transient outward potassium current (I_{to})-mediated notch. Taken together, it can be postulated that our patient has prominent I_{to} in epicardial RVOT, which might be responsible for the ST-segment elevation during ischemia. Our observations indicate that some patients with Brugada syndrome are specifically sensitive to ischemia in the RV outflow tract area, leading to ST-segment elevation in precordial ECG leads. The concomitant alterations of the myocardial electrophysiological properties may eventually cause VF.

References

- 1) Goda A, Yamashita T, Kato T, et al: Pilsicainide-induced coronary vasospasm in a patient with Brugada-type electrocardiogram. *Circ J* 2005; 69: 858–860
- 2) Chinushi M, Kuroe Y, Ito E, et al: Vasospastic angina accompanied by Brugada-type electrocardiographic abnormalities. *J Cardiovasc Electrophysiol* 2001; 12: 108–111
- 3) Di Diego JM, Fish JM, Antzelevitch C: Brugada syndrome and ischemia-induced ST-segment elevation. Similarities and differences. *J Electrocardiol* 2005; 38 (Suppl): 14–17
- 4) Noda T, Shimizu W, Taguchi A, et al: ST-segment elevation and ventricular fibrillation without coronary spasm by intracoronary injection of acetylcholine and/or ergonovine maleate in patients with Brugada syndrome. *J Am Coll Cardiol* 2002; 40: 1841–1847
- 5) Chinushi M, Furushima H, Tanabe Y, et al: Similarities between Brugada syndrome and ischemia-induced ST-segment elevation. Clinical correlation and synergy. *J Electrocardiol* 2005; 38 (Suppl): 18–21
- 6) Antzelevitch C, Brugada P, Borggrefe M, et al: Brugada syndrome: report of the second consensus conference: endorsed by the Heart Rhythm Society and the European Heart Rhythm Association. *Circulation* 2005; 111: 659–670
- 7) Di Diego JM, Fish JM, Antzelevitch C: Brugada syndrome and ischemia-induced ST-segment elevation. Similarities and differences. *J Electrocardiol* 2005; 38 (Suppl): 14–17