



## Case report

## Spontaneous pneumothorax in a teenager with prior congenital pulmonary airway malformation

Matthew P. Shupe<sup>a,\*</sup>, Herbert P. Kwon<sup>b</sup>, Michael J. Morris<sup>c</sup><sup>a</sup>Internal Medicine Residency, Department of Medicine, San Antonio Military Medical Center, 3851 Roger Brooke Drive, Fort Sam Houston, TX 78234, USA<sup>b</sup>Pulmonary/Critical Care Service, Department of Medicine, Womack Army Medical Center, Fort Bragg, NC, USA<sup>c</sup>Pulmonary/Critical Care Service, Department of Medicine, Brooke Army Medical Center, Fort Sam Houston, TX, USA

## ARTICLE INFO

## Article history:

Received 2 May 2012

Accepted 6 March 2013

## Keywords:

Congenital pulmonary airway malformation

Spontaneous pneumothorax

Pulmonary

## ABSTRACT

Congenital pulmonary airway malformation (CPAM), previously referred to as congenital cystic adenomatoid malformation (CCAM), is a developmental malformation of the lower respiratory tract and the most commonly reported congenital lung lesion. Affected patients typically present with respiratory distress in the neonatal period from expanding cysts and resulting compression of surrounding lung parenchyma. However, some patients also remain asymptomatic until later in life. In this report, we present a case of CPAM requiring emergent left lower lobectomy at the first day of life that remained asymptomatic until the patient developed a spontaneous pneumothorax 18 years later. Our patient's presentation with an isolated spontaneous pneumothorax at age 18 does not appear to have been previously reported. In addition, there are several aspects of this case that represent atypical features of CPAM. After an extensive literature search, few reports exist describing any long-term complications of CPAM following neonatal lobectomy. Chest imaging in our patient demonstrated residual left basilar bullae and there was a moderate fixed obstructive/restrictive defect on pulmonary function testing. His risk for recurrent pneumothorax or infectious complications is unknown based on minimal published information on long-term outcomes or complications in patients with resected CPAM lesions. We conclude that follow up of all CPAM patients should include an evaluation for evidence of residual lung disease both with spirometric testing and chest imaging. Furthermore, concern for infectious complications or symptomatic obstructive lung disease should likewise be considered.

Published by Elsevier Ltd. Open access under [CC BY-NC-ND license](http://creativecommons.org/licenses/by-nc-nd/4.0/).

## 1. Introduction

Congenital pulmonary airway malformation (CPAM), previously referred to as congenital cystic adenomatoid malformation (CCAM), is a developmental malformation of the lower respiratory tract and the most commonly reported congenital lung lesion.<sup>1,2</sup> Affected patients typically present with respiratory distress in the neonatal period from expanding cysts and resulting compression of surrounding lung parenchyma.<sup>3</sup> However, some patients also remain asymptomatic until later in life. Lesions are usually unilateral in the lower lobes and occur sporadically with no gender, racial, or exposure predilection.<sup>4,5</sup> Congenital pulmonary airway malformations are classified into five types based on size, histology, and

distinct characteristics and standard management includes surgical resection<sup>1</sup> (see [Table 1](#)). Few reports exist describing any long-term complications of CPAM following neonatal lobectomy. In this report, we present a case of CPAM requiring emergent left lower lobectomy at the first day of life that remained asymptomatic until the patient developed a spontaneous pneumothorax (PTX) 18 years later.

## 2. Case report

An 18 year old male presented to the emergency department at our institution with complaints of sudden onset left-sided pleuritic chest pain and dyspnea while sitting in church. His past medical history was significant for neonatal respiratory distress due to congenital lung disease requiring an emergent left lower lobe (LLL) resection the day following his birth. According to his father, he was reported to have an isolated type I CCAM. His past medical history was notable for a marfanoid body habitus, pectus excavatum, and double-curved scoliosis requiring intervertebral rod placement. Despite these physical findings, the patient noted lifelong

*Abbreviations:* CPAM, congenital pulmonary airway malformation; CCAM, congenital cystic adenomatoid malformation; PTX, pneumothorax; LLL, left lower lobe; FEV<sub>1</sub>, forced expiratory volume at one second; FVC, forced vital capacity; CT, computed tomography.

\* Corresponding author. Tel.: +1 210 916 0751.

E-mail address: [matthew.p.shupe@mail.mil](mailto:matthew.p.shupe@mail.mil) (M.P. Shupe).

**Table 1**  
Present classification scheme describing pathologic features of various congenital pulmonary airway malformations.

	Percent of total cases	Cyst characteristics	Cellular characteristics	Other
Type 0	1–3%	Small, max. diameter 0.5 cm	Ciliated pseudostratified epithelium	Usually involves entire lung; affected usually die at birth
Type 1	60–70%	Single, thin-walled, 2–10 cm in diameter	Ciliated pseudostratified columnar epithelium	One lobe involvement
Type 2	15–20%	Multiple cysts 0.5–2 cm in diameter	Ciliated cuboidal or columnar epithelium	Other congenital anomaly in 60% of cases
Type 3	5–10%	Numerous small cysts (<0.5 cm in diameter) comprising an entire lobe or several lobes	Non-ciliated cuboidal epithelium	Often very large
Type 4	10–15%	Max. diameter 7 cm	Non-ciliated, flattened, alveolar lining cells	Strongly associated with malignancy (pleuropulmonary blastoma)

participation in sports activities with minimal limitation. He denied any previous symptoms of dyspnea, cough, or productive sputum. No further evaluation had been performed since infancy based on a lack of pulmonary symptoms.

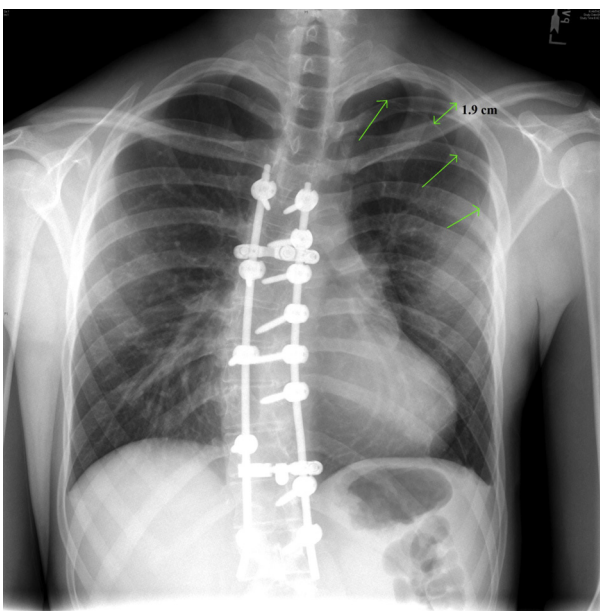
At initial presentation, the patient was breathing comfortably with no respiratory distress. Vital signs demonstrated he was normotensive with a heart rate of 80 and oxygen saturation of 100% on room air. Physical examination was only revealing for diminished breath sounds over the posterior left hemithorax. Chest radiograph revealed a left apical PTX measuring 1.9 cm from the pleural surface (see Fig. 1). A large-bore 32 French left chest tube was placed by the general surgery service and the patient was admitted for drainage of the PTX. His hospital course was unremarkable and the tube thoracostomy was removed after four days with minimal residual left apical air.

During follow-up evaluation several months later in the Pulmonary Clinic, the patient had returned to college where he described a recurrent episode of pleuritic chest pain lasting one hour for which he did not seek medical attention. He otherwise continued to be asymptomatic with no pulmonary symptoms and no limitation in physical activities. Pulmonary function testing revealed a mixed obstructive/restrictive defect with a forced

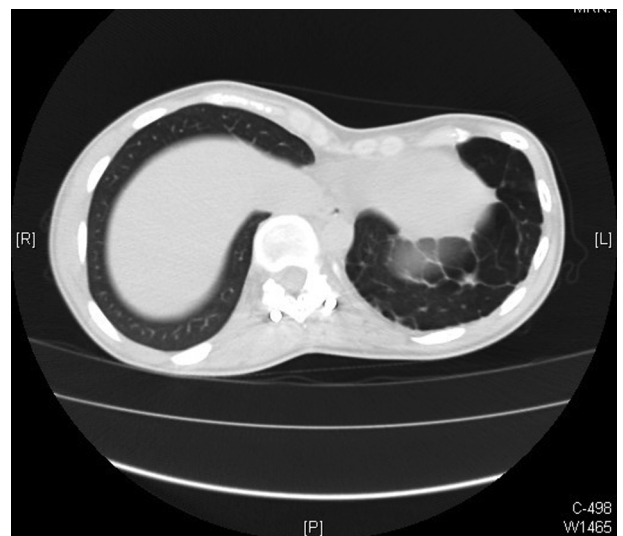expiratory volume at one second (FEV<sub>1</sub>) of 2.65 (54% predicted), forced vital capacity (FVC) of 3.78 (65% predicted), FEV<sub>1</sub>/FVC ratio of 70%, reduction in total lung capacity to 5.34 (67% predicted), and diffusing capacity of 25.2 (72% predicted). There was no bronchodilator response suggesting fixed obstruction. Repeat chest radiograph showed resolution of the left apical PTX and stable appearance of hyperexpanded lungs with a left basilar bleb. Computed tomography of the chest showed multiple left-sided peripheral and basilar bullae of varying sizes but no continued evidence of pleural air (see Fig. 2). The original pathology report was located by his father and the stated surgical pathology was the following: “Congenital cystic adenomatoid malformation (Type I) of the lung, clinically involving left lower lobe, with compressive atelectasis and acute interstitial emphysema.” The patient remained clinically stable and had no further PTX episodes. Repeat evaluation one year later demonstrated no further symptoms, stable findings on chest imaging, and unchanged pulmonary function testing.

### 3. Discussion

Congenital pulmonary airway malformations are hamartomatous lesions that are comprised of cystic and adenomatous elements of tracheal, bronchial, and alveolar tissue.<sup>1</sup> These lesions were previously identified as CCAM as classified into three major groups (Type I–III) based on the size of the cysts and their cellular characteristics. Two additional types (Type 0 and IV) have been



**Fig. 1.** Chest radiograph showing left apical pneumothorax (green arrows) measuring 1.9 cm from the pleural surface. Basilar bleb at left costophrenic angle can also be appreciated.



**Fig. 2.** Non-contrast computerized tomography showing multiple left basilar bullae.

added to make up the five current group CPAM classification with each having distinct pathologic characteristics (see Table 1).<sup>6,7</sup>

Type I CPAM is the most common etiology and accounts for 60 to 70 percent of all cases.<sup>8</sup> These congenital lesions consist of large cysts up to 10 cm lined by pseudostratified ciliated cells interspersed with mucous cells. The cysts are usually single but may be loculated. A characteristic finding is involvement of a single lobe. Type I lesions compress adjacent normal lung tissue and may cause neonatal respiratory distress with contralateral mediastinal shift. These lesions are usually resectable and carry a good prognosis.<sup>8</sup> The patient in this case had a typical presentation as a full term newborn with severe respiratory distress and a LLL cystic mass compressing the left upper lobe. The pathologic findings described lung tissue replaced by multiloculated cysts, the largest measuring 8.5 cm in diameter and confirmed the diagnosis of a Type I CPAM.

Variable presentations of CPAM have been described in the literature. Affected newborns typically present with symptoms of respiratory distress soon after birth, although 50% may remain asymptomatic until later in life.<sup>4</sup> The management of CPAM usually involves surgical resection not only to confirm the diagnosis but also decrease the risk of infection or malignant transformation.<sup>9</sup> Surgical resection of affected lung is usually performed in symptomatic newborns with respiratory distress but can be completed electively in older children with less acute symptoms. In older children, CPAM may also be discovered as incidental radiographic finding or present due to recurrent respiratory infections.<sup>10</sup> Presentation of CPAM in adulthood is rare and usually involves recurrent pulmonary infections involving a single lobe; only 24 reported cases of CPAM have been diagnosed in adults.<sup>9</sup>

There are several aspects of this case that represent atypical features of CPAM. Our patient's presentation with an isolated spontaneous PTX at age 18 does not appear to have been previously reported. There is an established association between PTX and undiagnosed CPAM. Spontaneous PTX has been described in early infancy (3 week old girl) due a CPAM with atypical histologic features.<sup>3</sup> It has also been reported in other children beyond the neonatal period (ages 1.5 months to thirteen years old) and in these cases, was the initial presentation for their congenital lung disease.<sup>10–17</sup> Two similar cases have been described in 18 year olds, one patient who presented with hemoptysis and hemothorax and another patient with pyopneumothorax, both who consequently underwent resection of a previously undiagnosed Type I CPAM.<sup>9,19</sup> There is likewise an established association between PTX and pleuropulmonary blastoma found in Type 4 CPAM where patients present within the first two years of life with a large cyst or cysts and respiratory distress; pneumothorax was present in 43% of cases.<sup>20,21</sup> Having already undergone surgical resection for a Type I CPAM during infancy, the spontaneous PTX in our patient was likely due to his residual lung disease and not a primary CPAM.

A second clinical issue in our patient is long-term follow-up for patients with diagnosed CPAM. Chest imaging in our patient demonstrated residual left basilar bullae and there was a moderate fixed obstructive/restrictive defect on pulmonary function testing. His risk for recurrent PTX or infectious complications is unknown based on minimal published information on long-term outcomes or complications in patients with resected CPAM lesions.<sup>18,22,24</sup> Pinter et al. described 17 patients in which 20 year follow-up data was compiled. While respiratory infections were reported in 35% of patients and eight patients had mild chest deformities, most had good long-term outcome with normal activity. Shorter follow-up with pulmonary function testing in a group of eight asymptomatic CPAM patients showed lung volumes at 90% predicted.<sup>24</sup> Despite the appearance of a spontaneous PTX 18 years later after surgical resection, the risk of malignancy due to pleuropulmonary blastoma or bronchoalveolar carcinoma is extremely remote. While

malignancy can arise in undiagnosed CPAM, the patient's age and the absence of any residual cysts or masses is reassuring. An additional consideration is the potential development of symptomatic pulmonary disease with increasing age due to the significant fixed airway obstruction. While the presence of a pectus excavatum is notable and has been reported in association with CPAM; it is unlikely to cause any symptoms given its mild appearance.<sup>23</sup>

This patient's presentation 18 years after surgical resection of a Type I CPAM should prompt clinicians to be aware of long-term complications related to residual lung disease. Our patient not only developed a spontaneous PTX due to unrecognized bullous changes, but also has a moderate fixed airway obstruction. There should be an evaluation of all CPAM patients for evidence of residual lung disease both with spirometric testing and chest imaging. Concern for infectious complications or symptomatic obstructive lung disease should likewise be considered.

## Disclosures

The opinions in this essay do not constitute endorsement by Brooke Army Medical Center, the U.S. Army Medical Department, the U.S. Army Office of the Surgeon General, the Department of the Army, Department of Defense, or the U.S. Government of the information contained therein.

Dr. Morris is paid speaker for Spiriva by Pfizer/Boehringer-Ingelheim. The other authors have no financial interests to disclose.

This study was not supported by any funding or financial sponsorship.

## References

1. Stocker JT, Drake RM, Madewell JE. Cystic and congenital lung disease in the newborn. *Perspect Pediatr Pathol* 1978;4:93.
2. Shanmugam G. Adult congenital lung disease. *Eur J Cardiothorac Surg* 2005;28(3):483–9.
3. Bentur L, Canny G, Thorner P, Superina R, Babyn P, Levison H. Spontaneous pneumothorax in cystic adenomatoid malformation. Unusual clinical and histologic features. *Chest* 1991;99(5):1292–3.
4. Hellmuth D, Glerant JC, Sevestre H, Remond A, Jounieaux V. Pulmonary adenomatoid malformation presenting as unilobar cysts in an adult. *Respir Med* 1998;92:1364–72.
5. Laberge JM, Puligandla P, Flageole H. Asymptomatic congenital lung malformations. *Semin Pediatr Surg* 2005;14(1):16–33.
6. Stocker JT. Congenital pulmonary airway malformation – a new name for and an expanded classification of congenital cystic adenomatoid malformation of the lung. *Histopathology* 2002;41:424.
7. Oermann Christopher M. *Congenital pulmonary airway (cystic adenomatoid) malformation*. UpToDate; 2010. [Web].
8. MacSweeney F, Papagiannopoulos K, Goldstraw P, Sheppard MN, Corrin B, Nicholson AG. An assessment of the expanded classification of congenital cystic adenomatoid malformations and their relationship to malignant transformation. *Am J Surg Pathol* 2003;27(8):1139–46.
9. Di Giorgio A, Mansour M, Cardini CL, Fonsi GB, Carmenini G, Gueli N. Congenital cystic adenomatoid malformation of the lung presenting as pyopneumothorax in an eighteen-year-old woman. *J Thorac Cardiovasc Surg* 2001;122(5):1034–6.
10. Luján M, Bosque M, Mirapeix RM, Marco MT, Asensio O, Domingo C. Late-onset congenital cystic adenomatoid malformation of the lung. *Respiration* 2002;69(2):148–54.
11. Alter SJ. Spontaneous pneumothorax in infants: a 10-year review. *Pediatr Emerg Care* 1997;13:401–3.
12. Boon D, Llewellyn T, Rushton P. A strange case of a tension pneumothorax. *Emerg Med J* 2002;19(5):470–1.
13. Moncrieff MW, Cameron AR, Astley R, Roberts KD, Abrams LD, Mann JR. Congenital cystic adenomatoid malformation of the lung. *Thorax* 1969;24:476–87.
14. Wexler HA, Dapena MV. Congenital cystic adenomatoid malformation. A report of three unusual cases. *Radiology* 1978;126:737–41.
15. Gaisie G, Oh KS. Spontaneous pneumothorax in cystic adenomatoid malformation. *Pediatr Radiol* 1983;13(5):281–3.
16. Heij HA, Ekkelkamp S, Vos A. Diagnosis of congenital cystic adenomatoid malformation of the lung in newborn infants and children. *Thorax* 1990;45:122–5.
17. Wolf SA, Rertzier JH, Philippart AI. Cystic adenomatoid dysplasia of the lung. *J Pediatr Surg* 1979;(15):925–30.

18. Wong A, Vieten D, Singh S, Harvey JG, Holland AJ. Long-term outcome of asymptomatic patients with congenital cystic adenomatoid malformation. *Pediatr Surg Int* 2005;**25**(6):479–85.
19. Lee SC, Cheng YL, Yu CP. Haemopneumothorax from congenital cystic adenomatoid malformation in a cryptorchidism patient. *Eur Respir J* 2000;**15**:430432.
20. Priest JR, Williams GM, Hill DA, Dehner LP, Jaffe A. Pulmonary cysts in early childhood and the risk of malignancy. *Pediatr Pulmonol* 2009;**44**:14.
21. Hill DA, Jarzembowski JA, Lennerz JK, Priest JR, Williams G, Schoettler P, et al. Type I pleuropulmonary blastoma: pathology and biology study of 51 cases from the International Pleuropulmonary Blastoma Registry. *Am J Surg Pathol* 2008;**32**:282–95.
22. Pinter A, Kalman A, Karsza L, Verebely T, Szemledy F. Long-term outcome of congenital cystic adenomatoid malformation. *Pediatr Surg Int* 1999;**15**:332–5.
23. Cloutier MM, Schaeffer DA, Hight D. Congenital cystic adenomatoid malformation. *Chest* 1993;**103**:761–4.
24. Frenckner B, Freyschuss U. Pulmonary function after lobectomy for congenital lobar emphysema and congenital cystic adenomatoid malformation. A follow-up study. *Scand J Thorac Cardiovasc Surg* 1982;**16**(3):293–8.