

CASE REPORT

Acute Pancreatitis Associated with Ifosfamide

Miao-Chiu Hung^{1,2}, Giun-Yi Hung^{1,2*}, Pei-Chin Lin³, Chui-Mei Tiu⁴, Yi-Ching Tien⁵

Departments of ¹Pediatrics, ⁴Radiology and ⁵Nursing, Taipei Veterans General Hospital and ²National Yang-Ming University School of Medicine, Taipei, and ³Department of Pediatrics, Kaohsiung Municipal Hsiao-Kang Hospital and Kaohsiung Medical University, Kaohsiung, Taiwan, R.O.C.

Acute pancreatitis is a rare complication during chemotherapy for pediatric patients with solid tumors. We report a 9-year-old boy with osteosarcoma who experienced 2 episodes of pancreatitis 1 day and 48 days after infusion of ifosfamide (IFOS), respectively. From a MEDLINE search, this is the 3rd reported case and 2nd reported pediatric case of IFOS-induced pancreatitis, and only this case experienced late-onset pancreatitis. [*J Chin Med Assoc* 2007;70(4):176–179]

Key Words: chemotherapy, ifosfamide, pancreatitis

Introduction

The etiology of childhood pancreatitis is known to be associated with trauma, gallstones, drugs, hypercalcemia, hypertriglyceridemia or idiopathic causes. Various drugs, including azathioprine, cimetidine, erythromycin, furosemide, hydrochlorothiazide, interferon- α , mesalazine, methyl dopa, metronidazole, tetracycline, valproate, and asparaginase have been found to induce acute pancreatitis.¹ Ifosfamide (IFOS) is an active drug against a variety of neoplasms, including rhabdomyosarcoma, non-rhabdomyosarcoma soft tissue sarcoma, osteosarcoma, and neuroblastoma.² It is relatively well tolerated in most patients. However, its side effects, such as arrhythmias, heart failure, severe encephalopathy and hemorrhagic cystitis might be fatal.³ Its other known side effects include myelosuppression, nephrotoxicity, neurotoxicity, Fanconi syndrome and psychosis.^{4,5} Only 2 cases of IFOS-induced pancreatitis have been reported previously.^{5,6} Here, we present a pediatric patient with IFOS-induced pancreatitis and compare the clinical characteristics of these 3 cases.

Case Report

A 9-year-old boy with osteosarcoma over the left proximal tibia diagnosed in June 2004 received chemotherapy at the Pediatric Department, Taipei Veterans

General Hospital. The chemotherapeutic protocol adopted at our hospital for nonmetastatic osteosarcoma over limbs comprises 4 drugs, including high-dose methotrexate, cisplatin, doxorubicin and IFOS.

The dosage of IFOS was 3 g/m²/day continuous drip for 5 days, for 2 courses of neoadjuvant chemotherapy. The patient underwent wide resection with limb salvage surgery in October 2004, and then adjuvant chemotherapy was commenced. In November 2004, while IFOS was being administered for the 3rd time, he complained of abdominal fullness, abdominal discomfort and nausea during infusion of drug. Due to persistent abdominal pain and bile-stained vomiting 1 day after the end of IFOS infusion, kidney, ureter and bladder (KUB) X-ray study, serum amylase, and lipase were checked. The result of KUB showed presence of colon cutoff sign (Figure 1A). Serum amylase and lipase were 1,173 U/L (normal, <180 U/L) and 5,027 U/L (normal, <190 U/L), respectively. The other laboratory results were 75 mg/dL for serum triglyceride (normal range, 20–200 mg/dL), and normal for aspartate transaminase and alanine transaminase. Abdominal computed tomography (CT) was performed and revealed swelling of pancreas with peripancreatic fat stranding. Fluid accumulated in the peripancreatic area, lesser sac, paraduodenal and left anterior pararenal space. The findings were compatible with acute pancreatitis, grade E (Balthazar's severity grade) (Figure 1B and C). After supportive treatment and total parenteral

*Correspondence to: Dr Giun-Yi Hung, Department of Pediatrics, Taipei Veterans General Hospital, 201, Section 2, Shih-Pai Road, Taipei 112, Taiwan, R.O.C.

E-mail: gyhung@vghtpe.gov.tw • Received: June 8, 2006 • Accepted: January 31, 2007

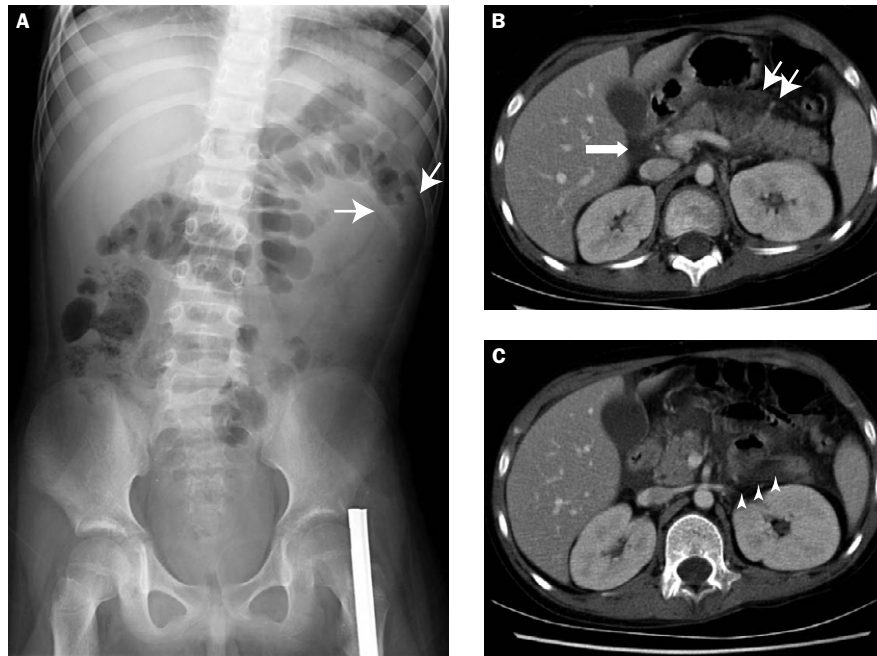


Figure 1. (A) Kidney, ureter and bladder show colon cutoff sign (arrows). (B,C) Computed tomography postcontrast shows swelling of the pancreas and peripancreatic fat stranding. Fluid has accumulated in the peripancreatic area (small arrows), lesser sac, paraduodenal space (big arrow), and left anterior pararenal space (arrowheads). The findings were compatible with acute pancreatitis grade E (Balthazar's severity grade).

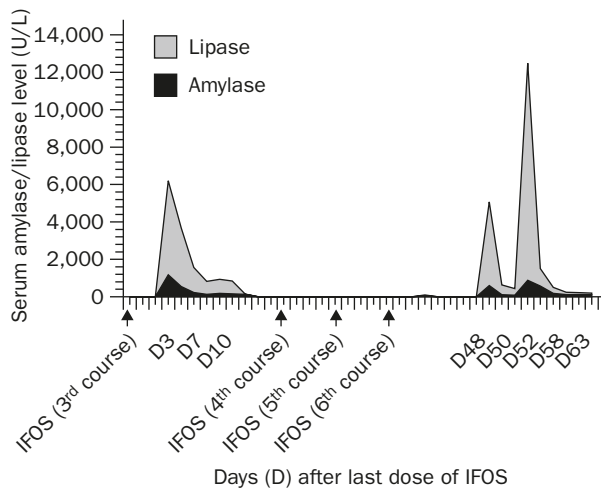


Figure 2. Acute pancreatitis with elevation of amylase and lipase levels after administration of the 3rd and 6th course of ifosfamide.

nutrition for 4 days, the patient's condition improved quickly. The level of amylase/lipase returned to normal 10 days later.

The dosage of subsequent IFOS was reduced to 2.4 g/m²/day for 5 consecutive days due to severe myelosuppression. The administration of a 4th and 5th course of IFOS was smooth in February 2005 and May 2005. Follow-up amylase/lipase levels in early

June were 81/46 U/L. A 6th course of IFOS was prescribed in late June 2005. Vomiting and epigastralgia developed 7 days after the end of infusion. Serum amylase/lipase levels were within normal limits (52 and 50 U/L, respectively), and abdominal sonography revealed no abnormal findings. The patient then suffered from neutropenic fever and received antibiotic treatment with meropenem. Amphotericin B was also prescribed for a total of 21 days when stool culture yielded *Candida glabrata*.

Vomiting and abdominal pain developed again in late August 2005, 48 days after the end of infusion of the last IFOS. Serum amylase/lipase levels were 600/4,475 U/L, compatible with acute pancreatitis. Magnetic resonance cholangiopancreatography revealed pancreatitis grade C, without dilatation of the pancreatic duct. The patient received supportive treatment, and amylase/lipase levels decreased to 80/366 U/L 4 days later. Due to improvement in his general condition, he started oral intake. However, abdominal pain developed again and elevation of amylase/lipase levels to 879/11,610 U/L was noted. Under supportive care, amylase/lipase returned to normal range 18 days later (Figure 2).

The whole chemotherapeutic regimen was completed in July 2005. Currently, he is well and being followed up as an outpatient.

Table 1. Characteristics of the 3 patients with ifosfamide (IFOS)-induced pancreatitis

Study	Age (yr)/sex	Diagnosis	IFOS dose (g/m ² /day)	Onset (days after final dose)	Highest amylase/lipase level (U/L)	Days to subside
Izraeli et al (1994) ⁵	16/F	Osteosarcoma with multiple lung, kidney and liver metastases	1.8 for 3 d	1	1,378/554	10
			1.2 for 3 d	1	1,956/8,340	10
Gerson et al (1997) ⁶	65/F	Small cell lung cancer metastatic to right adrenal and central nervous system	1.2 for 2 d (dose on 3 rd day was omitted)	2	452/402	6
Present study	9/M	Localized osteosarcoma over left proximal tibia	3 for 5 d	1	1,173/5,027	10
			2.4 for 5 d	48	879/11,610	18

Discussion

Without rechallenge, diagnosis of drug-induced pancreatitis is difficult. Though ondansetron and dexamethasone could cause acute pancreatitis, both anti-emetics had been prescribed during every course of chemotherapy.^{7,8} Besides, amphotericin B and meropenem, used for neutropenic fever before the second episode of pancreatitis in our patient, seemed to have no association with pancreatitis. This patient was young, on regular diet and not overweight. He denied history of smoking, alcohol or gallstone. Before he suffered both episodes of acute pancreatitis, he had no signs of viral infection. Therefore, there was no further study for virus. Hyperlipidemia and hypercalcemia were both excluded by laboratory results. Imaging studies, including CT and magnetic resonance cholangiopancreatography, eliminated the possibility of neoplasm, gallstone, or pancreas divisum. Notably, both his episodes happened after chemotherapy with IFOS. The 1st episode developed 1 day after the end of IFOS infusion, while the 2nd was noticed 48 days later. Since other possible causes of pancreatitis were excluded, IFOS should account for the cause of pancreatitis.

As to the pathogenesis, the 1st episode of pancreatitis 1 day after the end of infusion of IFOS could be an allergic reaction or due to direct toxicity. However, delayed onset of the 2nd episode of pancreatitis may be an immunologically mediated allergic reaction that may develop a few weeks after administration of the drug.⁸ However, further study of the details is still warranted.

Additionally, because we do not routinely check amylase and lipase levels during or after chemotherapy with IFOS, the prevalence of IFOS-induced pancreatitis may be underestimated. This patient did experience various degrees of abdominal discomfort during

every course of chemotherapy with IFOS. Since abdominal symptoms, such as nausea and vomiting, are common during chemotherapy, we may not include the diagnosis of pancreatitis initially. Even though pancreatitis develops, patients may show recovery with poor oral intake for a few days. Thus, we hypothesize that subclinical pancreatitis associated with IFOS does occur. This may account for there being no evidence of acute pancreatitis in our patient after the 4th and 5th course of IFOS.

There are 2 other case reports of IFOS-induced pancreatitis in the literature. Izraeli et al⁵ reported the 1st case in 1994. A 16-year-old girl experienced 2 episodes of acute pancreatitis, both developed 1 day after completion of IFOS infusion. The 2nd case was reported by Gerson et al⁶ in 1997. A 65-year-old female had pancreatitis 2 days after the last dose of IFOS. In comparison, our patient suffered the 1st episode of acute pancreatitis 1 day after the end of infusion of IFOS, similar to the previous reports. Nonetheless, the 2nd episode in our patient is the most delayed onset. The characteristics of these 3 patients are summarized in Table 1.

In these 3 cases, the total dosage of IFOS ranged from 2.4 to 15 g/m² and seemed not to be related to risk or severity of acute pancreatitis. It may be owing to the limited number of cases.

In conclusion, though most drug-induced pancreatitis is self-limited, it could be a potentially serious complication. IFOS could account for pancreatitis, even 48 days after infusion of the drug.

References

1. Manfred H, Lester R. Drug-induced pancreatitis: lessons in data mining. *Br J Clin Pharmacol* 2004;58:560-2.

2. Carli M, Passone E, Perilongo G, Bisogno G. Ifosfamide in pediatric solid tumor. *Oncology* 2003;65:99–104.
3. Klastersky J. Side effects of ifosfamide. *Oncology* 2003;65:7–10.
4. Garcia AA. Ifosfamide-induced Fanconi syndrome. *Ann Pharmacother* 1995;29:590–1.
5. Izraeli S, Adamson PC, Blaney SM, Balis FM. Acute pancreatitis after ifosfamide therapy. *Cancer* 1994;74:1627–8.
6. Gerson R, Serrano A, Villalobos A, Sternbach GL, Varon J. Acute pancreatitis secondary to ifosfamide. *J Emerg Med* 1997;15:645–7.
7. Alberti-Flor JJ. Pancreatitis associated with ondansetron. *J Natl Cancer Inst* 1995;87:689–90.
8. Feldman M. Acute pancreatitis. In: Sleisenger MH, Fordtran JS, Feldman M, eds. *Sleisenger and Fordtran's Gastrointestinal and Liver Disease*, 7th edition. Philadelphia: Saunders, 2002:919.