




Available online at
 ScienceDirect
www.sciencedirect.com

Elsevier Masson France

www.em-consulte.com

**Orthopaedics
& Traumatology**
 Surgery & Research

CLINICAL REPORT

Traumatic injury to a wrist with incidental Madelung's deformity

J.K. Dickson*, D. Williams, D. Standley

Department of Plastic Surgery, Royal Devon and Exeter Hospital, Devon, EX2 5DW, UK

Accepted: 14 December 2009

KEYWORDS

Madelung's;
 Distal radius;
 Fracture

Summary We present a longstanding case of subtle Madelung's deformity in association with a new traumatic radial styloid fracture. Magnetic resonance imaging accurately distinguished this deformity from an acute fracture and highlighted the correct cause of the patient's pain. An unnecessary procedure was avoided.

Published by Elsevier Masson SAS.

Introduction

Madelung's deformity is a rare developmental abnormality with a prevalence of less than 0.03% [1]. We report a case of previously undiagnosed Madelung's deformity identified incidentally in a patient with a fracture of the distal radius.

Case report

An 18 year-old girl fell awkwardly onto an outstretched hand while play fighting with a friend and attended the Accident and Emergency Department complaining of a painful wrist. The distal radius was tender. Radiographic imaging of the wrist revealed the abnormality (Fig. 1). There was no contralateral deformity and radiographs were not taken of the patient's asymptomatic contralateral wrist. The patient

was admitted for computerised tomographic imaging and planned open reduction and internal fixation of the fracture. Opinion was divided at our morning trauma meeting, regarding appropriate non-operative or operative management of this patient. Close inspection of the CT images raised the

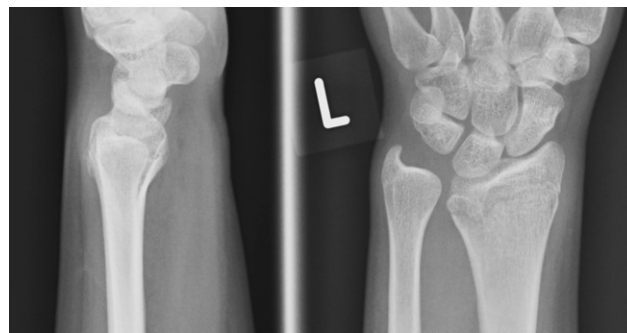

Figure 1 Postero-anterior radiograph of the wrist revealing subtle Madelung's deformity discovered incidentally following injury to the wrist: the V-carpus and prominent ulnar can be seen.

* Corresponding author. Tel.: +441392412279;
 fax: +441392402894.

E-mail address: john.k.dickson@gmail.com (J.K. Dickson).

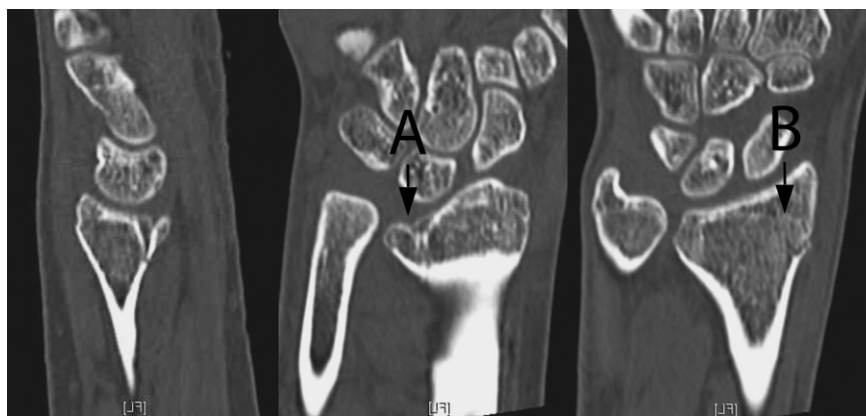

Figure 2 Computerised tomographic imaging of the wrist showing the two abnormalities. A. Madelung's deformity. B. Radial styloid fracture.

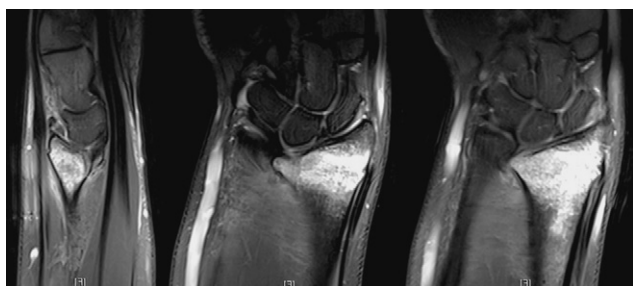

Figure 3 T2 weighted magnetic resonance imaging of the wrist demonstrating old changes at the ulnar-volar aspect of the distal radius (without associated high signal) and a cortical breach of radial styloid with an associated focus of high signal consistent with a new fracture.

possibility that the abnormality seen could represent an old condition (Fig. 2). T2 weighted magnetic resonance imaging of the wrist (Fig. 3) confirmed an old Madelung's deformity (without associated high signal) and a cortical breach of the radial styloid with an associated focus of high signal consistent with an undisplaced fracture. The patient was managed non-operatively resulting in a pain free wrist when reviewed at the 3-month clinic follow-up appointment.

Discussion

Madelung wrote the first complete and accurate description of the Madelung's deformity in 1878 [2]. The deformity most commonly affects young girls between 8 and 13 years of age, is often bilateral and has been linked to dyschondrosteosis, a form of mesomelic dwarfism [3]. It affects the volar, ulnar aspect of the distal radial physis leading to a characteristic deformity at the wrist. The radius is shortened and curved, the distal radioulnar joint is wide and the proximal carpal row becomes V-shaped (the so-called V-carpus) [2–5].

Madelung's deformity can lead to pain and stiffness and there can be aesthetic considerations if the deformity is severe [3]. In 1977, an extensive study of 1,476 patients

with congenital hand and wrist malformations revealed only 37 cases of Madelung's deformity [2]. This group of 1,476 patients represented 1–2% of the population as a whole and, of them, only 1.7% had Madelung's deformity; an overall prevalence, therefore, of less than 0.03%. However, this does not include the more subtle cases of the deformity that, in the absence of symptoms, may go undiagnosed.

Madelung's deformity should be considered in the assessment of an atypical distal radial fracture, particularly if the patient is a young girl. This case of a rather subtle abnormality divided opinion regarding optimum management in our centre. Operative treatment of a proven fracture with greater than 1 mm articular displacement is considered appropriate [6]. However, with the benefit of hindsight and a complete set of reported images, non-operative treatment of this patient with an undisplaced radial styloid fracture and a previously asymptomatic Madelung's deformity was the best course. If doubt exists in such cases MR imaging is effective in distinguishing between a longstanding developmental abnormality and a true fracture.

Conflict of interest statement

None.

References

- [1] Flatt AE. The congenital hand anomalies. St Louis: The C. V. Mosby Co; 1977.
- [2] Arora AS, Chung KC, Otto W. Madelung and the recognition of Madelung's deformity. *J Hand Surg Am* 2006;31:177–82.
- [3] Henry A, Thorburn MJ. Madelung's deformity. A clinical and cytogenetic study. *J Bone Joint Surg Br* 1967;49:66–73.
- [4] McCarroll Jr HR, James MA, Newmeyer 3rd WL, et al. Madelung's deformity: quantitative assessment of x-ray deformity. *J Hand Surg Am* 2005;30:1211–20.
- [5] Zebala LP, Manske PR, Goldfarb CA. Madelung's deformity: a spectrum of presentation. *J Hand Surg Am* 2007;30:1393–401.
- [6] Tumble TE, Culp RW, Hanel DP, et al. Intra-articular fractures of the distal aspect of the radius. *Instr Course Lect* 1999;48:465–80.