

CASE REPORT

Extrasosseous Osteogenic Sarcoma

Shao-Ying Lin^{1,4}, Wei-Ming Chen^{1,4}, Hungta H. Wu^{2,4}, Winby York-Kwan Chen^{3,4}, Tain-Hsiung Chen^{1,4*}

Departments of ¹Orthopedics and Traumatology, ²Radiology, and ³Pathology, Taipei Veterans General Hospital, and ⁴Institute of Surgery, National Yang-Ming University School of Medicine, Taipei, Taiwan, R.O.C.

Extrasosseous osteogenic sarcoma is a very rare malignant neoplasm. Out of the more than 400 cases of soft tissue sarcomas on file in our hospital, only 2 were extrasosseous osteogenic sarcomas. Both were situated in the thigh. The first case was initially diagnosed as a hematoma and treated by marginal excision. The diagnosis of high-grade osteosarcoma primarily arising in soft tissue was made from histopathologic examination. Radiotherapy of 60 Gy in 30 fractions was given postoperatively. The second patient, primarily diagnosed as having a soft tissue sarcoma, was treated by wide excision. The final pathologic report was high-grade extrasosseous osteogenic sarcoma. Adjuvant chemotherapy was given postoperatively. Both patients are alive without local recurrence and distant metastasis at postoperative 90-month and 107-month follow-up, respectively. [*J Chin Med Assoc* 2005;68(11):542-545]

Key Words: extrasosseous, osteogenic sarcoma, soft tissue sarcoma

Introduction

Extrasosseous osteogenic sarcoma of the somatic soft tissue is an extremely rare type of tumor, constituting only 1.2% of all soft tissue sarcomas.¹ The first case was reported by Wilson in 1941.² Since then, less than 200 cases have been reported in the English literature.¹⁻¹¹ The tumors occur in middle-aged and elderly patients. A previous report showed that the response of extrasosseous osteogenic sarcoma to multimodality therapy is not as good as that of intraosseous osteogenic sarcoma.⁴ Out of the more than 400 cases of soft tissue sarcomas on file in our hospital, only 2 were extrasosseous osteogenic sarcomas. The present study reviews these 2 cases from all of the 102 osteogenic sarcomas recorded at our institution during the 10-year period from 1990 to 1999.

Case Reports

Case 1

A 68-year-old woman had noted a small mass over her left thigh since the early 1970s, after a fall from a stairway. In the past 8 months, the mass progressively

enlarged and a painful sensation developed over her left thigh, but there was no obvious trauma. She was, therefore, taken to our clinic and admitted for further treatment in November 1996.

On physical examination, a tender movable soft tissue mass, about 8 cm in diameter, over the medial aspect of her left thigh was found. Radiography revealed a soft tissue mass with calcification over the left thigh (Figure 1). As the mass had grown very slowly over the years, the initial impression was that it was a benign lesion. Computer tomography of the lungs and whole body bone scintigraphy showed no lung or bone involvement. The tumor, measuring 9 × 7 × 6 cm, was excised with a margin. Microscopically, a network of eosinophilic, irregular and glassy osteoid structures interposed with pleomorphic-nuclei spindle cells were seen (Figure 2). The diagnosis of extrasosseous osteogenic sarcoma was made. Fortunately, the cut margins and skin were free of tumor cells.

As the margin of the tumor excision was not wide enough, postoperative radiotherapy with 60 Gy in 30 fractions was given. However, the patient refused any kind of chemotherapy. After 90 months of follow-up, she was alive without evidence of local recurrence or distant metastasis.

*Correspondence to: Dr. Tain-Hsiung Chen, Department of Orthopedics and Traumatology, Taipei Veterans General Hospital, 201, Section 2, Shih-Pai Road, Taipei 112, Taiwan, R.O.C.
E-mail: thchen@vghtpe.gov.tw • Received: June 18, 2004 • Accepted: December 23, 2004

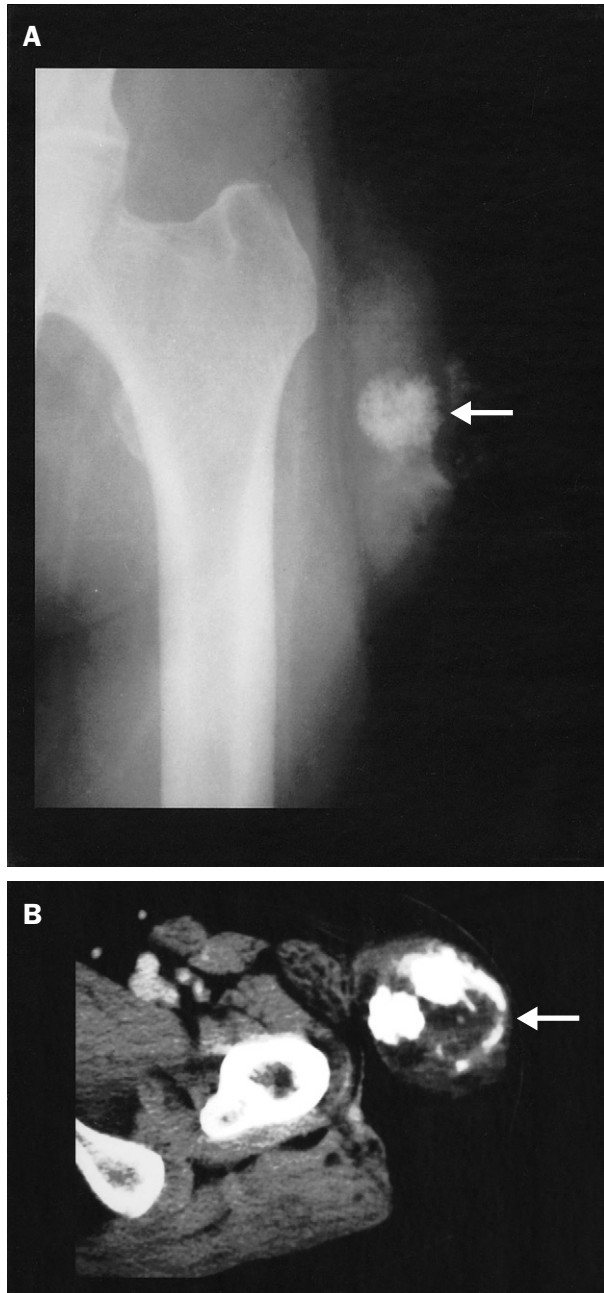


Figure 1. (A) X-ray shows a soft tissue mass with calcification over the left thigh (arrow). (B) Computed tomography scan shows a soft tissue mass with calcification arising from the soft tissue, without bony involvement (arrow).

Case 2

A 69-year-old woman had undergone modified radical mastectomy for breast adenocarcinoma in 1974. After the operation, she was continuously free of the disease. However, she found a small nodule over her left thigh, just below the inguinal area, in March 1995, 3 months prior to presentation. The soft tissue mass grew rapidly and became painful. A plain radiograph and magnetic

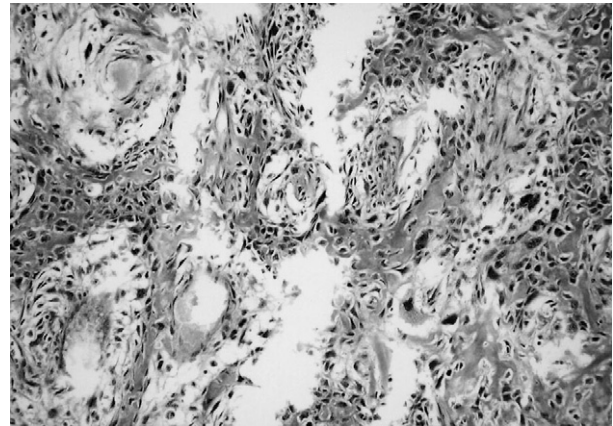


Figure 2. Case 1: a network of eosinophilic irregular and glassy osteoid structures interposed with pleomorphic-nuclei spindle cells.

resonance imaging (MRI) of the left proximal femur showed a calcified soft tissue mass over the upper medial thigh without a skeletal lesion (Figure 3). As the mass grew rapidly and MRI showed central necrosis, malignancy was highly suspected. Wide excision was performed. The neurovascular bundle lateral to the mass was well protected and preserved. Histopathologic examination revealed extraosseous osteogenic sarcoma with muscle involvement (Figure 4). The cut margins were free of tumor cells. Adjuvant chemotherapy with cisplatin and doxorubicin was administered postoperatively. No local recurrence or distant metastasis was noted from a postoperative 105-month follow-up.

Discussion

Extraosseous osteogenic sarcoma arising from soft tissue constitutes 1.2% of all soft tissue sarcomas.¹ At the Rosewell Park Memorial Institute, 4.6% of all osteogenic sarcomas were of soft tissue origin. A similar incidence has been reported by Allan and Soule,¹ and Wurlitzer et al.³

At the Memorial Sloan-Kettering Cancer Center, a review of 48 cases of extraosseous osteogenic sarcoma during 1950–1983 showed the median age at diagnosis to be 51 years (range, 6–80 years).⁴ The most common primary sites were the thighs and buttocks (26 cases, 54.2%). Spotty areas of calcification were seen in preoperative radiographs of the tumor in about half of the cases. Forty-one (91.1%) of the 45 patients who had been followed for more than 1 year developed local recurrence and/or distant metastasis.

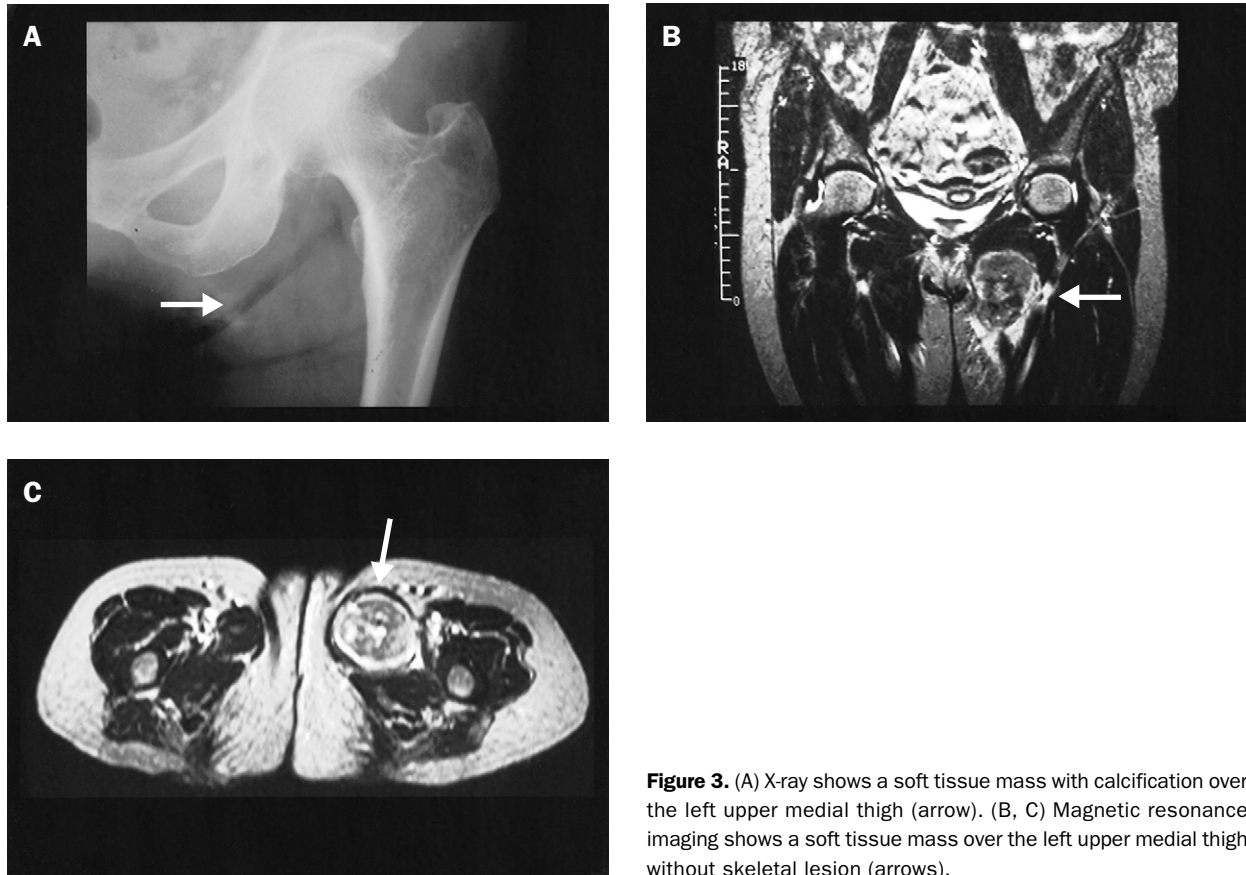


Figure 3. (A) X-ray shows a soft tissue mass with calcification over the left upper medial thigh (arrow). (B, C) Magnetic resonance imaging shows a soft tissue mass over the left upper medial thigh without skeletal lesion (arrows).

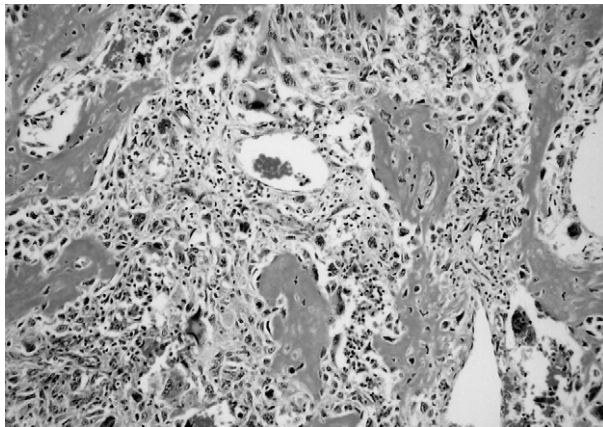


Figure 4. The tumor is composed of osteoid and atypical osteoblasts with muscle involvement. It is a high-grade tumor similar to conventional osteosarcoma.

While osteogenic sarcoma of bone occurs most frequently in children and adolescents, patients with extrasosseous osteogenic sarcomas are usually older than 40 years. A recent review of the literature placed the mean age of patients with extrasosseous osteogenic sarcoma at 53 years.⁵ Our 2 patients were older than

53 years of age (68 and 69 years). The common mode of presentation is swelling of insidious onset, with associated pain in approximately 1-third of patients. Frequently, the tumor grows to a large size before the patient seeks medical advice. The mean duration of symptoms before diagnosis was 3 months.⁴ The duration of symptoms before diagnosis in our 2 patients were 8 and 3 months. Previous radiation therapy is a well-known predisposing factor for the development of both soft tissue and bone sarcoma.⁶ The role of trauma in the incidence of extrasosseous osteogenic sarcoma is controversial. Several authors have suggested that trauma can be an important etiologic factor in the development of these neoplasms.⁷ One of our 2 patients had a history of trauma.

Radiographic examination of the soft tissue is essential to rule out any continuity of the tumor with bone. If adjacent bone shows radiologic changes of involvement by the tumor, it is most likely to be sarcoma originating from the bone rather than from the soft tissue. A soft tissue mass with spotty calcification without adjacent bone involvement is one of the classic radiographic appearances of this tumor, which were seen in our 2 cases.

The single most important criterion for diagnosis of this tumor is the presence of malignant osteoid.⁸ Indeed, a variable amount of fibroblastic and chondroblastic components may also be present. In limited biopsy material, in the absence of malignant osteoid and malignant chondrocytes, extraosseous osteogenic sarcoma may resemble malignant giant cell tumor or malignant fibrous histiocytoma of soft tissue. Therefore, specific histologic identification should be done only after generous sampling of the neoplasm. In addition, this tumor should be differentiated from myositis ossificans. The presence of a wide spectrum of malignant neoplastic elements and conspicuous absence of inflammatory cells and areas of hemorrhagic necrosis help to rule out myositis ossificans.

Wide local excision, with at least a 5-cm margin of normal tissue, should be the treatment of choice. If this is not feasible due to the anatomic location of the tumor, amputation should be recommended.⁹ Due to the high tendency of extraosseous osteogenic sarcoma to recur after resection, simple excision or enucleation of the tumor should not be considered. Since recurrence occurs mostly within 2 years after treatment, adjuvant chemotherapy and radiotherapy might be of benefit. However, a review of 48 cases of extraosseous osteogenic sarcoma and 39 trials of chemotherapy agents or combinations, including 16 combinations containing doxorubicin, showed that no patients had a major response.⁴ The average 5-year survival rates in 5 previous studies range from 15% to 25%.^{1,3,5,6,10} Around 80% of patients died within 2–3 years. These survival rates are comparable with those of “classic” type osteogenic sarcoma and poorly differentiated soft tissue sarcoma. Fortunately, both of our patients

(1 received wide excision and adjuvant chemotherapy, the other received marginal excision and postoperative radiotherapy) continue to be disease-free. The reasons for these encouraging results are unknown, but we should not underestimate the severity of the disease. Careful preoperative evaluation and multimodal treatment are essential in the management of patients with extraosseous osteogenic sarcoma.

References

1. Allan CJ, Soule EH. Osteogenic sarcoma of the soft tissue: a clinicopathologic study of 26 cases and review of the literature. *Cancer* 1971;27:1121–33.
2. Wilson H. Extraskeletal ossifying tumors. *Ann Surg* 1941;113:95–112.
3. Wurlitzer F, Ayala A, Romsdahl M. Extraosseous osteogenic sarcoma. *Arch Surg* 1972;105:691–5.
4. Sordillo PP, Hajdu SI, Magill GB, Golbey RB. Extraosseous osteogenic sarcoma: a review of 48 patients. *Cancer* 1982;51:727–34.
5. Rao U, Cheng A, Didolkar MS. Extraosseous osteogenic sarcoma: clinicopathological study of eight cases and review of literature. *Cancer* 1978;41:1488–96.
6. Lee WR, Laurie J, Townsend AL. Fine structure of a radiation-induced osteogenic sarcoma. *Cancer* 1975;76:1414–25.
7. Fine G, Stout AP. Osteogenic sarcoma of the extraskeletal soft tissue. *Cancer* 1956;9:1027–43.
8. Loretson R, Larsson SE, Boquist L. Extraosseous osteosarcoma: a clinical and histological study of four cases. *J Bone Joint Surg (Br)* 1979;61:205–8.
9. Lewis RJ, Lotz MJ, Beazley RM. Extraosseous osteogenic sarcoma: case report and approach to therapy. *Ann Surg* 1974;40:597–600.
10. Das Gupta TK, Hajdu SI, Foote FW. Extraosseous osteogenic sarcoma. *Ann Surg* 1968;168:1011–22.
11. Milosevic D. Extraosseous osteosarcoma—two cases. *Int Orthop* 1981;5:43–5.