

The spectrum, management and clinical outcome of Ehlers-Danlos syndrome type IV: A 30-year experience

Gustavo S. Oderich, MD,^a Jean M. Panneton, MD,^b Thomas C. Bower, MD,^a Noralane M. Lindor, MD,^c Kenneth J. Cherry, Jr, MD,^a Audra A. Noel, MD,^a Manju Kalra, MBBS,^a Timothy Sullivan, MD,^a and Peter Glociczki, MD,^a Rochester, Minn; and Norfolk, Va

Purpose: Ehlers-Danlos syndrome type IV (EDS-IV) results from abnormal procollagen III synthesis and leads to arterial, intestinal, and uterine rupture. The purpose of this study was to review the spectrum, management, and clinical outcome of EDS-IV patients.

Methods: We retrospectively reviewed the clinical data of 31 patients (15 male and 16 female) with a clinical diagnosis of EDS-IV treated over a 30-year period (1971 to 2001). Biochemical confirmation was obtained in 24 patients, and mutation of the *COL3A1* gene was confirmed in 11 patients. The study excluded patients with other connective tissue dysplasias.

Results: The mean age at the time of diagnosis was 28.5 ± 11 years (range, 10 to 53 years). Twenty-four patients developed 132 vascular complications; of these, 85 were present either before or at the time of the initial evaluation, and 47 complications occurred during a median follow-up of 6.3 years (range, 0.5 to 26 years). Survival free of vascular complications was 90% at age 20 years, 39% at 40 years, and 20% at age 60 years. Fifteen patients underwent 30 operative interventions for vascular complications, including arterial reconstruction ($n = 15$), simple repair or ligation ($n = 4$), coil embolization ($n = 3$), splenectomy ($n = 2$), and abdominal decompression, nephrectomy, graft thrombectomy, vein stripping and thoracoscopy ($n = 1$ each). Three hospital deaths occurred from exsanguinating hemorrhage: two after operative interventions and one because of a ruptured splenic artery. Procedure-related morbidity was 46%, including a 37% incidence of postoperative bleeding and a 20% need for re-exploration. The incidence of late graft-related complications was 40% of arterial reconstructions, including 4 anastomotic aneurysms, 1 fatal anastomotic disruption, and 1 graft thrombosis. Patient survival was 68% at age 50 years and 35% at age 80 years. Of the 12 deaths during the study period, 11 were associated with vascular or graft-related complications.

Conclusion: Operative mortality in patients with vascular complications of EDS-IV was not excessively high, but the incidence of postoperative bleeding complications and late graft-related problems was significant. Despite successful repair of vascular complications, survival was shortened because of secondary vascular or graft-related complications. (J Vasc Surg 2005;42:98-106.)

Ehlers-Danlos syndrome (EDS) is a term that encompasses a variety of types of inherited connective tissue disorders.¹⁻² Although most patients have the classic form with joint hypermobility, increased skin elasticity, and tissue fragility, EDS comprises a heterogeneous group of clinical syndromes with distinct inheritance, biochemical defects, and prognostic implications.¹⁻⁵ EDS type IV (EDS-IV), the vascular or arterial-ecchymotic type, is a rare autosomal dominant disorder resulting from mutations in the gene (*COL3A1*) encoding for type III procollagen synthesis.¹⁻⁵ Different from the other forms, EDS-IV may lead to premature death from spontaneous arterial, intestinal, or uterine rupture.⁶⁻⁸

Complications of EDS-IV are rare during childhood, but approximately 80% of patients have already experienced at least one complication by the age of 40.⁸ Patients are typically unaware of the diagnosis until they present, often to a vascular surgeon, with spontaneous arterial rupture or dissection. Management is challenging because of extreme tissue fragility, and numerous reports emphasize the exceedingly high risk of massive bleeding and anastomotic disruption with attempted operative repair.^{7,9-15}

Because no studies have reported long-term results after a successful operation or after watchful waiting of existing asymptomatic vascular lesions, we conducted a retrospective review of our experience with EDS-IV patients evaluated and treated during the last three decades. The purpose of this study was to review the spectrum, management, and clinical outcome in these patients.

METHODS

We used the vascular surgery and medical genetics registries to identify 31 patients with EDS-IV who were evaluated at the Mayo Clinic between January 1, 1971, and January 1, 2001. Clinical diagnosis was made from at least two of four major diagnostic criteria, as defined by the revised nosology of Villefranche, 1977: thin, translucent

From the Division of Vascular Surgery^a and Department of Medical Genetics,^{ac} Mayo Clinic; and Vascular and Transplant Specialists and Eastern Virginia Medical School.^b

Competition of interest: none.

Presented at the Twenty-ninth Annual Meeting of the Southern Association for Vascular Surgery, Marco Island, Fla, Jan 19-22, 2005.

Correspondence: Jean M. Panneton, MD, Vascular and Transplant Specialists, Brambleton Medical Center, 250 West Brambleton Avenue, Suite 101, Norfolk, VA 23510 (e-mail: jpanneton@vascularandtransplant.com).

0741-5214/\$30.00

Copyright © 2005 by The Society for Vascular Surgery.

doi:10.1016/j.jvs.2005.03.053

Table I. Clinical features of 31 patients with Ehlers-Danlos syndrome type IV according to the revised nosology, Villefranche, 1997²

Diagnostic clinical criteria	n	%
Major criteria		
Easy bruising	30	97
Arterial, intestinal or uterine fragility	26	84
Thin, translucent skin	24	77
Characteristic facial features*	9	29
Minor criteria		
Small joint hypermobility	18	58
Skin hyperextensibility	13	42
Spontaneous pneumothorax/hemothorax	5	16
Tendon or muscle rupture	4	13
Early-onset varicose veins	2	6
Talipes equinovarus (clubfoot)	1	3
Carotid-cavernous fistula	1	3
Family history of EDS-IV	18	58
Risk factors for atherosclerosis		
Hypertension	8	26
Hyperlipidemia	4	13
Cigarette smoking	3	10
Diabetes mellitus	2	6
Coronary artery disease	1	3

EDS-IV, Ehlers-Danlos syndrome type IV.

*Characteristic facial features include thin, delicate, and pinched nose; hollow cheeks and prominent staring eyes because of paucity of adipose tissue.

skin, extensive bruising, characteristic facial features, and a history of arterial, intestinal, or uterine fragility.² Comprehensive clinical and pedigree history were obtained by medical genetics consultation. Diagnostic confirmation included the demonstration of structurally abnormal type III procollagen molecules by using a culture of dermal fibroblasts or the presence of mutation in the *COL3A1* gene.

Demographics, risk factors for atherosclerosis, clinical presentation, and details of complications were collected from the patients' records. We determined the ages at the time of the clinical diagnosis and testing, time of complication, and time of death. We attempted to ascertain whether the complication or cause of death, or both, were associated with EDS-IV. Operative data, early and late medical and surgical morbidity, and mortality were recorded.

A *vascular complication* was defined as arterial or venous rupture, dissection, aneurysm formation, and organ rupture. Vascular complications included asymptomatic or incidental radiologic findings. *Early perioperative period* was defined as occurring in the hospital stay without regard to the number of days after the operation or ≤ 30 postoperative days.

Late follow-up data were obtained from medical records, office visits, correspondence with referring physicians, and telephone interviews. A detailed questionnaire was mailed to evaluate the presence of late complications and the need for secondary operative procedures. Late mortality data were also obtained using a national death index search. Survival curves were calculated using the Kaplan-Meier method. The study was approved by the institutional review board.

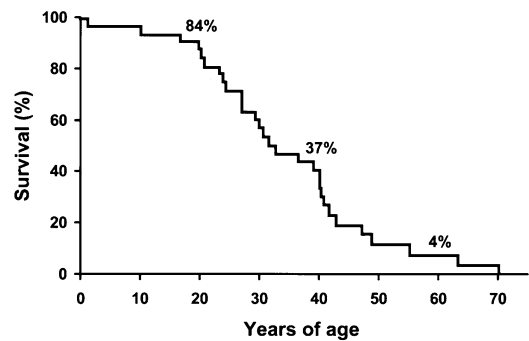


Fig 1. Kaplan-Meier estimates of survival free of any vascular, intestinal or uterine complication in 31 patients with clinical diagnosis of Ehlers-Danlos syndrome type IV.

RESULTS

Diagnosis. Fifteen male and 16 female patients met the diagnostic criteria summarized in Table I. Twenty-four patients (77%) had biochemical confirmation of abnormal procollagen III synthesis, including 11 patients who had confirmation of *COL3A1* gene mutation. Seven patients were diagnosed solely from clinical criteria. The mean age at the time of diagnosis was 28.5 ± 11 years, (range, 10 to 53 years). Fourteen patients with “EDS-like connective tissue dysplasia” were excluded from the study because they had normal type III procollagen ($n = 12$) or failed to meet clinical criteria ($n = 2$), including 11 patients with multiple vascular problems. Of the 31 patients with EDS-IV, only eight (26%) had an established diagnosis before they presented at our institution.

Twenty-six patients (84%) had a history of EDS-IV complications. Survival free of any arterial, intestinal, and uterine complication was 84% at age 20 years, 37% at 40 years, and only 4% at age 60 years (Fig 1). The most common complication was arterial rupture ($n = 14$), followed by intestinal rupture ($n = 7$) and postpartum complications ($n = 5$). A family history was positive for features suggestive of EDS-IV in 18 patients (58%), including history of vascular complications in 15, intestinal perforation in 7, and sudden, premature death in 5 patients. A pedigree analysis identified 60 family members at risk, of which 32 (53%) had findings suggestive of the diagnosis.

Radiologic investigation. Twenty-nine patients (94%) underwent noninvasive imaging studies, and 22 patients (76%) had positive findings (Table II). The abdominal and chest vessels were studied in 27 (87%) and 19 patients (61%), respectively. Thirteen patients (42%) underwent contrast arteriography, which yielded positive findings in 11 (85%). Serious complications developed after arteriography in three patients (23%), including two large access site hematomas and one carotid artery rupture during attempted embolization of a carotid-cavernous fistula. There was a wide spectrum of imaging findings in these patients (Fig 2, A to D).

Table II. Radiologic investigation in 29 patients with clinical diagnosis of Ehlers-Danlos syndrome type IV

Modality	Patients who underwent study		Patients with positive findings	
	N = 31	%	n	%
Noninvasive studies	29	94	22/29	76
Echocardiogram	28	90	8/28	29
Any head	12	39	4/12	33
CT	8	26	2/8	25
MRI	8	26	3/8	38
Any neck	22	71	7/22	32
US	22	71	7/22	32
CT	8	26	4/8	50
Any chest	19	61	12/19	63
CT	19	61	10/19	53
MRA	6	19	5/6	83
Any abdomen	27	87	13/27	48
US	9	29	7/9	78
CT	21	68	11/21	52
MRA	10	32	6/10	60
Arteriography	13	42	11/13	85
Cerebral	3	10	3/3	100
Arch and brachiocephalic arteries	8	26	7/8	87
Thoracic aorta	7	23	5/7	71
Abdominal aorta and branches	8	26	7/8	87
Lower extremity	5	16	3/5	60

CT, Computed tomography; MRI, magnetic resonance imaging; MRA, magnetic resonance arteriography; US, ultrasound.

Nonvascular complications. Nonvascular complications occurred in 20 patients (65%) and consisted of 7 (23%) spontaneous intestinal ruptures, 7 (23%) abdominal wall hernias, 5 (16%) spontaneous pneumothoraces, 5 (16%) major joint dislocations, and 3 (10%) lens dislocations. Five patients had pregnancy-related complications, including 3 postpartum hemorrhages (1 requiring hysterectomy), 2 miscarriages, and 1 uterine prolapse. De novo nonvascular complications occurred in seven patients (24%) and included five abdominal wall hernias and two postpartum hemorrhages. Overall, 15 patients had both vascular and nonvascular complications.

Vascular complications. Twenty-four patients (77%) developed 132 vascular complications (Fig 3). These include seven patients with diagnosis established solely from clinical criteria. A history of recent trauma was reported in only three patients. Eight patients (26%) had a history of prior interventions at outside institutions, including 2 subclavian artery ligations, 2 chest tube thoracostomies for hemothoraces, 1 embolization of carotid-cavernous fistula, 1 thoracic aneurysm repair, and 1 stripping of varicose vein. Of the 132 complications, 63 were symptomatic, 69 were incidental imaging findings, 78 were present prior or at time of initial evaluation, and 47 de novo complications occurred during a median follow-up of 6.3 years (mean, 8.2 ± 6.8 years; range, 0.5 to 26 years). Survival free of vascular complications was 90% at age 20 years, 39% at 40 years, and 20% at age 60 years (Fig 4).

The nature of 119 vascular complications was determined using imaging, operative, pathology, or autopsy findings. Most problems consisted of arterial dissections and dissecting aneurysms ($n = 57$, 48%) or arterial ruptures with or without contained hematomas ($n = 45$, 38%). True

fusiform aneurysms occurred in a minority of patients ($n = 17$, 14%). Three patients had cerebral aneurysms (10%), and one had a bilateral carotid-cavernous fistula. Four patients had early onset lower extremity varicose veins. Cardiac problems included 6 aortic, 2 mitral, and 1 tricuspid valve regurgitations. Organ rupture occurred in four patients and consisted of two spontaneous hemothoraces, and hepatic and splenic ruptures (one each).

Operative approach. Fifteen patients underwent 30 operative or interventional procedures (Table III), of which 70% were performed on an emergent or urgent basis. Indications were arterial rupture with active bleeding in 14 (47%), large aneurysm size in 10 (33%), and rapid aneurysm expansion in 2 (6.7%). Other indications included visceral or lower extremity ischemia, severe diplopia, and congestive heart failure (one each). There were 15 arterial reconstructions, including 5 interposition grafts, 4 abdominal aortic grafts (2 straight and 2 bifurcated), 3 ascending aortic grafts, 1 thoracic aortic graft, 1 carotid-subclavian bypass, and 1 femoropopliteal artery bypass. One patient underwent concomitant aortic valve replacement, and one patient had mitral valve replacement. The conduit of choice was polyester Dacron (DuPont) grafts in 14 cases and polytetrafluorethylene (PTFE) in one case.

One patient had an unplanned nephrectomy because of multiple renal arterial tears during attempted renal artery bypass. Two arterial ruptures were treated with simple repair and two with ligation. Other procedures included coil embolizations ($n = 3$), splenectomies ($n = 2$), and abdominal decompression, video-assisted thoracoscopy, and graft thrombectomy ($n = 1$ each).

Adjuncts included use of protected clamps or balloon occlusion for vascular control and buttressing of arterial

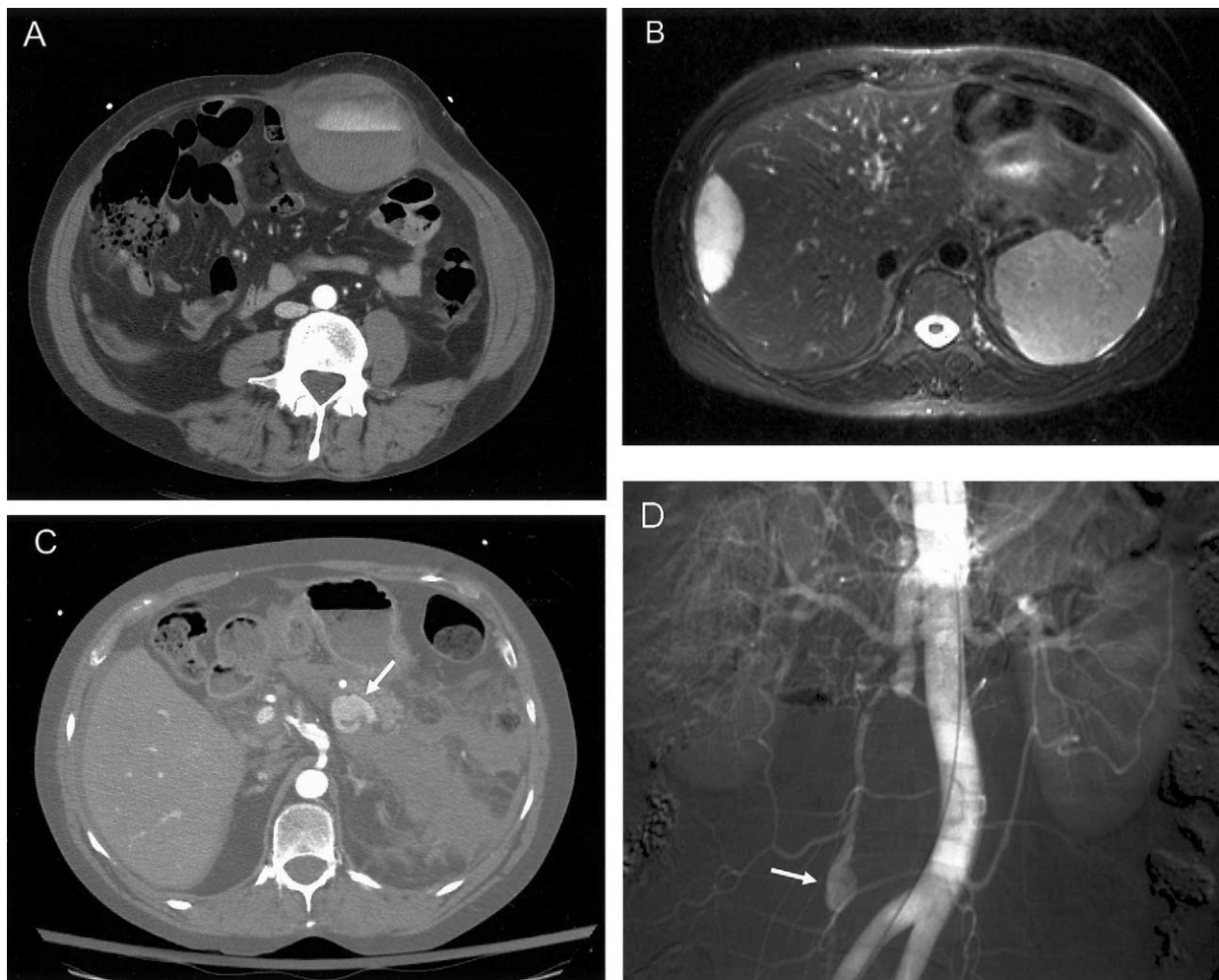


Fig 2. Wide spectrum of imaging findings in patients with clinical diagnosis of Ehlers-Danlos syndrome type IV, including (A) spontaneous inferior epigastric artery rupture, (B) spontaneous hepatic hematoma, (C) ectatic and dissected celiac axis with concomitant ruptured splenic vein aneurysm (*arrow*), and (D) ruptured ileocolic artery pseudoaneurysm confirmed by operative exploration (*arrow*).

anastomosis with Teflon (DuPont) felt strips in 14 cases. In one patient, the diagnosis of EDS-IV was established 10 years after stripping of saphenous vein.

The mean length of stay was 22 days (range, 3 to 90 days). Three hospital deaths occurred, including one patient who died en route to the operating room from a ruptured splenic artery. Two patients died from exsanguinating hemorrhage from anastomotic rupture and multiple arterial tears. The first patient had multiple prior vascular complications and had presented with a distal anastomotic rupture 8 years after a carotid-subclavian bypass. Despite an emergent operation, his tissues were extremely friable and vascular control could not be obtained. In the second patient, anastomotic and mediastinal bleeding developed immediately after an ascending aortic repair with concomitant aortic valve replacement. Despite attempted re-exploration to surgically control the bleeding, the patient died in the operating room.

Major morbidity occurred after 14 procedures (46%), and consisted of excessive bleeding in 11 patients (37%), which required re-exploration in 6 (20%); pulmonary complications in 6 (20%), renal failure in 3 (10%), and cardiac arrest, brachial plexopathy and prolonged ileus requiring parenteral nutrition in 1 patient each. The median follow-up in this group was 7.7 years (mean, 11 years; range, 2 to 22 years). Late graft-related complications occurred after six (40%) of the 15 arterial reconstructions, and consisted of 4 graft-anastomotic aneurysms, 1 anastomotic rupture, and 1 femoropopliteal graft thrombosis. All graft-related complications required operative repair.

Conservative approach. Forty-two vascular complications in 15 patients were approached conservatively at the time of the initial evaluation. These were followed for a median of 8.6 years (mean, 9 years; range, 0.1 to 22 years), with repeat imaging studies obtained in 13 patients (81%).

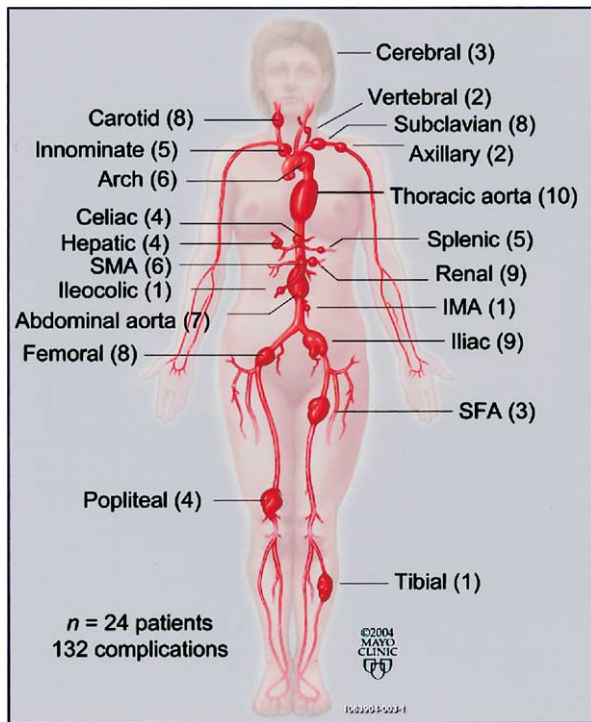


Fig 3. Distribution of 132 vascular complications in 24 patients with a clinical diagnosis of Ehlers-Danlos syndrome type IV.

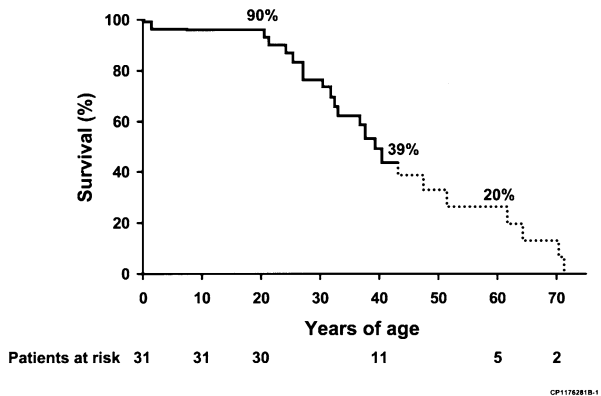


Fig 4. Kaplan-Meier estimates of survival free of vascular complications in 31 patients with a clinical diagnosis of Ehlers-Danlos syndrome type IV. The dotted line denotes >10% standard deviation.

Ten patients were started on β -blockers. Five patients (33%) developed 31 de novo vascular complications. Four patients (27%) died, two of them from rupture of existing vascular lesions. The first patient survived splenectomy and hepatic artery bypass for ruptured hepatic artery, but was treated conservatively for a carotid artery dissection and died of carotid artery rupture 3 years later. The second patient died from an innominate artery rupture 6 years after being diagnosed with innominate artery dissection. Two

patients died from de novo vascular complications, including an intra-abdominal hemorrhage of unknown source and a thoracic aortic rupture. Overall, six of the 42 existing vascular complications were associated with further problems, including 3 ruptures (2 fatal), 3 extensions of the dissecting process (1 resulting in kidney infarction), and 2 aneurysmal expansions.

Survival and cause of death. The median patient survival was 54 years of age. The overall patient survival was 98% at age 20 years, 68% at 50 years, and 35% at age 80 years (Fig 5). These figures were significantly decreased compared with the expected survival for age- and sex-matched general population controls. Overall, 12 patients died during the study period. The causes of death were probably associated with vascular complications in all except one patient (cancer). There were 5 confirmed arterial ruptures, 4 sudden deaths from probable arterial rupture, and 2 procedure-related deaths. No deaths were associated with uterine or intestinal complications.

DISCUSSION

EDS-IV is a challenging disorder. Although EDS as a broad category has an estimated prevalence of one in every 25,000 births, the arterial type is rare and accounts for <4% of EDS patients.^{1,6} The term *vascular* or *arterial-ecchymotic* EDS was coined by Barabas³⁻⁴ in 1967 to describe a subset of patients with increased vascular fragility. Later in 1975, Pope et al⁵ identified the biochemical basis of EDS-IV, a deficiency in the synthesis or secretion of type III procollagen. The distribution of type III procollagen predominantly in the skin, walls of blood vessels, and hollow organs explains its clinical manifestations. The biochemical defect was later found to result from heterozygous mutations in the *COL3A1* gene, located in the long arm of chromosome 2 and transmitted as an autosomal dominant condition.

The most recent EDS classification has been simplified from 11 into six distinct varieties: classical, hypermobility, vascular, kyphoscoliosis, arthrochalasia, and dermatosparaxis types.² The clinical diagnosis of EDS-IV, which is the vascular form of EDS, can be challenging because of its rarity and variable and subtle phenotypic features. This may explain why only 26% of our patients were aware of the diagnosis before presentation.

We found that excessive bruising and the tendency to form hematomas is the most frequent sign (97%). The history of tissue fragility is striking, and 84% of our patients had prior vascular, intestinal, or uterine complications typical of EDS-IV. The skin is not hyperextensible, but instead is thin, translucent, and has highly visible superficial veins, which are more apparent in the shoulders, chest, and abdomen. A characteristic facial appearance, with a thin, delicate, and pinched nose and prominent bones and eyes, was noticed in 30% of our patients. Severe joint hypermobility is uncommon; instead, EDS-IV patients typically have milder laxity involving small joints or even decreased mobility with contractures. Paradoxically, although the EDS-IV has less striking clinical features, it is clearly the most malignant type.

Table III. Operative details, indications for repair and clinical outcome in 15 patients with vascular complications of Ehlers-Danlos syndrome type IV

Patient	Age/ Sex	Clinical diagnosis*	Biochemical	COL3A1 gene	Vascular complication [†]	Operation	Clinical outcome (cause of death)
1	60M	3	No	No	Ruptured hepatic artery/splenic artery aneurysm	Interposition graft, splenectomy	Died at age 62 (aortic rupture)
2	16F	3	Yes	No	Ruptured femoral artery aneurysm Carotid-cavernous fistula Ruptured carotid artery	Interposition graft Coil embolization Simple repair with Teflon sheath	Alive at age 24
3	24F	3	Yes	No	Large multiple renal artery aneurysms	Attempted renal bypass	Alive at age 37
4	43M	3	No	No	Ascending aortic dissecting aneurysm Ruptured distal anastomotic aneurysm	Unplanned nephrectomy Ascending aortic graft Aortic-aortic graft (arterial rupture)	Died at age 49
5	47M	2	Yes	No	Large AAA (dissecting) Abdominal aortic and femoral aneurysms	Aortic-biliac graft Aortic-bifemoral graft	Alive at age 67
6	47M	4	Yes	Yes	Ruptured femoral artery Bilateral renal artery dissection with visceral ischemia; abdominal compartment syndrome	Interposition graft Abdominal decompression	Alive at age 52
7	41F	3	No	No	Ruptured splenic artery with pseudoaneurysm	Splenectomy	Died at age 44 (arterial rupture)
8	33F	3	Yes	No	Expanding AAA Ruptured splenic vein aneurysm Ruptured inferior epigastric artery	Aortic-aortic graft Coil embolization Coil embolization	Alive at age 55
9	48F	3	Yes	Yes	Spontaneous hemothorax	VAT	Died at age 53 (aortic rupture)
10	43F	3	No	No	Ruptured subclavian artery Large anastomotic aneurysm	Chest tube Primary ligation Interposition graft	Alive at age 69
11	40M	4	Yes	Yes	Ruptured ileocolic artery	Primary ligation	Alive at age 43
12	76M	4	No	No	Varicose veins	Avulsion of varicose veins	Died at age 84 (arterial rupture)
13	37M	2	Yes	No	Expanding femoral-popliteal pseudoaneurysm Large innominate-subclavian pseudoaneurysm Mitral valve regurgitation Ascending aortic dissection Femoropopliteal graft thrombosis Carotid artery rupture Large femoral anastomotic aneurysm Carotid-subclavian anastomotic rupture	Femoropopliteal graft Carotid-subclavian bypass Mitral valve replacement Ascending aortic graft Graft thrombectomy Simple repair Interposition graft Attempted control	Operative death
14	26F	3	No	No	Thoracic aortic pseudoaneurysm	Aortic-aortic graft	Alive at age 48
15	39M	4	Yes	No	Ascending aortic dissection	Ascending aortic graft with AVR	Operative death

M, Male; F, female; AAA, abdominal aortic aneurysm; VAT, video-assisted thoracoscopy; AVR, aortic valve replacement.

*Indicates the number of major clinical criteria, which includes easy bruising, thin and translucent skin, characteristic facial features and history of arterial, intestinal and/or uterine fragility.

[†]Vascular complications and operative procedures are in chronological order for each patient.

We agree with others that although clinical diagnosis is highly indicative of the disease, laboratory confirmation is more conclusive and may be advisable.^{1-2,6} Histology and electron microscopy often yield nondiagnostic results: arterial wall thinning, decreased collagen content, and distorted collagen fibril architecture.⁶ The most reliable study is a direct assessment of procollagen III deficiency by using a gel elec-

trophoresis technique. Although this method requires a skin biopsy specimen, it is more sensitive and has traditionally cost less than the alternative option of COL3A1 gene analysis.

In addition, one potential problem is that the nature of the COL3A1 gene mutation does not accurately predict the type, extent, and prognosis of EDS-IV.^{1,16} Because COL3A1 is a large gene and there are many different

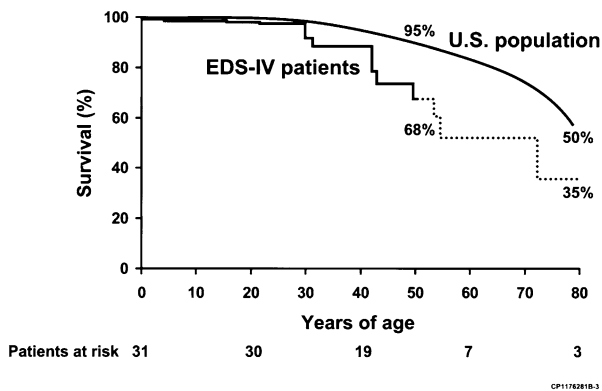


Fig 5. Comparison of Kaplan-Meier estimates of overall survival in 31 patients with a clinical diagnosis of Ehlers-Danlos syndrome type IV and in age- and sex-matched controls. The *dotted line* denotes >10% standard deviation.

mutations, mutations may be more prevalent than currently recognized and may correlate well with specific phenotypes. Some mutations may be so deleterious as to result in embryonic death, whereas others could account for minor degrees of skin fragility, digital hypermobility, and arterial or intestinal abnormalities.

Previous reports have suggested an autosomal recessive transmission, but current evidence supports only an autosomal dominant pattern.^{1,6} The implication of a dominant pattern of inheritance is straightforward: affected individuals have 50% chance of passing the mutated gene to each child. Therefore, genetic counseling is warranted so patients and their families can be informed regarding the severity and frequency of complications, its prognosis, and available reproductive options. Prenatal molecular diagnosis requires obstetric procedures, which may carry excessive risk in these patients. Families should be provided with a careful discussion on contraception, and reproductive and pregnancy risks, management of inadvertent pregnancies, and the options of adoption and artificial insemination with donor sperm in couples with an affected husband. Patients are also cautioned to avoid lifestyles with increased potential for trauma and to use a medical alert bracelet informing of the diagnosis.

The routine use of imaging studies is controversial. Some authors advise not pursuing any additional investigation or surveillance, because a conservative approach will be adopted irrespectively and undue anxiety would be created.⁷ Although there is no definitive evidence that knowledge of incidental lesions favorably affects survival, this study shows that the diagnostic yield of noninvasive studies is very high (76%) and that vascular lesions are often incidental findings (50%). In addition, six patients with incidental lesions treated conservatively had an adverse outcome, including two deaths from arterial rupture. Therefore, we continue to recommend echocardiography, carotid artery ultrasound scans, and noninvasive imaging of the abdominal aorta by ultrasound, computed tomography

(CT), or magnetic resonance angiography (MRA) during the initial evaluation. We prefer CT angiography of the chest and abdomen.

Arteriography has been associated with a high complication rate and was used mostly in the beginning of our experience.^{6-7,12} Arterial tears can occur in association with the access site or in remote locations, as exemplified by one of our patients, in whom a carotid artery tear developed during selective internal carotid artery catheterization.^{7,13} The risk-benefit ratio for any invasive diagnostic or therapeutic study should be carefully assessed. We currently advocate arteriography when arterial embolization is considered. In addition, these issues underscore the value of establishing the diagnosis as early as possible so procedures that carry high risk of complications can be avoided.

In this group of patients, vascular complications affected medium and large-sized arteries in many anatomic locations. Some series suggested that vascular lesions tend to affect arteries near the shoulder and hip joint, but we found that essentially all vascular territories could be affected, with most lesions located in the aorta and its proximal branches or within the visceral and renal arteries. Most complications were spontaneous, and only three patients reported a history of recent trauma.

The exact nature of vascular lesions has also been a matter of debate and confusion in the literature.¹⁷ We found that most vascular complications were either arterial dissections, often associated with aneurysmal degeneration, or arterial tears resulting in contained hematomas, false aneurysms, or intracavitary bleeding. It is possible that some dissections actually represented subintimal hematomas associated with intimal tears. We agree with other reports that most "aneurysms" described in the literature probably represent false aneurysms¹⁷; however, a small group of our patients (14%) did have true fusiform aneurysms.

Vascular complications shortened survival in patients with EDS-IV. Intestinal rupture was not associated with late deaths in this study. Our findings are in agreement with the landmark study by Pepin et al,⁸ who found that 92% of late deaths in a cohort of 220 index patients were from vascular complications.⁸ In addition, the median survival (48 vs 54 years of age) and overall patient survival at age 60 years (55% vs 68%) were similar in both studies. Finally, the Pepin et al study found decreased survival in affected family members compared with index patients (33% vs 55% at age 60 years, respectively), a finding that could not be confirmed in our study because of incomplete data.⁸

The traditional recommendation when dealing with vascular complications of EDS-IV has been a conservative approach, with operative treatment reserved for patients presenting with imminent or frank life-threatening bleeding.⁶⁻⁷ However, surgeons are occasionally faced with the dilemma of whether the elective repair of a large asymptomatic aneurysm is indicated. Decision making can be difficult because EDS-IV patients have a very heterogeneous spectrum of disease. Some patients have an aggressive form with excessive tissue fragility, whereas others respond as would a

typical vascular patient and tolerate aortic clamping and reconstruction without significant problems. Overall, we continue to exercise caution when indicating elective operations and advise a higher threshold for operating on non-ruptured dissecting aneurysms. Finally, one should be particularly cautious not to indicate avoidable elective operations (eg, avulsion of varicose vein) that carry excessive risk of complications, especially in patients with sporadic disease and mild phenotype.

To optimize clinical outcome, the surgeon should be aware of the diagnosis before an operation. Precautionary measures include gentle, atraumatic, and delicate handling of tissues. Normal handling of arteries is bound to induce more arterial tears. Retractors should be placed carefully to avoid damaging adjacent bowel or mesentery. Use of soft, protected arterial clamps, balloon occlusion, or an orthopedic tourniquet is preferable to standard arterial clamps. The surgeon should select the least complicated and most expeditious technique of repair. Arterial ligation is an excellent choice whenever possible without compromising blood supply (eg, subclavian artery). The use of umbilical tape over a PTFE sheath has been described as a useful technique to prevent sutures from cutting into the arterial wall.⁷

Simple arterial repairs are occasionally feasible. However, central arterial complications often require arterial reconstruction with prosthetic grafts. In these cases, use of autologous vein is contraindicated. The anastomosis should be tensionless and buttressed with Teflon felt strips or pledgets. However, despite the use of several of these techniques, a substantial number of our patients developed operative bleeding complications (37%) and late graft-anastomotic problems (40%).

Finally, there are currently no reports on the use of stent grafts to treat vascular complications of EDS-IV. Specific concerns include the introduction of large-bore devices and the potential risk of arterial rupture remote to the access site. In our opinion, endovascular treatment should be limited to coil embolization of ruptured arteries.

Although our findings are in agreement with previous reports, some potential limitations of our study merit discussion:

- In seven patients, the diagnosis was established solely from clinical criteria, without biochemical confirmation; it is possible that some of these cases represented EDS-like disorders with distinct yet unidentified biochemical mechanisms.
- Because the study was retrospective and spanned three decades, the exact circumstances involved in the decision making (eg, operation vs conservative approach, choice of repair) are difficult to determine.
- During this period diagnostic modalities, surgical experience, techniques, and perioperative care varied considerably.
- Despite being one of the largest surgical series, the numbers are too small to enable subgroup analysis.

- This series reflects a referral population to a tertiary care center and may be biased toward more severely affected EDS-IV patients and not fully representative of all EDS-IV patients in the general population.

There is currently no effective medical treatment that can predictably decrease the risk of vascular complications and increase life expectancy in patients with EDS-IV. However, the diagnosis should be considered in young patients with unexplained arterial rupture or dissections, particularly if there is a family history for vascular, intestinal, or uterine complications. Arteriography should be avoided whenever possible, but noninvasive imaging studies (echocardiogram, carotid and abdominal ultrasound scanning, CT or MRA) provide an excellent means of evaluating the presence and extent of complications. Operative treatment is indicated in patients with frank or imminent life-threatening bleeding. Although operative mortality was not excessively high in this study, the incidence of postoperative bleeding complications and late graft-related problems was significant. In addition, despite successful repair of vascular complications, survival was shortened because of secondary vascular or graft-related complications.

CONCLUSION

Ehlers-Danlos syndrome type IV, the vascular type, is a rare connective tissue disorder caused by type III procollagen deficiency due to *COL3A1* gene mutation. Clinical diagnosis is established from at least two of four major clinical criteria: thin, translucent skin; arterial, intestinal, or uterine fragility or rupture; extensive bruising; and characteristic facial appearance. Although the presence of two major clinical criteria is highly indicative of EDS-IV, laboratory testing for procollagen III deficiency is strongly recommended. Results of biochemical and gene mutation analysis may take months, and operative therapy should not be delayed if indicated. Initial imaging evaluation includes echocardiogram, carotid ultrasound, and noninvasive imaging of the chest and abdomen. Arteriography is indicated if coil embolization is considered.

Follow-up includes annual physical examination, carotid and abdominal ultrasound for asymptomatic patients, and noninvasive imaging of chest and abdomen if incidental findings are present. Patients treated conservatively for aneurysm need close follow-up (3 to 6 months) to assess expansion rate. Vascular complications typically include spontaneous arterial rupture, dissection, and dissecting aneurysms.

Patients with asymptomatic complications are managed conservatively. Patients with frank bleeding require emergent operative repair or catheter-directed embolization. The treatment of minimally symptomatic aneurysms is controversial, and data do not allow definitive recommendations. We generally treat these conservatively unless rapid aneurysm expansion or aneurysm size indicates an impending rupture.

We gratefully acknowledge the assistance of Jan Hofer, RN, with data collection, Rhonda Brincks with secretarial

assistance, and Carl G. Clingman with preparation of medical illustrations.

REFERENCES

1. Byers PH. Ehlers-Danlos syndrome. In: Rimoin DL, Connor JM, Pyeritz RE, editors. *Emery and Rimoin's principles and practice of medical genetics*. 3rd ed. Vol 1. New York: Churchill Livingstone, 1997;p. 1067-81.
2. Beighton P, De Paepe AD, Steinmann B, Tsipouras P, Wenstrup RJ. Ehlers-Danlos syndrome: revised nosology, Villefranche, 1997. *Am J Med Genet* 1998;77:31-7.
3. Barabas AP. Heterogeneity of the Ehlers-Danlos syndrome. Description of clinical types and a hypothesis to explain the basic defect. *BMJ* 1967;2:612-3.
4. Barabas AP. Vascular complications in the Ehlers-Danlos syndrome, with especial reference to the "arterial type" or Sack's syndrome. *J Cardiovasc Surg* 1972;13:160.
5. Pope FM, Martin GR, Lichtenstein JR, Penttinen R, Gerson B, Rowe DM, et al. Patients with Ehlers-Danlos syndrome type IV lack type III collagen. *Proc Natl Acad Sci U S A* 1975;72:1314-6.
6. Germain DP. Clinical and genetic features of vascular Ehlers-Danlos syndrome. *Ann Vasc Surg* 2002;16:391-7.
7. Bergqvist D. Ehlers-Danlos type IV syndrome: a review from a vascular surgical point of view. *Eur J Surg* 1996;162:163-70.
8. Pepin M, Schwarze U, Superti-Fuga A, Byers PH. Clinical and genetic features of Ehlers-Danlos syndrome type IV, the vascular type. *N Eng J Med* 2000;342:673-80.
9. Beighton P, Horan FT. Surgical aspects of the Ehlers-Danlos syndrome. A survey of 100 cases. *Br J Surg* 1960;56:255-9.
10. Burnett FH, Bledsoe JH, Char F, Williams D. Abdominal aortic aneurysmectomy in a 17-year-old patient with Ehlers-Danlos syndrome: case report and review of the literature. *Surgery* 1973;74:617-20.
11. Hunter GC, Malone JM, Moore WS, Misiorowski RL, Chvapil M. Vascular manifestations in patients with Ehlers-Danlos syndrome. *Arch Surg* 1982;117:495-8.
12. Cikrit DF, Miles JH, Silver D. Spontaneous arterial perforation: the Ehlers-Danlos specter. *J Vasc Surg* 1987;5:248-55.
13. Freeman KF, Swegle J, Sise MJ. The surgical complications of Ehlers-Danlos syndrome. *Am Surg* 1996;62:869-73.
14. Lauwers GL, Nevelsteen A, Daenen G, Lacroix H, Suy R, Frijns JP, et al. Ehlers-Danlos syndrome type IV: a heterogenous disease. *Ann Vasc Surg* 1997;11:178-82.
15. Karkos CD, Prasad V, Mukhopadhyay U, Thomson GJ, Hearn AR. Rupture of the abdominal aorta in patients with Ehlers-Danlos syndrome. *Ann Vasc Surg* 2000;14:274-7.
16. Pyeritz RE. Ehlers-Danlos syndrome (editorial). *N Eng J Med* 2000;342:730-2.
17. Barabas A. Ehlers-Danlos syndrome type IV. *N Eng J Med* 2000;343:366.

Submitted Feb 3, 2005; accepted Mar 22, 2005.