

Contents lists available at ScienceDirect

Asian Pacific Journal of Tropical Medicine

journal homepage: www.elsevier.com/locate/apjtm

Document heading doi:

Wound healing effect of flavonoid rich fraction and luteolin isolated from *Martynia annua* Linn. on streptozotocin induced diabetic rats

Santram Lodhi, Abhay K Singhai*

Department of Pharmaceutical Sciences, Dr. H. S. Gour University, Sagar (M.P.), India

ARTICLE INFO

Article history:

Received 10 October 2012

Received in revised form 15 November 2012

Accepted 15 December 2012

Available online 20 April 2013

Keywords:

Martynia annua

Wound healing

Flavonoids

Antioxidant

Povidone iodine ointment

Streptozotocin

ABSTRACT

Objective: To evaluate wound healing potential of flavonoid fractions of *Martynia annua* (*M. annua*) Linn. leaves in diabetic rats on the basis of folkloric information and preliminary study. **Methods:** The flavonoid compound luteolin and apigenin were isolated from dried leaves of plant by column chromatography. The two concentrations (0.2% and 0.5% w/w) of luteolin and flavonoid fraction were selected for topically applied as ointment on diabetic wound. The Povidone Iodine Ointment USP was used as a reference. On 18th days, protein content, hydroxyproline and antioxidants (SOD, CAT and GSH) level in granuloma tissues were determined. **Results:** The results showed that, percent wound contraction were observed significantly ($P < 0.01$) greater in MAF fraction and 0.5% w/w of luteolin treatment groups. Presence of matured collagen fibres and fibroblasts with better angiogenesis were observed in histopathological studies. **Conclusions:** In conclusion, our findings suggest that flavonoid fraction (MAF) and luteolin (0.5% w/w) may have potential benefit in enhancing wound healing in diabetic condition, possibly due to free-radical scavenging activity of plant.

1. Introduction

Wound healing, as a normal biological process in human body, is achieved through four precisely and highly programmed phases: hemostasis, inflammation, proliferation and remodeling. For successfully healing, all four phases must occur in the proper sequence that involves soluble mediators, blood cells, extracellular matrix, and parenchymal cells in a time frame[1]. Wounds that exhibit impaired healing, including delayed acute wounds and chronic wounds, generally have failed to progress through the normal stages of healing. Such wounds frequently enter a state of pathologic inflammation due to a postponed, incomplete, or uncoordinated healing process. Most chronic wounds are ulcers that are associated with ischemia, diabetes mellitus, venous stasis disease, or pressure[2].

The *Martynia annua* (*M. annua*) Linn. (Family Martyniaceae), a glandular hairy annual herb and commonly known as Bichchhu, used in epilepsy and applied locally to tuberculosis glands of camel's neck. The juice of leaves used as a gargle for sore throat, fruit in inflammation, leaf paste has beneficial effect when applied to wounds of domestic animal[3,4]. The root extract exhibited fungicide activity against *Alternaria alternata* (*A. alternata*) and *Aspergillus niger* (*A. niger*). Chemical examination of *M. annua* Linn. plant revealed the presence of glycosides, tannins, carbohydrates, phenols, flavonoids and anthocyanins. Flowers contain cyanidin-3-galactoside whilst p-hydroxy benzoic acid, snopic acid, and gentisic acid are present in leaves and fruits respectively[5]. The leaves contain chlorogenic acid and seeds-fatty acids. The anti-inflammatory activity of ethanol extract of *Martynia diandra* (*M. diandra*) Glox. was reported in both acute and sub-acute inflammatory process[6]. In previous study we had reported the ethanol extract of *M. annua* Linn. leaves have wound healing potential in incision and excision wound models in rats[7]. The present study was aimed to evaluate wound healing potential of flavonoid fractions of *M. annua*

*Corresponding author: Dr. Abhay K. Singhai (Professor), Department of Pharmaceutical Sciences, Dr. H. S. Gour University, Sagar (M.P.), India.

Tel: +91-7582264125

Fax: +91-07582-265457

E-mail: abhayksinghai@yahoo.co.in

Foundation project: This work is financially supported by Indian Council of Medical Research. (grant No. 45/12/2007/BMS/TRM; IRIS ID No. 2007-00690).

Linn. leaves in diabetic rats on the basis of preliminary study and folkloric information.

2. Material and method

2.1. Plant material

The leaves of *M. annua* Linn. were collected adjoining the campus of University, during month of September to October. The plant was identified (No. Bot/Her/267) in Department of Botany, Dr. H. S. Gour University Sagar, M. P. (INDIA). The plant material was dried in shade, powdered and sieved through 40-mesh size for further studies.

2.2. Extraction and isolation of flavonoids

The powdered plant materials *M. annua* Linn. leaves (2 kg) were defatted with petroleum ether (60–80 °C) and extracted with ethyl alcohol for 3–4 d. The dried ethyl alcohol extract was treated with chloroform repeatedly to obtain chloroform soluble fraction and chloroform insoluble fraction. The chloroform insoluble fraction was dissolved in methanol repeatedly to obtain methanol soluble fraction (5.7 g). The methanol soluble fraction (MAF) gives positive test for flavonoids.

The methanol soluble fraction was subjected to separate different constituents by column chromatography. The stationary phase Silica (Merck, 60–120 mesh) bed was prepared in chloroform as mobile phase in the glass column (35 cm × 1.5 cm), the bed (final geometry 28 cm × 1.5 cm) was allowed to settle. A 2.0 g dry fraction sample was applied to the column and elution was carried out with chloroform, chloroform–methanol using gradient elution (90:10, 80:20, 70:30, and 60:40). The 5 mL of each relevant fraction was collected and TLC of each fraction was done with, toluene: chloroform: acetone (40:25:35) as solvent system. The relevant fractions (No. 64–69) were combined and further purified by recrystallization from methanol to give compound–1 (26.0 mg). The relevant fractions (No. 80–86) were combined and purified by recrystallization from methanol to give compound–2 (20 mg). The compounds were further characterized by spectroscopic analysis and were identified by UV, infra red (IR), proton nuclear magnetic resonance (¹H–NMR) and mass spectroscopy (MS). UV spectra were recorded on double beam Shimadzu UV–1700 model (Japan). IR spectra were recorded on a spectrum 100 FT–IR spectrometer supplied by PerkinElmer (Cape Town, South Africa) using KBr pellets. The ¹H NMR data was recorded at a FT–NMR Cryo–magnet Spectrometer 400 MHz (Bruker) using CDCl₃ as solvent with tetramethylsilane (TMS) as internal standard. EI–MS spectrum was scanned at 70 eV on a JEOL

JMS600 instrument (Japan).

2.3. Preparation of formulations

The 5% w/w semisolid mass of *M. annua* fraction (MAF) was taken with simple ointment base B.P.[8]. The formulation of isolated compound–1 (luteolin) was prepared in two concentrations 0.2% and 0.5 % w/w by fusion method. Prepared formulations of luteolin and flavonoid fraction were referred as LUT and MAF ointment respectively which were subjected for dermal irritation study and wound healing activity in diabetic wound model. The marketed formulation, 5% w/w Povidone Iodine Ointment USP (Zenith Drugs Pvt. Ltd, India) was taken as a reference for comparison.

2.4. Experimental protocol

Wistar albino rats (150–200 g) of either sex were selected for experiment. They were housed individually in well-ventilated, temperature controlled (26±2) °C animal room for seven days of period prior experiment. The animals were given the standard commercial pellet rodent diet (Hindustan Lever Pvt Ltd, Bangalore, India) and water ad libitum. The procedures were reviewed and approved by the Institutional Animal Ethics Committee (Reg. No. 379/01/ab/CPCSEA). Six animals were taken in each group for study. The group I was referred as control group, given only simple ointment base while Group II, III and IV denoted as treatment groups were received topically MAF, LUT Ointment (0.2% w/w), LUT Ointment (0.5% w/w) ointment respectively. The Group V received 5% w/w Povidone Iodine Ointment USP (Zenith Drugs Pvt Ltd, India) and served as reference group. They were applied twice daily and healing property was assessed in terms of physical, biochemical parameters and histopathological study.

2.5. Diabetic wound creation

Wistar albino rats were made diabetic by being given a single injection of streptozotocin (STZ) prepared in Citrate buffer (0.1 M, pH 4.5) 50 mg/kg, i.p. after overnight fasting. Blood was taken from the orbital plexus, 24 h after the injection and glucose level was estimated using Glucometer. An excision wound was made on the rats showing elevated blood glucose (more than 250 mg/dL). Blood glucose level was estimated at the time of creation of the wounds and after treatment[9].

2.6. Dermal irritation study

A primary skin irritation test was conducted on rats to

determine the potential of the ointment to produce an irritation after a single topical application. Three healthy young adult albino rats of either sex were fed commercial pellets diet and water ad libitum. Animals were acclimated to laboratories conditions for a period of 7 d prior to initiation of dosing. Animal room was kept at a constant temperature (19–24 °C).

On the day before application, hairs of rats were removed from the dorsal and trunk area using a small animal clipper. On the day of dosing, but prior to application, the animals were examined for health and the skin checked for any abnormalities. No preexisting skin irritation was observed. Two to three grams of the ointment was applied to 6 cm² intact area on each animal and caged. After 4 h of exposure to extract ointment, the test sites were gently cleaned from any residual substance. Individual evaluation of test dose was scored according to Draize Scoring System at approximately 1, 24, 48 and 72 h after removal of extract ointment^[10]. The degree of irritancy was obtained by calculating the primary dermal irritation index (PDII).

$$\text{PDII} = \frac{(\text{PDI for 1, 24, 48 and 72 h})}{4}$$

Primary dermal irritation (PDI α) = Average erythema + Average edema

2.7. Percent wound contraction and epithelialization time

The wound contraction of individual animal from control and treatment groups were measured in each two days interval using transparent graph sheet and rate of healing expressed as percentage contraction:

$$\text{Percent wound contraction} = \frac{\text{Healed area}}{\text{Total area}} \times 100$$

2.8. Protein estimation

On the post wounding days 18th the protein content of skin tissues were determined in tissue lysate by treatment with a mixture of sodium tartrate, copper sulphate and sodium carbonate^[11]. The mixture was left to stand for 10 min and then treated with Folin–Ciocalteu reagent that resulted in a bluish color in 20–30 min. The absorbance was taken at 650 nm using Spectrophotometer.

2.9. Hydroxyproline measurement

Wound tissues were analyzed on 18th day for

hydroxyproline content, a basic constituent of collagen. Tissues were dried in a hot air oven at 60–70 °C to constant weight and hydrolysed in 6N HCl at 130 °C for 4 h in sealed tubes. The hydrolysate was neutralized to pH 7 then subjected to Chloramine–T oxidation for 20 min^[12]. The reaction was terminated by addition of 0.4M perchloric acid and developed color with Ehrlich reagent at 60 °C was read at 557 nm in UV (Shimadzu) Spectrophotometer.

2.10. Enzymatic and non–enzymatic antioxidant assay

In diabetic wound, the small part of granuloma tissue was taken for antioxidant assay. The granuloma tissues were homogenized in phosphate buffer (pH 7.0) and centrifuged under cold condition. The clear supernatant was taken to assay of antioxidants level. Catalase was estimated following the breakdown of hydrogen peroxide^[13]. Superoxide dismutase (SOD) was assayed^[14] based on the inhibition of epinephrine autoxidation by the enzyme. Reduced glutathione (GSH) level was determined in tissues homogenates by immediately precipitation with 0.1 mL of 25% TCA and the precipitate was removed after centrifugation^[15]. Free–SH groups were assayed in a total 3 mL volume by the addition of 2 mL of 0.6 mM DTNB and 0.9 mL 0.2 mM sodium phosphate buffer (pH 8.0) to 0.1 mL of the supernatant and the absorbance was read at 412 nm using UV spectrophotometer.

2.11. Histopathological study

Animals were anaesthetized before taking skin sample using diethyl ether. On 18th day wound tissue specimen from control, treatment and reference group were collected and store in 10% formalin after that usual processing 6 μ m thick sections were cut and stained with haematoxylin and eosin^[16]. The histopathologic criteria were used in each animal for: epithelial proliferation, granuloma tissue formation and organization, newly formed capillaries. Sections were qualitatively assessed under light microscope and were observed fibroblast proliferation, collagen maturation, angiogenesis and epithelialization.

2.12. Statistical analysis

Pharmacological data were represented as the mean \pm S.D. for six rats and data were evaluated using the Tukey test. Values of $P < 0.01$ were considered to be statistically significant.

3. Results

3.1. Separation of flavonoids

Compound-1: It was yellow amorphous powder, melting point 325–328 °C. It is soluble in ethyl acetate, acetone, methanol and slightly soluble in hot water. The UV spectrum showed maxima (MeOH, λ max) at 253, 268 and 348 nm, characteristic absorbance of polyphenolic compounds. The IR spectrum exhibited absorption bands [cm^{-1}]: 3420 (aromatic OH), 2822–2618 (C–H), 1655 (C=O), 1418 (aromatic C=C), 1265 and 1029 (C–O), 874, 741 and 708 (tri substituted benzene ring). The ^1H NMR spectrum exhibited a broad characteristic signal of aromatic hydroxyl groups at 9.43–10.84 (^3H , 3', 4' and 7–H), 12.41 (^1H , singlet, 5–H). The other protons signal at 7.40 (1H, double doublet, J = 9.2, 2.1 Hz, 6'–H), 7.39 (^1H , doublet, J = 2.2 Hz, 2'–H), 6.88 (^1H , doublet, J = 9.2 Hz, 5'–H), 6.60 (^1H , singlet at 3–H), 6.43 (^1H , doublet, J = 2.2 Hz, 8–H) and 6.19 (^1H , doublet, J = 6.2 Hz, 6–H) were found. The EI–MS spectrum was showed molecular ($\text{C}_{15}\text{H}_{10}\text{O}_6$) ion peak (m/z) at 286 (M+) and other fragments were found at 257, 137 and 120. By comparison of the spectral data with those of 2–(3, 4–Dihydroxyphenyl)–5,7–dihydroxy–4–chromenone, compound-1 was identified as luteolin.

Compound-2: It was yellow amorphous powder with melting point 335–338 °C and soluble in ethyl acetate, acetone, methanol and slightly soluble in hot water. The λ max was at 253, 265 and 335 nm, characteristic absorbance of polyphenolic compounds. The IR spectrum absorption bands at [cm^{-1}]: 3497–2922 (OH), 2618 (C–H), 1

654 (C=O), 1419 (aromatic rings), 1265 and 1028 (C–O), 877, 741 and 708 (para–substitution of benzene ring). The ^1H NMR spectrum exhibited a broad characteristic signal of aromatic hydroxyl groups at 9.41–10.82 (2H, 4' and 7–H), 13.09 (^1H , singlet, 5–H). The other protons signal at 7.93 (^2H , double doublet, J = 8.1, 2'–H and 6'–H), 6.79 (^1H , singlet, 3–H), 6.48 (^1H , doublet, J = 2.1, 8–H) and 6.19 (^1H , doublet, J = 2.1, 6–H) were found. The EI–MS spectrum was showed molecular ($\text{C}_{15}\text{H}_{10}\text{O}_5$) ion peak (m/z) at 270 (M+) and other fragments were found at 153 and 242. By comparison of the spectral data with those of 5, 7–dihydroxy–2–(4–methoxyphenyl) chromen–4–one, Compound-2 was identified as apigenin^[17].

3.2. Dermal irritation study

The dermal irrigation study showed at 1, 24, 48 and 72 h after the formulation application, very slight erythema was observed at 24 h in all formulations treatment group. The primary dermal irritation index for all formulations was found 0.25. No edema was observed in any treated group of rats. After 24 h, very slight erythema was observed in all treated groups of formulation.

3.3. Determination of percent wound contraction

Wound contraction on different days is shown in Table 1 (Figure 1). The treated group with 0.5 % w/w LUT ointment from 2 to 8 d, slightly increase in wound contraction was observed in comparison to control. From 10 to 18th days, in group treatment with 0.5 % w/w LUT ointment was observed significant ($P < 0.01$) difference in percentage of wound

Table 1

Effect of prepared formulations and reference ointment on percent wound contraction area of diabetic wound in rats.

Groups	Post wounding days (Percent wound contraction)										Epithelia–lization period
	2	4	6	8	10	12	14	16	18	20	
Control (Base)	7.53±0.14	12.76±0.59	21.58±1.08	29.10±0.92	35.84±1.12	46.29±1.47	54.08±2.01	65.94±3.17	72.17±2.98	80.14±2.76	23
MAF ointment	12.87±0.59 [*]	24.48±1.14 [*]	32.57±1.55 [*]	48.50±2.09 [*]	59.64±2.14 [*]	73.41±2.58	85.69±3.64 [*]	94.52±3.17 [*]	100.00±3.85 [*]	–	18
LUT ointment (0.2% w/w)	7.29±0.36 ^{ns}	14.43±0.26 ^{ns}	22.18±0.97 ^{ns}	33.46±1.27 ^{ns}	38.27±1.37 ^{ns}	49.24±1.64 ^{ns}	57.61±1.28 ^{ns}	68.40±1.29 ^{ns}	75.30±2.13 ^{ns}	81.24±3.10 ^{ns}	23
LUT ointment (0.5% w/w)	8.41±0.28 ^{ns}	16.27±0.77	29.49±1.42	35.10±1.71	46.19±1.08 [*]	58.20±1.52	67.27±2.10 [*]	76.52±3.20 [*]	87.61±3.17 [*]	93.19±3.41 [*]	21
Reference ointment	12.35±0.13	23.55±1.17	35.88±1.64	45.86±1.76	58.97±1.09 [*]	69.48±2.18	79.61±2.17 [*]	91.58±2.70 [*]	100.00±3.27 [*]	–	18

$n=6$ albino rats per group, value represents Mean±S.D. * $P < 0.01$, when each treated group was compared with control group; ^{ns} $P > 0.05$ (not significant).

Table 2

Effect of prepared formulations and reference ointment on different biochemical parameters of tissues from diabetic wound in rats.

Groups	Hydroxyproline (mg/g tissue)	Protein content (mg/g tissue)	SOD ($\mu\text{g}/50$ mg tissue)	CAT ($\mu\text{mol}/50$ mg tissue)	GSH ($\mu\text{mol}/50$ mg tissue)
Control (Base)	23.29±1.19	31.76±1.15	13.54±0.24	16.27±0.42	10.93±0.53
MAF ointment	51.67±2.17 [*]	61.28±2.67 [*]	27.61±1.27 [*]	29.52±1.37 [*]	21.67±1.06 [*]
LUT ointment (0.2% w/w)	20.84±0.34 ^{ns}	27.28±1.29 ^{ns}	15.43±0.63 ^{ns}	20.07±0.39 ^{ns}	14.34±0.64 ^{ns}
LUT ointment (0.5% w/w)	39.62±1.28 [*]	45.49±2.17 [*]	18.70±0.87 [*]	21.26±1.07 [*]	17.26±0.70 [*]
Reference ointment	50.43±1.64 [*]	60.45±1.97 [*]	25.15±1.26 [*]	28.64±1.69 [*]	23.53±1.02 [*]

$n=6$ albino rats per group, value represents Mean±S.D. * $P < 0.01$, when compared each treated group with control group; ^{ns} $P > 0.05$ (not significant).

contraction when compared to control group of animals. No significant difference was observed in group treated with 0.2% w/w LUT ointment group of animals. On day 18th, the treatment with MAF ointment was showed 100% contraction but other group treated with 0.2% w/w LUT, 0.5% w/w LUT ointment and control group were showed (75.30 ± 2.13), (87.61 ± 3.17) and (72.17 ± 2.98) respectively. On day 18th no scars were observed in animal treated with MAF fraction and reference ointment, which was an indication for complete healing.

3.4. Hydroxyproline measurement

The hydroxyproline content in wound tissue treated with different formulations and control group of animals are shown in Table 2. The hydroxyproline content in animals treated with MAF (51.67 ± 2.17), 0.5% w/w LUT (39.62 ± 1.28) and reference ointment (50.43 ± 1.64) was found significantly ($P < 0.01$) greater than control (23.29 ± 1.19) group of animals. The treatment group of 0.2% w/w LUT ointment was not significantly increase in hydroxyproline content as compared to control group.

3.5. Protein estimation

Over the 18th days treatment period, the protein content of wounds treatment groups with MAF (61.28 ± 2.67), 0.5% w/w LUT (45.49 ± 2.17) and reference ointment (60.45 ± 1.97) was found significantly ($P < 0.01$) increased. No significant increase was observed in treatment group of 0.2% w/w LUT and control group of animals (Table 2).

3.6. The enzymatic and non-enzymatic assay

The enzymatic and non-enzymatic assay during wound healing in skin tissues are given in Table 2. The activity of tissue antioxidant components were increased in control group as well as in 0.2% w/w LUT ointment treated animals in comparison to reference group and other treated groups. Due to increased activity of antioxidants, their content was lower during healing process. Slightly increase in SOD, CAT and GSH was found in treatment groups of 0.5% w/w LUT, MAF ointment and reference ointment on 18th days.

3.7. Histopathological study

Histopathological study was showed that well organized collagen fibers, increase in fibroblast cells and new blood vessels formation was observed (identified by the presence of erythrocytes in their lumen) in treated groups (MAF, LUT and reference ointment), other than control group. In the control

group as well as 0.2% w/w LUT ointment group of animals was found a more marked proliferation of angioblasts and fibroblast with infiltration of large number of lymphocytes, microphages and a few neutrophils on 18th days (Figure 2). In the group treated with MAF and reference ointment, formation of dense fibrous tissue and blood capillaries was observed on 18th days. The arrangement of capillaries was perpendicular to the fibrous tissue. Mature connective tissue and a few capillaries with a thick epidermal lining at the periphery of the wound were observed at 18th day. The group treated with 0.5% w/w LUT ointment was found these changes were less pronounced and moderate degrees of inflammation were observed.

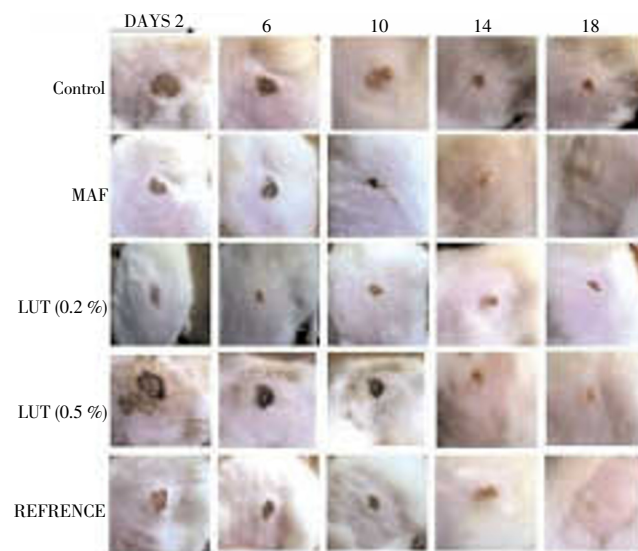


Figure 1. Wound area of different groups treated with different formulations in diabetic wound method in rat.

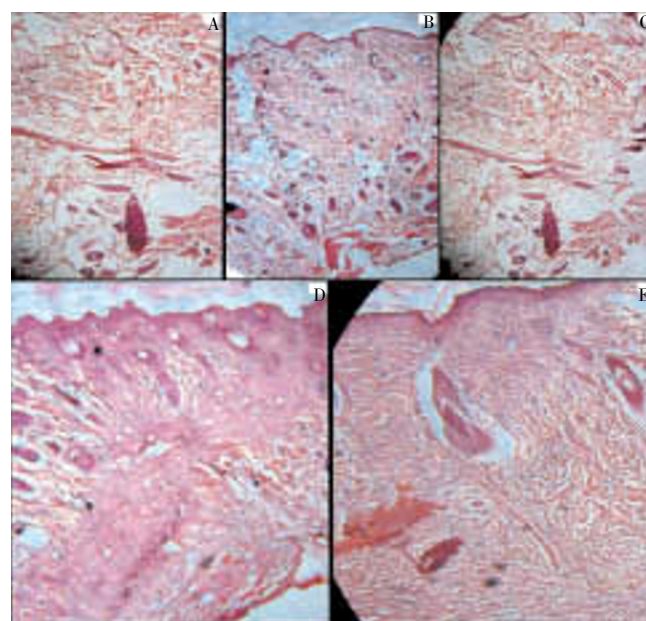


Figure 2. Photomicrograph of rat skin after post wounding with different formulation treatment in diabetic wound method. A: Control; B: MAF ointment; C: LUT ointment (0.2% w/w); D: LUT ointment (0.5% w/w); E: Reference ointment.

4. Discussion

Elevated blood glucose levels may cause endothelial damage with potential occlusion of capillary vessels as well as hyperglycemia-induced leukocyte dysfunction, decreased chemotaxis and phagocytosis resulting in impaired wound healing and increased risk of infection. Defective collagen metabolism in diabetics is also thought to be a factor in delayed wound healing. Hyperglycemia in animal studies is associated with increased collagenase and protease activity in rat gingiva and impaired vascular wound healing^[18].

The objective of present study was to evaluate healing property of flavonoid fraction of *M. annua* Linn. leaves and luteolin in diabetic rats. The phytochemical work concluded that ethanol extract of *M. annua* Linn. leaves contains flavonoids, which have been documented to have free radical scavenging effect and antibacterial activity^[19]. Luteolin exerts a variety of pharmacological activities including anti-oxidant properties associated with its capacity to scavenge oxygen and potent anti-inflammatory. Luteolin is a flavone widely distributed in the plant kingdom, showed a concentration-dependent inhibitory activity in several models of oxidative stress^[20–24]. The antioxidant potential of luteolin, is twice stronger than that of vitamin E and has strong scavenging properties for superoxide radicals. It is a potent physical quencher of singlet oxygen. Luteolin inhibits single strand break in DNA induced by singlet oxygen in a dose-dependent manner^[25,26].

Inflammation is a normal part of the wound healing process, and is important to the removal of contaminating microorganisms. In the absence of effective decontamination, however, inflammation may be prolonged as microbial clearance is incomplete. Both bacteria and endotoxins can lead to the prolonged elevation of pro-inflammatory cytokines (interleukin-1 and TNF- α) and elongate the inflammatory phase. If this continues, the wound may enter a chronic state and fail to heal. This prolonged inflammation also leads to an increased level of matrix metalloproteases (MMPs), a family of proteases that can degrade the ECM^[27,28]. Some swelling in a wound is inevitable and to a degree it is required for successful healing to occur, because if there is no inflammation then healing does not begin and if too little inflammation occurs then healing may be slow. However, if too much inflammation occurs, then the likelihood of excessive scar is produced. This inflammatory fluid, derived from the blood, is high in fibrinogen. Fibrinogen coagulates in the wound and in the surrounding tissues that are now fluid filled. The coagulated fibrin will later mature into a dense, binding scar. Excessive swelling, therefore, must not be permitted^[29]. Thus luteolin and other flavonoids containing fraction may shortened the inflammation period, and contributes a resistance against the infections.

Due to vascular disruption and high oxygen consumption by metabolically active cells, the microenvironment of the wound is quite hypoxic. Several systemic conditions,

including old age and diabetes, can create impaired vascular flow, thus produced poor tissue oxygenation. In the context of healing, this overlay of poor perfusion creates a hypoxic wound^[30]. The proper oxygen level is crucial for optimum wound healing. At initial stages, hypoxia is required to stimulate wound healing such as the release of growth factors and angiogenesis, while oxygen is needed to sustain the healing process^[31]. In summary, the impaired healing that occurs in diabetic rats involves hypoxia, dysfunction in fibroblasts and epidermal cells, impaired angiogenesis, neovascularization and high levels of metalloproteases. An increase in the level of antioxidants was observed in granuloma tissues of diabetic wound. These antioxidants are known to quench the superoxide radical and thus prevent the damage of cells caused by free radicals. There is plenty of evidence to suggest that increased production of reactive oxygen species, lipid peroxidation and ineffective scavenging play a crucial role in various skin lesions and in modulation of fibroblast proliferation^[32]. Cutaneous wounding causes a depression in the overall antioxidant status making it more vulnerable to oxygen radical attack^[33]. All these finding indicate that in wound healing, antioxidants may play an important role. Significant increase was also observed in hydroxyproline content which was a reflection of increased collagen levels that was further supported by histopathological evidence. This indicated improved collagen maturation by increased cross-linking. Flavonoids have been shown to increase collagen synthesis, promote the cross-linking of collagen, decrease the degradation of soluble collagen, accelerate the conversion of soluble collagen to insoluble collagen, and inhibit the catabolism of soluble collagen. From a clinical point of view, collagen deposition in the wound is the most important phase of healing. Facilitating oxygen diffusion, increasing lymphatic drainage, diminishing oxygen free radical overproduction and increasing the collagen synthesis were together found to improve healing^[34]. Collagen is a major protein of the extracellular matrix and is the component that ultimately contributes to wound strength. Breakdown of collagen liberates free hydroxyproline and its peptides. Measurement of this hydroxyproline therefore has been used as an index of collagen turnover. The increased hydroxyproline content of the excision wound has indicated faster collagen turnover leading to rapid wound healing. The differences in severity of vascular and cellular changes between the wounds treated with various medicaments might be due to different chemical constituents in medicaments.

In conclusion, the observation and results obtained in present study indicated that flavonoid fraction of *M. annua* Linn. (MAF) possesses a definite healing action. The fraction, MAF was containing flavonoid, luteolin have also found healing promoter in concentration of 0.5% w/w. This is demonstrated by a significant increase in rate of wound contraction and by enhanced epithelization. Thus the present study reveals that one of the mechanisms of the improved healing by these plants may be due to its capacity to enhance tissue

antioxidant levels. These findings could justify, at least partially, the inclusion of this plant in the management of wound healing in folk medicine. This study also confirms the promising wound healing activity of luteolin in diabetic animals and deserve for detailed experiments on cellular level and clinical studies in future.

Conflict of interest statement

The authors report no conflicts of interest. The authors alone are responsible for the content and writing of the paper.

Acknowledgements

The authors would like to acknowledge to Indian Council of Medical Research (File No. 45/12/2007/BMS/TRM; IRIS ID No. 2007–00690), New Delhi, for financial support for this research work and Punjab University, Chandigarh to support for spectroscopic study.

References

- [1] Guo S, Dipietro LA. Factors affecting wound healing. *J Dental Res* 2010; **89**(3): 219–229.
- [2] Biswas TK, Maity LN, Mukherjee B. Wound healing potential of *Pterocarpus santalinus* Linn: A pharmacological evaluation. *Int J Low Extrem Wounds* 2002; **3**(3): 143–150.
- [3] Khare CP. *Indian Medicinal Plants: An Illustrated Dictionary*. Heidelberg: Springer-Verlag; 2007, p. 399–400.
- [4] Kirtikar KR, Basu BD. *Indian Medicinal Plants*. Vol. 1, 2nd edition. Allahabad: Lalit Mohan Basu; 1956, p. 723.
- [5] Mali PC, Ansari AS, Chaturvedi M. Antifertility effect of chronically administered *Martynia annua* root extract on male rats. *J Ethnopharmacol* 2002; **82**(3): 61–67.
- [6] Chatpalliwar VA, Johrapurkar AA, Wanjari MM, Chakraborty RR, Kharkar VT. Antiinflammatory activity of *Martynia diandra* GLOX. *Ind Drugs* 2002; **39**(10): 543–545.
- [7] Lodhi S, Singhai AK. Preliminary pharmacological evaluation of *Martynia annua* Linn. leaves for wound healing. *Asian Pac J Trop Biomed* 2011; **1**: 421–427.
- [8] Anonymous. *British Pharmacopoeia*. General Medical Council, London: The Pharmaceutical Press; 1953.
- [9] Prasad SK, Kumar R, Patel DK, Hemalatha S. Wound healing activity of *Withania coagulans* in streptozotocin– induced diabetic rats. *Pharm Biol* 2010; **48**(12): 1397–1404.
- [10] Rogiers V, Pauwels M. Safety Assessment of cosmetics in europe. *Curr Prob Dermatol* 2008; **36**: 134.
- [11] Shanmugam S, Kumar TS, Selvam KP. *Laboratory Handbook on Biochemistry*. New Delhi: PHI Learning Pvt. Ltd; 2010, p. 20–23.
- [12] Woessner JF. The determination of hydroxyproline in tissue and protein samples containing small portion of this imino acid. *Arch Biochem Biophys* 1961; **193**: 440–447.
- [13] Li YD, HE Schellhorn. Rapid kinetic microassay for catalase activity. *J Biomol Tech* 2007; **18**(4): 185–187.
- [14] Surapaneni KM, Venkataramana G. Status of lipid peroxidation, glutathione, ascorbic acid, vitamin E and antioxidant enzymes in patients with osteoarthritis. *Ind J Med Sci* 2007; **61**(1): 9–14.
- [15] Tripathi R, Mohan H, Kamat JP. Modulation of oxidative damage by natural products. *Food Chem* 2005; **100**(1): 81–90.
- [16] Bancroft JD, Gamble M. *Theory and practice of histological techniques 6th edition*. Churchill Livingstone: Elsevier; 2008, p. 93–133.
- [17] Jung HA, Islam MDN, Kwon YS, Jin SE, Son YK, Park JJ, et al. Extraction and identification of three major aldose reductase inhibitors from *Artemisia montana*. *Food Chem Toxicol* 2011; **49**: 376–384.
- [18] Decker RT, Sirois DA, Mobley CC. Nutrition and oral medicine. In: Winkler MF, Makowski S. *Wound Healing*. Totowa: Humana Press; 2005, p. 273–283.
- [19] Sengar NPS, Pathak AK, Mehta PD, Shirole D, Singh A. Comparative antimicrobial studies of ethanolic extract of leaves of *Nerium indicum* and *Martynia annua*. *Bios Biotech Res Asia* 2006; **3**: 1.
- [20] Michalak A. Phenolic compounds and their antioxidant activity in plants growing under heavy metal stress. *Polish J Environ Stud* 2006; **15**(4): 523–530.
- [21] Ghasemi K, Ghasemi Y, Ebrahimzadeh MA. Antioxidant activity, phenol and flavonoid contents of 13 citrus species peels and tissues. *Pak J Pharm Sci* 2009; **22**(3): 277–281.
- [22] Narendhirakannan RT, Nirmala JG, Caroline A, Lincy S, Saj M, Durai D. Evaluation of antibacterial, antioxidant and wound healing properties of seven traditional medicinal plants from India in experimental animals. *Asian Pac J Trop Biomed* 2012; **2**(Suppl 3): S1245–S1253.
- [23] Roy SK, Mishra PK, Nandy S, Datta R, Chakraborty B. Potential wound healing activity of the different extract of *Typhonium trilobatum* in albino rats. *Asian Pac J Trop Biomed* 2012; **2**(Suppl 3): S1477–S1486.
- [24] Jha M, Sharma V, Ganesh N. Antioxidant and wound healing potential of *Pistia stratiotes* L. *Asian Pac J Trop Dis* 2012; **2**(Suppl2): S579–S584.
- [25] Kumpulainen JT; Salonen JT. *Natural Antioxidants and Food Quality in Atherosclerosis and Cancer Prevention*. Cambridge: Woodhead Publishing Limited; 1996, p. 56–259.
- [26] Del Bano MJ, Castillo J, Benavente-García O, Lorente J, Martín-Gil R, Acevedo C, et al. Radioprotective–antimutagenic effects of rosemary phenolics against chromosomal damage induced in human lymphocytes by gamma–rays. *J Agric Food Chem* 2006; **54**(6): 2064–2068.
- [27] Edwards R, Harding KG. Bacteria and wound healing. *Curr Opin Infect Dis* 2004; **17**: 91–96.
- [28] Menke NB, Ward KR, Witten TM, Bonchev DG, Diegelmann RF. Impaired wound healing. *Clinical Dermatol* 2007; **25**: 19–25.
- [29] Sochen JE. Orthopedic wounds. *Amer J Surg* 1994; **167**: 52S–54S.
- [30] Tandara AA, Mustoe TA. Oxygen in wound healing– More than a nutrient. *World J Surg* 2004; **28**: 294–300.
- [31] Bishop A. Role of oxygen in wound healing. *J Wound Care* 2008; **17**: 399–402.
- [32] Winyard PG, Blake DR, Evans CH. *Free Radicals and Inflammation*. Switzerland: Birkhauser; 2000, p. 195–203.
- [33] Schafer M, Werner S. Oxidative stress in normal and impaired wound repair. *Pharmacol Res* 2008; **58**(2): 165–171.
- [34] Inan A, Sen M, Koca C, Akpınar A, Dener C. The effect of purified micronized flavonoid fraction on the healing of anastomoses in the colon in rats. *Surg Today* 2006; **36**: 818–822.