

ORIGINAL ARTICLE

Surgical Treatment of Open Diaphyseal Fractures of Both the Radius and Ulna

Jung-Pan Wang, Fang-Yao Chiu*, Chuan-Mu Chen, Tain-Hsiung Chen

Department of Orthopaedics and Traumatology, Taipei Veterans General Hospital and National Yang-Ming University School of Medicine, Taipei, Taiwan, R.O.C.

Background: This study was designed to determine the effects of surgical treatment of acute, open and displaced diaphyseal fractures of both the radius and ulna by early debridement, reduction and internal fixation with a dynamic compression plate (DCP).

Methods: From 1991 to 2003, data from 25 patients with acute, open and displaced diaphyseal fractures of both the radius and ulna were collected and evaluated retrospectively. Twenty-four patients were managed with early surgical debridement, open reduction and internal fixation with a DCP, and 1 fracture was reduced and fixed 3 days after the initial injury. The mean follow-up period was 74.7 months (standard deviation [SD], 38.6 months; range, 16–150 months). All patients had complete functional and radiographic assessments.

Results: Twenty-four patients (96%) achieved normal union in a mean of 20.2 weeks (SD, 3.8 weeks; range, 12–24 weeks). One patient with an open type I fracture had nonunion. Functional outcomes showed that 15 patients had excellent results, 8 had satisfactory results, 1 had an unsatisfactory result, and there was 1 failure. There was 1 delayed superficial wound infection.

Conclusion: Early meticulous debridement, good open reduction and internal fixation with a small DCP proved very effective in the management of type I and II open fractures of both the radial and ulnar diaphyses. [*J Chin Med Assoc* 2005;68(8):379–382]

Key Words: dynamic compression plate, open fractures, radius, ulna

Introduction

Excellent results for plate fixation in displaced diaphyseal fractures of both the radius and ulna have been reported by many authors,^{1–20} but only a few authors have focused on plate fixation in the management of open diaphyseal fractures of both the radius and ulna.^{12,13,21,22} The purpose of this study was to evaluate the effects of immediate meticulous debridement, open reduction and internal fixation with a dynamic compression plate (DCP) in acute open diaphyseal fractures of both the radius and ulna.

Methods

Study population

Between 1991 and 2003, 33 consecutive cases of acute, displaced and open diaphyseal fractures of both the radius and ulna were treated with early meticulous debridement, open reduction and internal fixation with a small DCP. Eight patients were excluded from the study: 1 had preoperative compartment syndrome, 3 were lost to follow-up, and 4 had fractures with metaphyseal extension. The remaining 25 patients had complete records for evaluation. At the time of injury, the mean patient age was 41 years (standard deviation

*Correspondence to: Dr. Fang-Yao Chiu, Department of Orthopaedics and Traumatology, Taipei Veterans General Hospital, 201, Section 2, Shih-Pai Road, Taipei 112, Taiwan, R.O.C.
E-mail: fychiu@vghtpe.gov.tw • Received: September 30, 2004 • Accepted: February 15, 2005

[SD], 18.7 years; range, 19–81 years). There were 17 male and 8 female patients, with a total of 15 right-sided and 10 left-sided fractures. Based on the system of Gustilo and Anderson,⁹ open fractures were classified as type I ($n = 16$), type II (6), type IIIA (2), and type IIIB (1); no patient had a type IIIC fracture. The causes of injury were motor-vehicle accident ($n = 11$), simple fall (6), crushing injury (5), sports injury (1), and fall from a height (2). Seven patients had associated injuries, including 1 head injury, 1 chest injury, 1 tibial fracture, 1 radial artery laceration, and 3 preoperative neural injuries (2 posterior interosseous nerve palsies and 1 combined posterior interosseous nerve and ulnar nerve palsy), and were managed appropriately. The mean follow-up period was 74.7 months (SD, 38.6 months; range, 16–150 months).

Patient management

Twenty-four fractures were managed within 8 hours of injury, and 1 was managed 3 days after injury because of a poor initial condition resulting from head injury. The patient with delayed management had initial debridement and copious irrigation with 5 L sterile normal saline in the emergency room, followed by the same surgical management as the other 24 patients. Total management for the other 24 patients included irrigation with 5 L sterile normal saline, meticulous debridement, immediate open reduction, internal fixation with a small DCP, and systemic antibiotic therapy. All necrotic tissues were excised, and bone fragments with no soft-tissue attachments were discarded. Final culture specimens were obtained from the tissue after debridement. Rigid fixation of the fractures was accomplished according to the methods recommended by the AO (Arbeitsgemeinschaft für Osteosynthesefragen) Foundation.¹¹ The bones were exposed through separate incisions. The ulna was exposed subcutaneously between the flexor carpi ulnaris and the extensor carpi ulnaris muscles. The radius was exposed via the dorsal Thompson approach¹ or volar (Henry) approach.⁷

Two patients received autogenous cancellous bone grafts from the iliac crest because of a bone defect in 1 case (radius) and comminution involving more than 1-third of the cortex (ulna) in the other. All other patients had anatomic reduction of their fractures. After fixation, 1 patient with a type IIIB open fracture was treated by delayed split-thickness skin-grafting. Two patients with type I open fracture were treated by delayed primary closure because of operator doubt about the wound condition. All other patients, including the one with delayed surgical management, underwent primary wound closure with a suction

draining tube, which was removed 48–72 hours after the operation. Three patients had a postoperative cast for 4 weeks: 1 was poorly compliant and the other 2 had more comminuted fractures. The other 22 patients did not have any postoperative immobilization. Systemic antibiotics were administered for 2–5 days after the operation according to wound-healing status.

Postoperative follow-up

After the operation, each patient was followed up once every 2 weeks in the first month, and once every month thereafter. Additional visits were arranged if needed. Functional evaluation was done at every visit, and once every 2 months after fracture union. Each patient had a special chart with detailed records of personal data, cause and condition of the injury, type and classification of the fracture, management course (including timing of treatment, implant chosen, size or number of implants, status of fixation, operative course, degree of blood loss, operation time, type and duration of antibiotic therapy, length of hospital stay, early and late complications, and management of complications), course of fracture healing, and functional recovery.

Radiographic check-ups were done at each follow-up visit, with all evaluations and recordings performed by senior staff. Normal union was defined as the presence of periosteal or endosteal callus bridging the fracture site or trabeculation extending across it within 6 months.⁸ Fractures that healed in 6 months without an additional operative procedure were defined as delayed unions; those that failed to unite in 6 months, or that required an additional operative procedure for union, were defined as nonunion; and those that united with angulation or rotational deformity of more than 10° were defined as malunion.⁸

Functional evaluation was performed from the third follow-up visit, usually 1 month after discharge. Using the criteria of Anderson et al,⁸ the results were graded as excellent, satisfactory, unsatisfactory, or failure. An excellent result was defined as union of the fracture, loss of flexion and extension at the wrist or elbow of less than 10°, and loss of pronation and supination of less than 25%. A satisfactory result was defined as union of the fracture, loss of flexion and extension at the wrist or elbow of less than 20°, and loss of pronation and supination of less than 50%. An unsatisfactory result was defined as union of the fracture with either loss of flexion and extension at the wrist or elbow of more than 20°, or loss of pronation and supination of more than 50%. Finally, failure was defined as nonunion or unresolved chronic osteomyelitis. All values were expressed as mean \pm SD.

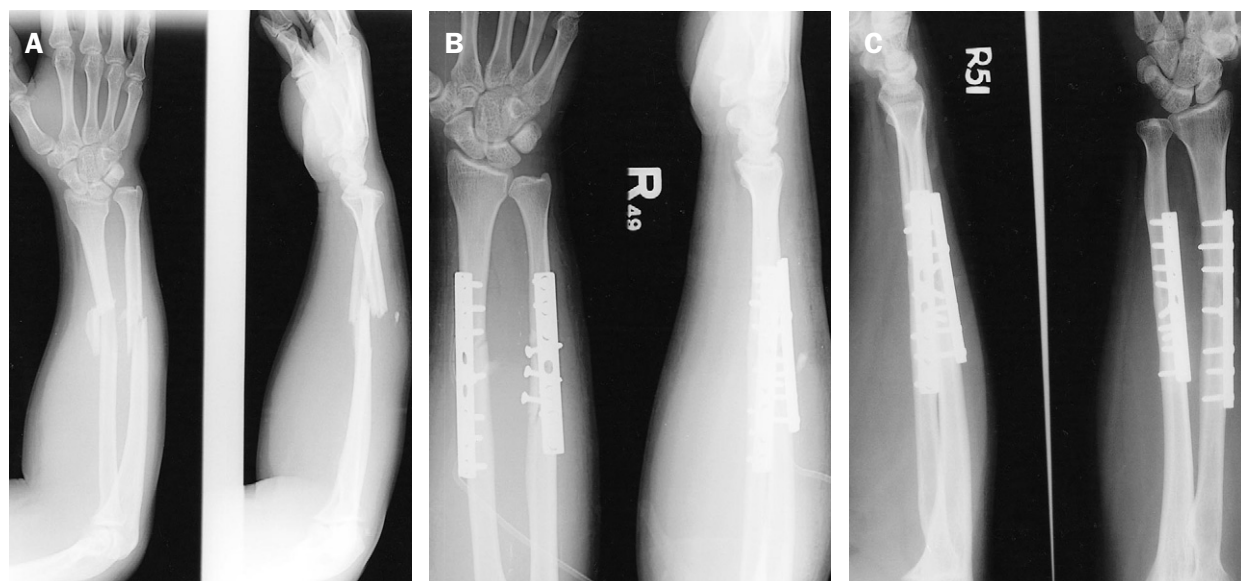


Figure 1. (A) Preoperative plain radiographs of the right forearm of a 25-year-old male with open type I fractures of the right radius and ulna, M/3, comminuted. (B) Immediate postoperative plain radiographs of the right forearm of the same patient showing 2 dynamic compression plates. (C) Plain radiographs 20 months postoperatively of the right forearm of the same patient shows solid union of the radius and ulnar fractures.

Results

Twenty-four patients (96%) achieved normal union in a mean of 20.2 weeks (SD, 3.8 weeks; range, 12–24 weeks) (Figure 1). One patient with an open type I fracture had nonunion of the ulna and was managed with autogenous bone grafting to make union 11 months later. The initial fracture of this nonunion had comminution involving less than 1-third of the circumferential cortex. Final outcomes revealed that 15 patients had excellent results, 8 had satisfactory results, 1 had an unsatisfactory result, and 1 had failure due to nonunion. The patient with an unsatisfactory result had an initial crushing injury with tendon and nerve involvement that led to subsequent loss of motion.

In this series, no fixation failure or cross union was noted. There was no deep infection and all intraoperative cultures showed negative results. There was 1 delayed superficial wound infection (in the patient with a type IIIA open fracture) that occurred 1 month after the initial operation, and that was cured after debridement and the use of systemic antibiotics. There was no iatrogenic neural injury. The 2 patients with posterior interosseous nerve palsy recovered spontaneously without treatment. The patient with combined interosseous and median nerve palsies failed to have median nerve recovery until the final follow-up visit. Five patients asked to have their plates removed

12 months after fracture union. No re-fracture was noted in this series.

Discussion

This study reports our experience in 25 patients with acute open fractures, involving both the radius and ulnar diaphyses, treated by early meticulous debridement, open reduction and rigid internal fixation with a small DCP, over a mean follow-up period of 6 years. Associated injuries were found in 7 patients (28%), which suggested a more severe state of injury. However, union rate and union time in our series were compatible with values in several other reports,^{4,6,8,11,13–22} including other series of closed fractures.^{4,6,8,11,13,14,18} This emphasizes the value of fixation with a DCP in achieving union of fractures of both the radius and ulna, even in open fractures.

Our study demonstrated a similar infection rate (4%) to that reported by other investigators,^{8,13,21} but without deep infection. Several studies have indicated that immediate plating of open fractures of the forearm does not increase the rate of infection, and has a complication rate compatible with that of closed fractures.^{10,12,17,20–22} Our results support this point, but we have to emphasize the importance of preventing infection, meticulous debridement, open reduction and rigid fixation to obtain good results. Meticulous

debridement is the key to preventing infection in the management of open fractures. Good early reduction and rigid fixation restore forearm stability earlier and limit dead space produced as a result of shortening and malposition,⁸ thus, such procedures permit earlier and more effective management of the soft-tissue injury, and subsequently improve wound care and avoid soft-tissue complications.

In our series, 92% (23/25) of patients had excellent or satisfactory results. These results were better than those in the series reported by Anderson et al⁸ (85%), in which plating was delayed in open fractures. Loss of motion is most likely to occur in patients with postoperative cast immobilization.¹³ Twenty-three of our patients (92%) had no postoperative immobilization. Thus, good early reduction and rigid internal fixation, which made postoperative immobilization unnecessary, and early range-of-motion rehabilitation, may have been important factors in obtaining good functional results. However, severity of the initial trauma was also important, as indicated in our 2 patients with unsatisfactory or failed functional results. In a series of 69 patients with open fractures in 1 or both bones of the forearm, type IIIB and IIIC open forearm fractures yielded poor results when managed by immediate open reduction and internal fixation.²¹

In conclusion, early meticulous debridement, good reduction and rigid internal fixation with a small DCP are very effective in the management of type I and II open fractures of both the radial and ulnar diaphyses. For Gustilo type IIIA or IIIB open fractures of both the radius and ulna, no conclusions can be made from this study, and more patients are required for further evaluation.

References

1. Thompson JE. Anatomical methods of approach in operations on the long bones of the extremities. *Ann Surg* 1918;68:309-29.
2. Knight RA, Purvis GD. Fractures of both bones of the forearm in adults. *J Bone Joint Surg Am* 1949;31:755-64.
3. Hicks JH. Fractures of the forearm treated by rigid fixation. *J Bone Joint Surg Br* 1961;43:680-7.
4. Burwell HN, Charnley AD. Treatment of forearm fractures in adults with particular reference to plate fixation. *J Bone Joint Surg Br* 1964;46:404-25.
5. Naiman PT, Schein AJ, Siffert RS. Use of ASIF compression plates in selected shaft fractures of the upper extremity. A preliminary report. *Clin Orthop* 1970;71:208-16.
6. Dodge HS, Cady GW. Treatment of fractures of the radius and ulna with compression plates: a retrospective study of one hundred and nineteen fractures in seventy-eight patients. *J Bone Joint Surg Am* 1972;54:1167-76.
7. Henry WA. *Extensile Exposure*, 2nd edition. New York: Churchill Livingstone, 1973:100-6.
8. Anderson LD, Sisk TD, Tooms RE, Parks WI III. Compression-plate fixation in acute diaphyseal fractures of the radius and ulna. *J Bone Joint Surg Am* 1975;57:287-97.
9. Gustilo RB, Anderson JT. Prevention of infection in the treatment of one thousand and twenty-five open fractures of long bones: retrospective and prospective analysis. *J Bone Joint Surg Am* 1976;58:453-8.
10. Chapman MW, Mahoney M. The role of early internal fixation in the management of open fracture. *Clin Orthop* 1979;138:120-31.
11. Muller ME, Allgower M, Schneider R, Willenegger H. *Manual of Internal Fixation*, 2nd edition. New York: Springer-Verlag, 1979.
12. Chapman MW. The use of immediate internal fixation in open fractures. *Orthop Clin North America* 1980;11:579-91.
13. Moed BR, Kellam JF, Foster RJ, Tile M, Hansen ST. Immediate internal fixation of open fractures of the diaphysis of the forearm. *J Bone Joint Surg Am* 1986;68:1008-17.
14. Hadden WA, Reschauer R, Seggl W. Results of AO plate fixation of forearm shaft fractures in adults. *Injury* 1983;15:44-52.
15. Stern PJ, Drury WJ. Complications of plate fixation of forearm fractures. *Clin Orthop* 1983;175:25-9.
16. Moore TM, Klein JP, Patzakis MJ, Harvery JP. Results of compression-plating of Galeazzi fractures. *J Bone Joint Surg Am* 1985;67:1015-21.
17. Grace TG, Eversmann WW Jr. Forearm fractures: treatment by rigid fixation with early motion. *J Bone Joint Surg Am* 1980;62:433-8.
18. Chapman MW, Gordon JE, Zissimos AG. Compression-plate fixation of acute fractures of the diaphyses of the radius and ulna. *J Bone Joint Surg Am* 1989;71:159-69.
19. Ross ER, Gourevitch D, Hastings GW, Wynn-Jones CE, Ali S. Retrospective analysis of plate fixation of diaphyseal fractures of the forearm bones. *Injury* 1989;20:211-4.
20. Schemitsch EH, Richards RR. The effect of malunion on functional outcome after plate fixation of fractures of both bones of the forearm in adults. *J Bone Joint Surg Am* 1992;74:1068-78.
21. Duncan R, Geissler W, Freeland AE, Savoie FH. Immediate internal fixation of open fracture of the diaphysis of the forearm. *J Orthop Trauma* 1992;6:25-31.
22. Reilly TJ. Isolated and combined fractures of the diaphysis of the radius and ulna. *Hand Clin* 2002;18:179-94.