


Contents lists available at [ScienceDirect](http://ScienceDirect.com)

# Interdisciplinary Neurosurgery: Advanced Techniques and Case Management

journal homepage: [www.inat-journal.com](http://www.inat-journal.com)

## Case Reports & Case Series (CRP)

### Partially thrombosed giant aneurysm arising from a distal anterior inferior cerebellar artery–posterior inferior cerebellar artery variant: A case report



Hidetoshi Ooigawa <sup>a,\*</sup>, Eiharu Morikawa <sup>a</sup>, Shoichiro Ishihara <sup>b</sup>, Takeshi Ogura <sup>a</sup>,  
Ririko Takeda <sup>a</sup>, Hiroki Kurita <sup>a</sup>

<sup>a</sup> Department of Cerebrovascular Surgery, International Medical Center, Saitama Medical University, 1397-1 Yamane, Hidaka City, Saitama 350-1298, Japan

<sup>b</sup> Department of Endovascular Neurosurgery, International Medical Center, Saitama Medical University, 1397-1 Yamane, Hidaka City, Saitama 350-1298, Japan

#### ARTICLE INFO

##### Article history:

Received 15 January 2015

Revised 4 April 2015

Accepted 26 April 2015

##### Keywords:

AICA–PICA

Giant aneurysm

Thrombosed aneurysm

#### ABSTRACT

Anterior inferior cerebellar artery (AICA)–posterior inferior cerebellar artery (PICA) is a well-known variant in cerebral arteries. However, aneurysms located on the variant are rare and a giant one has not been reported. We report a case of a partially thrombosed giant aneurysm arising from an AICA–PICA variant. The patient was a 42-year-old man who presented with right hearing loss and facial numbness associated with left hemidysesthesia. Magnetic resonance imaging revealed an approximately 3.0-cm mass lesion at the right cerebello-pontine angle (CPA). Angiography showed a partially thrombosed aneurysm arising from the right AICA–PICA. The aneurysm was treated with endovascular trapping and surgical thrombectomy. Although cerebral aneurysm is known to occur at this site, this case provides awareness, that manifestations of aneurysms in the CPA include progressive multiple cranial nerve palsies and sensory disturbance caused by brainstem compression.

© 2015 The Authors. Published by Elsevier B.V. This is an open access article under the CC BY-NC-ND license (<http://creativecommons.org/licenses/by-nc-nd/4.0/>).

#### Introduction

The anterior inferior cerebellar artery (AICA)–posterior inferior cerebellar artery (PICA) variant is well-known. However, intracranial aneurysms arising from this variant are extremely rare. We describe herein a case of a giant thrombosed aneurysm in an AICA–PICA variant, presenting with an infratentorial mass lesion, and causing progressive, multiple cranial nerve palsies and sensory disturbance, due to brainstem compression.

#### Case report

A 42-year-old man with a clinical history of hypertension and polycystic kidney disease presented to our hospital with the primary symptoms of progressive, right facial sensory disturbance, and hemidysesthesia in the left extremities. He had experienced right hearing loss for a few years. Extraocular movement was bilaterally smooth, and diplopia was not observed. Facial movement was symmetrical, and a definite facial nerve palsy was not detected. His

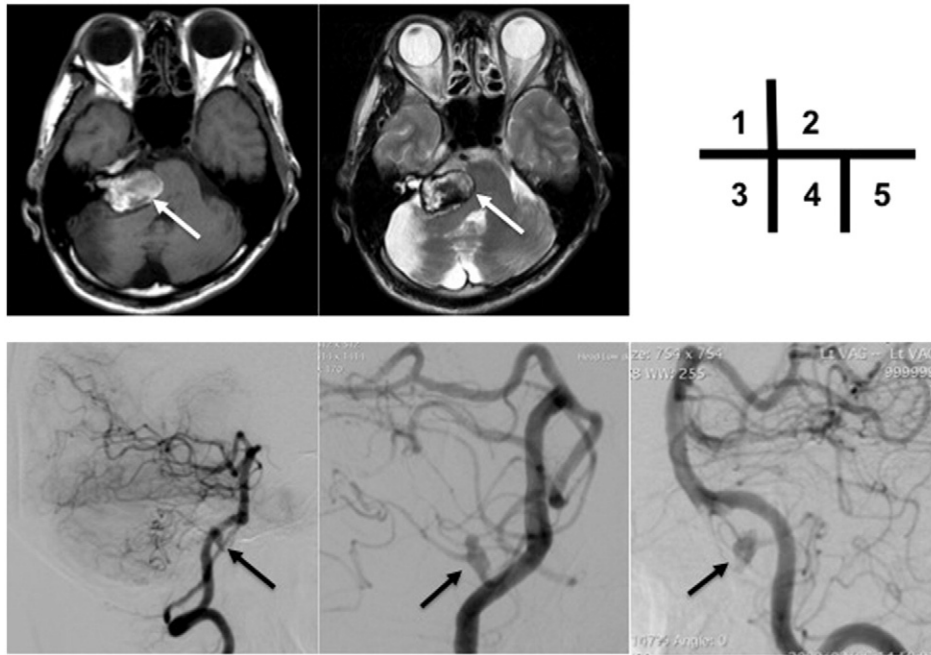
auditory brainstem response testing showed a flat wave for the right ear, and blink reflex testing showed no R1 and R2 waves bilaterally, with right-side stimulation. Magnetic resonance imaging (MRI) revealed an approximate 3.0 cm mass lesion at the right cerebello-pontine angle (CPA), compressing the brainstem and mimicking a vestibular schwannoma (Fig. 1.1 and 2). An ipsilateral cerebellar infarction was also evident. Magnetic resonance angiographic findings suggested that the space-occupying lesion represented a giant thrombosed aneurysm. Digital subtraction angiography demonstrated that the aneurysm was partially thrombosed, and located in the distal segment of an AICA–PICA variant (Fig. 1.3, 4, and 5).

In order to obtain radical cure, both mass reduction and neck occlusion of the aneurysm were necessary. Endovascular trapping, endovascular coiling, and proximal occlusion of the AICA–PICA, with or without bypass, and using a hybrid operating room, were treatment options considered. Of these procedures, endovascular trapping was the most simple, and seemed likely to succeed without a new neurological deficit. This was because the patient had already sustained a cerebellar infarction of a distal part of the AICA–PICA territory, and the aneurysm was sitting on the lateral wall of the pons, where the perforators to the brain stems were rare. We utilized both a platinum coil and *N*-butyl cyanoacrylate for the endovascular trapping, identical to our usual use of liquid materials for an intracranial artery in AVM embolization. Accordingly, we evaluated both the lidocaine provocation test and the balloon occlusion test.

\* Corresponding author at: Department of Cerebrovascular Surgery, International Medical Center, Saitama Medical University, 1397-1 Yamane, Hidaka City, Saitama 350-1298, Japan. Tel.: +81 42 984 4111.

E-mail address: [ooigawa@saitama-med.ac.jp](mailto:ooigawa@saitama-med.ac.jp) (H. Ooigawa).

<sup>1</sup> Department of Neurosurgery, Saitama Cardiovascular Respiratory Center, 1696 Itai, Kumagaya City, Saitama 360-0150, Japan. Tel.: +81 48 536 0990.



**Fig. 1.** 1, 2) MRI demonstrating the mass lesion at the right CPA (white arrow, 1: T1-weighted image; 2: T2-weighted image). Note the infarction of the inferolateral area of the cerebellum on the right side. 3, 4) Digital subtraction angiogram showing the partially thrombosed aneurysm in the distal portion of the right AICA–PICA (black arrow, 3: lateral projection of the right vertebral angiography; 4: right oblique view of the right vertebral angiography; 5: lateral projection of the left vertebral angiography).

Because these studies did not induce neurological deterioration, simple endovascular trapping to the wide orifice of the aneurysm was done without vascular reconstruction, such as a bypass procedure, between the occipital artery and AICA–PICA. The patient was then moved into surgical position in a hybrid operating room, and surgical thrombectomy was performed, using a lateral suboccipital approach. The aneurysm wall was incised, and the thrombus was completely removed. On postoperative examination, impaired eye movement, mild right-sided facial nerve palsy, and a swallowing disturbance were apparent, but gradually improved. MRI revealed marked reduction of the mass effect on the brainstem. The patient is now well, five years after surgery, and a recent MRI revealed no aneurysm recurrence (Fig. 2.1 and 2).

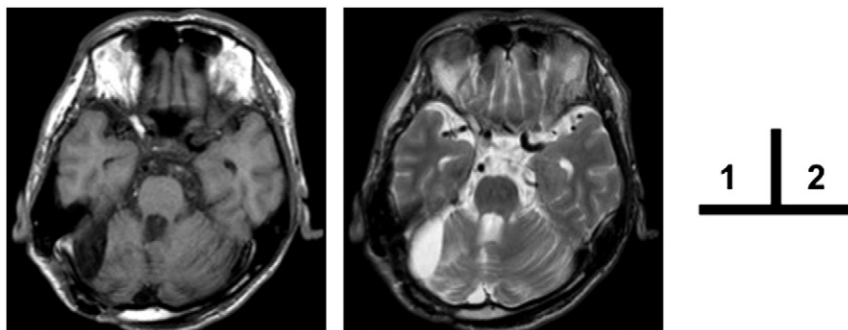
## Discussion

This report documents a case of a partially thrombosed giant AICA–PICA aneurysm that presented with progressive neurological symptoms, due to compression of the cranial nerves and brainstem. The first manifestation was hearing loss. Most infratentorial mass lesions presenting with hearing impairment involve brain tumors, such as a vestibular schwannoma. This case highlights hearing difficulty as a manifestation of an intracranial thrombosed aneurysm at the CPA [1].

A giant thrombosed intracranial aneurysm should be considered in the differential diagnoses of CPA lesions.

The AICA–PICA variant in the posterior circulation is well known. To date, four variants have been reported [2]. The first is a single, proximal basilar-origin trunk, with two peripheral branches that act as an AICA and PICA. The second is a bifid, intradural vertebral origin of the PICA. The third is a bifid, vertebrobasilar origin of the PICA. The fourth is a PICA without an AICA. Depending on its origin, the AICA–PICA covers different territories.

Only seven cases of aneurysm arising from the distal AICA–PICA have been reported in the literature [3–8]. All the reported cases involved rupture that caused subarachnoid or intraventricular hemorrhage. Six saccular aneurysms were treated, with surgical neck clipping in five cases, and endovascular coiling in one; the dissecting aneurysm was treated with trapping of the parent vessel. Interestingly, most of the aneurysms arose from a non-branching site of the artery, including the caudal loop, tonsillomedullary segment, telovelotonsillar segment, and anterior pontine segment. These parent arteries were of the first variant, including the present case. In this variant, the proximal trunk requires greater blood flow, which perfuses a wider cerebellar area than the usual PICA or AICA, and is thus strongly affected by hemodynamic stress. This characteristic may have been involved in the development of the aneurysm in the present case.



**Fig. 2.** MRI obtained five years postoperatively, demonstrating no aneurysm recurrence (1: T1-weighted image; 2: T2-weighted image).

## Conclusion

Aneurysms arising from the AICA–PICA variant are extremely rare. However, giant thrombosed AICA–PICA aneurysms may manifest with symptoms similar to those of a vestibular schwannoma. This intracranial aneurysm should be considered in the differential diagnosis of CPA lesions.

## References

- [1] Pasler D, Baldauf J, Runge U, Schroeder HW. Intrameatal thrombosed anterior inferior cerebellar artery aneurysm mimicking a vestibular schwannoma. *J Neurosurg* 2011;114(4):1057–60.
- [2] Lasjaunias P, Berenstein A, ter Brugge KG. 3.2 Arterial supply to the posterior fossa central nervous system. *Surgical neuroangiography* 1. 2nd ed. New York: Springer; 2001. p. 224–59.
- [3] Baskaya MK, Coscarella E, Jea A, Morcos JJ. Aneurysm of the anterior inferior cerebellar artery–posterior inferior cerebellar artery variant: case report with anatomical description in the cadaver. *Neurosurgery* 2006;58(2):E388.
- [4] Gopalakrishnan CV, Menon G, Nair S. Aneurysm of the anterior inferior cerebellar artery–posterior inferior cerebellar artery variant: two case reports and review of literature. *Br J Neurosurg* 2009;23(5):554–6.
- [5] Kojima A, Nakamura T, Takayama S, Harada S, Takamiya Y. A case of de novo aneurysm of the distal posterior inferior cerebellar artery with intraventricular hemorrhage [in Japanese]. *No Shinkei Geka* 1996;24(5):469–73.
- [6] Suh SH, Kim DJ, Kim DI, Kim BM, Chung TS, Hong CK, et al. Management of anterior inferior cerebellar artery aneurysms: endovascular treatment and clinical outcome. *AJNR Am J Neuroradiol* 2011;32(1):159–64.
- [7] Ebara M, Tanaka T, Sawauchi S, Morooka S, Yuhki K, Abe T. A ruptured aneurysm of the anterior and posterior inferior cerebellar artery: a case report [in Japanese]. *No Shinkei Geka* 1999;27(11):1013–7.
- [8] Gi H, Inoha S, Uno J, Ikai Y, Koga H, Yamaguchi S, et al. Four cases of direct surgery for anterior inferior cerebellar artery aneurysms [in Japanese]. *No Shinkei Geka* 2007;35(6):571–8.