

## Case Report

## Volcano like pattern in optical coherence tomography in chronic diabetic macular edema



Sivakami A. Pai, MS, DNB, PhD<sup>a,\*</sup>; Nazimul Hussain, MS, DNB, FACS<sup>b</sup>; Sudhira P. Hebri, DOMS, DNB, FRCS<sup>c</sup>; Afra M. Lootah, MS, FRCS<sup>a</sup>; Moza A. Dekhain, FRCS, MRCS<sup>a</sup>

## Abstract

In this article we herein report an interesting vitreo-macular interface abnormality associated with chronic diabetic cystoid macular edema. It is an observational case study of three diabetic patients examined in the diabetic clinic. All the patients had proliferative diabetic retinopathy with chronic macular edema. A serial cross sectional OCT examination and tracking of both the longitudinal progression of macular thickening and vitreo-macular interface revealed cystoid macular edema with a characteristic hyperreflective vitreous shadow emerging from the vitreofoveal interface. All the patients had dehiscence of inner retinal layers. This particular morphological feature at the vitreo-foveolar interface, which we name as "volcano sign", has not been described earlier. The probable mechanism of such a finding probably could be due to slow progressive leakage of chronic cytoid fluid into the vitreous with condensation of the overlying vitreous. Vitreo-macular traction followed by posterior vitreous detachment probably would have contributed to such a morphological event.

**Keywords:** Diabetic cystoid macular edema, Optical coherence tomography, Posterior vitreous detachment, Retinal morphology, Vitreo-macular interface

© 2014 Production and hosting by Elsevier B.V. on behalf of Saudi Ophthalmological Society, King Saud University.  
<http://dx.doi.org/10.1016/j.sjopt.2014.03.007>

## Introduction

The pathogenesis of diabetic maculopathy is still not fully understood. Three major mechanisms that are involved in barrier breakdown are increased paracellular permeability of the vascular endothelium due to disruption of cell tight junctions, loss of endothelial cell layer integrity due to cell destruction and increased transcellular transport through the endothelium.<sup>1</sup> Cumulative endothelial cell death becomes more relevant after prolonged diabetic conditions.<sup>2</sup> With the advent of High definition OCT, we have a better understanding of vitreo-macular and RPE-Choriocapillary interface relationship. Various types of macular edema and

vitreo-macular surface abnormalities have been described earlier in association with diabetic macular edema.<sup>3,4</sup> We herein, report an interesting morphologic phenomenon seen on HD OCT associated with chronic diabetic macular edema.

## Design and method

Observational, retrospective case study of three patients seen in the diabetic clinic. All the patients underwent complete eye examination and HD-OCT. Two patients were female and one male. Ages were 48, 54 and 60 years. Two patients were non-insulin dependent and one an insulin dependent diabetic. One patient was hypertensive,

Received 19 January 2014; received in revised form 13 March 2014; accepted 15 March 2014; available online 24 March 2014.

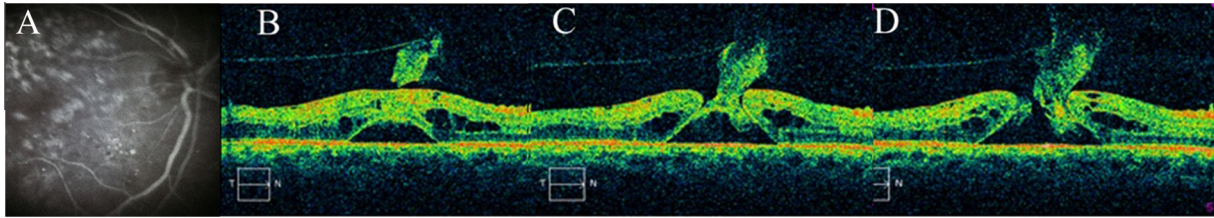
<sup>a</sup> Department of Ophthalmology, Dubai Health Authority, Dubai, United Arab Emirates

<sup>b</sup> Department of Ophthalmology, Al Zahra Hospital, Sharjah, United Arab Emirates

<sup>c</sup> New Medical Centre, Dubai, United Arab Emirates

\* Corresponding author.

e-mail address: [sudhirshiv@yahoo.com](mailto:sudhirshiv@yahoo.com) (S.A. Pai).



**Figure 1.** Fundus Fluorescein Angiography (FA) picture and serial optical coherence tomography (OCT) images of right eye of a 46 year old insulin dependent diabetic female. (A) FA picture shows (Extreme Left) shows staining due to macular laser marks and late leakage. (B) OCT images showed subfoveal outer retinal cysts with surrounding perifoveal cytooid retinal changes and hyperreflective shadows at the vitreofoveal interface with posterior vitreous detachment. (C) OCT image showing dehiscence of the outer retinal cyst wall with hyperreflective vitreous shadows seen continuously along the cyst wall. (D) OCT image showing a macular hole with the bed of the hole formed by the subfoveal dehiscent cyst.

controlled with medications. Best corrected visual acuity (BCVA) at presentation ranged from 1/60 to 6/60. All the patients had proliferative diabetic retinopathy and chronic macular edema, and had undergone multiple sessions of pan retinal and macular laser photocoagulation earlier. Last session was done 2–6 months earlier elsewhere. Two of these patients had also undergone an intravitreal injection of triamcinolone acetonide a year earlier. Two patients had posterior vitreous detachment (PVD) and one patient had incomplete PVD. Intraocular pressure ranged from 18–22 mmHg. Anterior chamber was quiet. All were phakic. Two patients had nuclear sclerosis grade 1 and 2. There were no signs of iris neovascularization and no relative afferent pupillary defect. None of the patients had nephropathy or a past history of cerebrovascular accidents. All patients were on regular medications and systemically controlled diabetic status. These three patients were documented to have an interesting morphologic vitreomacular interface abnormality seen on OCT. OCT was performed (Cirrus TM HD OCT, Carl Zeiss Meditec, Dublin, CA) and the examination was focused on the retinal architecture and the vitreomacular relationship. The serial optical coherence tomographic examinations of macular thickening and vitreo-macular interface abnormality were captured and documented.

### Case 1

A 46-year-old lady, an Insulin dependent diabetic for the last 16 years had a BCVA of 1/60 in the right eye. Fundus examination showed regressed fibro vascular membranes on the optic disc with pseudomacular hole and scatter laser marks. Fundus Fluorescein (Fig. 1, Extreme Left) showed staining due to macular laser marks and late leakage. OCT cross sectional images showed subfoveal outer retinal cysts

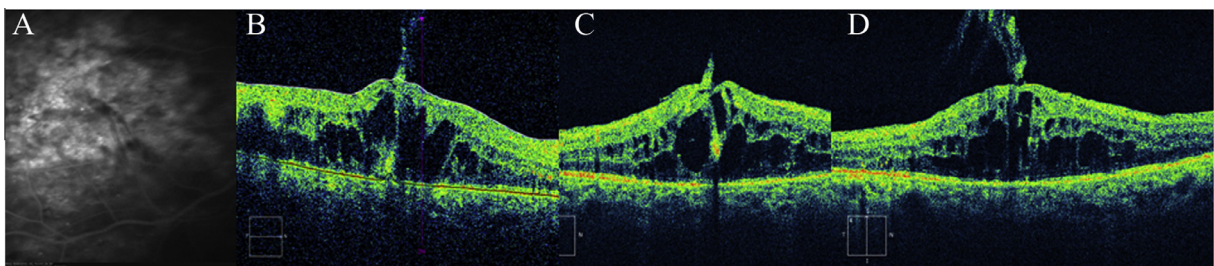
with surrounding perifoveal cytooid retinal changes. A gross hyperreflective shadow was seen in the vitreofoveal interface with incomplete posterior vitreous detachment (Fig. 1B). The other crosssectional OCT image showed dehiscence of the outer retinal cyst wall with hyperreflective vitreous shadows seen continuously along one of the cyst walls (Fig. 1C). Partial inner foveal dehiscence was seen with overlying condensed tissue partially attached to the edge (Fig. 1D).

### Case 2

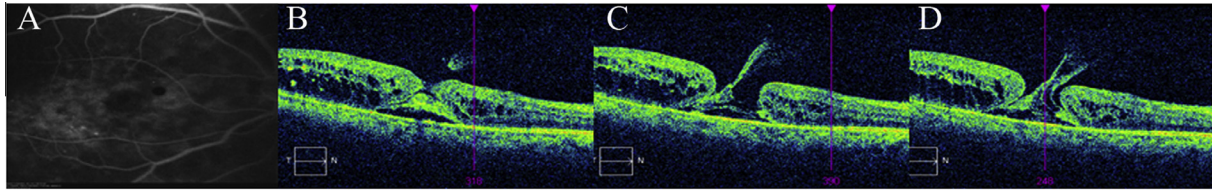
A 58-year-old non-insulin dependent diabetic female had undergone previous laser photocoagulation and intravitreal triamcinolone (IVTA) in the right eye 12 months ago. Her presenting visual acuity was 6/60 in the right eye. Late phase FA (Fluorescein angiography) showed a diffuse macular leak with petalloid appearance (Fig. 2A). Longitudinal and vertical-crosssectional OCT images showed gross evidence of intraretinal cystoid changes. Characteristic hyperreflective vitreous shadow was seen emerging from the vitreofoveal interface with no obvious dehiscence of inner retinal layers on OCT. (Fig. 2, B–D).

### Case 3

A 60-year-old male, a non-insulin dependent diabetic presented with a visual acuity of 2/60. He had undergone laser photocoagulation and IVTA in the right eye earlier. Late phase FA showed a diffuse macular leak with a well defined inner edge circle in the fovea (Fig. 3A). There was a faint zone of fluorescence seen surrounding the fovea. Cross-sectional OCT images showed a spongy type of macular edema. Multiple cross-sectional OCT images showed the characteristic dehiscence of the inner retinal layers with a break in the outer



**Figure 2.** Fluorescein angiography (FA) frame and serial OCT images of the right eye, of a 58 year old non-insulin dependent diabetic female. (A) Late FA frame shows a diffuse macular leak with a petalloid appearance. (B–D) OCT images show intraretinal cystoid changes. Characteristic hyperreflective vitreous shadow seen emerging from the vitreofoveal interface with no obvious dehiscence in the inner retinal layers.



**Figure 3.** FA frame and serial OCT images of the right eye of a 58 year old non-insulin dependent diabetic female. (A) Late phase FA showed a diffuse macular leak with a well defined inner edge circle in the fovea. (B–D) Cross-sectional OCT images showed a spongy type of macular edema. Dehiscence of the inner retinal layers with a break in the outer retinal cyst is seen with hyper-reflective vitreous shadow seen arising from the cyst.

retinal cyst and hyper-reflective vitreous shadow is seen arising from the cyst (Fig. 3B-D).

## Discussion

High resolution OCT has brought revolution in the diagnosis and management of vitreo-retinal disorders, especially in macular disorders, enhancing surgical and medical management.<sup>4,5</sup> Based on the retinal morphology on OCT, the diabetic macular edema has been classified into several types namely the cystoid type, spongy type, mixed type, foveal serous retinal detachment, associated with taut posterior hyloid, with vitreo-macular traction etc. But the characteristic morphologic phenomenon seen on OCT in the present case series has not been described earlier in the literature (Medline search). Such a phenomenon occurring in the case of chronic macular edema is not well understood. The probable hypothesis of this morphological phenomenon may be leakage of long duration intraretinal cystoid fluid into the vitreous cavity during the occurrence of posterior vitreous detachment (Partial or complete) which may be seen occurring in cases of chronic cystoid macular edema with vitreo-macular traction. In the present case study, OCT images showed gross evidence of intraretinal cystoid changes. Characteristic hyperreflective vitreous shadow was seen emerging from the vitreofoveal interface, which we named as "Volcano sign". It may be possible that leakage of the cellular exudates under a tensed cystic cavity may have spilled out condensing with the overlying vitreous leading to such a morphologic phenomenon. Cellular cystic fluid contents must have also caused an inflammatory vitreous reaction and condensation of the prefoveal vitreous cortex contributing to hyperreflective vitreous changes. Such a phenomenon may have been

triggered by the vitreofoveolar traction which is common in the posterior vitreous abnormalities in chronic diabetics. Besides, it may also be likely that condensations are dense prefoveal remnants of the posterior vitreous cortex which have been partially detached as seen in cases 2 and 3. This phenomenon is differentiated from vitreomacular traction by the absence of actual traction on the fovea. One may also speculate that in such morphologic phenomenon, possible surgical intervention may prevent the dehiscence of the inner retinal layer in the fovea and possibly accentuate the resolution of the macular edema.

To conclude, this small case series has shown an interesting morphologic phenomenon as seen in OCT in patients with chronic diabetic macular edema

## Conflict of interest

The authors declared that there is no conflict of interest.

## References

1. Krohne TU, Fauser S, Kirchhof B, Joussem AM. Pathogenesis of diabetic macular oedema. *Klin Monbl Augenheilkd* 2003;**220**:521–5.
2. Joussem AM, Smyth N, Niessen C. Pathophysiology of diabetic macular edema. *Dev Ophthalmol* 2007;**39**:1–12.
3. Panozzo G, Parolini B, Gusson E, Mercanti A, Pinackatt S, Bertoldo G, et al. Diabetic macular edema: an OCT-based classification. *Semin Ophthalmol* 2004;**19**:13–20.
4. Kim NR, Kim YJ, Chin HS, Moon YS. Optical macular oedema: prediction of visual outcome after focal laser photocoagulation. *Br J Ophthalmol* 2009;**93**:901–5.
5. Massin P, Duguid G, Erginay A, Haouchine B, Gaudric A. Optical coherence tomography for evaluating diabetic macular edema before and after vitrectomy. *Am J Ophthalmol* 2003;**135**:169–77.