

# A Novel Two-Dimensional Echocardiographic Image Analysis System Using Artificial Intelligence-Learned Pattern Recognition for Rapid Automated Ejection Fraction

Maxime Cannesson, MD,\* Masaki Tanabe, MD,\* Matthew S. Suffoletto, MD,\*  
Dennis M. McNamara, MD, FACC,\* Shobhit Madan, MD,† Joan M. Lacomis, MD,†  
John Gorcsan III, MD, FACC\*  
*Pittsburgh, Pennsylvania*

<b>Objectives</b>	We sought to test the hypothesis that a novel 2-dimensional echocardiographic image analysis system using artificial intelligence-learned pattern recognition can rapidly and reproducibly calculate ejection fraction (EF).
<b>Background</b>	Echocardiographic EF by manual tracing is time consuming, and visual assessment is inherently subjective.
<b>Methods</b>	We studied 218 patients (72 female), including 165 with abnormal left ventricular (LV) function. Auto EF incorporated a database trained on >10,000 human EF tracings to automatically locate and track the LV endocardium from routine grayscale digital cine-loops and calculate EF in 15 s. Auto EF results were independently compared with manually traced biplane Simpson's rule, visual EF, and magnetic resonance imaging (MRI) in a subset.
<b>Results</b>	Auto EF was possible in 200 (92%) of consecutive patients, of which 77% were completely automated and 23% required manual editing. Auto EF correlated well with manual EF ( $r = 0.98$ ; 6% limits of agreement) and required less time per patient ( $48 \pm 26$ s vs. $102 \pm 21$ s; $p < 0.01$ ). Auto EF correlated well with visual EF by expert readers ( $r = 0.96$ ; $p < 0.001$ ), but interobserver variability was greater ( $3.4 \pm 2.9\%$ vs. $9.8 \pm 5.7\%$ , respectively; $p < 0.001$ ). Visual EF was less accurate by novice readers ( $r = 0.82$ ; 19% limits of agreement) and improved with trainee-operated Auto EF ( $r = 0.96$ ; 7% limits of agreement). Auto EF also correlated with MRI EF ( $n = 21$ ) ( $r = 0.95$ ; 12% limits of agreement), but underestimated absolute volumes ( $r = 0.95$ ; bias of $-36 \pm 27$ ml overall).
<b>Conclusions</b>	Auto EF can automatically calculate EF similarly to results by manual biplane Simpson's rule and MRI, with less variability than visual EF, and has clinical potential. (J Am Coll Cardiol 2007;49:217-26) © 2007 by the American College of Cardiology Foundation

Two-dimensional (2D) echocardiography is widely used clinically to assess left ventricular (LV) ejection fraction (EF) (1-5). Because EF has become an important criterion for pharmacologic, defibrillator, and resynchronization therapy, an accurate and reproducible EF has become increasingly important (1,6-10). Recent advances in 3-dimensional echocardiography have improved the accuracy of LV volumes and EF (11-13); however, 2D imaging currently remains most widely used in mainstream clinical practice (14). Because previous automated

EF approaches were affected by gain-dependence and endocardial dropout (15-20), quantitative EF usually requires manual endocardial tracing of end-diastolic and end-systolic frames, which requires experience and may be time consuming. Consequently, visual estimation of EF is most popular in clinical practice, even though it is inherently subjective (21-25). A new approach applied to routine 2D images, known as Auto EF, has been developed using artificial intelligence-learned pattern recognition programming trained on several thousand human endocardial tracings to mimic steps such as bridging gaps in endocardial dropout and excluding papillary muscles. The objectives of this study were to test the hypotheses that Auto EF can: 1) rapidly and reproducibly calculate EF similar to results by manually traced biplane Simpson's rule; 2) perform with less variability than visual EF by expert readers; 3) perform more accurately than visual

From the \*Cardiovascular Institute and †Department of Radiology, University of Pittsburgh, Pittsburgh, Pennsylvania. Dr. Gorcsan was supported in part by National Institutes of Health award K24 HL04503-01. Dr. Cannesson was a recipient of a grant from the Médaille d'Or des Hospices Civils de Lyon Program at the Claude Bernard University of Lyon, France.

Manuscript received April 10, 2006; revised manuscript received August 17, 2006, accepted August 21, 2006.

**Abbreviations  
and Acronyms****2D** = 2-dimensional**EF** = ejection fraction**LV** = left ventricle/  
ventricular**MRI** = magnetic resonance  
imaging

EF by novice trainee readers; and 4) correlate favorably with EF by magnetic resonance imaging (MRI).

**Methods**

The study group of 218 patients referred for routine transthoracic echocardiography consisted of 165 consecutive patients with LV dysfunction (aged  $65 \pm 14$  years, 50 women) and 53 consecutive patients with preserved LV function (aged  $51 \pm 20$  years, 22 women). The protocol was approved by the Institutional Review Board for Biomedical Research of the University of Pittsburgh, and patients gave informed consent consistent with this protocol. Routine echocardiography (Acuson Sequoia; Siemens, Mountain View, California) was performed using harmonic imaging and routine gain settings with a standard clinical protocol including parasternal, apical, and subcostal views. Contrast for LV opacification (Definity; Bristol-Myers Squibb Imaging, North Billerica, Massachusetts) was used in 10% of studies with suboptimal endocardial definition. Digitally captured cine-loops were exported in DICOM format to a digital workstation (KinetDx; Siemens) and also to a separate off-line personal computer for Auto EF analysis (Siemens). Data were analyzed in 3 separate ways (visual EF, manual EF, and Auto EF) by readers blinded to the results from the alternative approaches.

First, EF was determined by visual assessment by 1 of 6 expert readers using all recorded views, including the subset with contrast injections. The EFs were reported in a range of 5% EF units, from 5–10% to 65–70%, which is the clinical routine for our laboratory and was the EF that appeared on the patient's clinical report. To test the hypothesis that Auto EF may aid less experienced readers, 2 cardiology fellows, who just completed their first month of echocardiography training and were blinded to the other EF results, interpreted 60 randomly selected cases. The novice readers recorded visual assessments of EF in 5% ranges, similar to the expert readers, and then subsequently reanalyzed the same cases with Auto EF, operating the program for their first time.

Second, all digital cine-loops from apical 4- and 2-chamber views were analyzed by a group of experienced investigators blinded to the other EF results using routine manual endocardial border tracing from end-diastolic and -systolic frames with computer application of Simpson's rule for biplane EF (26). Time necessary from the beginning of the tracing to the determination of the biplane EF was recorded.

Third, the same digital apical 4- and 2-chamber view cine-loops used for manual tracing were analyzed by the Auto EF program (Auto EF Version 0.9, Siemens) on a separate personal computer by an independent operator blinded to the visual and manual EF results.

**Auto EF.** Auto EF is unique from previous echocardiographic image analysis approaches, because it applies the

concept of learned pattern recognition from artificial intelligence theory, which generically seeks to mimic human behavior and learn from past experiences (27,28).

**STEP 1: CREATING A DATABASE.** An extensive database was previously created from expert manual LV tracing of >10,000 apical 4- and 2-chamber view images, including patients with cardiomyopathies, wall motion abnormalities, and dyssynchrony (29). Each cine-loop was manually contoured frame by frame to train the system and create a database of learned LV shapes and patterns.

**STEP 2: IDENTIFYING THE LV CAVITY.** The program would begin by searching the first frame of the entire digital DICOM grayscale image for a pattern consistent with an LV cavity. This input image was automatically compared with the database of learned LV patterns for shared common characteristics. Unlike previous border detection attempts that used pixel video intensity or backscatter, matching was done by shape and pattern recognition of pixel location. The LV shape typically consisted of an inverted "U" with the ends anchored in the echo-bright mitral annulus and could be identified by the system at different depths and orientations.

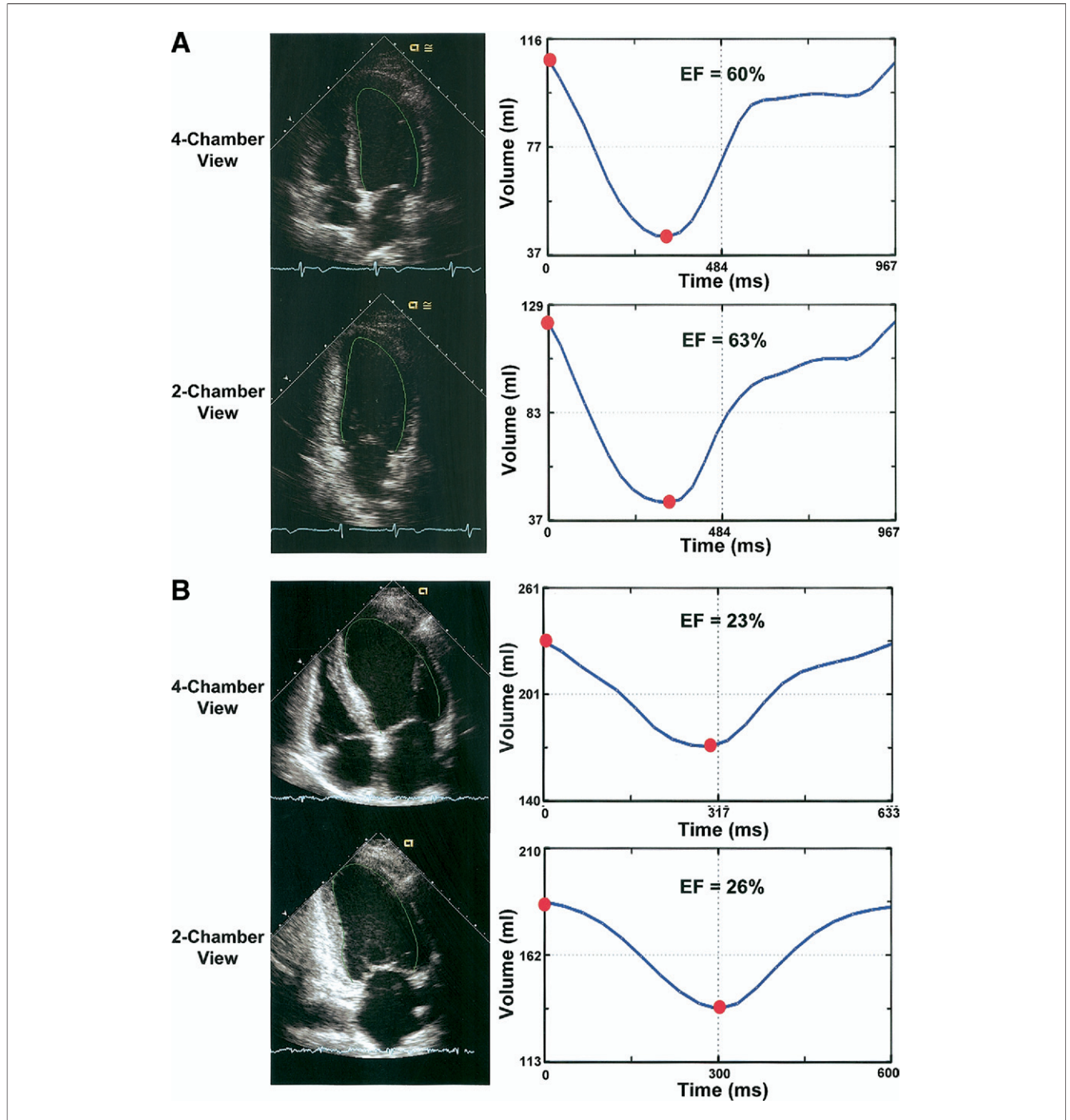
**STEP 3: TRACING THE ENDOCARDIAL BORDER.** A unique LV shape model and endocardial contour for the current case being analyzed was then created using the database of normal and abnormal LV shapes as a guide. Segments from the current case were compared to the database to find 1 or more cases that were similar (27). For example, there were cases in the database where the border was manually drawn to exclude the papillary muscle. If the presently analyzed case had a prominent papillary muscle, the system would search the database for cases with similarly appearing prominent papillary muscles and automatically cut the papillary muscle.

**STEP 4: TRACKING THE LV BORDER THROUGHOUT THE CARDIAC CYCLE.** The location of a point of the LV contour was tracked from frame to frame by matching the patterns from the database combined with learned models of motion (27). This process, called information fusion, used multiple candidate contours that were tracked in parallel, and the one that matched the current frame best was chosen (28). This allowed for motion detection even in frames with endocardial dropout. For example, if the lateral wall would dropout in mid-systole, the manual user could "imagine" its motion by interpolating traces between frames where the lateral wall was seen, and this system would mimic the clinical expert. In addition, a previously learned a priori shape model constrained the possible location of the endocardium within the uncertainty detected by the system.

**STEP 5: CALCULATING LV VOLUMES.** The EF was calculated from LV volumes using a modified Simpson's rule method of disks (26) with LV length determined as the maximal distance from the mid-mitral annulus to the LV apex. A time-volume

curve was generated with EF determined as (maximum – minimum)/maximum volume × 100%. The Auto EF endocardial contour appeared as a moving green line on the cine loop in autoplay mode, giving the operator instant visual feedback of endocardial tracking (Fig. 1, Videos 1 and 2 [see Appendix]).

Manual editing of endocardial tracking was possible using a click-and-drag feature of the contour. This was performed only when the automated endocardial tracing was judged to be <80% of the endocardial border using visual feedback (17). The entire Auto EF process took <15 s per view. The



**Figure 1** Auto EF Automated Time-Volume Curves

Examples of left ventricular (LV) endocardial tracings by Auto ejection fraction (EF) of the apical 4-chamber and 2-chamber views (left) and corresponding volume curves and EF (right). (A) A patient with normal ventricular function. (B) A heart failure patient with LV dysfunction.

[▶ Please see the Appendix for accompanying videos.](#)

**Table 1** Clinical Characteristics of Study Patient Groups

	Abnormal Ejection Fraction Patients (n = 150)	Normal Ejection Fraction Patients (n = 50)
Age (yrs)	65 ± 14	51 ± 20
Gender	45 women, 105 men	22 women, 28 men
Indication for echocardiography	Ischemic heart disease, 97 (65%) Idiopathic cardiomyopathy, 30 (20%) Valvular heart disease, 16 (11%) Chemotherapy cardiomyopathy, 3 (2%) Alcoholic cardiomyopathy, 2 (1%) Cocaine cardiomyopathy, 1 (0.7%) Viral cardiomyopathy, 1 (0.7%)	Hypertension, 8 (16%) Syncope, 8 (16%) Chest pain, 8 (16%) Normal volunteer, 5 (10%) Stroke, 5 (10%) Murmur, 5 (10%) Dyspnea, 5 (10%) Palpitations, 4 (8%) Brugada's syndrome, 1 (2%) Marfan's syndrome, 1 (2%)

investigator recorded the frequency and additional time required for any manual editing. The EF results from 4- and 2-chamber views were averaged for biplane EF.

**Magnetic resonance imaging.** Twenty-one consecutive patients were included who also underwent cardiac MRI with a 1.5-T scanner (Echospeed Excite 11.0, GE, Milwaukee, Wisconsin) within 24 h of echocardiography for comparison. Briefly, steady-state free-precession 2-chamber, 4-chamber, and short-axis cine views were acquired during end-expiration with 8-mm slice thickness and frame rates of 14 to 24 Hz. Off-line calculation of end-diastolic and end-systolic LV volumes and EF were derived from manual endocardial tracing of the short-axis stack from the mitral annulus to the LV apex using the methods of disks (Medical Imaging Systems, Leiden, the Netherlands) (30). Papillary muscles and trabeculations were included as blood volume in the cavity trace.

**Statistical analysis.** Group data (mean ± SD) were compared using paired 2-tailed Student *t* test within groups and unpaired 2-tailed Student *t* test between groups. Comparisons were assessed using least square linear regression analysis with 95% confidence intervals determined by a Fisher *r*-to-*z* transformation and agreement determined by Bland-Altman analysis (31). Intraobserver and interobserver variability for EF by all 3 echocardiography methods were analyzed in 20 randomly selected studies and expressed as absolute difference ± SD. A *p* value of <0.05 was considered to be significant.

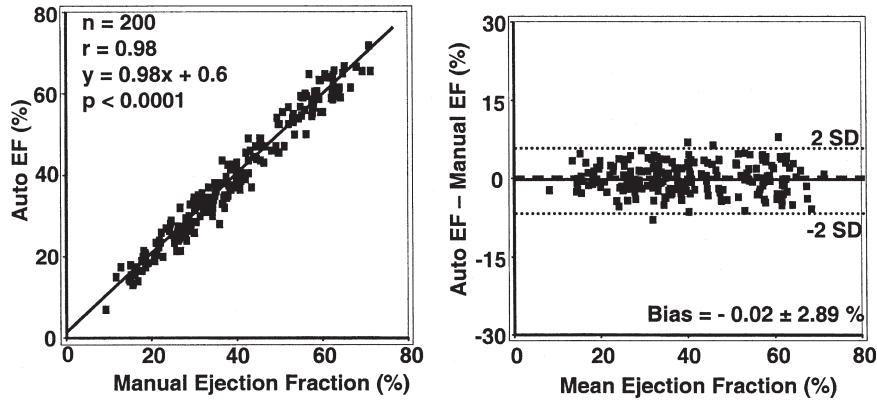
## Results

Of 218 consecutive echocardiographic studies analyzed, 18 (8%) with the poorest routine noncontrast image quality prohibiting manual endocardial tracing were prospectively excluded. Although visual EF was possible with contrast on these studies, they were excluded because the version of Auto EF was incapable of analyzing contrast images. No other echocardiographic or clinical exclusion criteria were used. Accordingly, the study group consisted of 200 patients (Table 1). A wide range of abnormalities were included,

such as regional wall motion abnormalities, apical aneurysms, paced rhythm or left bundle branch block, prosthetic valve replacement, pericardial effusion, and apical thrombus. Auto EF appeared unaffected by these scenarios. Auto EF correctly tracked >80% of the endocardium for acceptable determination of EF in 77% of attempted cases in approximately 15 s. Manual editing of the endocardial tracing was required in 23% of cine-loops. This usually consisted of expanding the endocardial tracing near the apex and required <30 s per view in cases where editing was necessary.

**Comparison with manual biplane Simpson's rule.** End-diastolic volumes ranged from 41 to 421 ml, end-systolic volumes ranged from 15 to 357 ml, and EF ranged from 9% to 71%. Overall, biplane EF by Auto EF and manual methods were closely related: *r* = 0.98; *p* < 0.01 (Fig. 2). The relationship was also favorable for single-plane EF in apical 4- and 2-chamber views (*r* = 0.95 and *r* = 0.92, respectively; *p* < 0.01). Absolute volumes by Auto EF also correlated with those by manual tracings (biplane LV end-diastolic volume: *r* = 0.94; *p* < 0.01; biplane LV end-systolic volume: *r* = 0.96; *p* < 0.01) (Fig. 3). Bland-Altman analysis revealed a bias of -15 ± 24 ml for LV end-diastolic volume and -10 ± 18 ml for LV end-systolic volume, suggesting an underestimation of LV volumes by Auto EF compared with manual tracing. The bias and agreement for biplane EF was favorable, however (mean = -0.02 ± 2.89%), suggesting that this underestimation of absolute volume did not significantly affect the EF calculation. The relationship of Auto EF to manual EF was similar in the 97 patients with ischemic disease and regional wall motion abnormalities (*r* = 0.96; limits of agreement = 5%) as in 53 patients with nonischemic cardiomyopathy (*r* = 0.97; limits of agreement = 6%) (Fig. 4). Despite requiring some manual editing in 23% of Auto EF cases, the overall time requirement for biplane Auto EF was significantly lower than manual tracing of biplane EF: 48 ± 26 s versus 102 ± 21 s, respectively (*p* < 0.01).

**Comparison with visual estimation.** Auto EF also correlated well with visual EF by expert readers (*r* = 0.96; *p* <

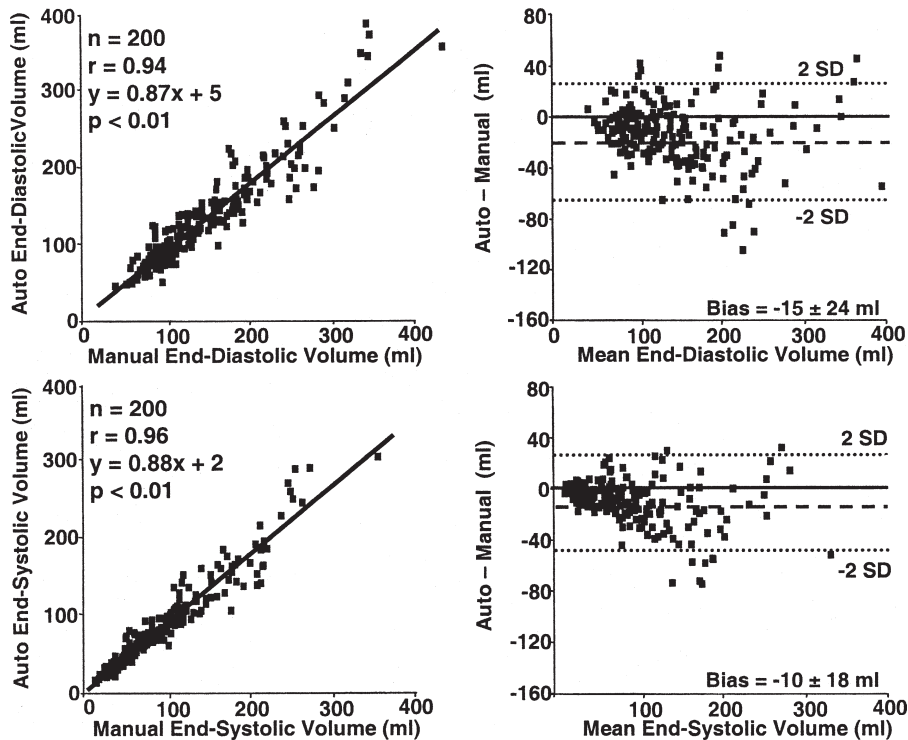


**Figure 2** Auto EF Versus Manual Biplane Simpson's Rule

Ejection fraction (EF) scatter plots with linear regression (left) and Bland-Altman (right) analyses of assessment of biplane left ventricular EF by Auto EF versus manual tracings using Simpson's rule, demonstrating a close correlation and narrow limits of agreement.

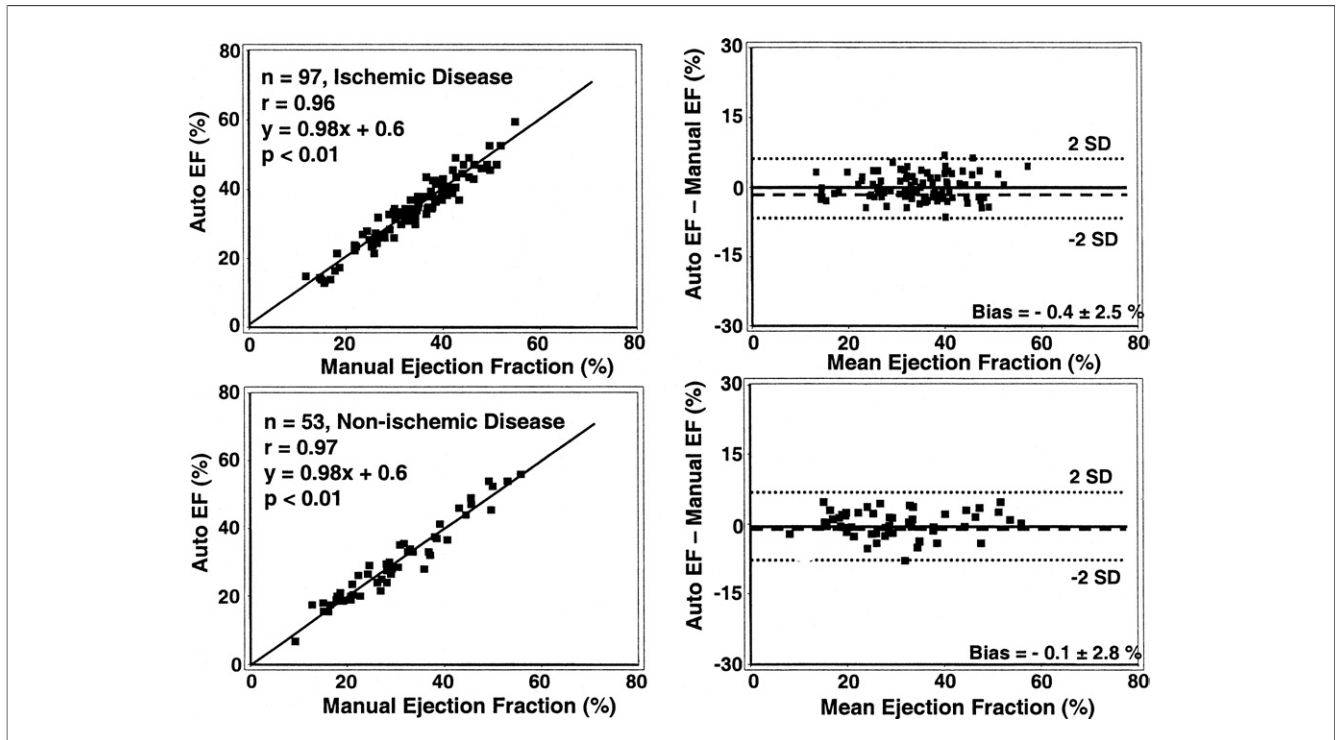
0.001), with a bias of 2%, although limits of agreement were wider at 10% (Fig. 5). Of interest, the widest variability occurred in the 30% to 35% EF range, which is the threshold used for determining defibrillator and resynchronization therapy (1). Novice readers with 1 month of echocardiography training performed well for their level

with a significant correlation with manual biplane EF ( $r = 0.82$ ;  $p < 0.01$ ) (Fig. 6). The novice readers had wider limits of agreement than expert readers, as expected (19% vs. 10%, respectively;  $p < 0.05$ ). The novice readers, however, achieved similar favorable results with Auto EF ( $r = 0.96$ ;  $p < 0.001$ ), with 7% limits of agreement, even though they



**Figure 3** Auto EF Versus Manual Biplane Simpson's Rule Volumes

Scatter plots with linear regression (left) and Bland-Altman (right) analyses of assessment of left ventricular end-diastolic (top) and end-systolic (bottom) volumes by Auto EF versus manual tracings using Simpson's rule, demonstrating a close correlation with a tendency for slight underestimation of volume by Auto EF.



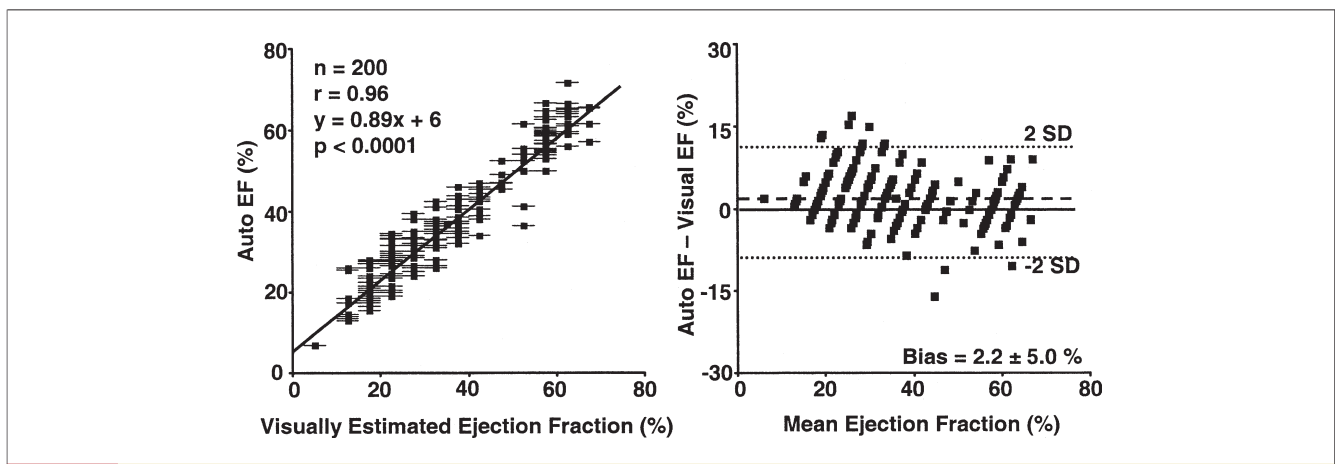
**Figure 4** Comparison of Auto EF in Patients With Ischemic Heart Disease Versus Others

Scatter plots with linear regression (left) and Bland-Altman (right) analyses of assessment of biplane ejection fraction (EF) by Auto EF versus manual tracings in 97 patients with ischemic disease (top) and regional wall abnormalities and 53 patients with nonischemic cardiomyopathy (bottom), demonstrating similar close correlations and narrow limits of agreement.

operated Auto EF for their first time. Respective variability analyses for these methods appear in Table 2, demonstrating significantly lower interobserver and intraobserver variability by Auto EF.

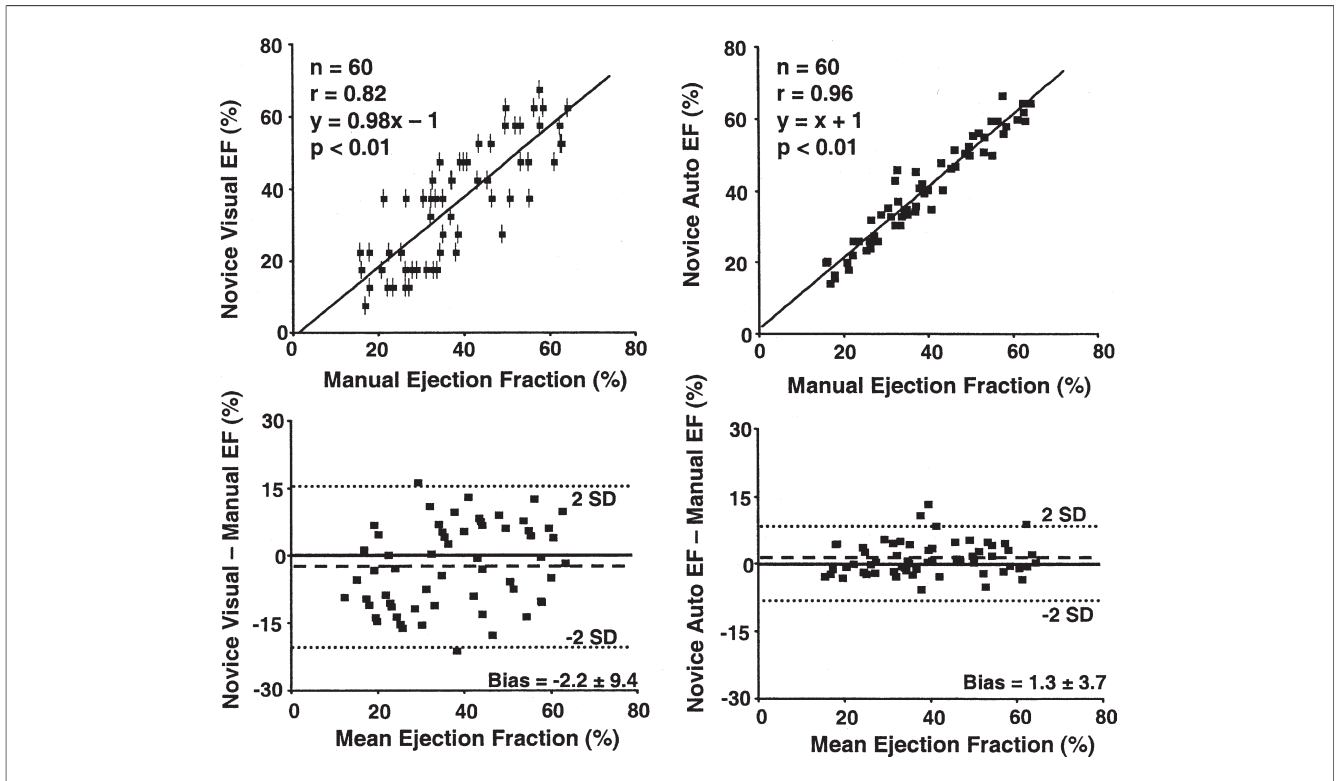
**Comparison with MRI.** End-diastolic volumes ranged from 102 to 368 ml, end-systolic volumes ranged from 33 to

275 ml, and EF ranged from 9% to 72% in the 21 patients with both imaging studies. A favorable correlation was observed between Auto EF and MRI EF:  $r = 0.95$ ; 95% confidence interval 0.88 to 0.98, bias  $-0.3\%$ , and limits of agreement 12% (Fig. 7). End-diastolic and end-systolic volumes were also significantly correlated:  $r = 0.92$  (95% confi-



**Figure 5** Auto EF Versus Visual EF by Expert Readers

Scatter plots with linear regression (left) and Bland-Altman (right) analyses of assessment of biplane left ventricular ejection fraction (EF) by Auto EF versus visual assessment by expert readers, demonstrating a significant correlation but wider limits of agreement. The EF was visually estimated by 5% ranges, which appear as horizontal bars.



**Figure 6** Auto EF Versus Visual EF by Novice Readers

Results of linear regression (top) and Bland-Altman (bottom) analyses of assessment of left ventricular ejection fraction (EF) by novice trainee readers compared with manual biplane tracing by expert readers. Their visual assessment (left) was in 5% ranges and appear as vertical bars. Their results operating Auto EF for the first time (right) demonstrate a closer correlation and more favorable limits of agreement.

dence interval 0.81 to 0.97) and  $r = 0.96$  (95% confidence interval 0.90 to 0.98), respectively ( $p < 0.001$ ). Auto EF, however, underestimated absolute LV volumes, with a bias of  $-45 \pm 29$  ml for end-diastolic volumes,  $-26 \pm 22$  ml for end-systolic volumes, and  $-36 \pm 27$  ml when combined.

## Discussion

This is the first study to demonstrate the utility of Auto EF, which uses a unique artificial intelligence pattern recognition program to rapidly and reproducibly determine EF from routine 2D echocardiographic images. Unlike previous automated border-detection methods that were highly dependent on gain settings (15–20), Auto EF operates on routine grayscale images with routine gain settings to rapidly determine LV volumes and EF in a high percentage

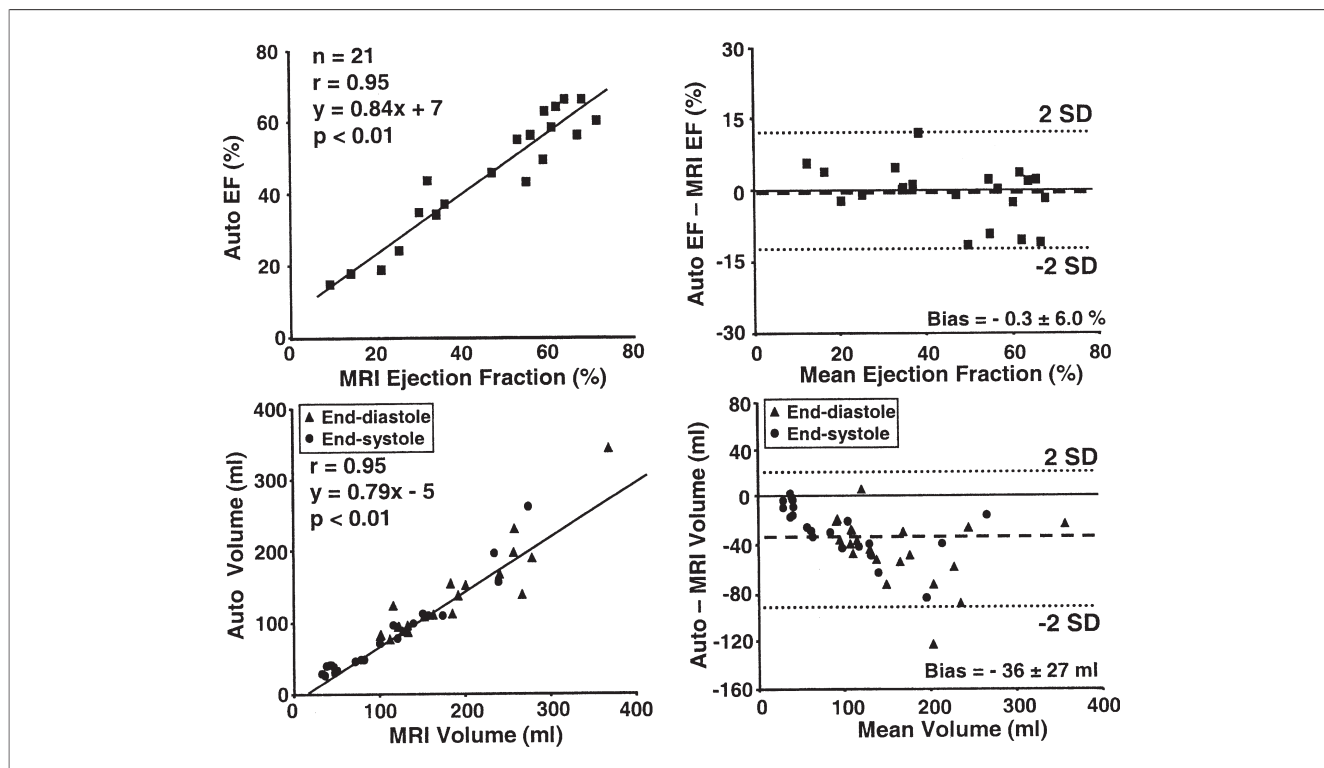
of consecutive patients with a variety of pathologies. Auto EF values closely correlated with manual endocardial tracing of EF by biplane Simpson’s rule EF in a large group of patients and MRI EF in a smaller subgroup of patients who had both studies. Auto EF was significantly less time consuming than the manual method, including when manual editing of the Auto EF contour was required. Although Auto EF underestimated absolute LV volumes when compared with MRI, EF was similar. Auto EF also correlated well with visual EF by expert readers with less variability. Finally, visual EF was less accurate by trainee readers, as expected, but trainee-operated Auto EF had favorable results similar to those of experienced operators.

Ejection fraction is of major importance to clinical management of patients with cardiac disease, in particular, heart failure (1,2–5,7). Ejection fraction has been used as an outcome variable in several clinical studies (32,33) and is a principal selection criterion for implantable cardioverter-defibrillator (6) and resynchronization therapy (8,9). Two-dimensional echocardiography is currently the most commonly used technique for EF, with manual 2D tracing of biplane EF accepted as the quantitative standard (26). However, the extra time required for manual tracing makes visual assessment of EF popular in busy clinical practices. Visual assessment, however, is highly dependent on training

**Table 2** Variability of Ejection Fraction Determinations (EF Units)

	Interobserver Variability	Intraobserver Variability
Visual EF by expert readers	$9.8 \pm 5.7\%$	$3.4 \pm 2.9\%$
Manual EF by biplane Simpson’s rule	$2.9 \pm 2.1\%^*$	$2.0 \pm 1.3\%$
Auto EF	$1.3 \pm 1.7\%^{\dagger}$	$0.5 \pm 1.2\%^{\dagger}$

Values expressed as absolute difference  $\pm$  SD (EF units). \* $p < 0.05$  versus visual ejection fraction (EF) by expert readers.  $\dagger p < 0.05$  versus manual EF by biplane Simpson’s rule.



**Figure 7** Auto EF Versus Magnetic Resonance Imaging

Scatter plots with linear regression (left) and Bland-Altman (right) analyses of assessment of left ventricular ejection fraction (EF) by Auto EF versus magnetic resonance imaging (MRI) (top) and combined end-systolic and end-diastolic volumes from the same patients (bottom), demonstrating significant correlations but underestimation of absolute volumes.

and experience. Amico et al. (23) previously showed superiority of visual EF to computer-assisted manual tracing of videotaped images. However, marked improvements in 2D imaging have occurred since that publication, including harmonic imaging (34), digital acquisition and archiving (35), and continued refinements in transducer design and signal processing. The results of the present study demonstrate that visual EF by expert readers was highly correlated with manual biplane EF within clinically acceptable limits of agreement. However, variability was reduced and agreement improved with Auto EF, in particular for novice readers, with minimal added time.

Previous methods of automated or semi-automated EF determination have been proposed for angiography (36), computerized tomography (37), positron emission tomography (38), MRI (11,12,30,39), and echocardiography (15-17,40,41). Auto EF differs markedly from previous automated echocardiographic methods that used backscatter signal analysis to detect the blood-tissue interface and constructed time-area and time-volume curves on-line. (15-20). Although useful for trained operators, previous methods were highly dependent on gain settings and image quality, which limited widespread clinical use. Auto EF, uniquely, applied concepts of learned pattern recognition from artificial intelligence theory to identify LV shapes and patterns. It mimicked human tracing by using an extensive

database of prior manual tracings. Our correlations of biplane Auto EF to MRI volumetric EF are similar to previous findings. Limits of agreement were 13% by Jenkins et al. (12) and 17.7% to 19.9% by Chuang et al. (30) for 2D echo biplane EF and MRI EF. Jenkins et al. (12) reported similar underestimation of volumes by 2D echocardiography compared with MRI (end-diastolic volumes -54 ml, end-systolic volumes -28 ml), which improved with 3-dimensional imaging (11,12), usually because of more complete imaging of the LV apex. Another reason for greater volumes by MRI appears to be inclusion of trabeculations in the blood volume (11,12,30). Echocardiographic Auto EF is easier to accomplish, requires shorter scan times and significantly less post-processing, and was performed portably in several cases.

**Study limitations.** A limitation was that 3-dimensional echocardiography was not part of the study. However, EF correlated favorably with MRI EF in a subset of patients with both imaging techniques, although an underestimation of absolute volumes was observed. Underestimation of LV volumes by 2D imaging may occur from foreshortening of the LV apex and may be improved with either 3-dimensional echocardiography or MRI (11,12,30). The slight but consistent underestimation of absolute LV volumes by Auto EF compared with manual 2D tracing may augment this limitation. However, Auto EF was in close



agreement with manual tracing by biplane Simpson's rule, which is an accepted standard for EF in many important research trials (6-10,26). Another limitation is with variable gating from the electrocardiogram for the start and end of the cardiac cycle. Improvements in frame rates, triggering, and beat averaging will likely overcome this. A potential limitation of this method is that it is off line and analyzes 1 cardiac cycle at a time, unlike automated border detection, which has a continuous on-line output. This favors automated border detection for pressure-volume loop analysis (20) during rapid alterations in loading, but rapid off-line determination of EF is suitable for practical purposes.

#### Acknowledgments

The authors are grateful to Sriram Krishnan, PhD, and associates at Siemens Medical Solutions for creation of the Auto EF software and to Helene Houle, RDMS, for technical support. They are also grateful to the University of Pittsburgh Presbyterian Hospital echocardiography laboratory attending staff, fellows, and sonographers for their time and expertise.

**Reprint requests and correspondence:** Dr. John Gorcsan III, University of Pittsburgh, Scaife 564, 200 Lothrop Street, Pittsburgh, Pennsylvania 15213-2582. E-mail: gorcsanj@upmc.edu.

#### REFERENCES

- Hunt SA, Abraham WT, Chin MH, et al. ACC/AHA 2005 guideline update for the diagnosis and management of chronic heart failure. *Circulation* 2005;112:e154-235.
- Aaronson KD, Schwartz JS, Chen TM, Wong KL, Goin JE, Mancini DM. Development and prospective validation of a clinical index to predict survival in ambulatory patients referred for cardiac transplant evaluation. *Circulation* 1997;95:2660-7.
- Bart BA, Shaw LK, McCants CBJ, et al. Clinical determinants of mortality in patients with angiographically diagnosed ischemic or nonischemic cardiomyopathy. *J Am Coll Cardiol* 1997;30:1002-8.
- Curtis JP, Sokol SI, Wang Y, et al. The association of left ventricular ejection fraction, mortality, and cause of death in stable outpatients with heart failure. *J Am Coll Cardiol* 2003;42:736-42.
- Cohn JN, Johnson GR, Shabetai R, et al. Ejection fraction, peak exercise oxygen consumption, cardiothoracic ratio, ventricular arrhythmias, and plasma norepinephrine as determinants of prognosis in heart failure. The V-HeFT VA Cooperative Studies Group. *Circulation* 1993;87:V15-6.
- Moss AJ, Zareba W, Hall WJ, et al., for the Multicenter Automatic Defibrillator Implantation Trial II Investigators. Prophylactic implantation of a defibrillator in patients with myocardial infarction and reduced ejection fraction. *N Engl J Med* 2002;346:877-83.
- Bardy GH, Lee KL, Mark DB, et al. Amiodarone or an implantable cardioverter-defibrillator for congestive heart failure. *N Engl J Med* 2005;352:225-37.
- Abraham WT, Fisher WG, Smith AL, et al. Cardiac resynchronization in chronic heart failure. *N Engl J Med* 2002;346:1845-53.
- Bristow MR, Saxon LA, Boehmer J, et al. Cardiac-resynchronization therapy with or without an implantable defibrillator in advanced chronic heart failure. *N Engl J Med* 2004;350:2140-50.
- Cleland JG, Daubert JC, Erdmann E, et al. The effect of cardiac resynchronization on morbidity and mortality in heart failure. *N Engl J Med* 2005;352:1539-49.
- Corsi C, Lang RM, Veronesi F, et al. Volumetric quantification of global and regional left ventricular function from real-time three-dimensional echocardiographic images. *Circulation* 2005;112:1161-70.
- Jenkins C, Bricknell K, Hanekom L, Marwick TH. Reproducibility and accuracy of echocardiographic measurements of left ventricular parameters using real-time three-dimensional echocardiography. *J Am Coll Cardiol* 2004;44:878-86.
- Kuhl HP, Schreckenberg M, Rulands D, et al. High-resolution transthoracic real-time three-dimensional echocardiography: quantitation of cardiac volumes and function using semi-automatic border detection and comparison with cardiac magnetic resonance imaging. *J Am Coll Cardiol* 2004;43:2083-90.
- Gorcsan J, Pandey P, Sade LE. Influence of hand-carried ultrasound on bedside patient treatment decisions for consultative cardiology. *J Am Soc Echocardiogr* 2004;17:50-5.
- Perez JE, Waggoner AD, Barzilay B et al. On-line assessment of ventricular function by automatic boundary detection and ultrasonic backscatter imaging. *J Am Coll Cardiol* 1992;19:313-20.
- Vandenberg BF, Rath LS, Stuhlmuller P, Melton HEJ, Skorton DJ. Estimation of left ventricular cavity area with an on-line, semiautomated echocardiographic edge detection system. *Circulation* 1992;86:159-66.
- Gorcsan J, Lazar JM, Schulman DS, Follansbee WP. Comparison of left ventricular function by echocardiographic automated border detection and by radionuclide ejection fraction. *Am J Cardiol* 1993;72:810-5.
- Gorcsan J, Romand JA, Mandarino WA, Deneault LG, Pinsky MR. Assessment of left ventricular performance by on-line pressure-area relations using echocardiographic automated border detection. *J Am Coll Cardiol* 1994;23:242-52.
- Gorcsan J, Morita S, Mandarino WA, et al. Two-dimensional echocardiographic automated border detection accurately reflects changes in left ventricular volume. *J Am Soc Echocardiogr* 1993;6:482-9.
- Gorcsan J, Gasior TA, Mandarino WA, Deneault LG, Hattler BG, Pinsky MR. On-line estimation of changes in left ventricular stroke volume by transesophageal echocardiographic automated border detection in patients undergoing coronary artery bypass grafting. *Am J Cardiol* 1993;72:721-7.
- Erbel R, Schweizer P, Lambertz H, et al. Echoventriculography—a simultaneous analysis of two-dimensional echocardiography and cineventriculography. *Circulation* 1983;67:205-15.
- Bellenger NG, Burgess MI, Ray SG, et al. Comparison of left ventricular ejection fraction and volumes in heart failure by echocardiography, radionuclide ventriculography and cardiovascular magnetic resonance; are they interchangeable? *Eur Heart J* 2000;21:1387-96.
- Amico AF, Lichtenberg GS, Reisner SA, Stone CK, Schwartz RG, Meltzer RS. Superiority of visual versus computerized echocardiographic estimation of radionuclide left ventricular ejection fraction. *Am Heart J* 1989;118:1259-65.
- van Royen N, Jaffe CC, Krumholz HM, et al. Comparison and reproducibility of visual echocardiographic and quantitative radionuclide left ventricular ejection fractions. *Am J Cardiol* 1996;77:843-50.
- McGowan JG, Cleland JG. Reliability of reporting left ventricular systolic function by echocardiography: a systematic review of 3 methods. *Am Heart J* 2003;146:388-97.
- Lang RM, Bierig M, Devereux RB, et al. Recommendations for chamber quantification: a report from the American Society of Echocardiography's Guidelines and Standards Committee and the Chamber Quantification Writing Group. *J Am Soc Echocardiogr* 2005;18:1440-63.
- Georgescu B, Zhou XS, Comaniciu D, Gupta A. Database-guided segmentation of anatomical structures with complex appearance. Proceedings of the 2005 IEEE Computer Society Conference on Computer Vision and Pattern Recognition. 2:429-36.
- Comaniciu D, Zhou XS, Krishnan S. Robust real-time myocardial border tracking for echocardiography: an information fusion approach. *IEEE Trans Med Imaging* 2004;23:849-60.
- Gorcsan J, Kanzaki H, Bazaz R, Dohi K, Schwartzman D. Usefulness of echocardiographic tissue synchronization imaging to predict acute response to cardiac resynchronization therapy. *Am J Cardiol* 2004; 93:1178-81.
- Chuang ML, Hibberd MG, Salton CJ, et al. Importance of imaging method over imaging modality in noninvasive determination of left ventricular volumes and ejection fraction: assessment by two- and three-dimensional echocardiography and magnetic resonance imaging. *J Am Coll Cardiol* 2000;35:477-84.
- Bland JM, Altman DG. Statistical methods for assessing agreement between two methods of clinical measurement. *Lancet* 1986;1:307-10.

32. Sharpe N, Murphy J, Smith H, Hannan S. Treatment of patients with symptomless left ventricular dysfunction after myocardial infarction. *Lancet* 1988;1:255-9.
33. Doughty RN, Whalley GA, Gamble G, MacMahon S, Sharpe N. Left ventricular remodeling with carvedilol in patients with congestive heart failure due to ischemic heart disease. Australia-New Zealand Heart Failure Research Collaborative Group. *J Am Coll Cardiol* 1997;29:1060-6.
34. Rubin DN, Yazbek N, Garcia MJ, Stewart WJ, Thomas JD. Qualitative and quantitative effects of harmonic echocardiographic imaging on endocardial edge definition and side-lobe artifacts. *J Am Soc Echocardiogr* 2000;13:1012-8.
35. Thomas JD, Adams DB, Devries S, et al. Guidelines and recommendations for digital echocardiography. *J Am Soc Echocardiogr* 2005;18:287-97.
36. Staal EM, de Heer M, Jukema JW, et al. End-diastolic and end-systolic volume from the left ventricular angiogram: how accurate is visual frame selection? Comparison between visual and semi-automated computer-assisted analysis. *Int J Cardiovasc Imaging* 2003;19:259-66.
37. Schlosser T, Pagonidis K, Herborn CU, et al. Assessment of left ventricular parameters using 16-MDCT and new software for endocardial and epicardial border delineation. *AJR Am J Roentgenol* 2005;184:765-73.
38. Kanayama S, Matsunari I, Hirayama A, et al. Assessment of global and regional left ventricular function by electrocardiographic gated N-13 ammonia positron emission tomography in patients with coronary artery disease. *Circ J* 2005;69:177-82.
39. Danilouchkine MG, Westenberg JJ, Lelieveldt BP, Reiber JH. Accuracy of short-axis cardiac MRI automatically derived from scout acquisitions in free-breathing and breath-holdings modes. *MAGMA* 2005;18:7-18.
40. Sugioka K, Hozumi T, Watanabe H, et al. Rapid and accurate noninvasive assessment of global left ventricular systolic function using biplane advanced automated contour tracking method. *J Am Soc Echocardiogr* 2003;16:1237-43.
41. Marcus RH, Bednarz J, Coulden R, Shroff S, Lipton M, Lang RM. Ultrasonic backscatter system for automated on-line endocardial boundary detection: evaluation by ultrafast computed tomography. *J Am Coll Cardiol* 1993;22:839-47.

 **APPENDIX**

To view videos that accompany Figure 1, please see the online version of this article.